



A Review on Alopecia Areata

Deepak Kumar Mahto, Dr.Gaurav Kumar Sharma, Dr.Kaushal Kishore Chandrul

STUDENT OF B.PHARMA 4TH YEAR, HOD, PRINCIPAL,
DEPARTMENT OF PHARMACY, MEWAR UNIVERSITY, CHITTORGARH, RAJASTHAN INDIA.

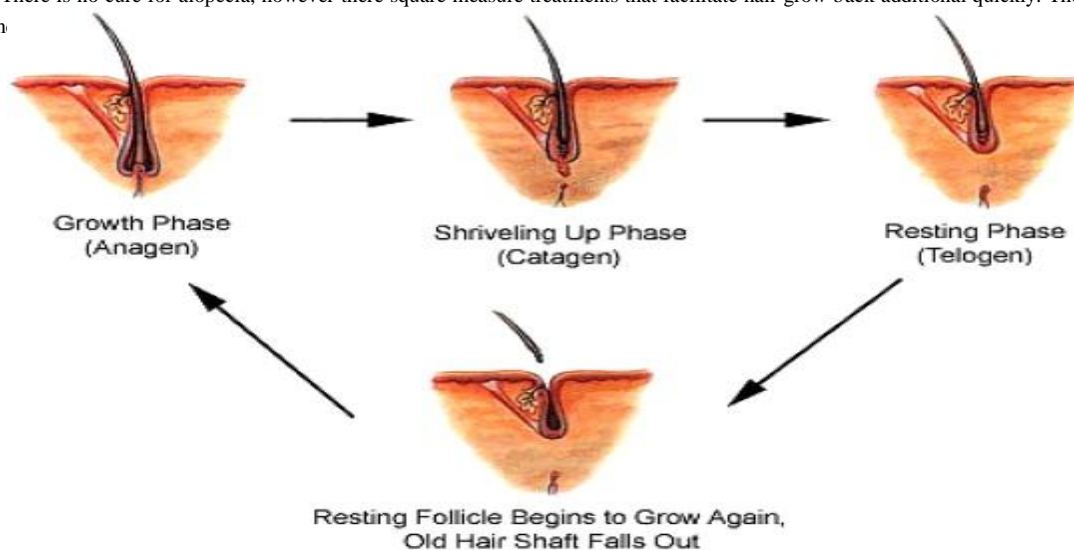
ABSTRACT

Alopecia areata is a complicated genetic, immune-mediated unwellness that targets anagen hair follicles. The unwellness affects youngsters and adults and is characterized by spherical or oval patches of hair loss, loss of all scalp hair (alopecia totalis), hair (alopecia universalis), or ophiasis pattern hair loss. Patients might also gift with uneven loss in multiple hair-bearing areas. ordinarily associated diseases embody respiratory disorder, rhinitis, atopic eczema, thyroid unwellness, and autoimmune diseases, like inflammation and skin condition. Nail abnormalities could precede, follow, or occur at the same time with hair loss activity. alopecia has no far-famed age, race, or ethnic preponderance and in distinction to different response diseases like inflammation or lupus, the follicle doesn't typically sustain permanent injury and maintains its potential to acquire hair. it's calculable that alopecia affects between 6 and 7 million people within the U.S . Genes, the immune and nervous systems have all been concerned within the pathological process of alopecia. though several treatments ar obtainable, there's still no cure. Bolstered by new scientific and translational opportunities from recently revealed genome-wide association studies, AN bold treatment development program has recently been initiated by the National alopecia Foundation

Keywords :-Causes and Symptoms of alopecia areata , its diagnosis , potential treatments and conclusion.

Introduction of Alopecia Areata :-

Alopecia areata is a common autoimmune disorder that often results in unpredictable hair loss. It affects roughly 6.8 million people in the United States and 147 million people worldwide. In most cases, hair falls out in small patches around the size of a quarter. There may be only a few patches, but alopecia areata can affect wider areas of the scalp. If there is a complete loss of hair on the scalp, doctors diagnose alopecia totalis. If there is hair loss throughout the entire body, the condition is called alopecia universalis. Alopecia can affect anyone, regardless of age, gender, or race, though most cases develop before the age of 30. In this article, we look at the causes and symptoms of alopecia areata, its diagnosis, and potential treatments. Alopecia areata may be a malady that happens once the system attacks hair follicles and causes hair loss. Hair follicles square measure the structures in skin that type hair. whereas hair may be lost from any a part of the body, alopecia sometimes affects the pinnacle and face. Hair usually falls go into tiny, spherical patches regarding the dimensions of 1 / 4, however in some cases, hair loss is additional intensive. the general public with the malady square measure healthy and haven't any alternative symptoms. The course of alopecia varies from person to person. Some have bouts of hair loss throughout their lives, whereas others solely have one episode. Recovery is unpredictable too, with hair regrowing absolutely in some individuals however not others. There is no cure for alopecia, however there square measure treatments that facilitate hair grow back additional quickly. There are resources to assist in



TYPES OF ALOPECIA AREATA:-

There are three main types of alopecia areata:

- **Patchy alopecia areata.** In this type, which is the most common, hair loss happens in one or more coin-sized patches on the scalp or other parts of the body.
- **Alopecia totalis.** People with this type lose all or nearly all of the hair on their scalp.
- **Alopecia universalis.** In this type, which is rare, there is a complete or nearly complete loss of hair on the scalp, face, and rest of the body.

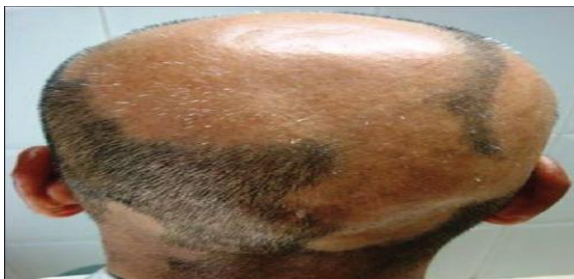Other forms of Alopecia:-

Diffuse alopecia ends up in sharp and sudden cutting of the hair everywhere the scalp. It will be arduous to diagnose as a result of it's a great deal like different types of hair loss like telogen emission or male or feminine pattern hair loss.

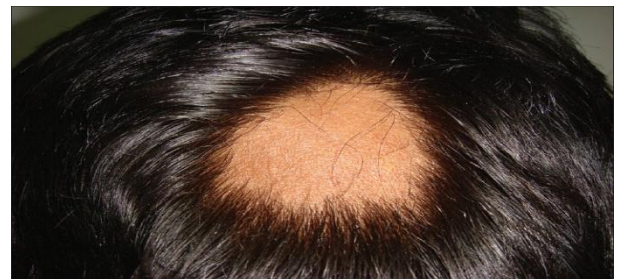Ophiasis phalacroscis includes a distinctive pattern of hair loss, which has the edges and lower back of the scalp (called the os region) within the form of a band. Ophiasis alopecia will be tougher to treat, as a result of it doesn't respond as quickly to medication.

With every type of alopecia, hair loss and regrowth will be terribly unpredictable and alternating (happen over and over), for several years. tho' for a few individuals, hair might grow and not fall out once more. presently there's no cure for alopecia. However, your hair follicles stay alive in spite of what sort you've got. this implies that hair regrowth will happen once a few years of severe or widespread hair loss.

There are many treatment choices accessible for these completely different types of alopecia. the sole thanks to make sure what sort of alopecia you'll have, and also the best course for treatment, is to create an arrangement along with your doctor.



Localized patch of alopecia areata

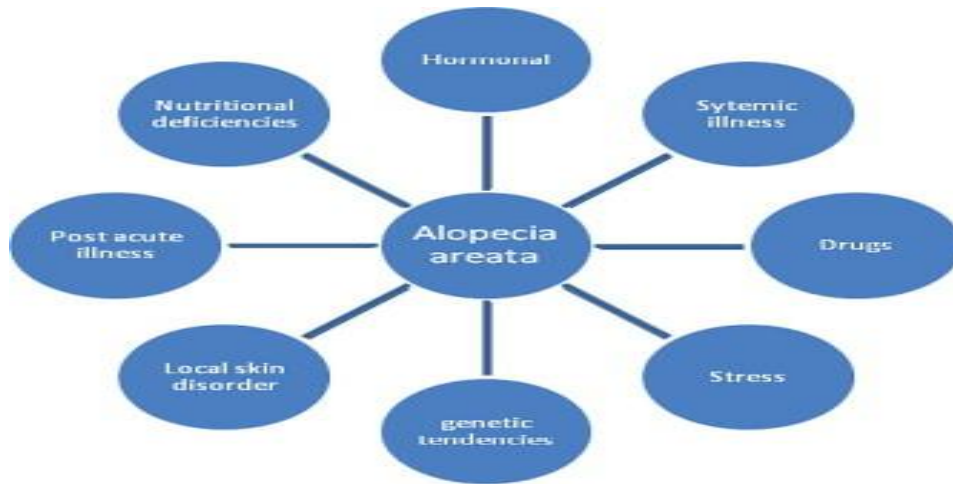

Small patches, merging and forming larger patch

Causes:-

- ❖ The condition happens once white blood cells attack the cells in hair follicles, inflicting them to shrink and dramatically hamper hair production. it's unknown exactly what causes the body's system to focus on hair follicles during this means. While scientists are unsure why these changes occur, it appears that biology is concerned as alopecia is a lot of possible to occur in an exceedingly one who incorporates a shut friend with the illness. One in 5 individuals with the illness incorporates a friend WHO has conjointly developed alopecia. Other analysis has found that a lot of individuals with a case history of alopecia even have a private or case history of alternative reaction disorders, like immediate allergy, a disorder characterised by a bent to be hyper allergic, redness, and skin disease.

Despite what many of us assume, there's little or no scientific proof to support the read that alopecia is caused by stress. Extreme cases of stress may probably trigger the condition, however most up-to-date analysis points toward a genetic cause.



Multifactorial etiology of alopecia areata.(fig)

Symptoms:-

The most outstanding symptom of alopecia is uneven hair loss. Coin-sized patches of hair begin to fall out, chiefly from the scalp. Any website of hair growth is also affected, though, together with the beard and eyelashes. The loss of hair are often fast, developing in barely a couple of days or over a amount of a couple of weeks. There is also skin sensation or burning within the space before hair loss. The hair follicles don't seem to be destroyed so hair will re-grow if the inflammation of the follicles subsides. those who expertise simply a couple of patches of hair loss typically have a spontaneous, full recovery with none style of treatment.

About thirty p.c of people United Nations agency develop alopecia notice that their condition either becomes additional intensive or becomes a continual cycle of hair loss and regrowth.

About 1/2 patients pass though alopecia among one year, however several can expertise over one episode. Around ten p.c of individuals can prolong to develop phalacroasis totalis or phalacroasis universalis. Alopecia areata also can have an effect on the fingernails and toenails, and generally these changes ar the primary sign that the condition is developing.

There are variety of tiny changes which will occur to nails:

- pinpoint dents seem
- white spots and features seem
- nails become rough
- nails lose their shine
- nails become skinny and split

Additional clinical signs include

- Exclamation mark hairs: this happens once few short hairs that get narrower at their bottom and grow in or round the edges of bald spots.
- Cadaver hairs: this can be wherever hairs break before reaching the skin surface.
- White hair: this could grow in areas full of hair loss.

Alopecia areata primarily affects hair, however in some cases, there ar nail changes moreover. folks with the sickness ar sometimes healthy and haven't any different symptoms.

Hair Changes Alopecia areata usually begins with unforeseen loss of spherical or oval patches of hair on the scalp, however any a part of the body is also affected, like the beard space in men, or the eyebrows or eyelashes. round the edges of the patch, there ar typically short broken hairs or “exclamation point” hairs that ar narrower at their base than their tip. there's sometimes no sign of a rash, redness, or scarring on the clean patches. Some folks say they feel tingling, burning, or cutaneous sensation on patches of skin right before the hair falls out.

When a clean patch develops, it's exhausting to predict what is going to happen next. the probabilities include

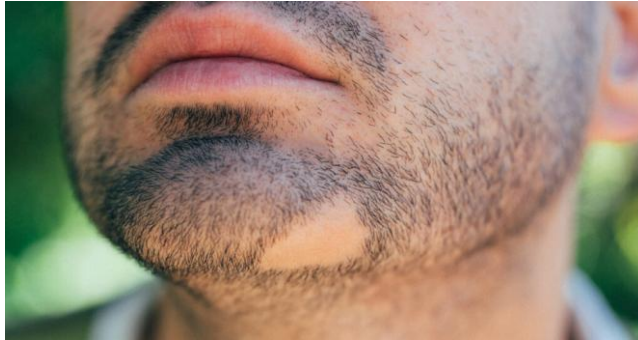- The hair regrows at intervals a number of months. could|it's going to|it should} look white or grey initially however may regain its natural color over time.
- Additional clean patches develop. generally hair regrows within the initial patch whereas new clean patches ar forming.
- Small patches be a part of to make larger ones. In rare cases, hair is eventually lost from the whole scalp, known as phalacroasis totalis.
- There is a progression to complete loss of hair, a kind of the sickness known as phalacroasis universalis. this is often rare.

In most cases, the hair regrows, however there is also sequent episodes of hair loss. The hair tends to acquire on its own additional totally in folks with:

- Less intensive hair loss.
- Later age of onset.
- No nail changes.
- No case history of the sickness.
- Nail Changes

Nail changes like ridges and pits occur in some folks, particularly people who have additional intensive hair loss.

❖ **Diagnosis:**



Doctors are sometimes able to diagnose alopecia fairly simply by examining symptoms. They could investigate the degree of hair loss and examine hairs from affected areas underneath a magnifier.

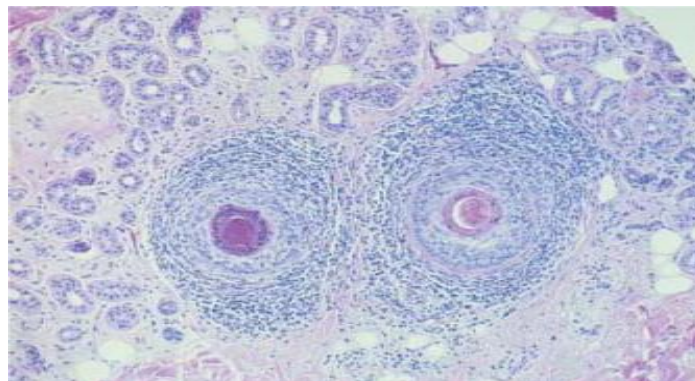
Doctors typically diagnose alopecia by:

- Examining the areas wherever the hair has been lost and looking out at your nails.
- Examining your hair and follicle openings employing a hand-held magnifying device.
- Asking regarding your medical and case history.

Other health conditions will cause hair to fall go into identical pattern as alopecia. To work out if another condition is inflicting the hair loss, your doctor might order blood tests or a skin diagnostic test

Histopathology:-

The histopathologic options of alopecia rely on the stage of the present episode and don't vary with the age, sex or race of the patient (Igarashi et al., 1981). Within the acute stage, terminal hairs are encircled by neural structure lymphocytes ('swarm of bees'). Within the acute stage, faded anagen and enhanced catagen and telogen hairs are characteristically found. Within the chronic stage, faded terminal and enhanced miniaturized hairs are found, with variable inflammation. Technique studies have shown deposits of C3, IgG, and immune gamma globulin on the basement membrane of the inferior part of the follicle (Shimmer and Parker, 2001). Throughout recovery, increasing numbers of terminal anagen hairs from regrowth of miniaturized hairs and a scarcity of inflammation are noted. Alopecia areata ought to histologically be suspected once high percentages of telogen hair or miniaturized hair are found, even within the absence of a peribulbar leucocyte infiltrate. The histopathology of the lesion in ADTA reveals infiltration of mononuclear cells round the hair follicles and distinguished pigment incontinence (Garcia-Hernandez, 2000).



Swarm of bees' appearance of the inflammatory infiltrate around terminal hair follicles in alopecia areata. (H&E stain).

Testing

The **pull test** helps evaluate diffuse scalp hair loss. Gentle traction is exerted on a bunch of hairs (about 40) on at least 3 different areas of the scalp, and the number of extracted hairs is then counted and examined microscopically. Normally, < 3 telogen-phase hairs should come out with each pull. If > 4 to 6 hairs come out with each pull, the pull test is positive and is suggestive of telogen effluvium.

The **pluck test** involves sequentially pulling out about 50 individual hairs abruptly ("by the roots"). The roots of the plucked hairs are examined microscopically to determine the phase of growth and thus help diagnose a defect of telogen or anagen or an occult systemic disease. Anagen hairs have sheaths attached to their roots; telogen hairs have tiny bulbs without sheaths at their roots. Normally, 85 to 90% of hairs are in the anagen phase, about 10 to 15% are in telogen phase, and < 1% are in catagen phase. Telogen effluvium shows an increased percentage of telogen-phase hairs on microscopic examination (typically > 20%), whereas anagen effluvium shows a decrease in telogen-phase hairs and an increased number of broken hairs. Primary hair shaft abnormalities are usually obvious on microscopic examination of the hair shaft.

Scalp biopsy is indicated when alopecia persists and diagnosis is in doubt. Biopsy may differentiate scarring from non-scarring forms. Specimens should be taken from areas of active inflammation, ideally at the border of a bald patch. Fungal and bacterial cultures may be useful.

Daily hair counts can be done by the patient to quantify hair loss when the pull test is negative. Hairs lost during the first morning combing or during washing are collected in clear plastic bags daily for 14 days. The number of hairs in each bag is then recorded. Scalp hair counts of > 100/day are abnormal except after shampooing, when hair counts of up to 250 may be normal. Hairs may be brought in by the patient for microscopic examination.

❖ Treatment

There is presently no cure for alopecia, though there are some types of treatment that may be steered by doctors to assist hair re-grow additional quickly.

Treatments for gentle alopecia

INTRALESIONAL adrenal cortical steroid INJECTIONS

This methodology of treatment — the foremost common sort of treatment for alopecia — uses corticosteroids that are injected into vacant patches of skin with a little needle. These injections square measure perennial regarding each four to 6 weeks and square measure sometimes given by a specialist.

TOPICAL Rogaine

With this type of treatment, a five-hitter topical Rogaine resolution is applied once or doubly daily to assist stimulate hair on the scalp, eyebrows and beard to grow. 2 and five-hitter topical Rogaine solutions square measure obtainable however aren't sometimes effective for alopecia once used alone, however once applied together with topical adrenal cortical steroid medications, some individuals see improved results.

ANTHRALIN CREAM OR OINTMENT

This artificial, tar-like substance — conjointly wide used for skin disease — may be a common sort of treatment for alopecia. Anthralin is applied to the smooth-faced patches once daily and so washed off usually when a brief time (usually 30-60 minutes later) or in some cases, when many hours

TOPICAL CORTICOSTEROIDS

In alopecia, corticosteroids square measure thought to decrease the inflammation round the follicle. Topical steroids will be available in totally different brands, strengths and preparations, like solutions, lotions, foams, creams, or ointments.

Treatments for in depth alopecia, baldness totalis and baldness universalis

ORAL CORTICOSTEROIDS

Corticosteroids taken within the sort of a pill area unit typically prescribed for in depth scalp hair loss to do to suppress sickness activity and acquire hair.

TOPICAL therapy

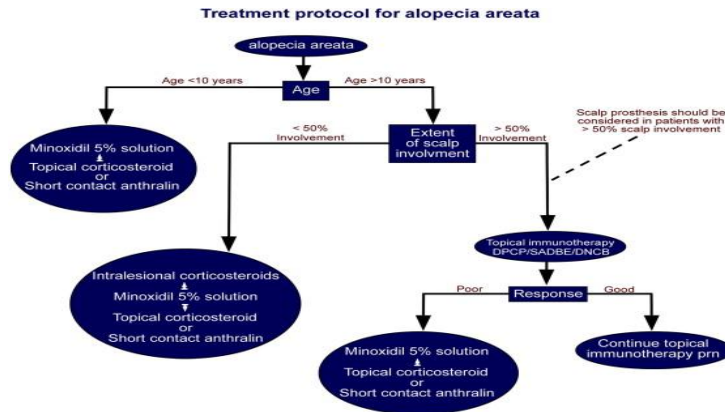
Topical therapy is employed to treat in depth alopecia, baldness totalis and baldness universalis. this type of treatment involves applying chemicals like diphenylprone (DPCP), dinitrochlorobenzene (DNCB) or squaric acid dibutyl organic compound (SADBE) to the scalp. This causes associate degree allergic rash (allergic contact dermatitis) that appears like poison oak or *Hedera helix*, that alters the immune reaction.

IMMUNOMODULATORS: medication to block THE immune reaction

Immunomodulatory medication — specifically, Roman deity enzyme (JAK) inhibitors — like tofacitinib (Xeljanz) and ruxolitinib (Jakafi), area unit a brand new sort of medical aid being tested for alopecia. These medications were originally approved to treat bound blood disorders and atrophic arthritis. they're not approved by the agency for alopecia however, associate degree area unit solely out there right away within the sort of an oral medication. A topical formulation is presently in clinical trials within the us.

Biological medical care

These medications synthesized from recombinant proteins cut back the unhealthy T cells, inhibit T-cell activation and inhibit inflammatory cytokines, suggesting a possible role within the treatment of AA. Enbrel may be a agent and a fusion macromolecule receptor consisting of 2 human TNF receptors and Fc domain of human human gamma globulin G1. Strober et al. administered fifty mg of Enbrel double weekly to patients with moderate to severe AA. They but discovered no vital hair regrowth once twenty four weeks of treatment (Strober et al., 2005). Studies with alternative biological agents within the treatment of AA ar still current. In cases wherever all the treatments fail, alternative choices that are reported for AA ar hair transplant, however recently it's solely been performed in eyebrows with sensible results. Another various is micropigmentation, conjointly called tattoo; it's been used aesthetically to camouflage varied medical conditions associated with medicine.



Algorithm for management of Alopecia areata in different age groups. (*Adapted with permission from the Editor, *J. Am. Acad. Dermatol.* 2010;62:191–202).

CONCLUSION

Alopecia areata encompasses a nice impact on the looks and psyche of the afflicted individual. Moreover, no uniformly dependable treatment is thought. Corticosteroids have shown promising results and ar time tested medication in management over the years. different treatments that are used with some success include: Rogaine, anthralin, DNCB, SADBE, PUVA, cyclosporine. With every treatment, facet effects and cosmetically acceptable improvement should be thought of. Support mechanisms within the type of native support teams ought to be shaped so as to produce content for the affected patients and allay their psychiatric comorbidity

❖ References

- Gilhar A, Etzioni A, Paus R. Alopecia areata. *N Engl J Med.* 2012 Apr 19;366(16):1515-25. [PubMed]
- Pratt CH, King LE, Messenger AG, Christiano AM, Sundberg JP. Alopecia areata. *Nat Rev Dis Primers.* 2017 Mar 16;3:17011. [PMC free article] [PubMed]
- Safavi KH, Muller SA, Suman VJ, Moshell AN, Melton LJ. Incidence of alopecia areata in Olmsted County, Minnesota, 1975 through 1989. *Mayo Clin Proc.* 1995 Jul;70(7):628-33. [PubMed]
- Mirzoyev SA, Schrum AG, Davis MDP, Torgerson RR. Lifetime incidence risk of alopecia areata estimated at 2.1% by Rochester Epidemiology Project, 1990-2009. *J Invest Dermatol.* 2014 Apr;134(4):1141-1142. [PMC free article] [PubMed]
- Rajabi F, Drake LA, Senna MM, Rezaei N. Alopecia areata: a review of disease pathogenesis. *Br J Dermatol.* 2018 Nov;179(5):1033-1048. [PubMed]
- Messenger AG, McKillop J, Farrant P, McDonagh AJ, Sladden M. British Association of Dermatologists' guidelines for the management of alopecia areata 2012. *Br J Dermatol.* 2012 May;166(5):916-26. [PubMed]
- Chu TW, AlJasser M, Alharbi A, Abahussein O, McElwee K, Shapiro J. Benefit of different concentrations of intralesional triamcinolone acetonide in alopecia areata: An intrasubject pilot study. *J Am Acad Dermatol.* 2015 Aug;73(2):338-40. [PubMed]
- Melo DF, Dutra TBS, Baggieri VMAC, Tortelly VD. Intralesional betamethasone as a therapeutic option for alopecia areata. *An Bras Dermatol.* 2018 Mar;93(2):311-312. [PMC free article] [PubMed]
- Ro BI. Alopecia areata in Korea (1982-1994). *J Dermatol.* 1995 Nov;22(11):858-64. [PubMed]
- Lee S, Kim BJ, Lee YB, Lee WS. Hair Regrowth Outcomes of Contact Immunotherapy for Patients With Alopecia Areata: A Systematic Review and Meta-analysis. *JAMA Dermatol.* 2018 Oct 01;154(10):1145-1151. [PMC free article] [PubMed]
- Strazzulla LC, Avila L, Lo Sicco K, Shapiro J. An Overview of the Biology of Platelet-Rich Plasma and Microneedling as Potential Treatments for Alopecia Areata. *J Invest Dermatol Symp Proc.* 2018 Jan;19(1):S21-S24. [PubMed]
- Cervantes J, Jimenez JJ, DelCanto GM, Tosti A. Treatment of Alopecia Areata with Simvastatin/Ezetimibe. *J Invest Dermatol Symp Proc.* 2018 Jan;19(1):S25-S31. [PubMed]
- Iorizzo M, Tosti A. Emerging drugs for alopecia areata: JAK inhibitors. *Expert Opin Emerg Drugs.* 2018 Mar;23(1):77-81. [PubMed]
- Perper M, Aldahan AS, Fayne RA, Emerson CP, Nouri K. Efficacy of fractional lasers in treating alopecia: a literature review. *Lasers Med*

- Sci. 2017 Nov;32(8):1919-1925. [PubMed]
15. <https://www.ncbi.nlm.nih.gov/28300084/>
 16. <https://niams.nih.gov/health-topics/alopecia-areata>
 17. <https://www.msdmanuals.com/en-in/professional/dermatologic-disorders/hair-disorders/alopecia>
 18. <https://www.sciencedirect.com/science/article/pii/S2210836X13000237#bb0005>