



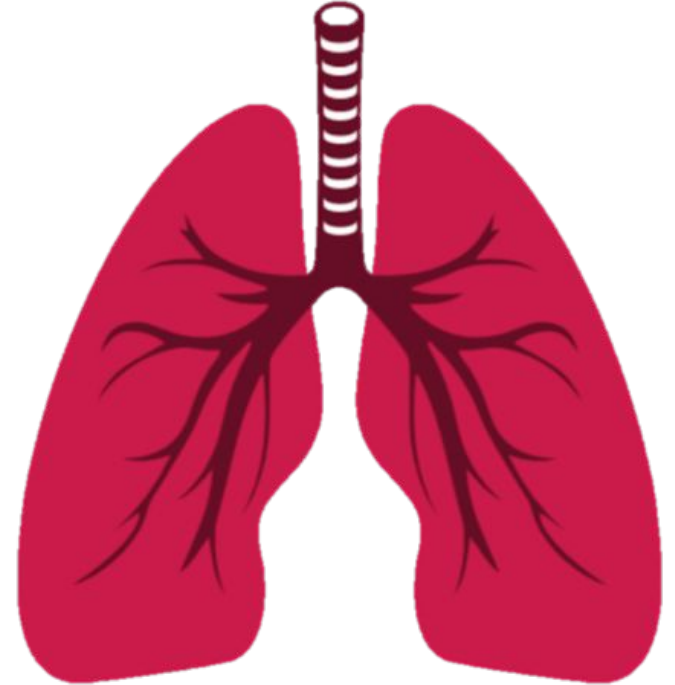
Anatomy team
med 438



Larynx, Trachea & Bronchi

Respiratory block-Anatomy-Lecture 3

Editing file



Objectives

- **By the end of the lecture, you should be able to:**
- Describe the Extent, structure and functions of the larynx.
- Describe the Extent, structure and functions of the trachea.
- Describe the bronchi and branching of the bronchial tree.
- Describe the functions of bronchi and their divisions.

Color guide :

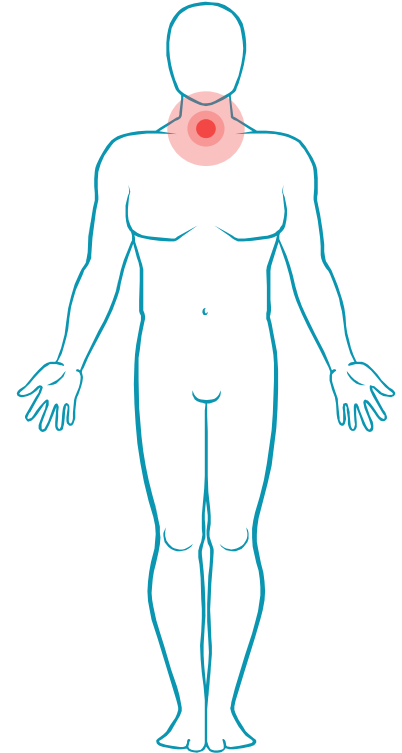
Only in boys slides in **Blue**

Only in girls slides in **Purple**

important in **Red**

Doctor note in **Green**

Extra information in **Grey**

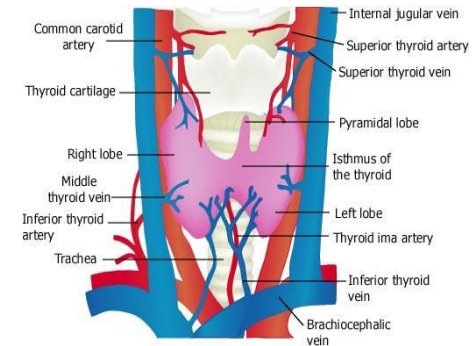
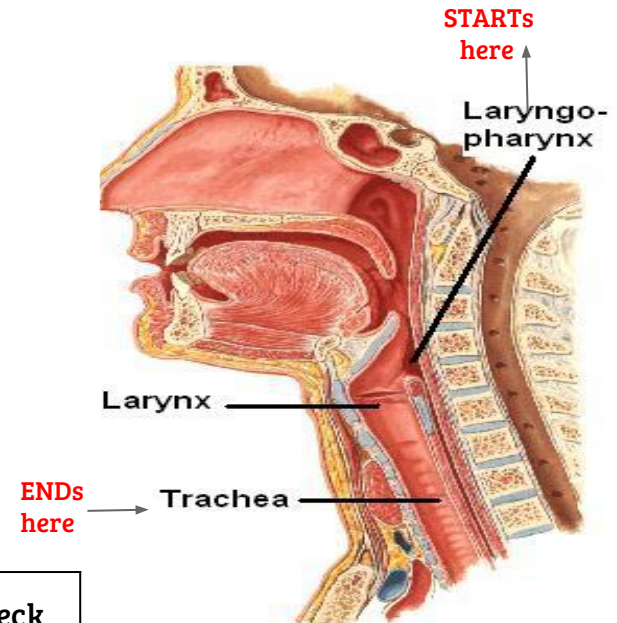


Larynx

- ❖ The larynx is the part of the respiratory tract which contains the **vocal cords**.
- ❖ In adult it is about **2 -inches-** long tube.
- ❖ The larynx has function in:
 - **Respiration** (breathing).
 - **Phonation** (voice production).
 - **Deglutition** (swallowing).

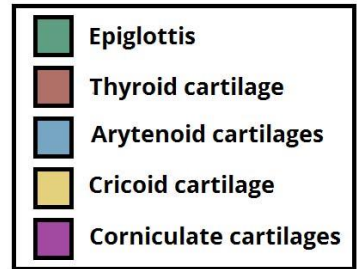
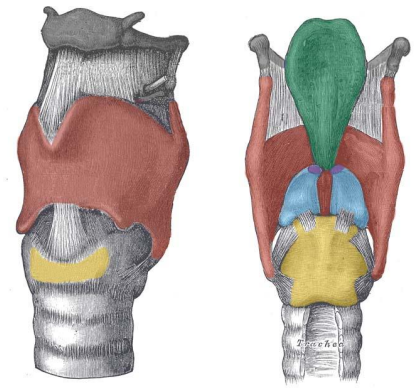
Relations of the Larynx : its related to major critical structures in the neck

★ Arteries	Veins	Nerves
<p>3 Carotid arteries: (common, external and internal).</p> <p>3 Thyroid arteries: (superior & inferior thyroid arteries and thyroidema artery).</p>	<p>2 Jugular veins, (external & internal).</p>	<p>-Laryngeal nerves: (Superior laryngeal & recurrent laryngeal).</p> <p>-Vagus nerves.</p>



Larynx components

- ❖ The larynx consists of four basic components:
 - Cartilaginous skeleton
 - Membranes and Ligaments
 - Mucosal Lining
 - Muscles (intrinsic & Extrinsic)



1- Cartilaginous Skeleton

The Cartilaginous Skeleton is made up of 9 cartilages:

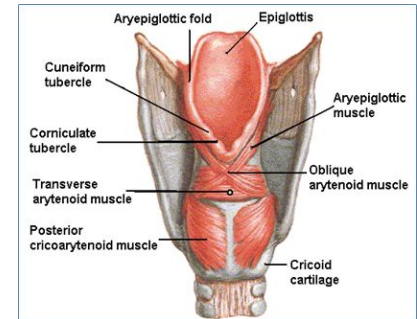
3 single cartilages:

1. **Epiglottis**
2. **Thyroid**
3. **Cricoid**

3 pairs of cartilages:

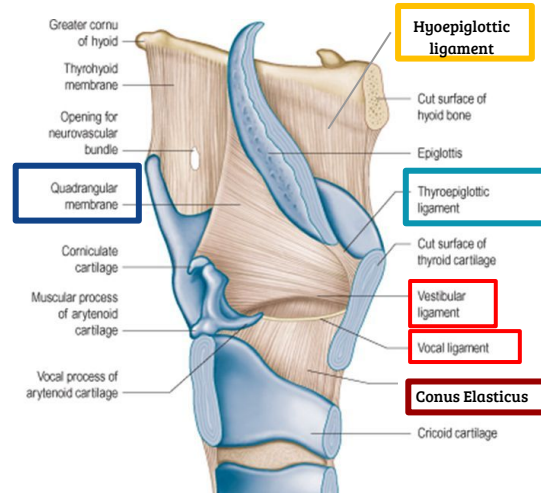
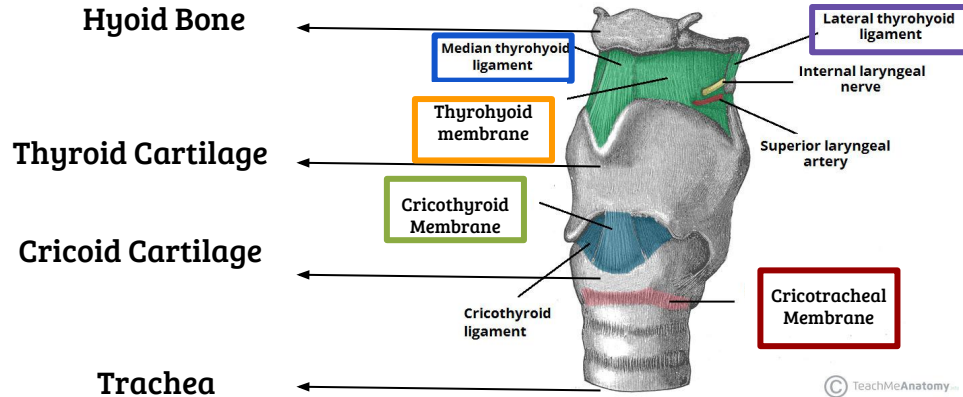
1. **Arytenoid**
2. **Coniculate**
3. **Cuneiform**

- All the cartilages are hyaline **EXCEPT** the **Epiglottis**, it's **elastic**.
- The cartilages are: Connected by joints, & ligaments. Lined by membranes. Moved by muscles.



Larynx components

2- Membranes and Ligaments



- In between the hyoid bone and the Thyroid Cartilage = **Thyrohyoid membrane**
 - it has **2 thickenings**: **median thyrohyoid ligament** and 2 x **lateral thyrohyoid ligaments**
- **In between the Thyroid Cartilage and the Cricoid Cartilage = Cricothyroid Membrane (Conus Elasticus)**
 - It's upper margin form the **vocal ligament** which forms the vocal fold or **true vocal fold**.
 - Its lower margin is attached to the upper border of cricoid cartilage.
- In between the the Cricoid Cartilage and Trachea = **Cricotracheal Membrane**
- In between the epiglottis and the hyoid bone = **Hyoepiglottic ligament**
- In between the epiglottis and the thyroid = **Thyroepiglottic ligament**
- In between epiglottis and arytenoid.= **Quadrangular (aryepiglottic) Membrane**
 - It's lower margin form the **vestibular ligament** which forms the vestibular fold or **false vocal fold**.

Laryngeal inlet and Cavity

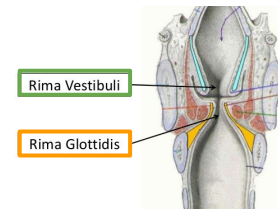
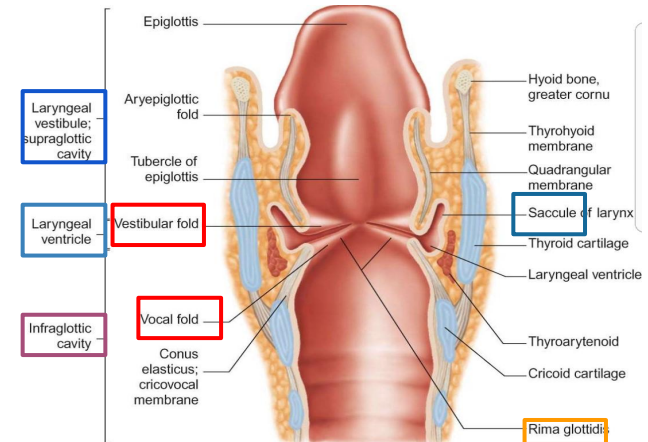
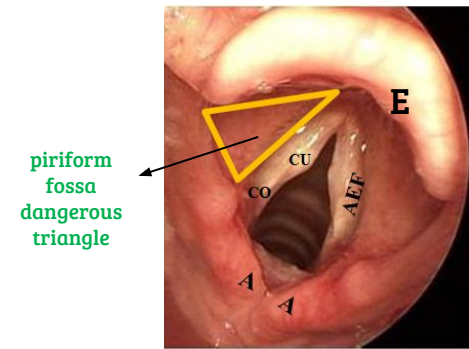
- The upper opening of the larynx into the **laryngopharynx**.
- It is directed upward and backward
- It opens into the laryngeal part of the pharynx, (laryngopharynx).
- Bounded:

Anteriorly: upper border of the epiglottis (E)

Posteriorly: Arytenoid (A)

Laterally: Aryepiglottic folds (AEF)

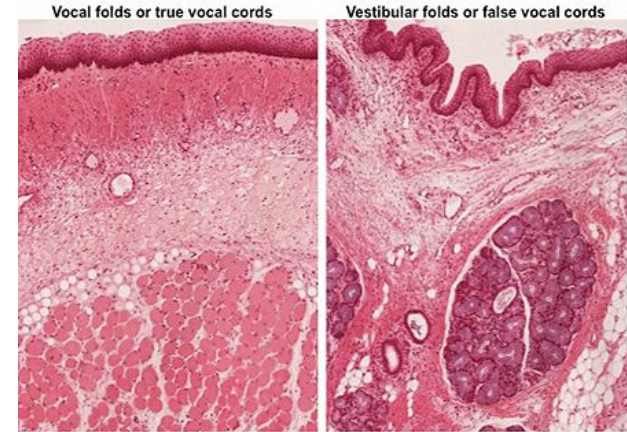
- The laryngeal cavity extends from the laryngeal inlet to the lower border of the cricoid cartilage.
 - **Rima vestibuli** is a narrow region between the vestibular folds
 - **Rima glottidis** is a more narrow region between the vocal folds.
- It's divided into **three parts**:
 - **supraglottic** (vestibule) :the part above the vestibular folds.
 - **ventricle** : the part between vestibular & vocal folds
 - **infraglottic** : the part below the vocal folds.
- The ventricle has an upward invagination called **saccule** which is rich in goblet cells



Larynx components

3- Mucosal Lining

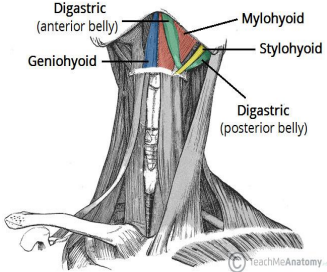
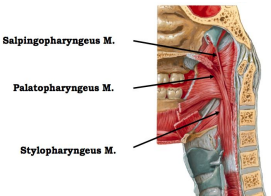
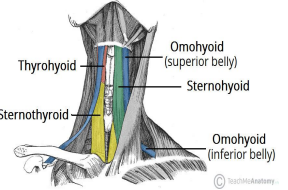
- The laryngeal cavity is lined by:
ciliated columnar epithelium
EXCEPT the surface of the vocal cords it's lined by:
Non-keratinized stratified squamous epithelium
Because they're exposed to trauma during phonation.(voice production)
- The ventricle part has an upward vagination called **saccul** that contains **goblet cells (mucous glands)** to lubricate the vocal cords.



Larynx components

4- Muscles

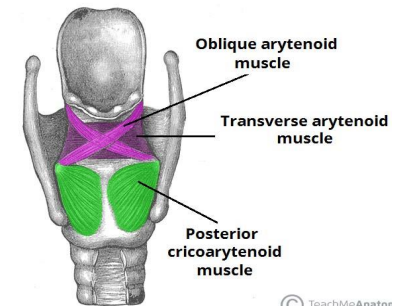
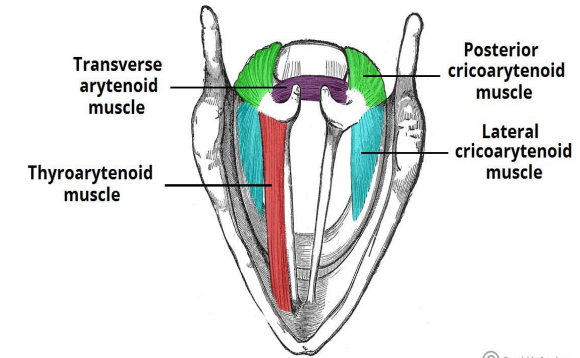
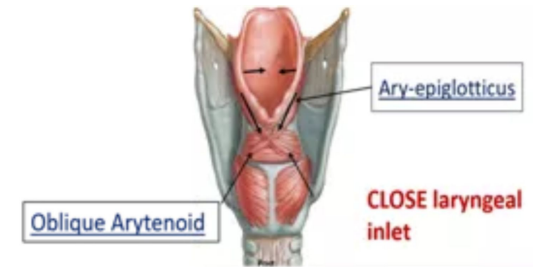
A-Extrinsic muscles : subdivided into two groups :

Elevators of the Larynx	Suprahyoid (MSGD)	Mylohyoid		
		Stylohyoid		
		Geniohyoid		
		Digastric		
	Longitudinal muscles of the pharynx (SSP)	Stylopharyngeus		
		Salpingopharyngeus		
Palatopharyngeus				
Depressors of the Larynx	Infrahyoid	Sternohyoid		
		Sternothyroid		
		Omohyoid		

Larynx components

4- Muscles

B-Intrinsic muscles: subdivided into two groups :		
Muscles controlling the laryngeal inlet	Oblique Arytenoid muscle	
	Aryepiglottic muscle	
Muscles controlling Movement of the vocal cord	Decrease Vocal cord length and tension	Thyroarytenoid muscle (Vocalis)
	Increase vocal cord length and tension	Cricothyroid muscle (Only one can found outside the larynx)
	Adductors	Lateral Cricoarytenoid
		Transverse Arytenoid
Abductors	Posterior Cricoarytenoid	



Nerve Supply and Semon's Law:

Motor:

- All intrinsic muscles are supplied by **recurrent laryngeal nerve** of vagus nerve
- **EXCEPT cricothyroid, it's supplied by external laryngeal nerve** of superior laryngeal of vagus.

Sensory:

- Above the vocal cord = **Internal laryngeal nerve** of branch superior laryngeal of vagus nerve
- Under the vocal cord = **Recurrent laryngeal nerve**. Of vagus nerve

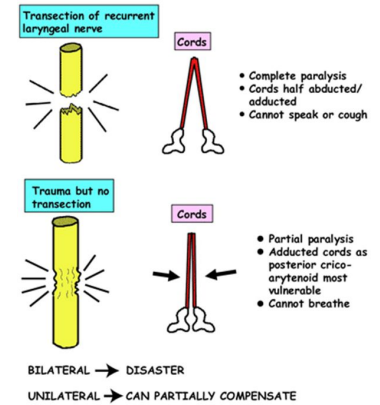
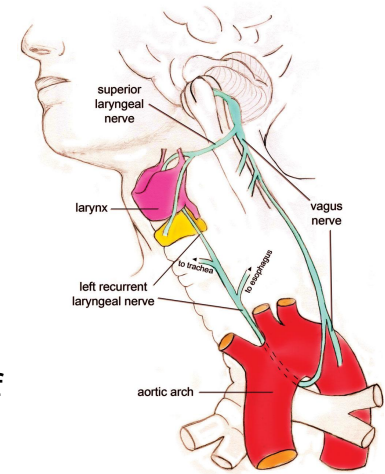
Semon's Law: (damage of **recurrent laryngeal nerve**.)

- due to surgery in region of the neck (e.g. thyroidectomy or parathyroidectomy)
- **Transected (قطع):** complete paralysis, cannot speak, cannot cough **BUT can breath.**
- **Trauma without transected:** partial paralysis, adducted vocal cords, **AND cannot breath.**

In non-transected nerve damage:

- Bilateral (both sides) = VERY dangerous
- Unilateral = can partially compensate

Note :The nerve fibers supplying the abductors lie in the periphery of the recurrent laryngeal nerve and any lesion involves these fibers first before involving the deeper fibers that supply the adductors.

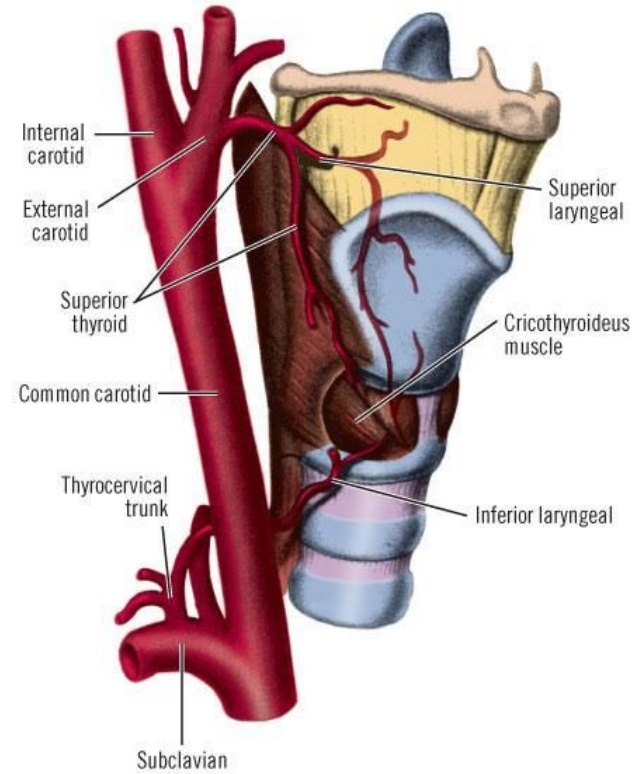


Blood Supply

- **Arteries:**
 1. **Upper half:** Superior laryngeal artery, branch of superior thyroid artery.
 2. **Lower half:** Inferior laryngeal artery, branch of inferior thyroid artery.
- **Veins:**

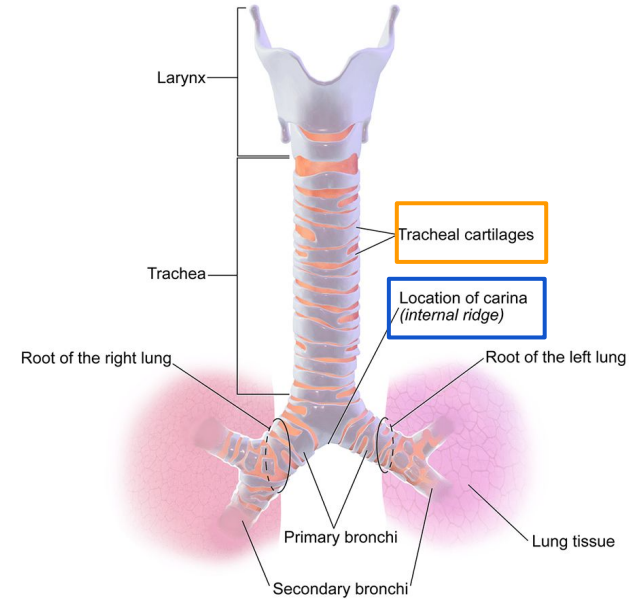
Accompany the corresponding arteries.
- **Lymphatics:**

The lymph vessels drain into the deep cervical lymph nodes.

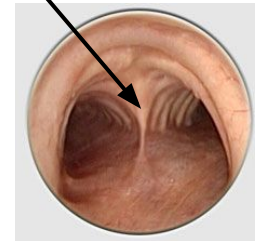


Trachea (windpipe)

- Mobile, fibrocartilage tube
- In adult it is about **5 inches** long tube with 1 inch in diameter
- **Begins:**
 - **Below the cricoid cartilage (at C6)**
- **Ends:**
 - **Thorax (behind sternal angle) lower border of T4**
- **Divides into:**
 - right and left primary(main) bronchi
- its wall supported by **16-20 horseshoe cartilage** anteriorly.
- The ridge at the bifurcation from inside is called **carina**
 - It is the most sensitive part of the respiratory tract
 - It's associated with the **cough reflex**



carina

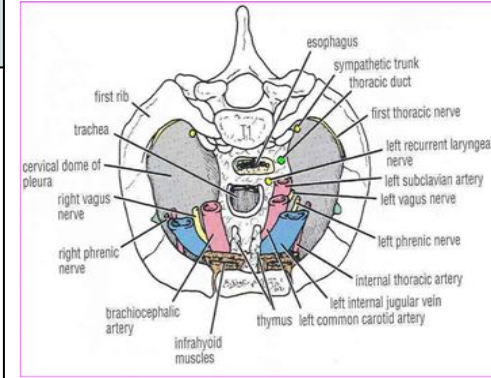


Trachea (windpipe)

13

Relations in the trachea :

Anterior	Posterior	Right	Left
<ul style="list-style-type: none"> -Sternum -Thymus -Left brachiocephalic vein -Arch of the aorta, origin of: brachiocephalic artery left common carotid artery 	<ul style="list-style-type: none"> -Esophagus -Left recurrent laryngeal n. 	<ul style="list-style-type: none"> -Azygos vein -Right vagus nerve -Right pleura 	<ul style="list-style-type: none"> -Left vagus nerve -Left phrenic nerve -Left pleura -Arch of the aorta -left common carotid artery -left subclavian artery



Nerve & Blood Supply :

Artery Supply	Venous supply	Nerve Supply	Lymphatic Supply
Inferior thyroid and bronchial arteries.	Drain into inferior thyroid vein.	-Branches of the vagus nerve and recurrent laryngeal nerve give sensory fibers to supply the mucous membrane Trachealis (muscle behind the trachea) is supplied by the sympathetic trunk	Drain into pre and para tracheal lymph nodes

Bronchi

Right Bronchus:

- **One inch long.**, wide, short, more vertical bronchus
- Gives superior lobar before entering the hilum and gives the inferior and middle lobar after.

Left Bronchus

- **Two inches long.**, narrow, long, more horizontal bronchus
- Gives superior and inferior lobar after entering the hilum. (**no middle lobar**)
- Passes below the aortic arch and in front of the esophagus.

Divisions :

- Within the lung each bronchus divides and redivides into number of branches

Conduction zone

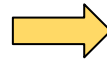Primary bronchus



Secondary bronchus (Lobar)



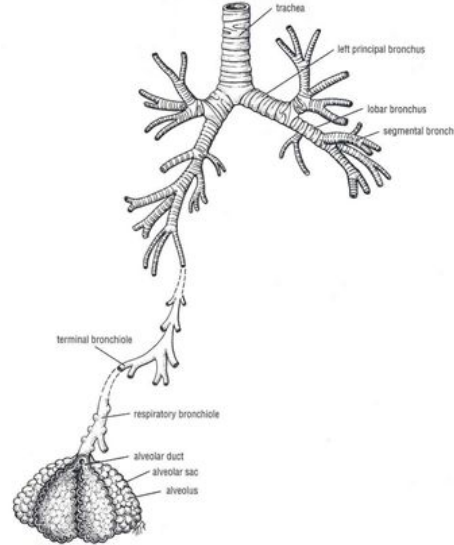
Tertiary bronchus (segmental)
Supplied by bronchopulmonary segment.



Bronchiole



Terminal bronchiole



Respiratory zone

alveolar sac

Alveoli

alveolar sac



Alveolar duct



Respiratory bronchiole



MCQs

Question 1: Right Bronchus after entering the lung it ?

- A. dose not divide
- B. divides into middle and inferior lobar bronchi
- C. divides into superior and inferior lobar bronchi
- D. divides to 3 different branches

Question 2: unilateral non-transected nerve damage?

- A. very dangerous
- B. happen in left side of the nerve only
- C. can partially compensate
- D. same as bilateral

Question 3: surface of the vocal cords lined by?

- A. Non-keratinized stratified squamous epithelium
- B. keratinized stratified squamous epithelium
- C. squamous epithelium
- D. ciliated columnar epithelium

Question 4: which one of the following is one of The larynx function?

- A. Respiration
- B. Phonation
- C. All of them
- D. Deglutition

Question 5: a membrane located In between epiglottis and arytenoid ?

- A. Cricothyroid Membrane
- B. Quadrangular Membrane
- C. Thyrohyoid membrane
- D. Cricotracheal Membrane

Question 6: which is True about Thyroarytenoid MUSCLE ?

- A. Decrease Vocal cord length and tension
- B. Increase vocal cord length and tension
- C. one of Depressors of the Larynx
- D. an Adductors muscle

Question 7: Nerve supply of Trachealis muscle?

- A. vagus nerve
- B. recurrent laryngeal nerves.
- C. sympathetic trunk
- D. external laryngeal nerve

Question 8: The lymph vessels of the larynx drain into the ?

- A. deep cervical lymph nodes.
- B. superful cervical lymph nodes
- C. deep axillary lymph nodes
- D. anterior cervical lymph nodes

Best wishes



**Don't forget to leave
your feedback:**



Team members

Boys team:

- Khalid AL-Dossari
- Naif Al-Dossari
- Faisal Alqifari
- Salman Alagla
- Ziyad Al-jofan
- Suhail Basuhail
- Ali Aldawood
- Khalid Nagshabandi
- ★ Mohammed Al-huqbani
- Jihad Alorainy
- Khalid AlKhani
- Omar Alammari

Team leaders

- ★ Abdulrahman Shadid
- Ateen Almutairi

Girls team :

- Ajeed Al Rashoud
- Taif Alotaibi
- Noura Al Turki
- Amirah Al-Zahrani
- Alhanouf Al-haluli
- Sara Al-Abdulkarem
- Rawan Al Zayed
- Renad Al Haqbani
- Nouf Al Humaidhi
- Jude Al Khalifah
- Nouf Al Hussaini
- Alwateen Al Balawi
- Rahaf Al Shabri
- Danah Al Halees
- Rema Al Mutawa
- Amirah Al Dakhilallah
- Maha Al Nahdi
- Ghaida Al Braithen