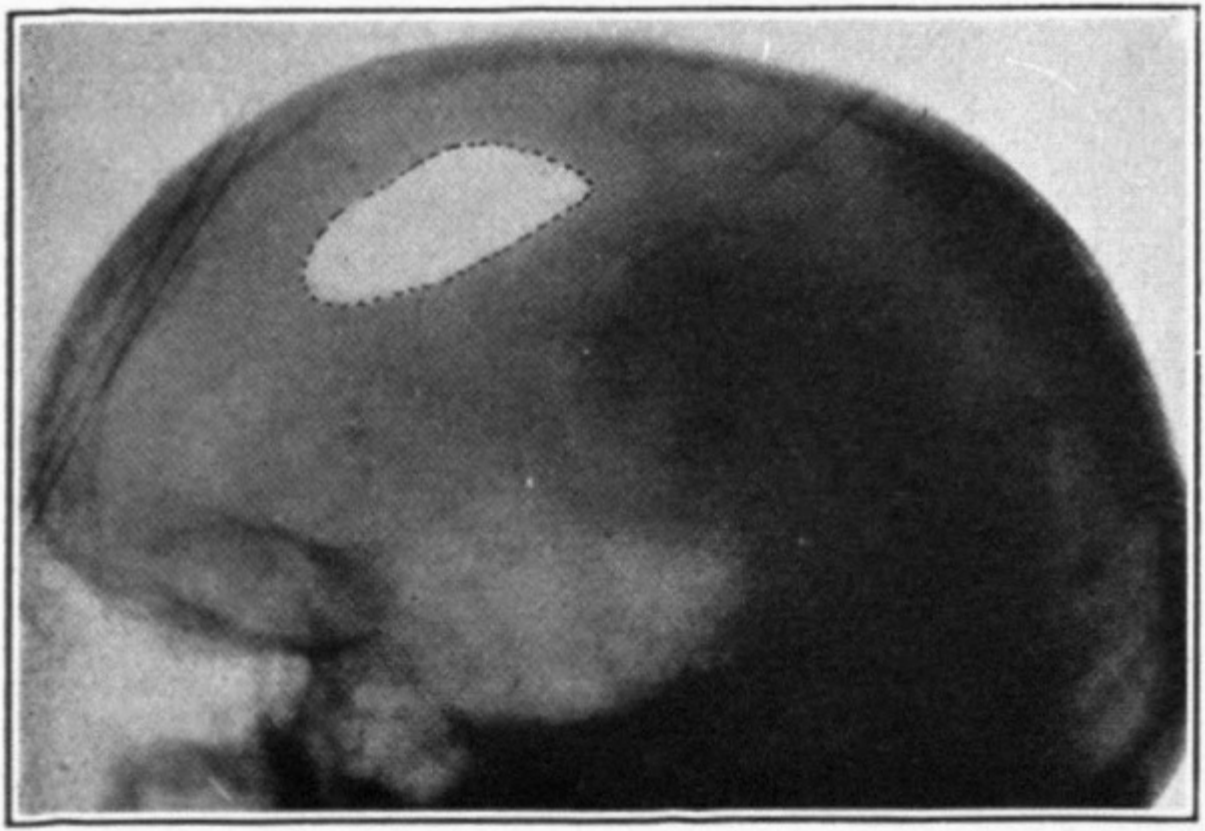

FIG. 35.—Skiagraph of a characteristic oval defect in the frontal region