

Successful Treatment of Fungemia Caused by *Cyberlindnera fabianii* with Anidulafungin: A Case Report

Jeong In Lee¹, Shinae Yu², Jong Sin Park¹, Eun-Jeong Joo¹, Jong Hee Shin³, Min-Jung Kwon²

Departments of ¹Internal Medicine and ²Laboratory Medicine, Kangbuk Samsung Hospital, Sungkyunkwan University School of Medicine, Seoul, ³Department of Laboratory Medicine, Chonnam National University Medical School, Gwangju, Korea

Cyberlindnera fabianii (previously known as *Hansenula fabianii*, *Pichia fabianii*, and *Lindnera fabianii*) is a yeast species that forms a biofilm, allowing it to resist azole drugs. In this study, we report a case of fungemia with *C. fabianii* that was successfully treated with anidulafungin. In this case, the organism was initially misidentified as *Candida utilis* (with a high probability of 93%, suggesting good identification) using the VITEK 2 yeast identification card (YST ID; bioMérieux, USA). The species responsible for the patient's fungemia was correctly identified after se-

quencing the internally transcribed spacer region and the D1/D2 domain of the large subunit (26S) *rDNA* gene. The CLSI M27-A3 broth microdilution method was used to determine the *in vitro* antifungal activity of anidulafungin and fluconazole against *C. fabianii*. The MICs of anidulafungin and fluconazole were found to be 0.03 μ g/mL and 2 μ g/mL, respectively. The patient recovered after 14 days of anidulafungin treatment. (**Ann Clin Microbiol 2015;18:94-97**)

Key Words: Anidulafungin, *Cyberlindnera fabianii*

INTRODUCTION

Cyberlindnera fabianii (previously known as *Hansenula fabianii*, *Pichia fabianii*, and *Lindnera fabianii*) is an ascomycetous yeast that is rarely involved in human infections [1]. However, *C. fabianii* has been described to cause pneumonia, endocarditis, prostatitis, and catheter-related infections and is usually treated with antifungal agents such as ketoconazole, fluconazole, voriconazole, or caspofungin [2-5]. Azole resistance has been detected in some cases of *C. fabianii* infection [4,5]. Such antifungal resistance may be facilitated by the ability of this species to form biofilms [4]. In addition, commercial biochemical fungal identification kits often misidentify *C. fabianii* as *Candida utilis* [3,5]. Here, we report a case of fungemia caused by *C. fabianii*. The diagnosis was confirmed using molecular assays, and the infection was successfully treated with anidulafungin.

CASE REPORT

An 87-year-old man with untreated lung cancer presented with dyspnea. He had been diagnosed with lung cancer a year prior to his presentation, but did not undergo any surgery or chemoradiotherapy. An initial chest X-ray in the emergency room revealed obstructive pneumonitis that was most likely related to his cancer. He was treated with antibiotics for pneumonia. On the 14th day after admission, the patient was found to be drowsy with altered mentation. He was diagnosed with a subacute cerebral infarction and was transferred to the intensive care unit. The patient's condition deteriorated as his pneumonia worsened. He was intubated and placed on a ventilator. The patient was started on broad-spectrum antibiotics including meropenem (1,000 mg per 8 hours via intravenous line) and colistin (60 mg per 8 hours via intravenous line) for ventilator-associated pneumonia caused by multidrug resistant *Actinobacter baumannii*. Hemodialysis was initiated on the 30th hospital day via an internal jugular catheter. A peripheral

Received 10 April, 2015, Revised 15 June, 2015, Accepted 25 June, 2015

Correspondence: Min-Jung Kwon, Department of Laboratory Medicine, Kangbuk Samsung Hospital, Sungkyunkwan University School of Medicine, 29 Saemunan-ro, Jongno-gu, Seoul 03181, Korea. (Tel) 82-2-2001-5211, (Fax) 82-2-757-0711, (E-mail) mjkkmd@gmail.com

© The Korean Society of Clinical Microbiology.

© This is an Open Access article distributed under the terms of the Creative Commons Attribution Non-Commercial License (<http://creativecommons.org/licenses/by-nc/4.0>) which permits unrestricted non-commercial use, distribution, and reproduction in any medium, provided the original work is properly cited.

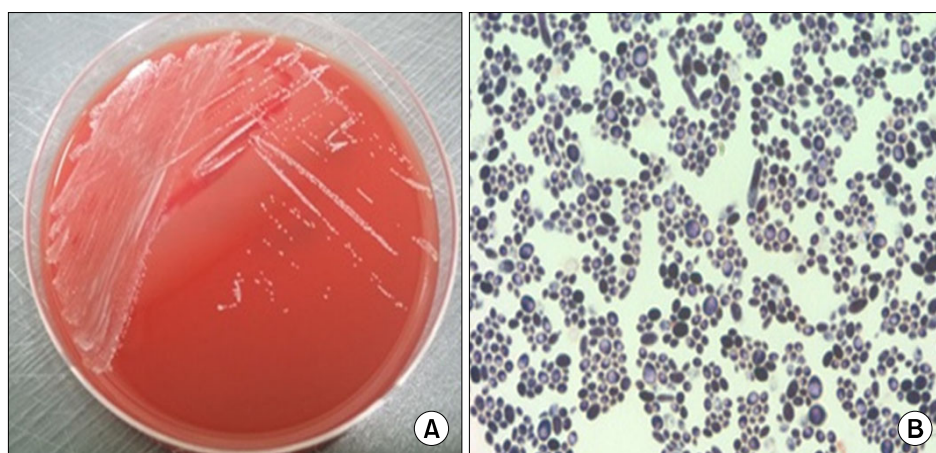


Fig. 1. Colony morphology on sub-inoculation and microscopic morphology. (A) Small white colonies identified after incubation on a blood agar plate at 35°C in the presence of 5% CO₂. (B) Microscopic analysis revealed variably sized Gram-positive yeast-like structures in the colonies (Gram stain, ×1,000).

catheter was also inserted at the same time for intravenous fluid therapy.

The patient developed a fever on the 62nd hospital day. Laboratory investigation showed a leukocyte count of 15,700/mm³ with 75.4% segmented neutrophils. Other laboratory tests revealed a serum C-reactive protein level of 9.65 mg/dL (reference range; 0-0.6 mg/dL), and serum lactate dehydrogenase level of 287 IU/L (reference range; 0-250 IU/L), both of which were elevated. There was no evidence of urinary tract infection or pneumonia in routine urinary analysis and chest X-ray work-up. Blood cultures were drawn from the internal jugular catheter, a peripherally inserted central catheter, and another peripheral site and vancomycin was added to the antibiotic regimen.

After 24-hr incubation in BACTEC FX (Becton, Dickinson and Company, Sparks, MD, USA), there was growth in one of the aerobic bottles from the internal jugular catheter. Small white colonies were subsequently isolated after 36 hrs of incubation on a blood agar plate at 35°C in the presence of 5% CO₂. Microscopic examination of the colonies revealed gram-positive, yeast-like structures (Fig. 1). The organism was identified as *C. utilis* with a probability of 93% using the VITEK 2 yeast identification card (YST ID; bioMérieux, Durham, NC, USA). The internal jugular catheter and peripherally inserted central catheter were immediately removed and tip cultures were performed for both catheters. All of the tip cultures showed no growth. The patient was started on anidulafungin treatment (200 mg loading dose via intravenous line, then 100 mg per 24 hours).

In addition, molecular identification was performed by sequencing the internally transcribed spacer (ITS) region and the D1/D2 domain of the large subunit (26S) *rDNA* gene [6]. The following primer pairs of ITS1/ITS4, ITS5/ITS4, and D1/D2 primers were used: forward ITS1: 5'-TCCGTAGGTGAACCTG

Table 1. Antifungal susceptibilities of *C. fabianii*

Antifungal agent	MIC (μg/mL)	
	Broth microdilution* (24 h)	VITEK 2
Amphotericin B	0.5	0.5
Fluorocytosine	Not done	≤1
Voriconazole	0.03	≤0.12
Fluconazole	2	≤1
Caspofungin	0.5	≤0.25
Micafungin	0.125	0.12
Anidulafungin	0.03	Not done

*Performed by the CLSI M27-A3 broth microdilution method.

CGG-3', reverse ITS4: 5'-TCCTCCGCTTATTGATATGC-3', forward ITS5: 5'-GGAAGTAAAAGTCGTAACAAGG-3', reverse ITS4: 5'-TCCTCCGCTTATTGATATGC-3', forward D1: 5'-GCATATCAATAAGCGGAGGAAAAG-3' and reverse D2: 5'-GGTCCGTGTTTCAAGACGG-3'. The GenBank (NCBI) (<http://blast.ncbi.nlm.nih.gov/>) database and the basic local alignment search tool (BLAST) algorithm were used for sequence comparison. The BLAST search revealed that the partial ITS sequence was 99.8% (532/533) similar to that of *Cyberlindnera fabianii* (accession no. LK392379.1#34-565) and *Pichia mississippiensis* (*Cyberlindnera mississippiensis*, accession no. GQ 340433.1 #41-572). The D1/D2 domain sequence was identical (100% [569/569] similarity) to that of *Pichia fabianii* (*Cyberlindnera fabianii*, accession no. AF335971.1 #4-572) and 98.8% (562/569) similar to that of *Pichia mississippiensis* (*Cyberlindnera mississippiensis*, accession no. DQ409159.1 #4-572). On the basis of these results, we concluded that *C. fabianii* was actually the responsible species. We also performed *in vitro* antifungal susceptibility tests using the VITEK 2 yeast antimicrobial susceptibility testing card (AST-YS07; bioMérieux). Moreover,

based on the CLSI M27-A3 broth microdilution method, the MIC values of anidulafungin and fluconazole were 0.03 $\mu\text{g/mL}$ and 2 $\mu\text{g/mL}$, respectively (Table 1).

The patient was treated with anidulafungin for 14 days, after which subsequent blood cultures revealed no growth. His vital signs became stable and he remained afebrile. Leukocytosis improved to 8,500/mm³ from 15,700/mm³. However, on the 80th hospital day, mucus accumulated in the airway tree, possibly caused by the increased volume of sputum produced, and chest X-ray revealed increased haziness in both lower lobes. We performed a sputum culture study and multidrug resistant *A. baumannii* was identified on the 82nd hospital day. We concluded that the hospital/ventilator-associated pneumonia had relapsed. The patient had persistent hypotension despite the use of inotropes. At this time, continuous renal replacement therapy was initiated. Despite all efforts, the patient died on the 90th hospital day secondary to septic shock and multiorgan failure.

DISCUSSION

C. fabianii is a member of a clade of 27 species of ascomycetous yeast [1] that has been used commercially to treat waste water that drains from food processing plants [7]. The CBS5640/NRRL Y-1871 strain was originally cultured by Wickerham in 1942. Since then, it has been isolated from alcoholic beverage fermentation, sugarcane, and human infections [8,9]. Previously, *C. fabianii* has been described to cause pneumonia, endocarditis, prostatitis, and catheter-related infections and has been treated with ketoconazole, fluconazole, voriconazole, and caspofungin [2-5]. There were no prior cases of *C. fabianii* treated with anidulafungin. Here, we present the first case of fungemia with *C. fabianii* that was successfully treated with anidulafungin.

Previously reported cases of *C. fabianii* have shown azole resistance [4,5]. In 2006, Valenza et al. described a fatal case of *C. fabianii* in a 46-year-old man (initially with severe pneumococcal septicemia) who was treated with fluconazole followed by caspofungin. The species forms a biofilm, which may facilitate azole resistance [4]. In 2008, Hamal et al. reported a case of aortic valve endocarditis caused by *Pichia fabianii*. Antifungal therapy with fluconazole and voriconazole led to the development of resistant strains with high MIC values for both antifungal agents. This may have resulted from the development of cross-resistance to azoles and biofilm formation that can prevent the antimycotics from accessing the yeast cells [5]. According to the clinical practice guidelines for the management of candi-

diasis from the Infectious Diseases Society of America (IDSA, 2009 update), an echinocandin is preferred for patients with recent azole exposure, patients with moderately severe to severe illness, or patients who are at high risk of infection with *C. glabrata* or *C. krusei* [10]. Therefore, although our patient had no evidence of azole resistance or no prior exposure to azoles this might be another treatment option, especially when severe clinical illness with underlying lung cancer, subacute cerebral infarction, and ventilator-associated pneumonia are concerns.

In this case, *C. fabianii* was initially misidentified as *Candida utilis*. However, *C. utilis* fungemia is rare and there are reported cases of species misidentification using the VITEK-2 YST ID card [3,5]. In particular, unusual species such as *C. fabianii* are not included in the databases of commercial kits. Because another approach was needed for identification of the uncommon fungemia, we performed molecular identification to confirm the fungal species using standard methods according to the CLSI guideline MM18-A [11]. This analysis identified the true pathogen as *C. fabianii*. On the basis of these results, we concluded that *C. fabianii* was most likely responsible for the fungemia. This phenomenon highlights the importance of genomic speciation in infection diagnosis and treatment. Therefore, molecular identification should be considered for the speciation of unusual species, especially in patients who are immunocompromised or with neutropenia, those with a long-term inserted catheter, and those who are treated with broad-spectrum antibiotics or empirical azole-based antifungal agents.

Although this is the second reported case of fungemia caused by *C. fabianii* in Korea [3], to the best of our knowledge, this is the first case of fungemia with *C. fabianii* that was treated with anidulafungin. Our case contributes to knowledge regarding optimal treatment options against *C. fabianii*. Our report also emphasizes the critical role that molecular identification plays in the speciation of uncommon fungi such as *C. fabianii*.

REFERENCES

1. Kurtzman CP, Robnett CJ, Basehoar-Powers E. Phylogenetic relationships among species of *Pichia*, *Issatchenkia* and *Williopsis* determined from multigene sequence analysis, and the proposal of *Barnettozyma* gen. nov., *Lindnera* gen. nov. and *Wickerhamomyces* gen. nov. FEMS Yeast Res 2008;8:939-54.
2. Dooley DP, Beckius ML, McAllister CK, Jeffery BS. Prostatitis caused by *Hansenula fabianii*. J Infect Dis 1990;161:1040-1.
3. Yun JW, Park KS, Ki CS, Lee NY. Catheter-related bloodstream infection by *Lindnera fabianii* in a neutropenic patient. J Med Microbiol 2013;62:922-5.

4. Valenza G, Valenza R, Brederlau J, Frosch M, Kurzai O. Identification of *Candida fabianii* as a cause of lethal septicaemia. *Mycoses* 2006;49:331-4.
5. Hamal P, Ostransky J, Dendis M, Horváth R, Ruzicka F, Buchta V, et al. A case of endocarditis caused by the yeast *Pichia fabianii* with biofilm production and developed in vitro resistance to azoles in the course of antifungal treatment. *Med Mycol* 2008;46:601-5.
6. Kurtzman CP and Robnett CJ. Identification of clinically important ascomycetous yeasts based on nucleotide divergence in the 5' end of the large-subunit (26S) ribosomal DNA gene. *J Clin Microbiol* 1997;35:1216-23.
7. Moriya K, Iefuji H, Shimoi H, Sato S-I, Tadenuma M. Treatment of distillery wastewater discharged from beet molasses-spirits production using yeast. *J Ferment Bioeng* 1990;69:138-40.
8. Nyanga LK, Nout MJ, Smid EJ, Boekhout T, Zwietering MH. Fermentation characteristics of yeasts isolated from traditionally fermented *masau* (*Ziziphus mauritiana*) fruits. *Int J Food Microbiol* 2013;166:426-32.
9. Mukisa IM, Porcellato D, Byaruhanga YB, Muyanja CM, Rudi K, Langsrud T, et al. The dominant microbial community associated with fermentation of *Obushera* (sorghum and millet beverages) determined by culture-dependent and culture-independent methods. *Int J Food Microbiol* 2012;160:1-10.
10. Pappas PG, Kauffman CA, Andes D, Benjamin DK Jr, Calandra TF, Edwards JE Jr, et al; Infectious Diseases Society of America. Clinical practice guidelines for the management of candidiasis: 2009 update by the Infectious Diseases Society of America. *Clin Infect Dis* 2009;48:503-35.
11. CLSI. Interpretive criteria for identification of bacteria and fungi by DNA target sequencing: approved guideline. CLSI document MM18-A. Wayne, PA: Clinical and Laboratory Standards Institute; 2008.

=국문초록=

Anidulafungin 치료 효과가 있었던 *Cyberlindnera fabianii* 감염 1예

성균관대학교 의과대학 강북삼성병원 ¹감염내과, ²진단검사의학교실, ³전남대학교 의과대학 진단검사의학교실
이정인¹, 유신애², 박종신¹, 주은정¹, 신종희³, 권민정²

Cyberlindnera fabianii (이전에 명명된 *Hansenula fabianii*, *Pichia fabianii*, *Lindnera fabianii*)는 바이오 필름을 형성하여 아졸계 항진균제에 내성을 띄는 곰팡이로, 본 증례는 anidulafungin 치료 효과가 있었던 *C. fabianii* 감염 1예이다. 초기에 VITEK 2 YST ID 카드를 사용하여 *Candida utilis*로 오인되었으나, ITS (internally transcribed spacer) 부위와 26S rDNA D1/D2 domain에 대한 염기서열분석방법을 시행하여 *C. fabianii*임을 규명하였다. 생체 외에서 *C. fabianii*에 대한 fluconazole과 anidulafungin에 대한 항진균 효과를 CLSI M27-A3 broth microdilution method을 통해 확인하였고, MIC는 각각 0.03 $\mu\text{g}/\text{mL}$ 와 2 $\mu\text{g}/\text{mL}$ 로 확인되었다. 본 증례의 환자는 14일간 anidulafungin 치료를 받은 후 진균혈증에서 회복되었다. [*Ann Clin Microbiol* 2015;18:94-97]

교신저자 : 권민정, 03181, 서울시 종로구 새문안로 29
성균관대학교 의과대학 강북삼성병원 진단검사의학교실
Tel: 02-2001-5211, Fax: 02-757-0711
E-mail: mjkkmd@gmail.com