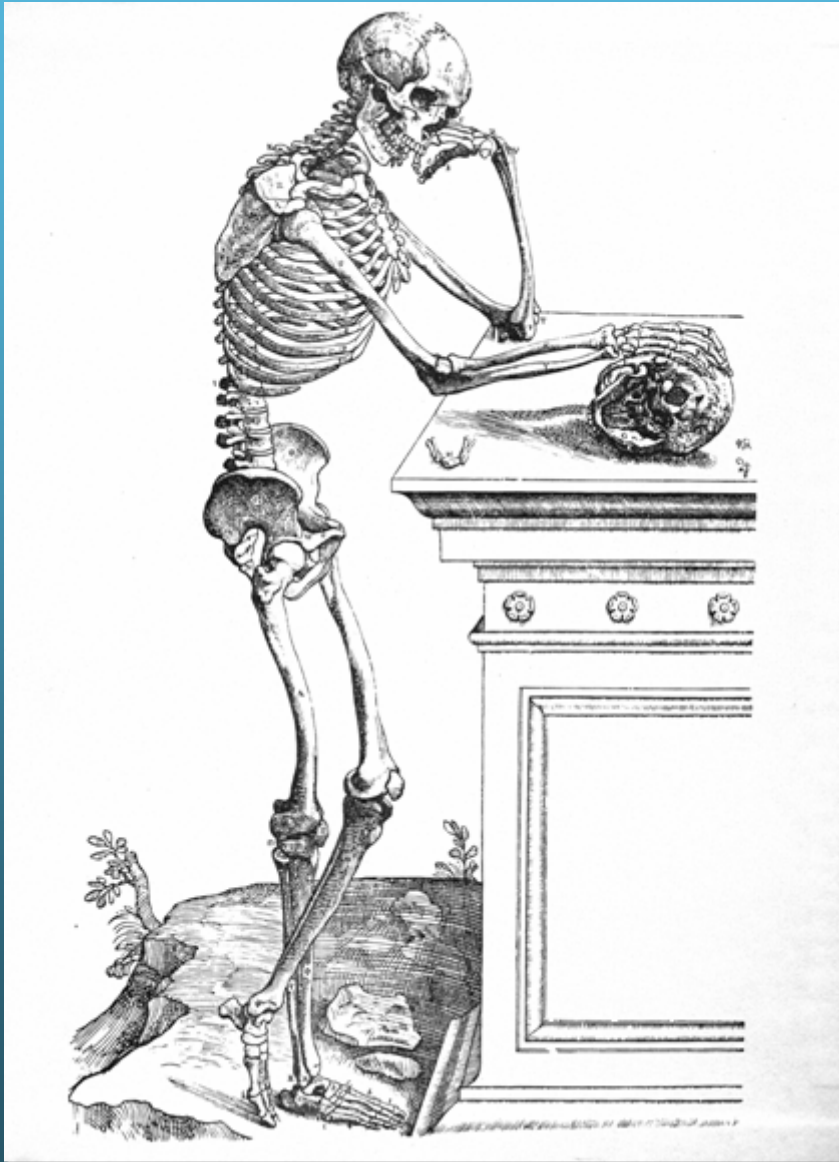

Organization of the Lower Limb

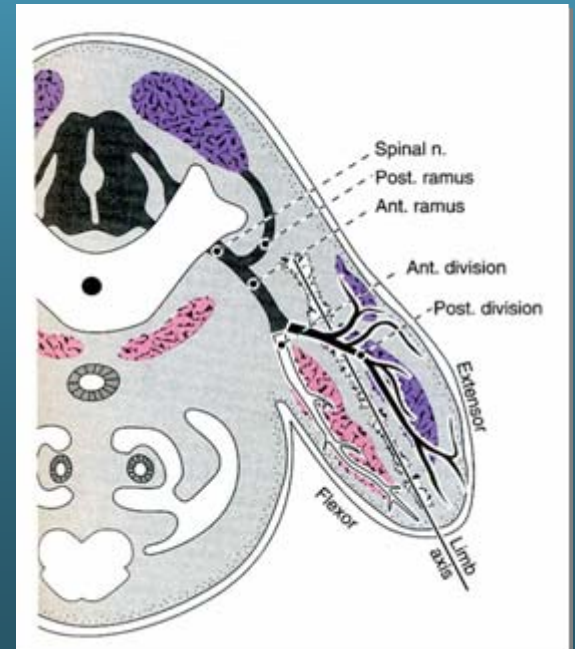
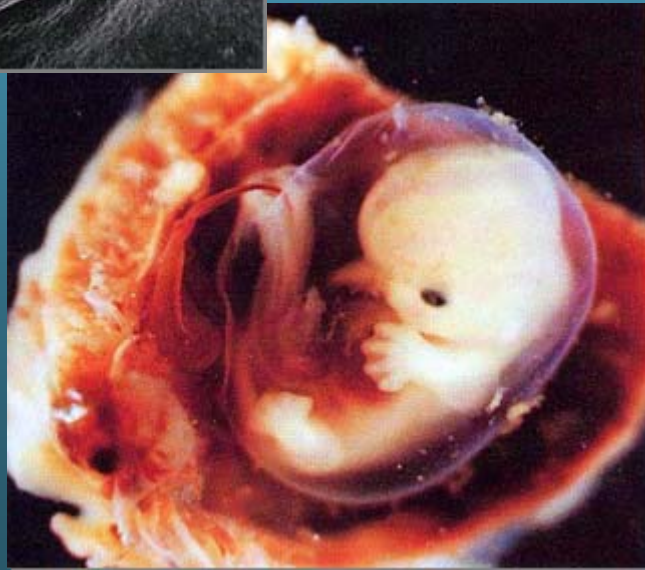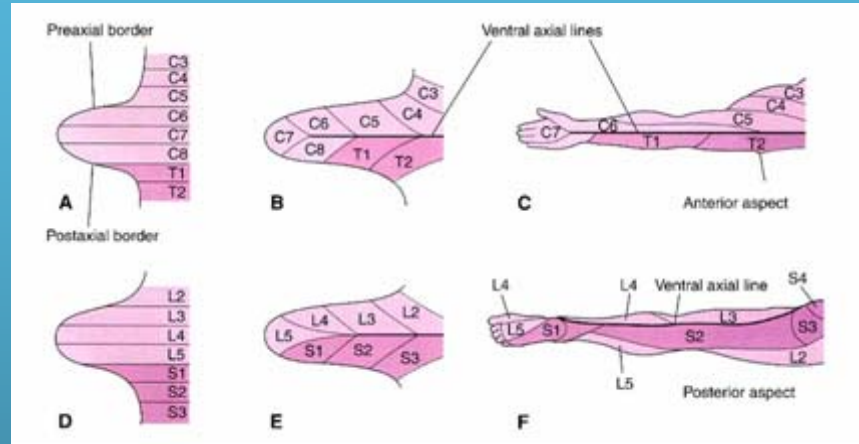

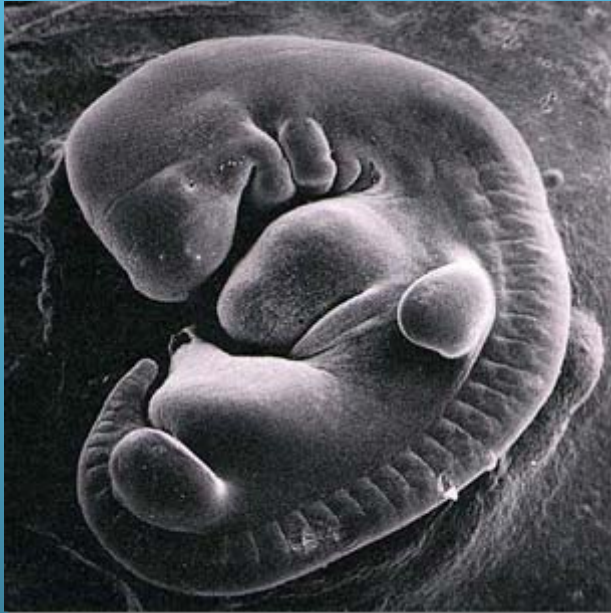
Most illustrations from:

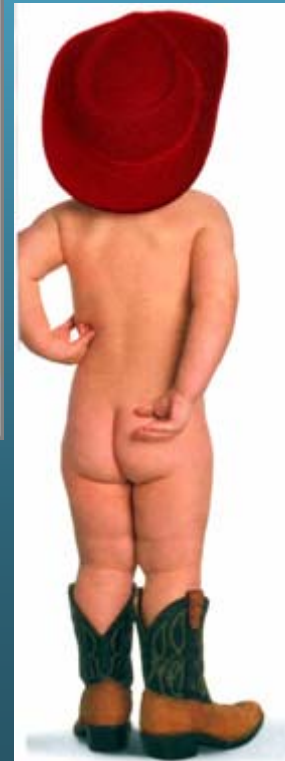
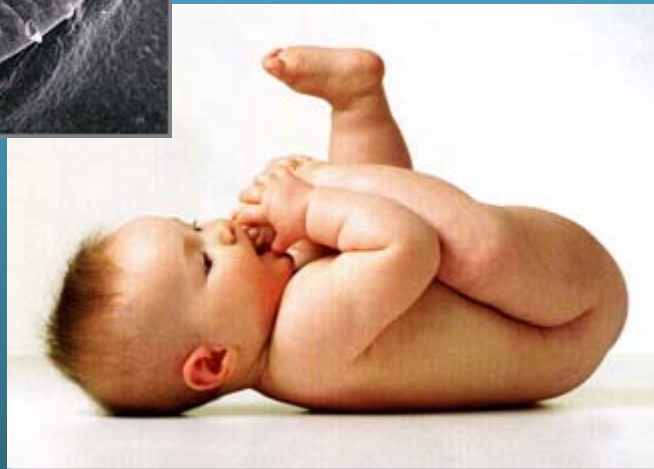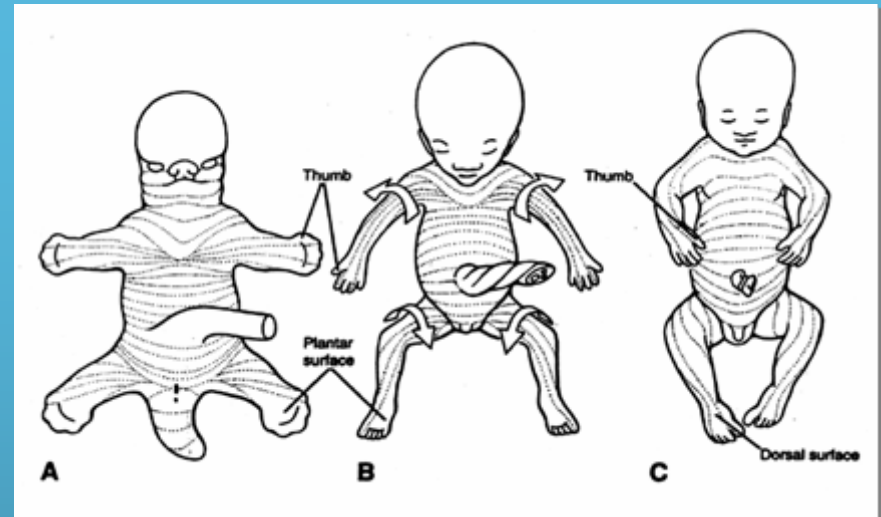
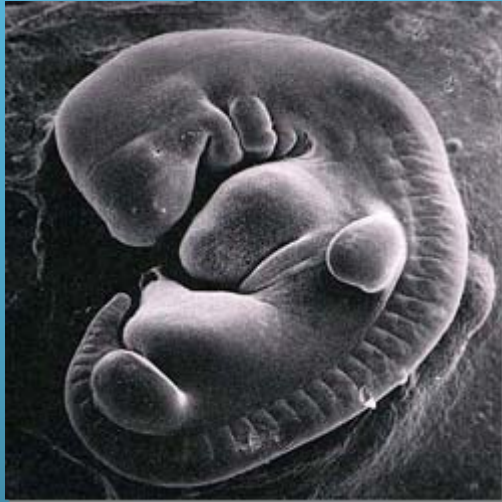
Thieme Atlas of Anatomy: Musculoskeletal System. M Schuenke, et al, 2006.

Anatomy: A Regional Atlas of the Human Body. Carmine Clemente, 4th edition.

Limb Development



Limb Rotation

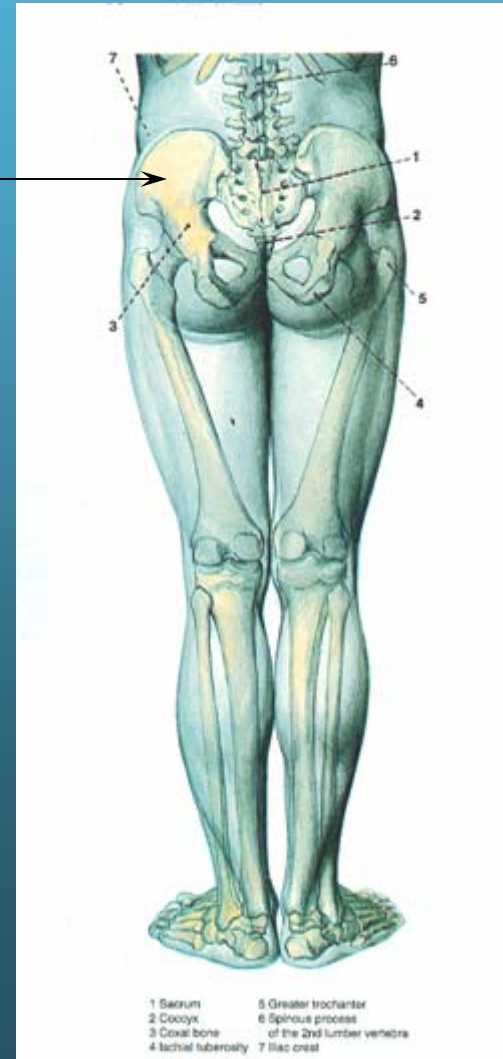


Lower Limb Rotation

- Medial rotation
- Adduction
- Extension

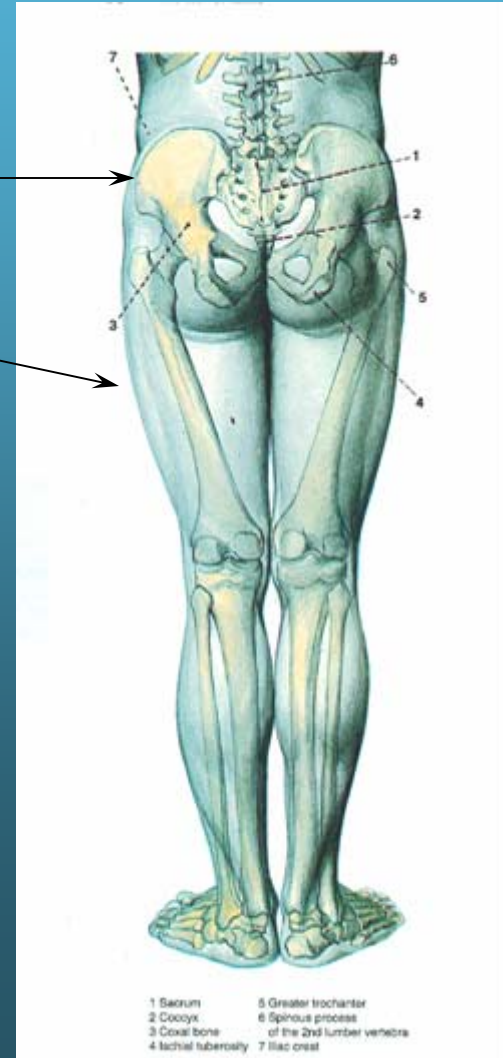
Basic Organization of the Lower Limb

- Segments
 - Pelvic girdle (gluteal)



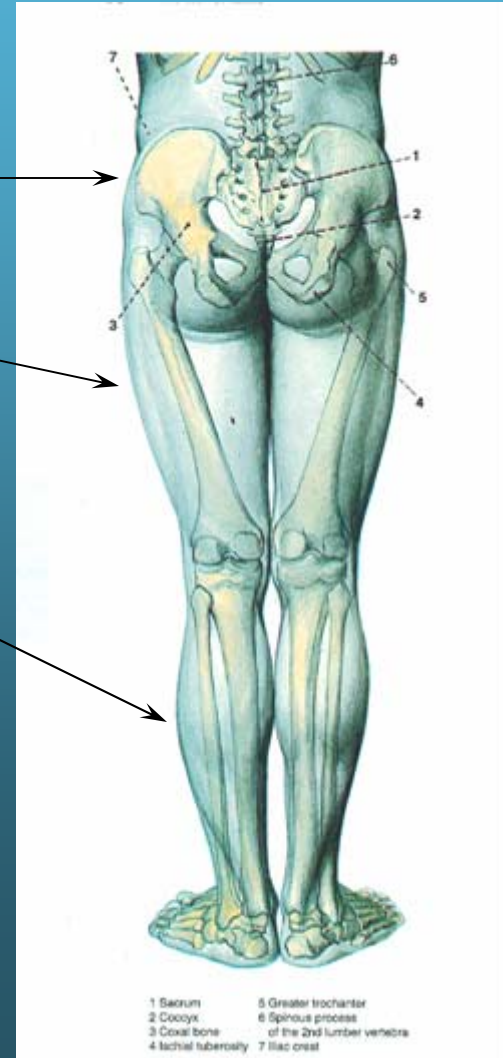
Basic Organization of the Lower Limb

- Segments
 - Pelvic girdle (gluteal)
 - Thigh



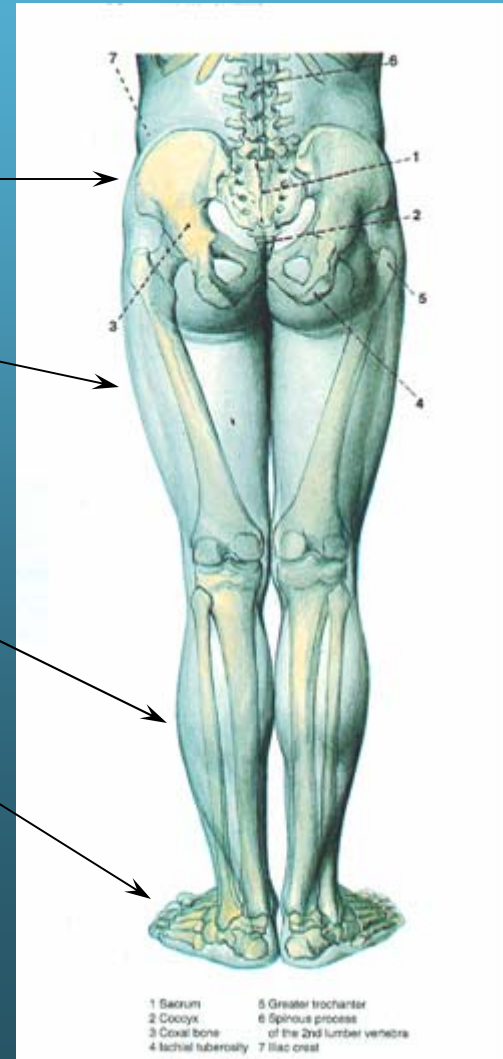
Basic Organization of the Lower Limb

- Segments
 - Pelvic girdle (gluteal)
 - Thigh
 - Leg



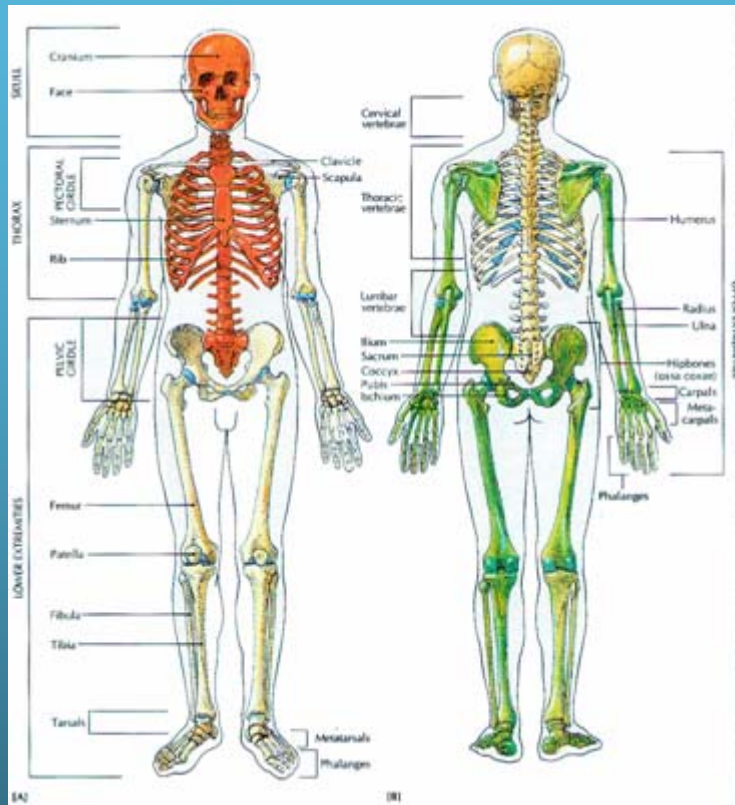
Basic Organization of the Lower Limb

- Segments
 - Pelvic girdle (gluteal)
 - Thigh
 - Leg
 - Foot

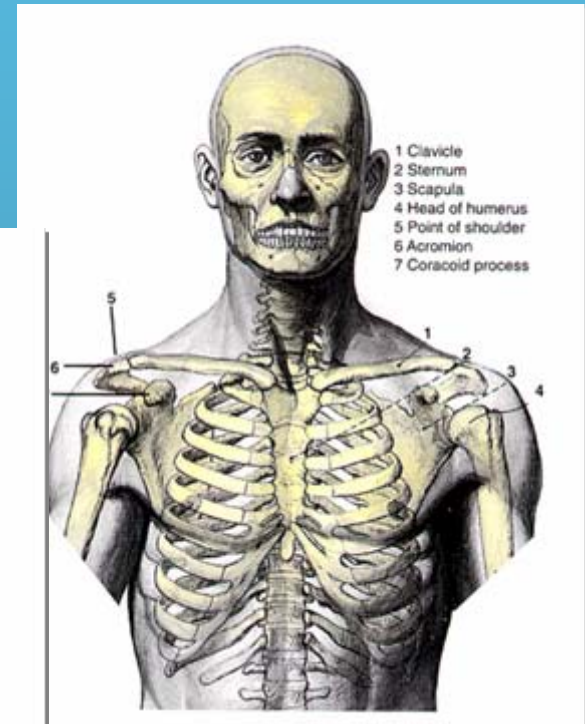
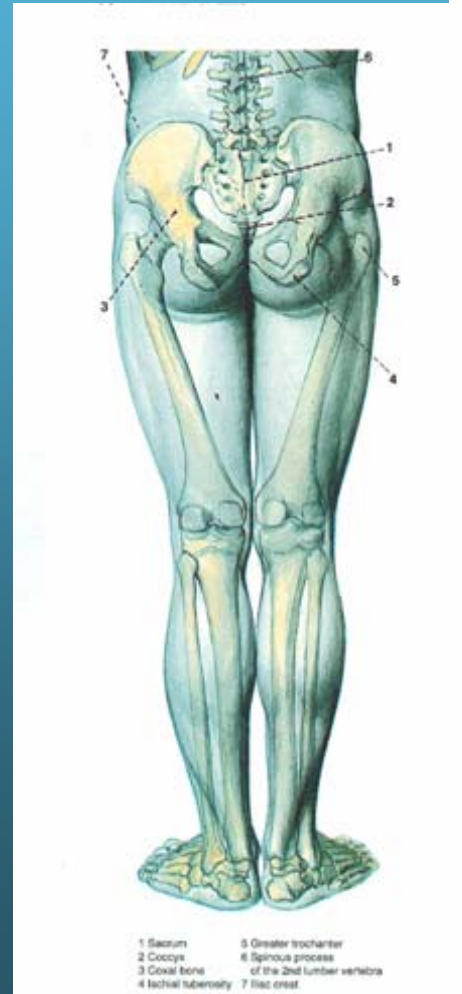


Joints of the Lower Limb

Articulation with Axial Skeleton

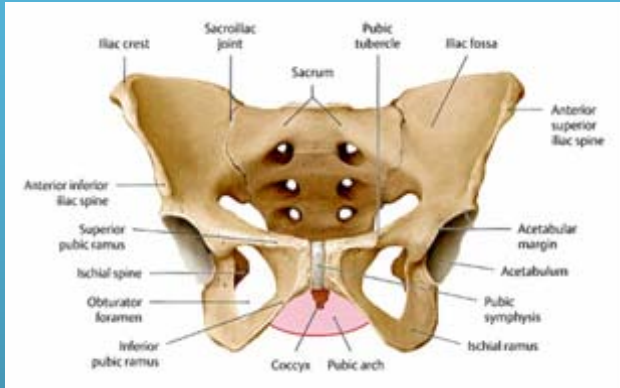


Sacroiliac jt.

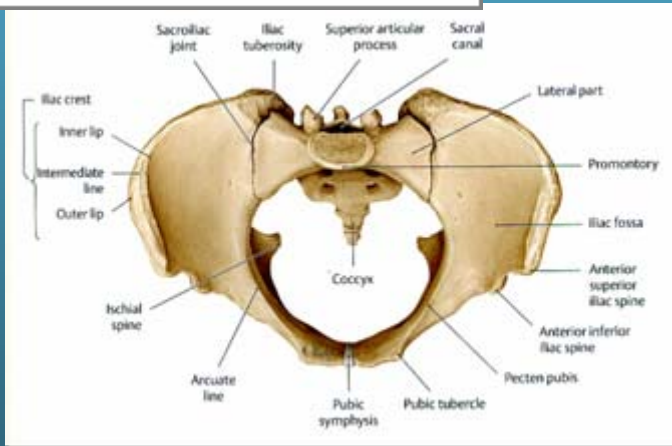
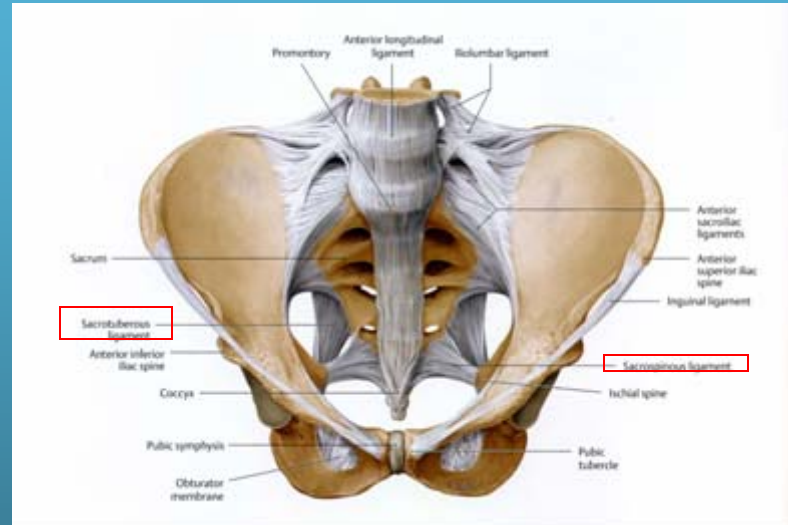


Sternoclavicular jt.,

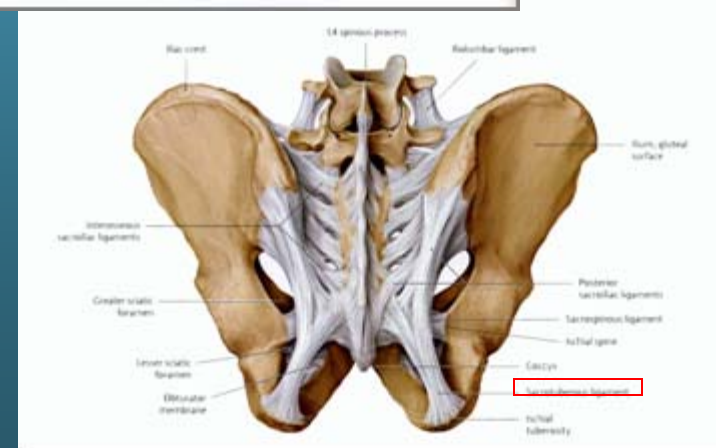
Sacroiliac Joint



Anterior sacroiliac ligaments



Sacroiliac joint



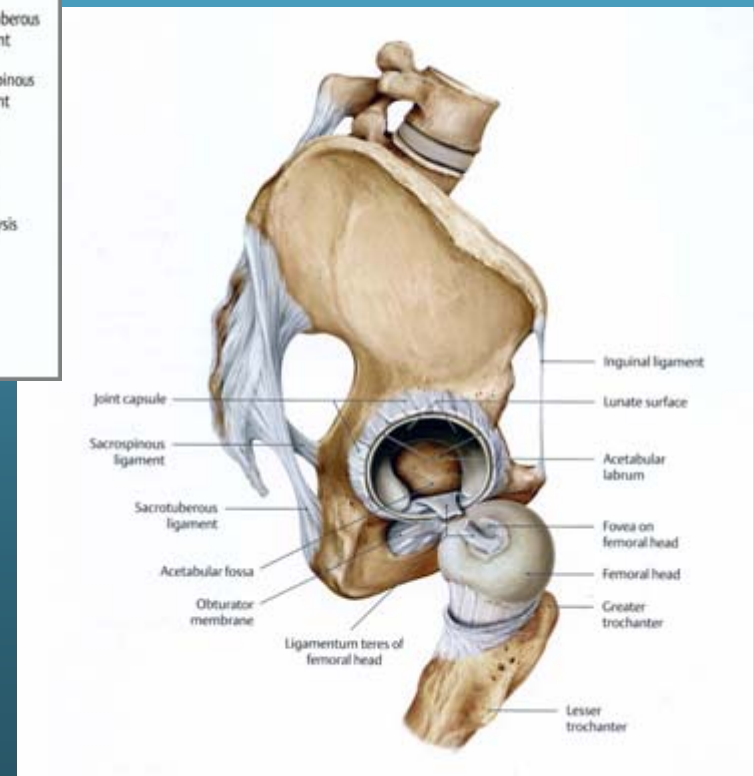
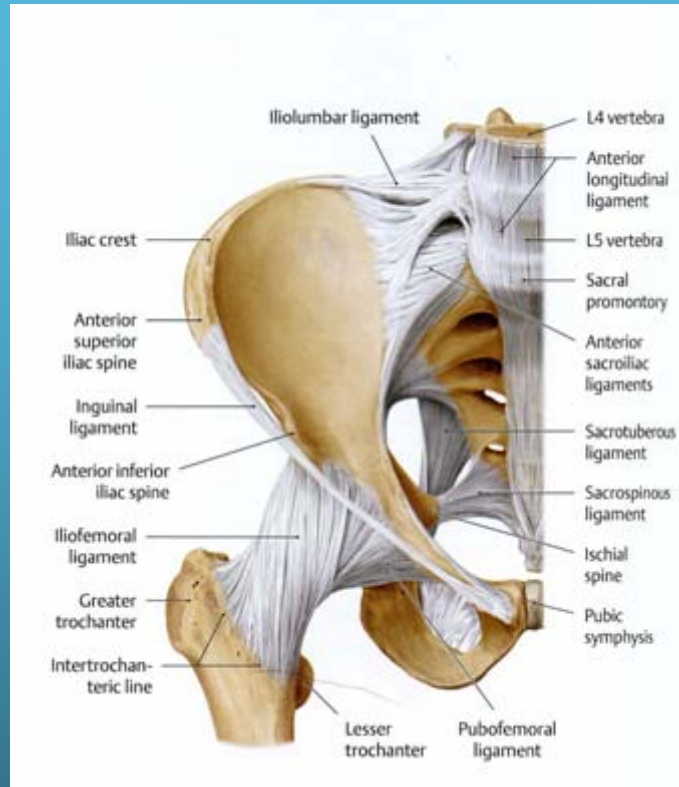
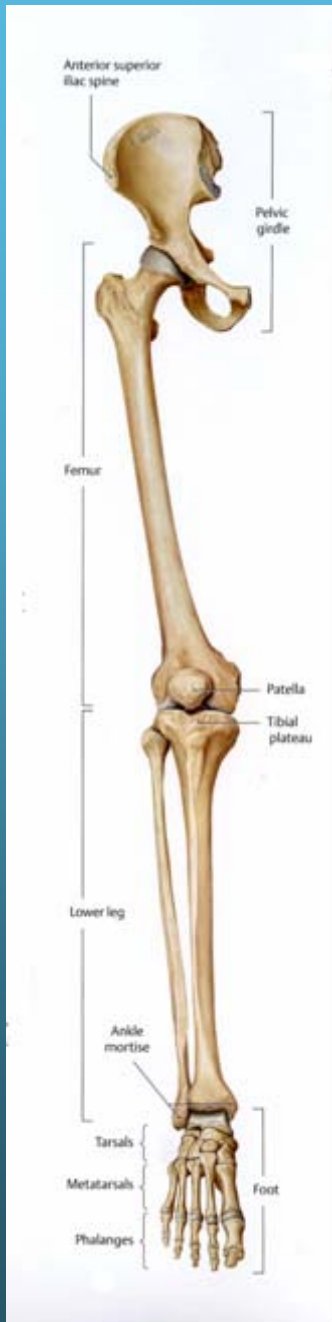
Posterior sacroiliac ligaments

Joints of the Free Limb

Hip

Polyaxial ball and socket joint:

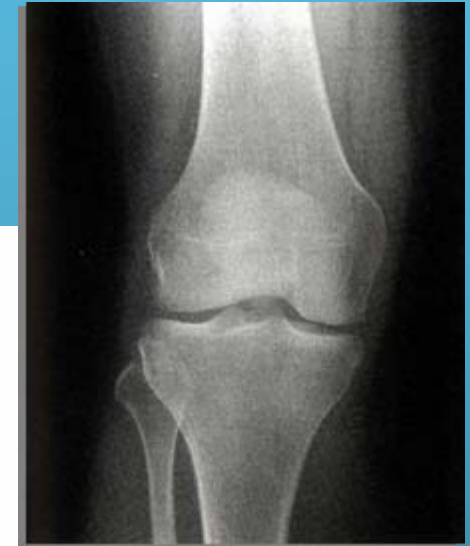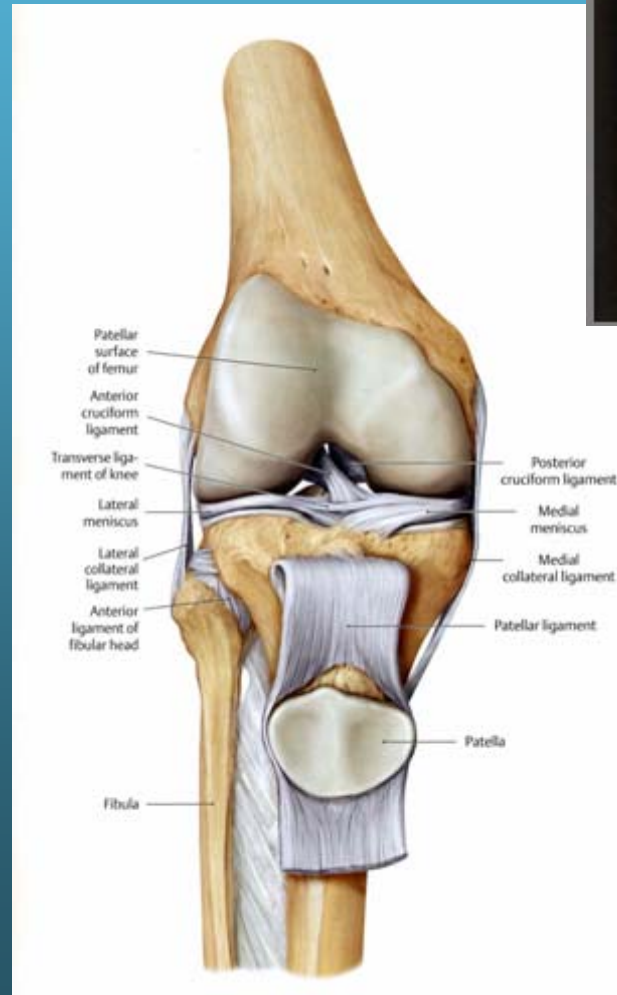
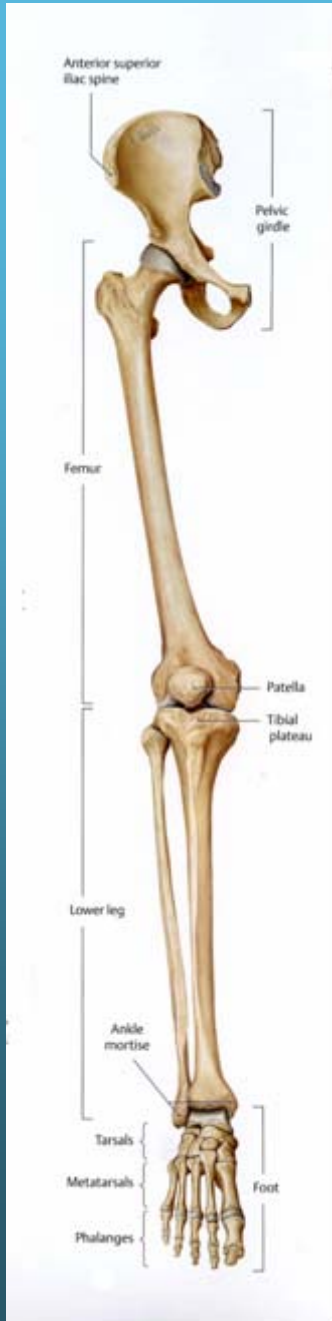
- Flexion/extension
- Adduction/abduction
- Medial/lateral rotation



Joints of the Free Limb

Knee

Modified hinge joint



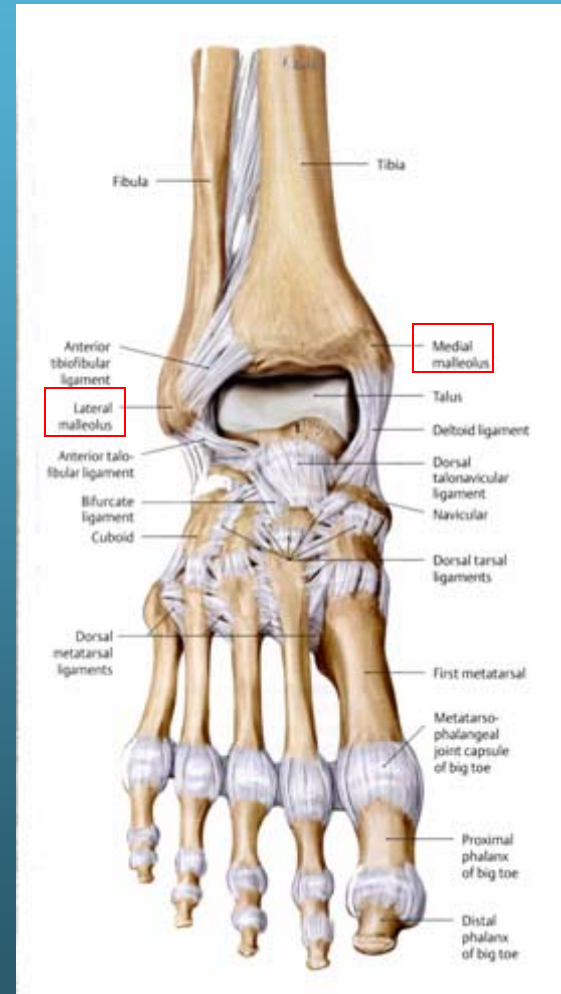
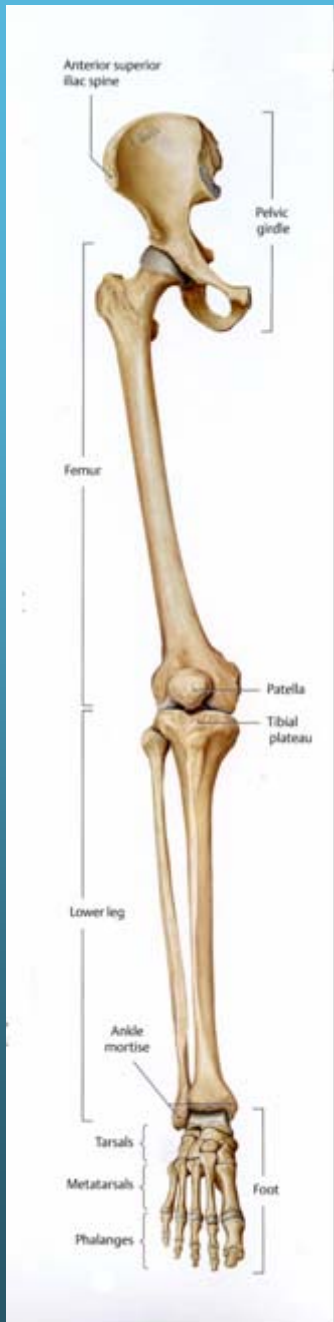
Femur
Tibia
Patella

Joints of the Free Limb

Ankle (talocrural) joint

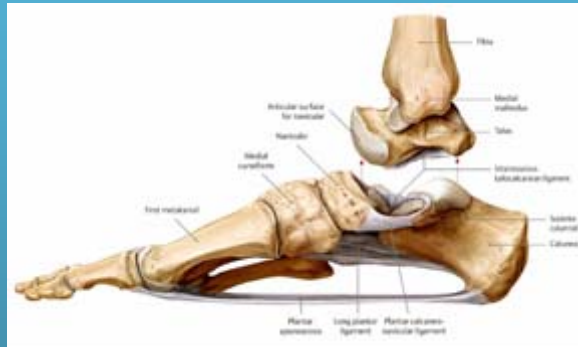
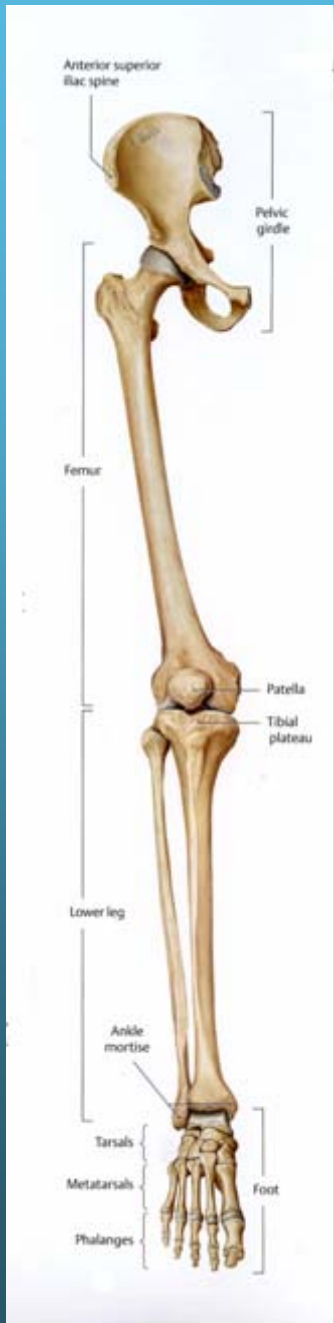
Hinge joint

1 axis of movement:
Dorsiflexion/plantarflexion

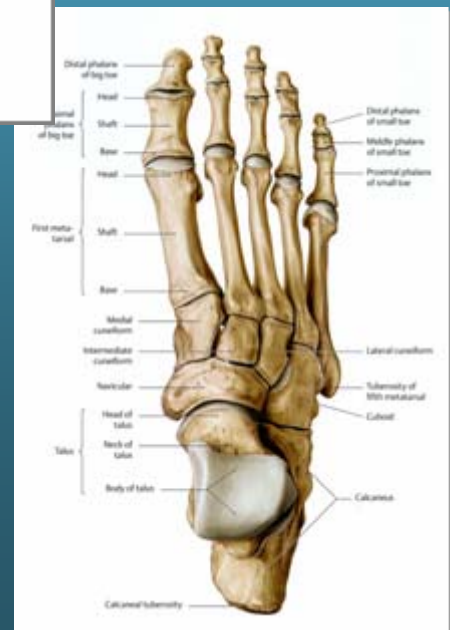
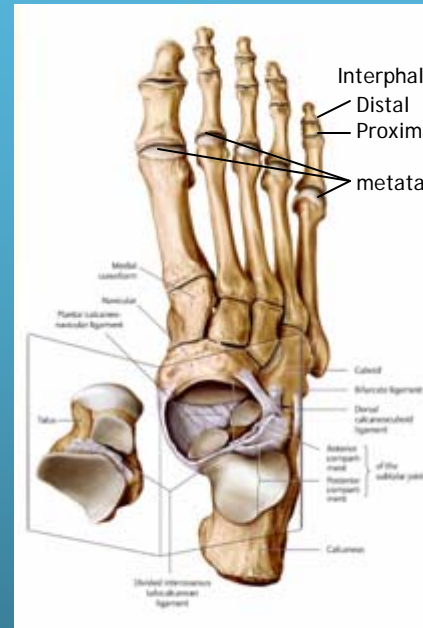

Joints of the Free Limb

Foot



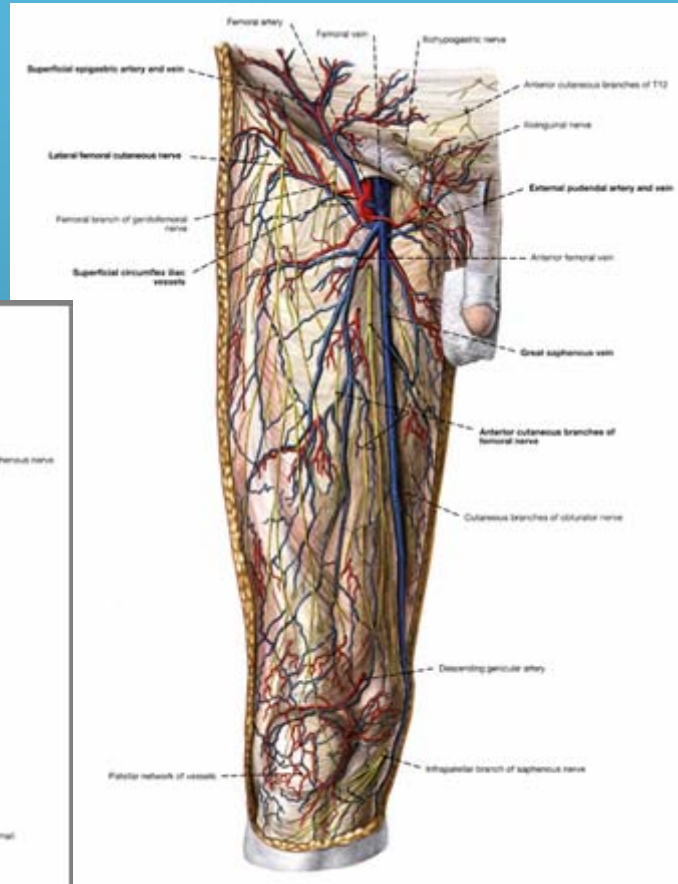
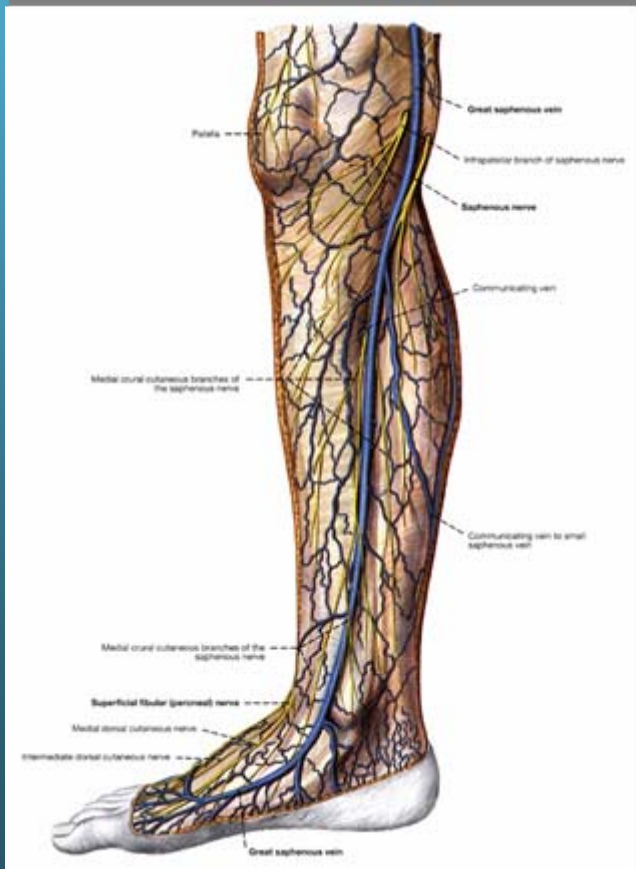
Inversion/eversion occurs at subtalar joint



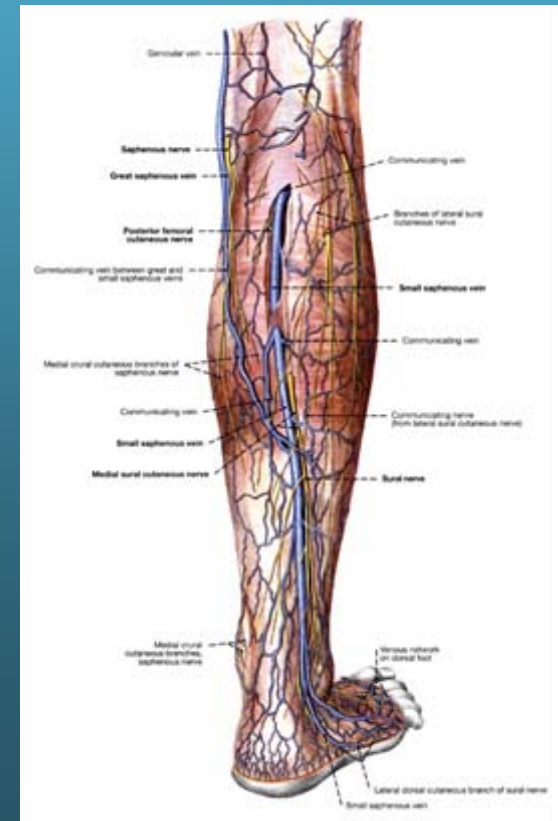
Vasculature of the Lower Limb

Superficial Veins

Great saphenous v.



Small saphenous v.



Arterial Blood Supply

External Iliac a



Femoral a



Popliteal a



Anterior tibial a

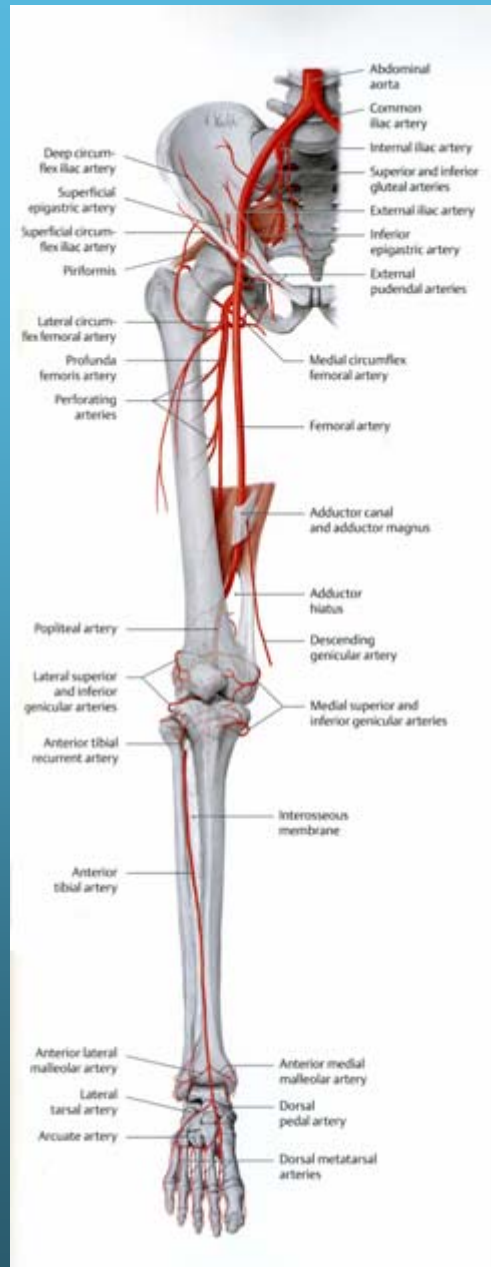
Posterior tibial aa



dorsalis pedis



med/lat plantar a



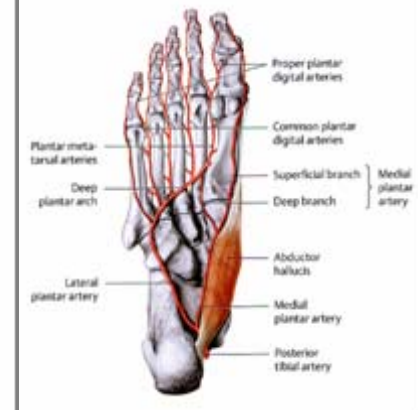
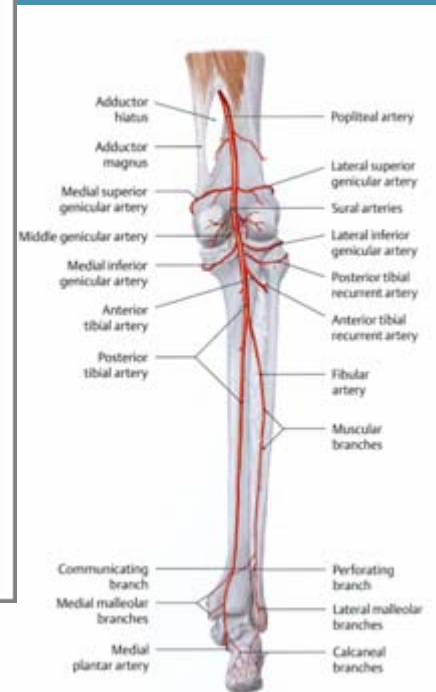
Internal Iliac a



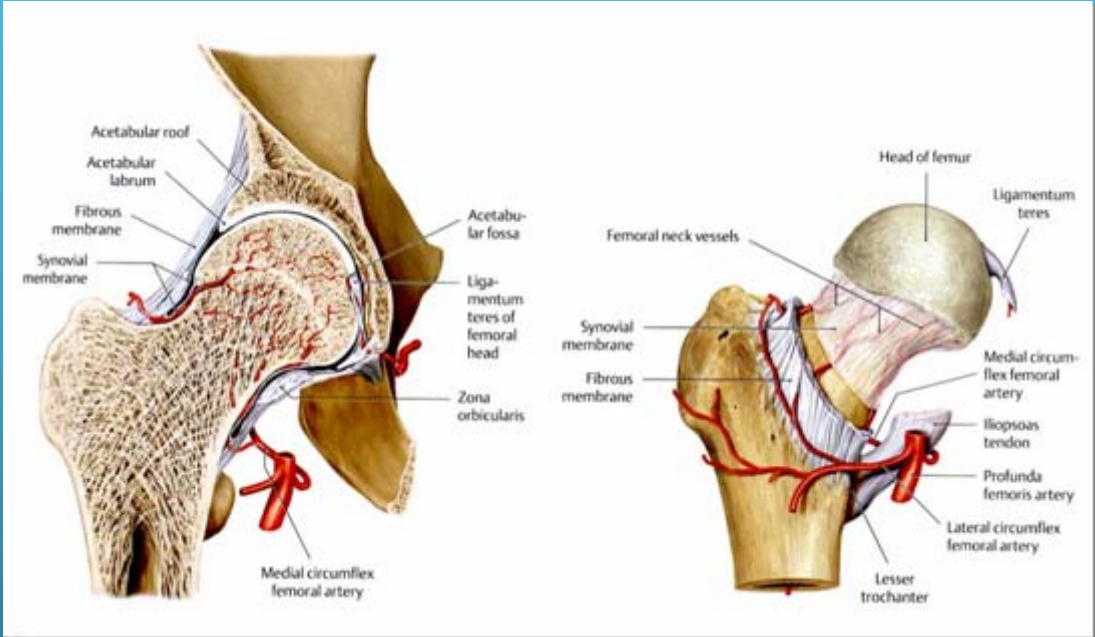
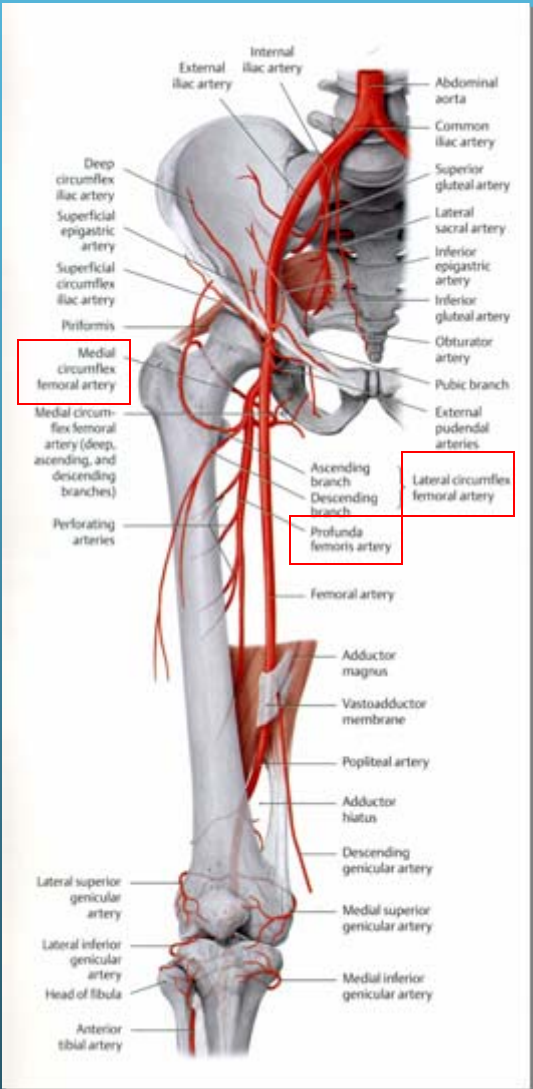
Superior gluteal a

Inferior gluteal a

Obturator a



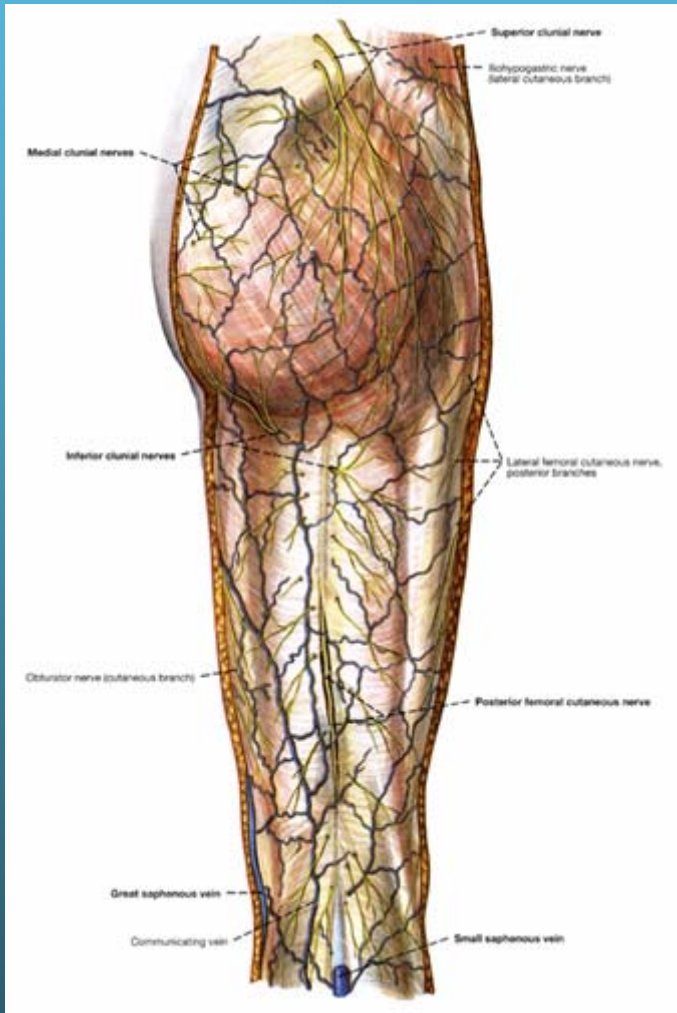
Deep Femoral Artery



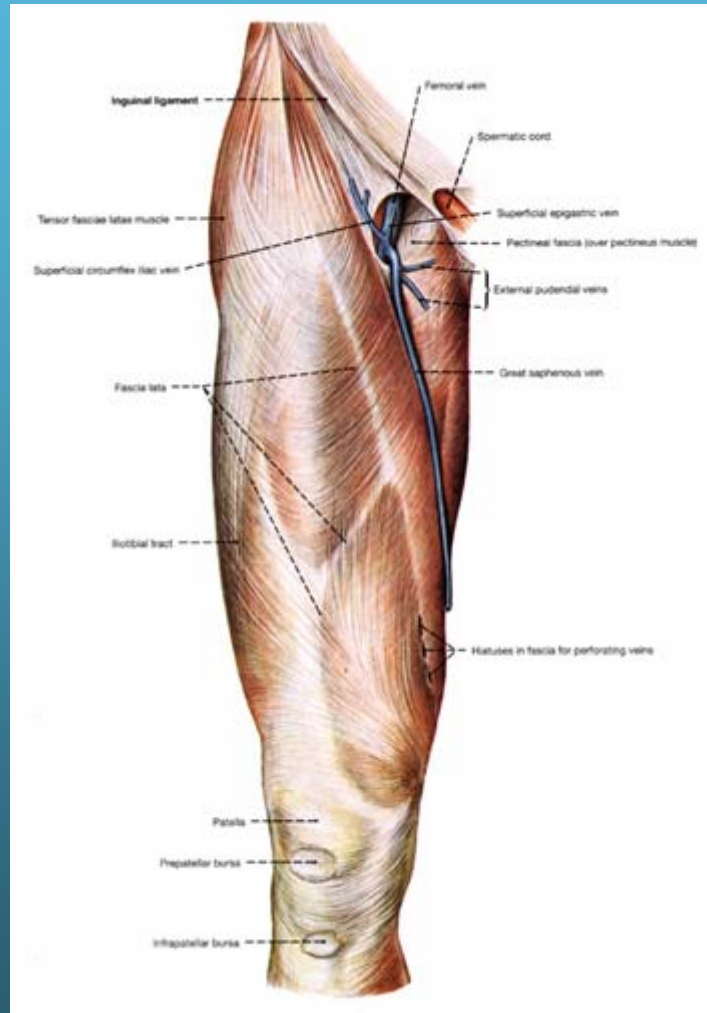
Medial & lateral femoral circumflex arteries

Fascial Compartments

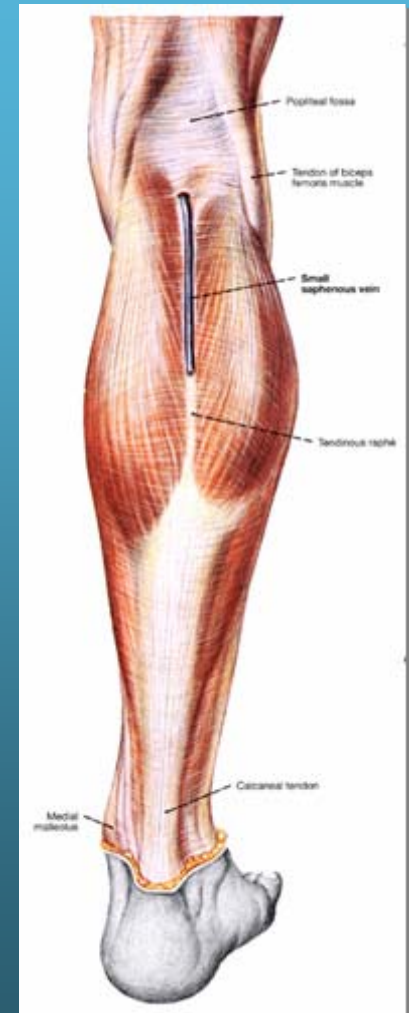
Fascia of the Lower Limb



Gluteal Fascia

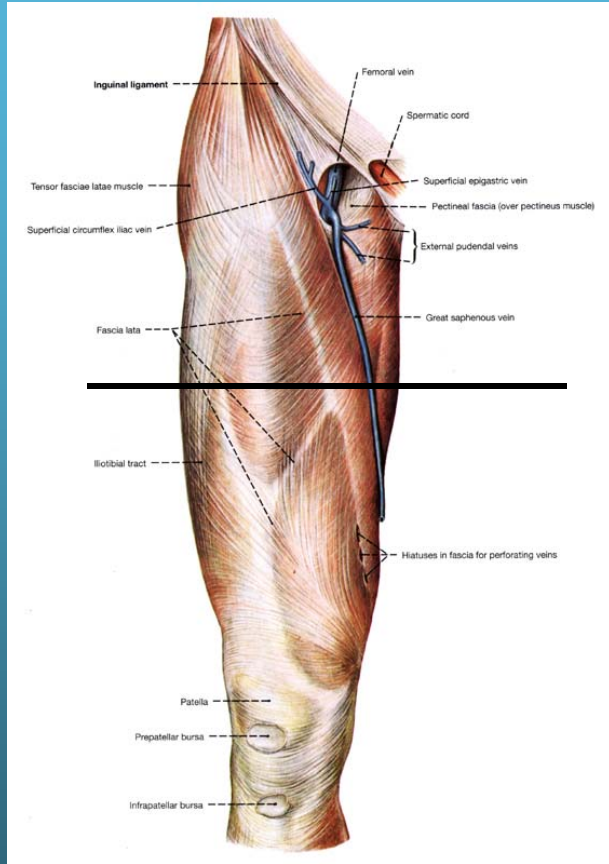


Fascia Lata

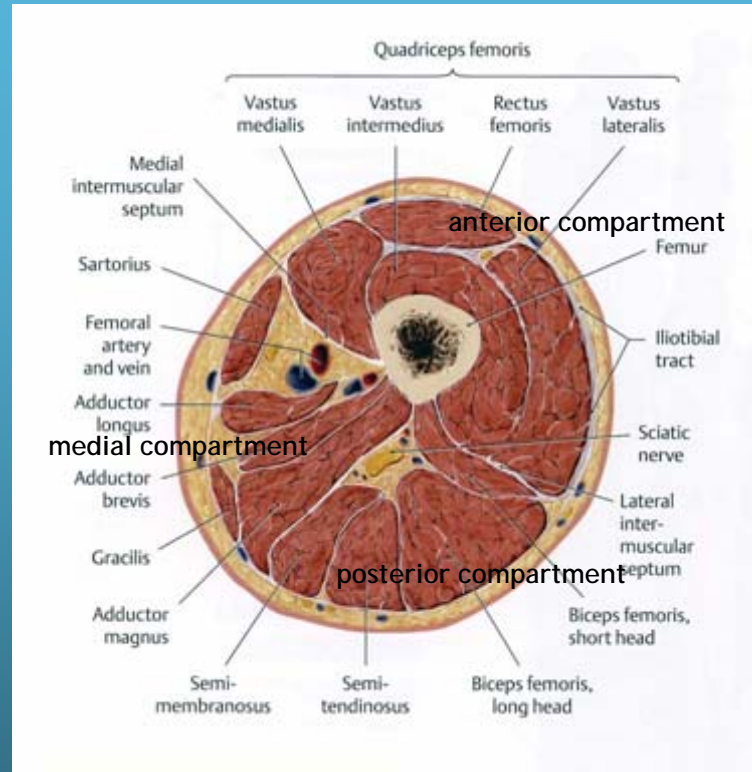


Crural Fascia

Fascial Compartments of the Thigh



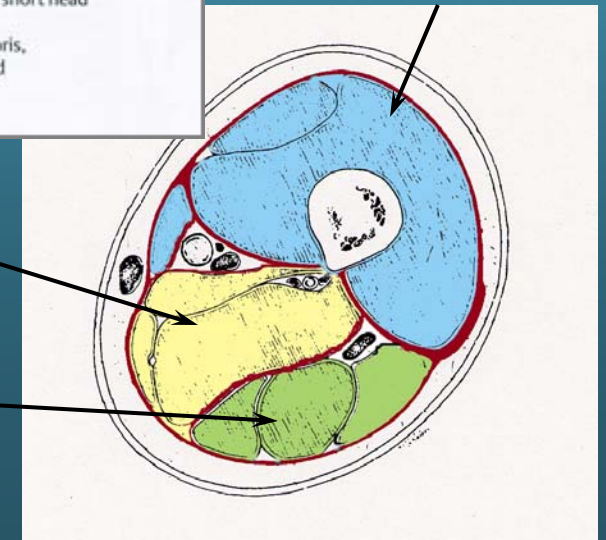
Fascia Lata



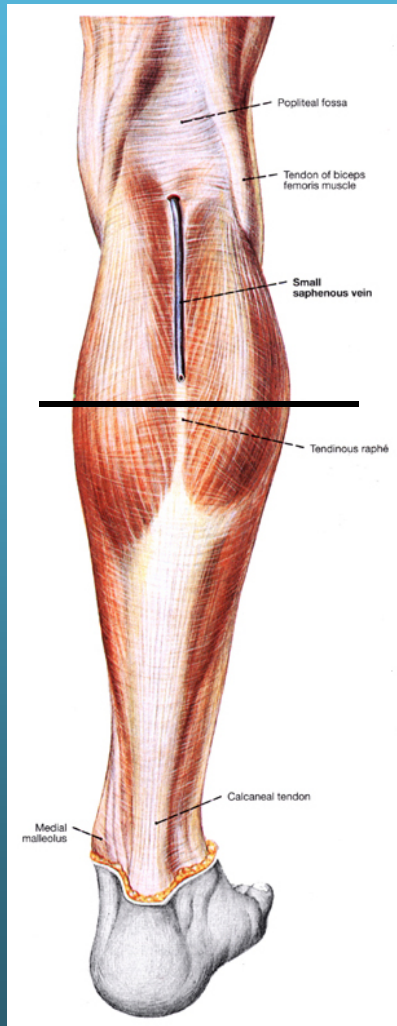
Anterior compartment

Medial (adductor) compartment

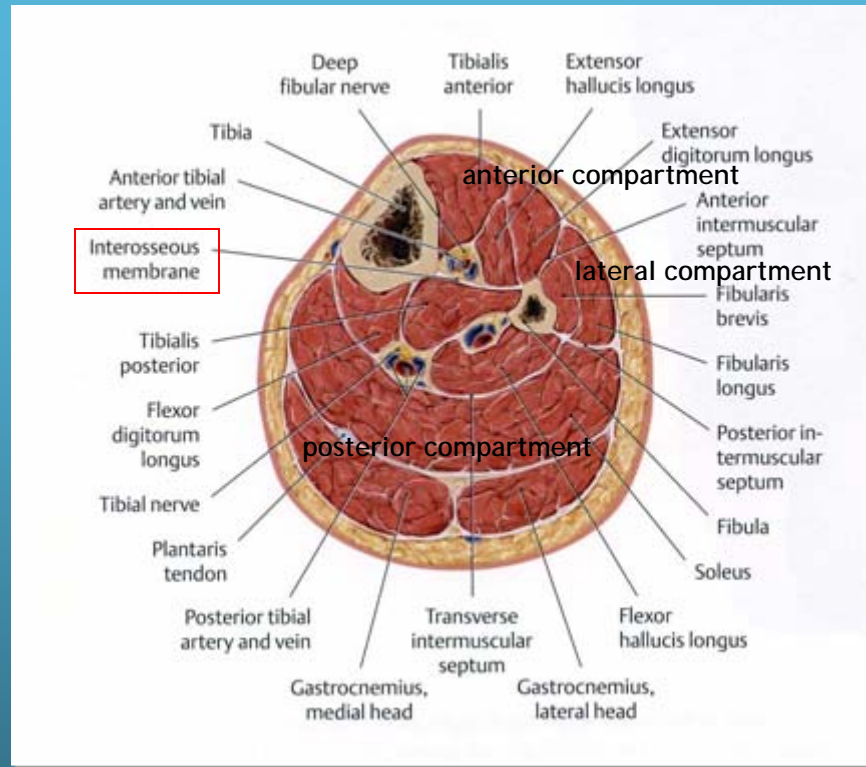
Posterior compartment



Fascial Compartments of the Leg



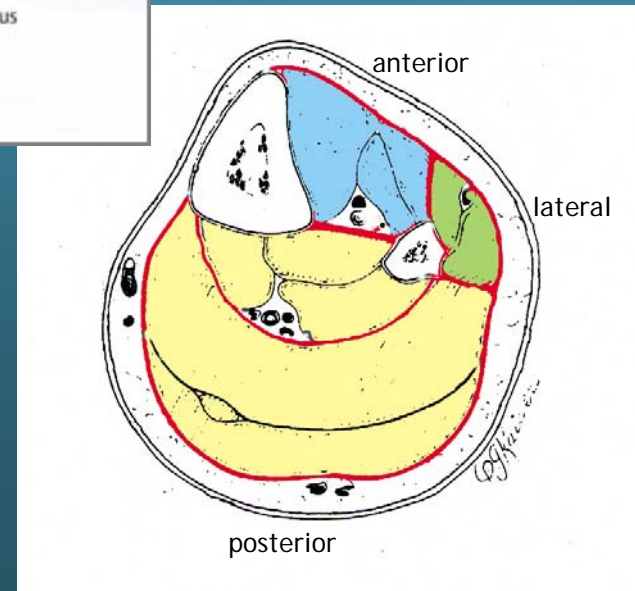
Crural Fascia



Anterior crural compartment

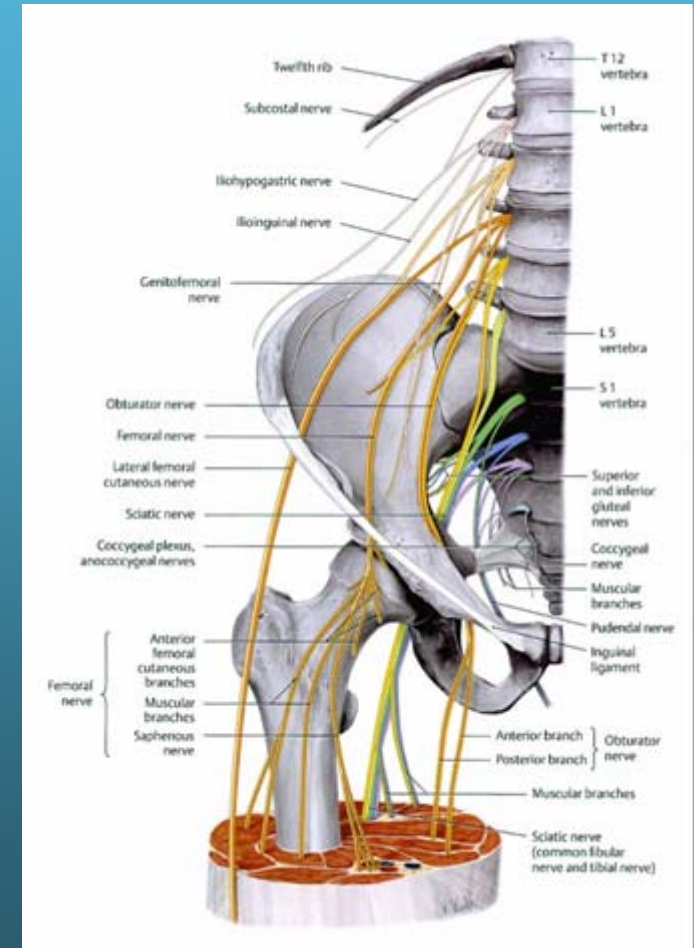
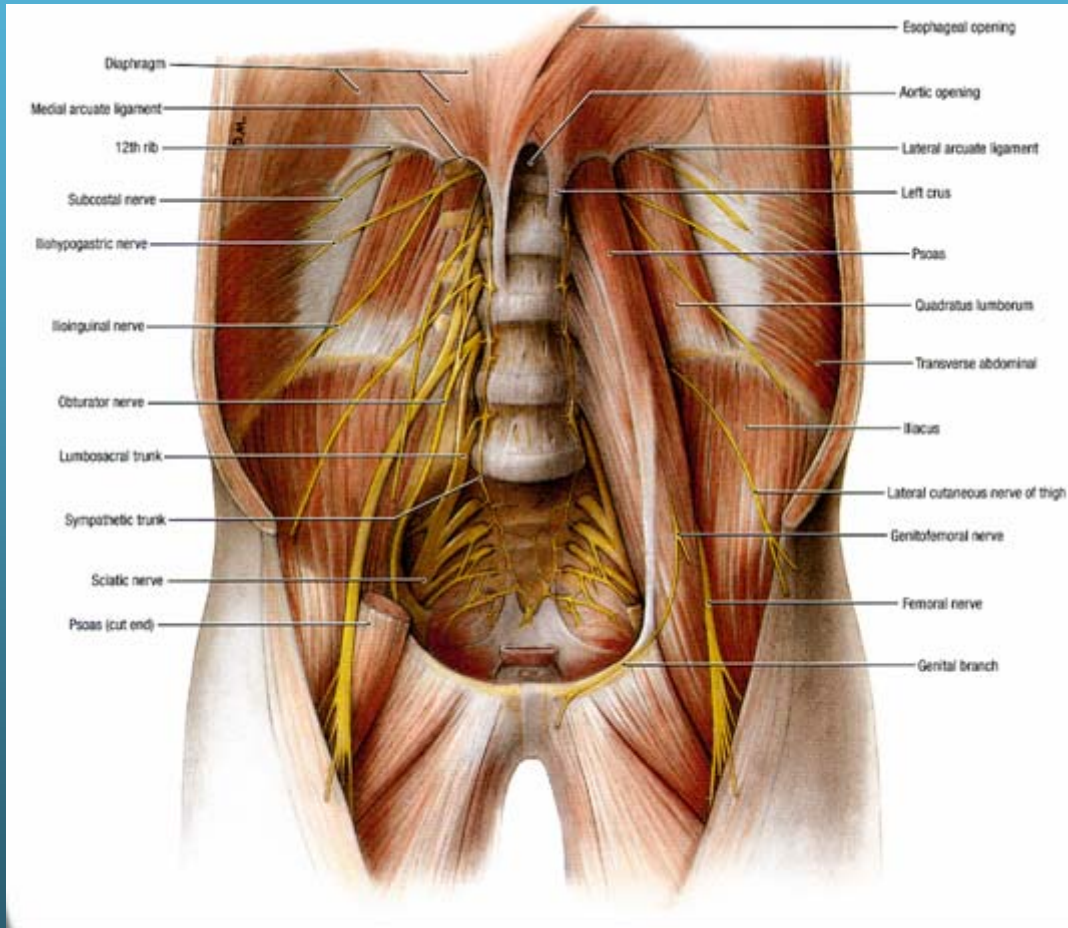
Lateral crural compartment

Superficial & deep posterior crural compartments



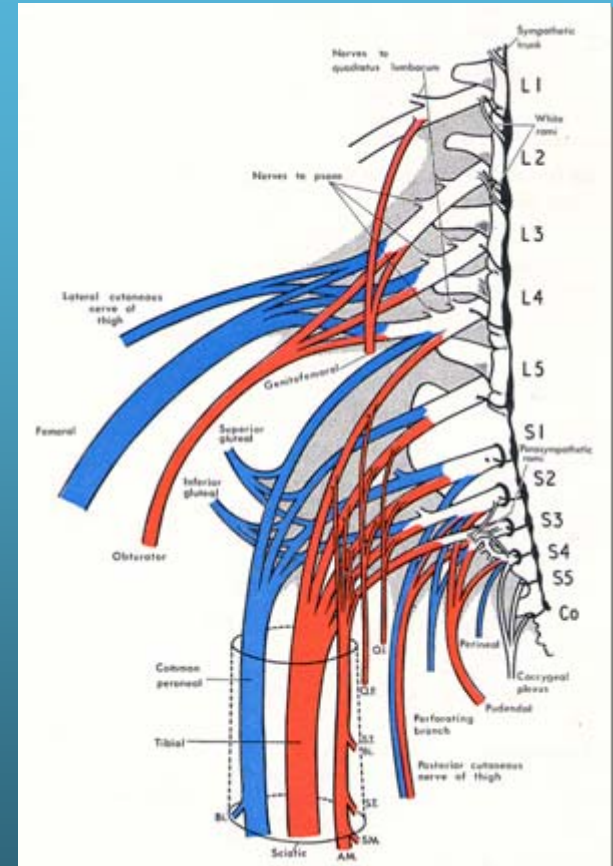
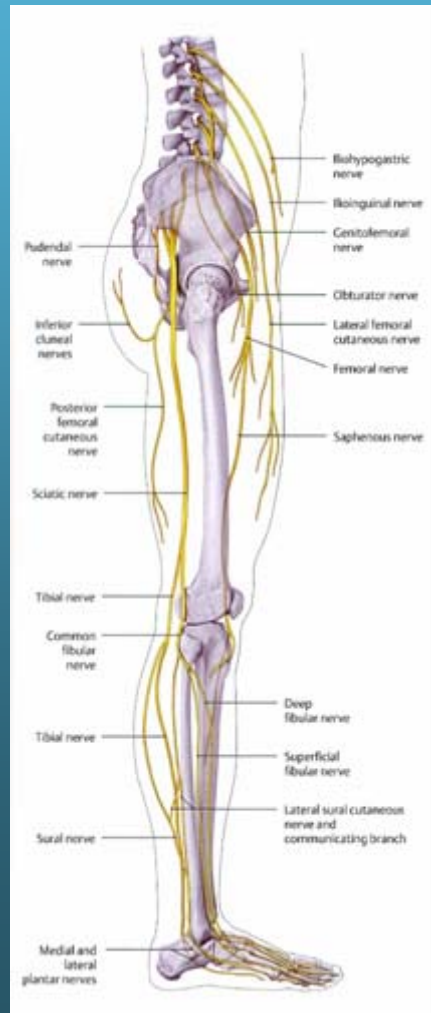
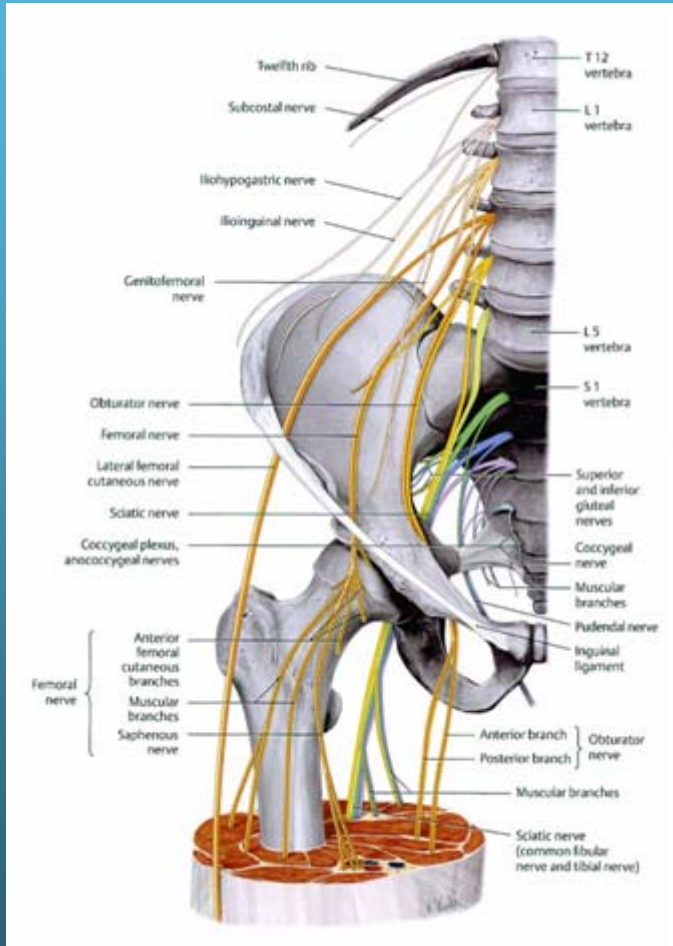
Lumbosacral Plexus

Innervation of the Lower Limb: Lumbosacral Plexus (L1 - S3)



Lumbosacral Plexus

L1 - S3



Gluteal innervation:

Superior gluteal n (L4,5, S1):

- gluteus medius m.
- gluteus minimus m.
- tensor fascia lata

Inferior gluteal n (L5, S1,2):

- gluteus maximus m.

N to obturator internus

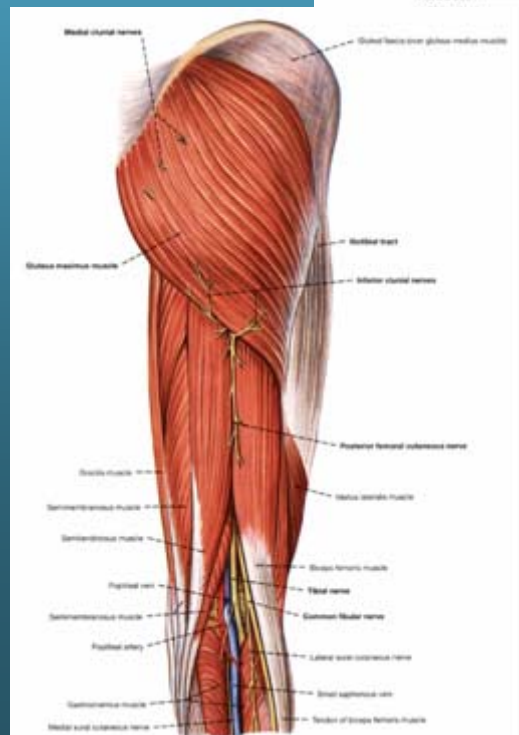
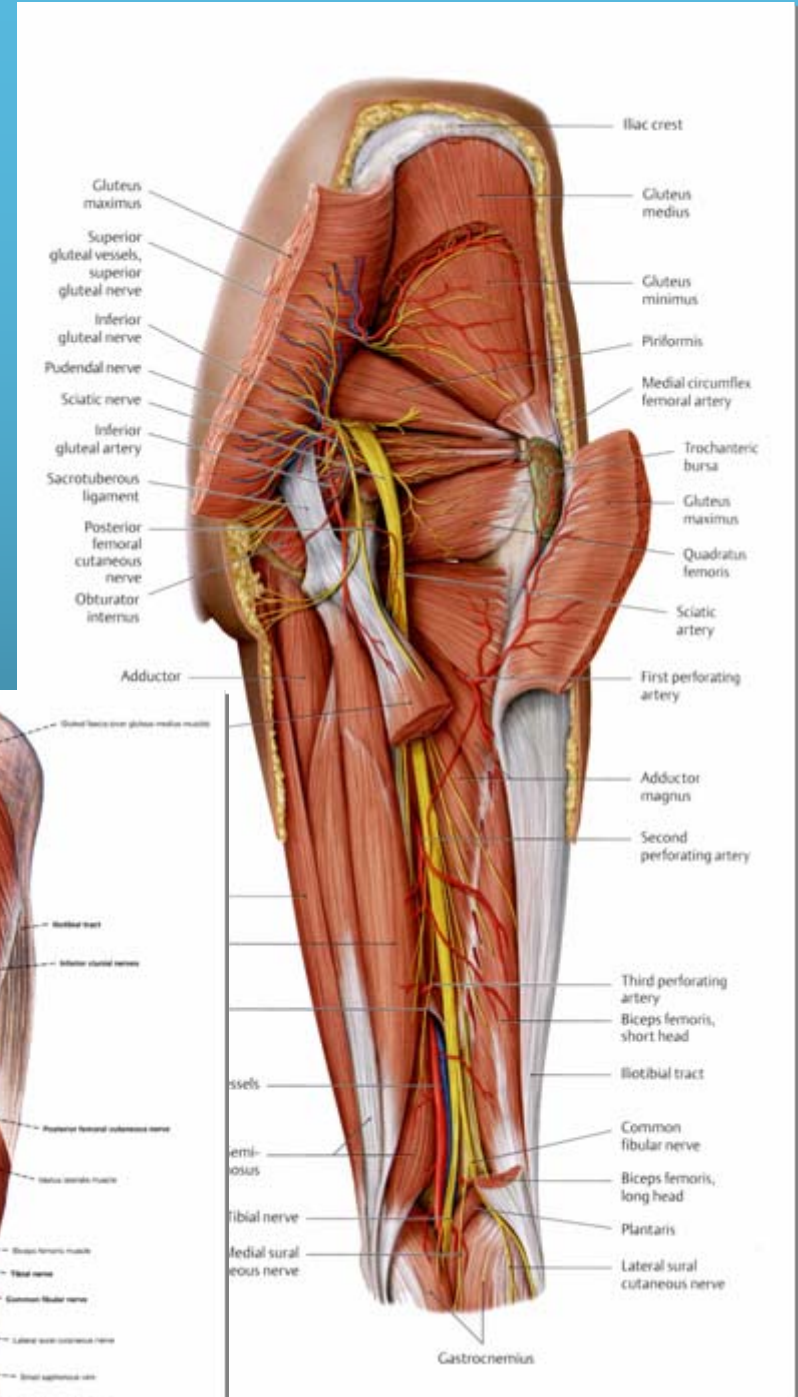
(L5, S1, 2):

- obturator internus
- superior gemellus





Nerve to quadratus femoris

(L4,5, S1):

- inferior gemellus
- quadratus femoris

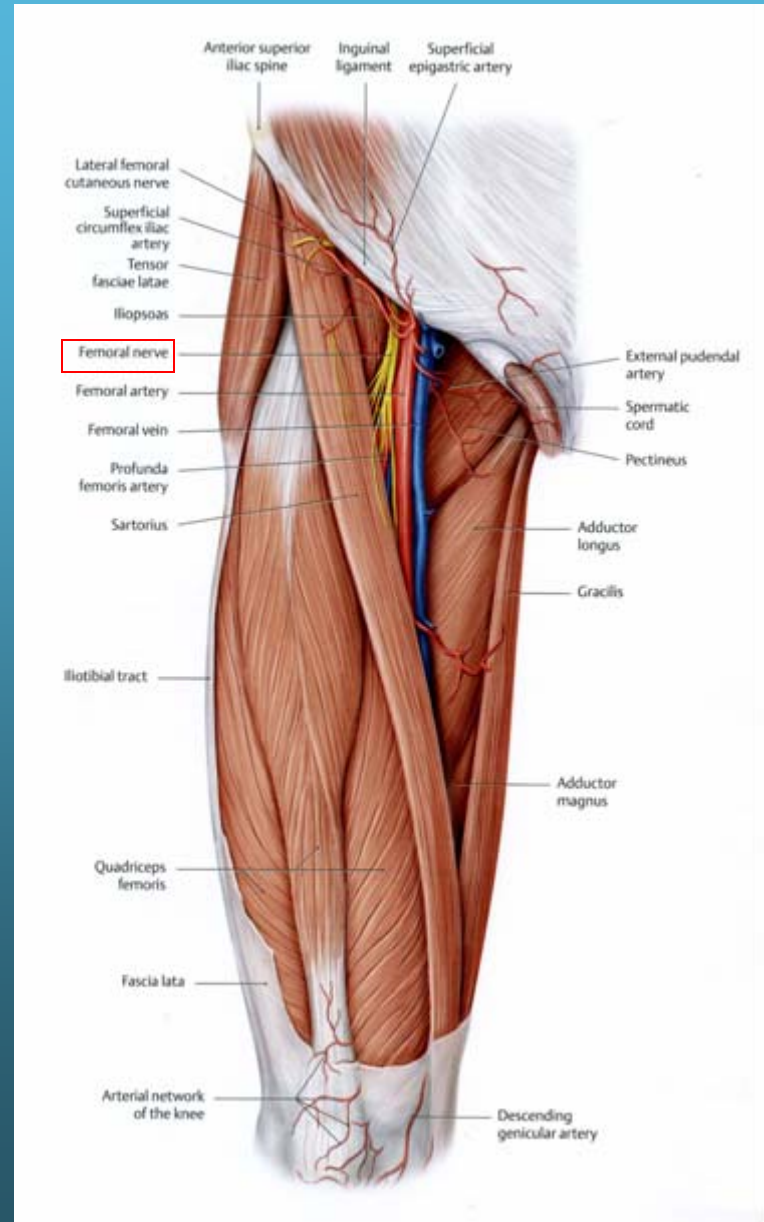
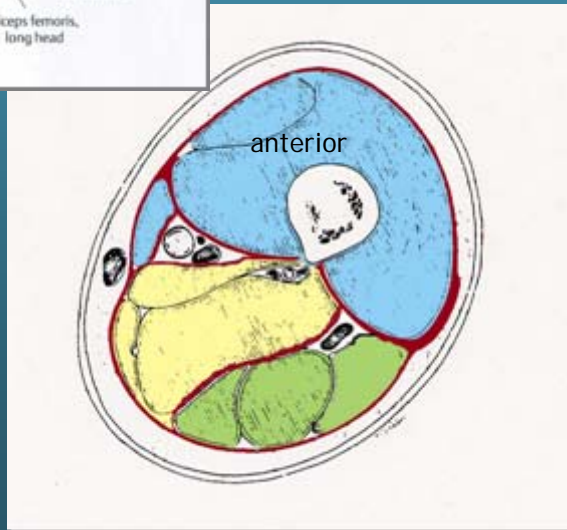
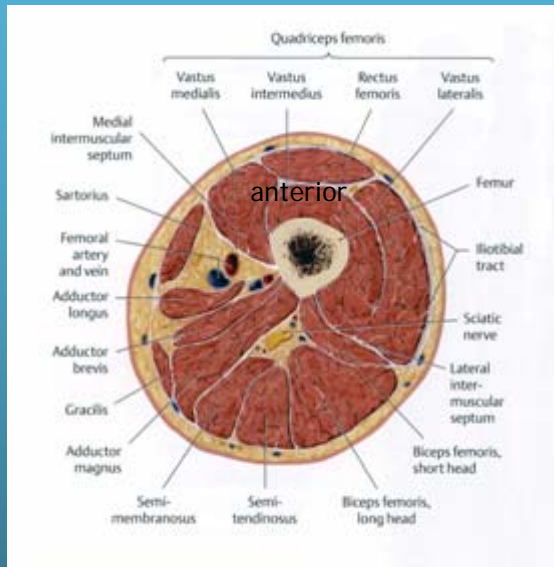


Compartmental Innervation Of the Free Limb

	Anterior compartment	Medial compartment	Posterior compartment	Lateral compartment
Thigh				
Leg				
Foot				

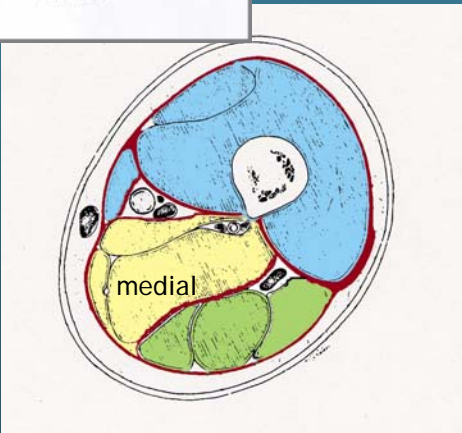
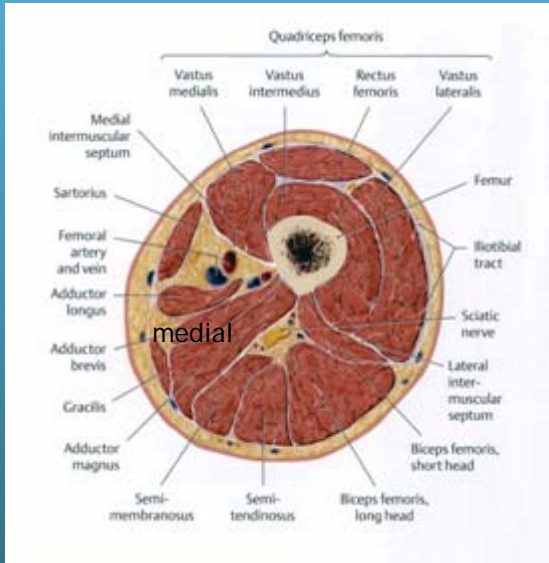
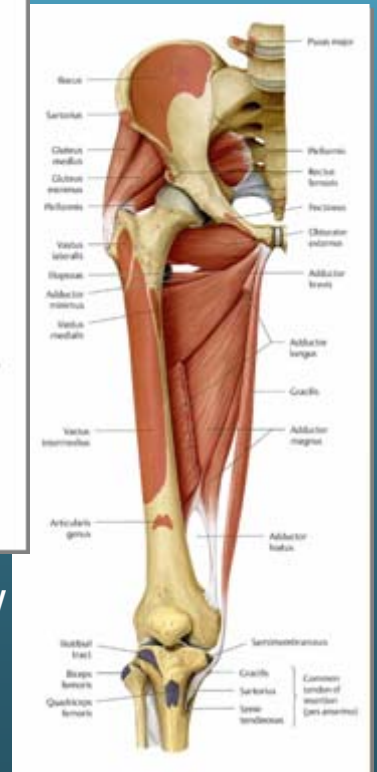
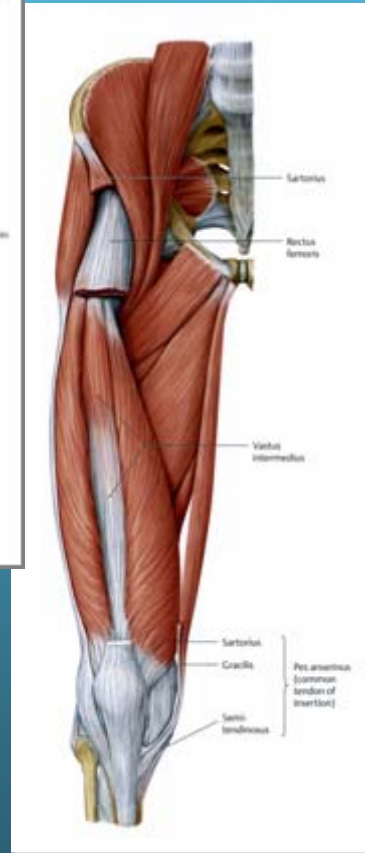
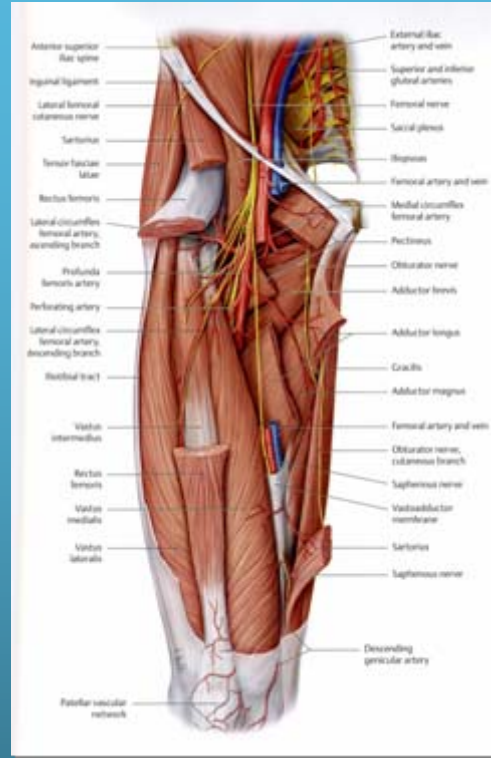
Anterior compartment of the thigh

Innervation: femoral nerve



Medial compartment of the thigh

Innervation:
obturator nerve*



*Adductor Magnus innervated by both obturator n and tibial division of sciatic n

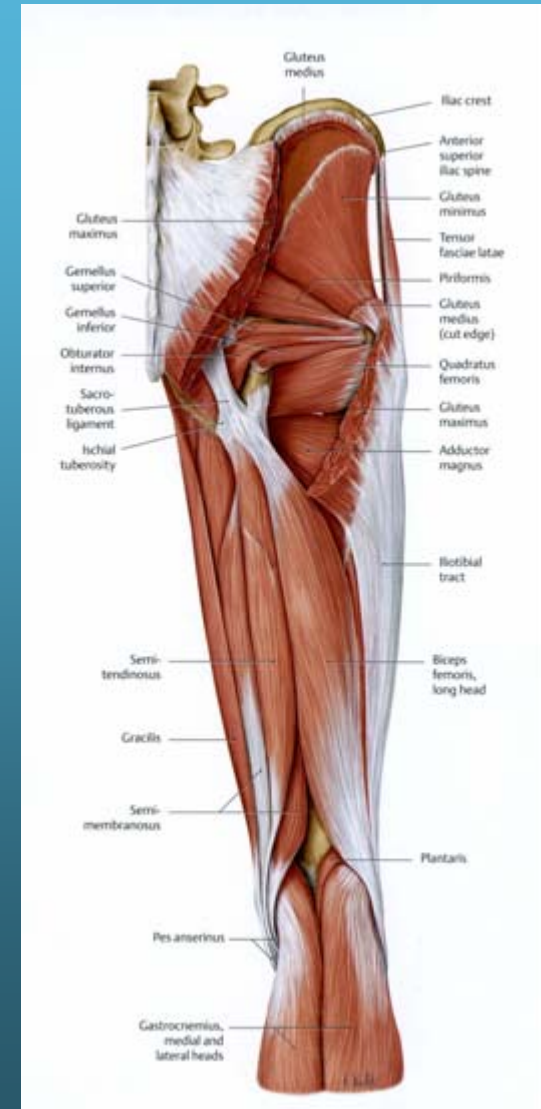
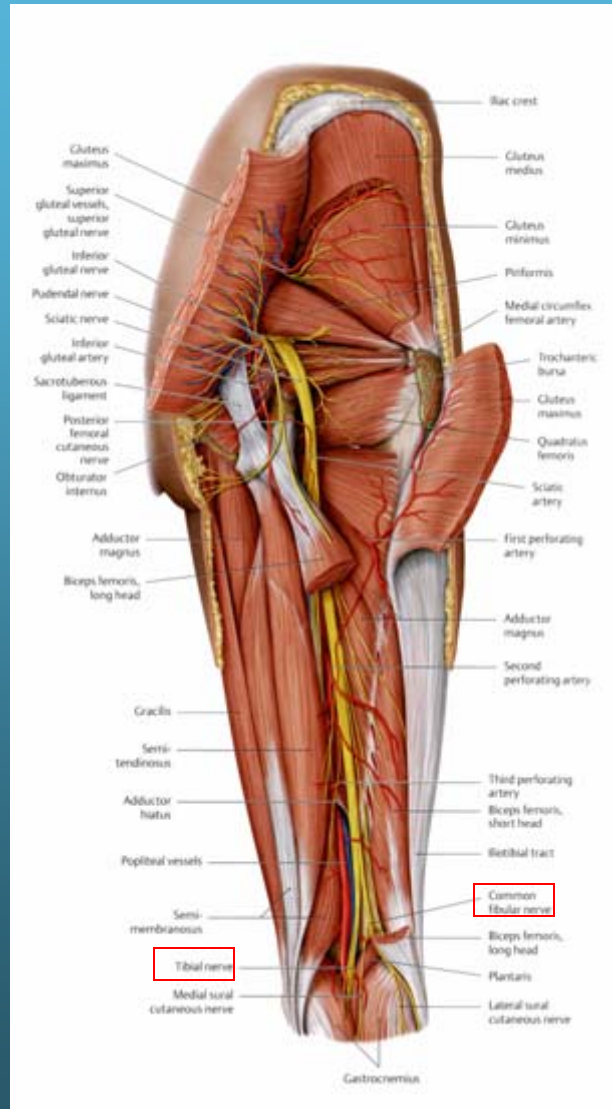
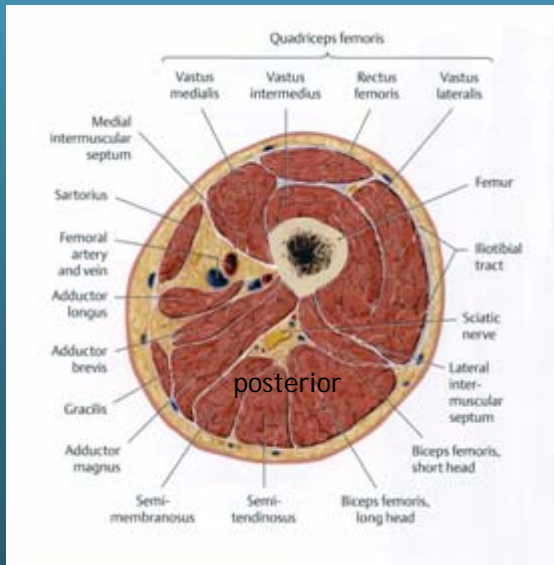
Posterior compartment of the thigh

Hamstring mm: arise from ischial tuberosity & innervated by tibial division of sciatic n.

Innervation:

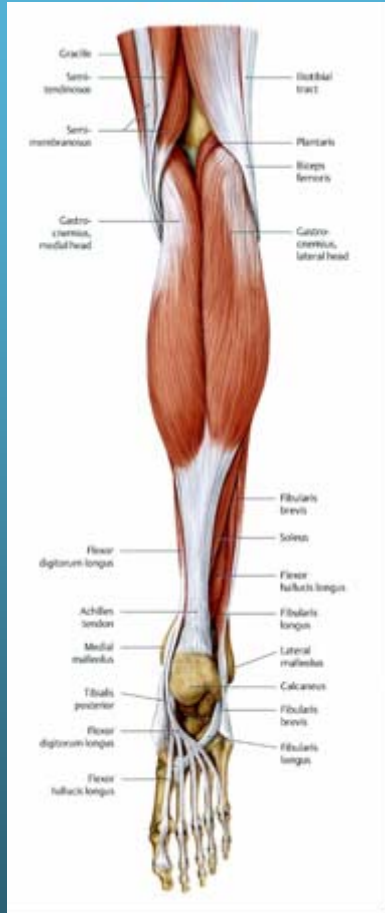
- Tibial division of sciatic nerve

✓ Except short head of biceps femoris: common fibular division of sciatic nerve

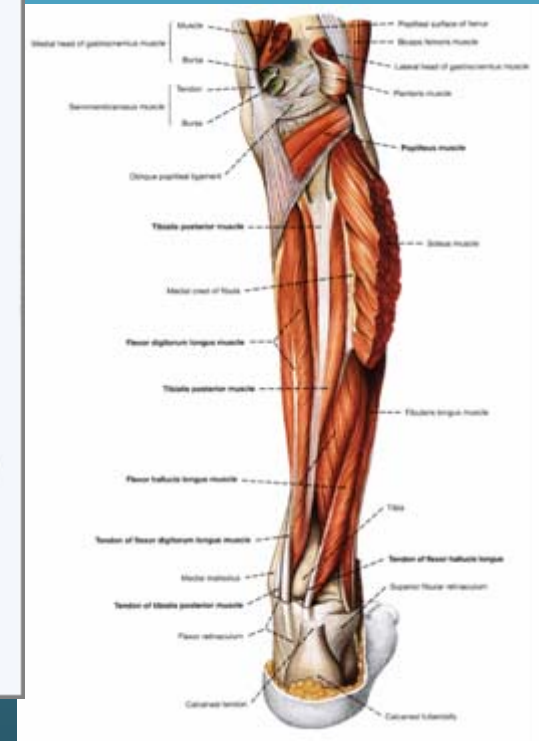
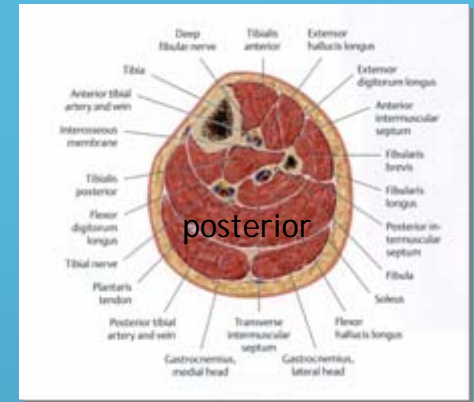
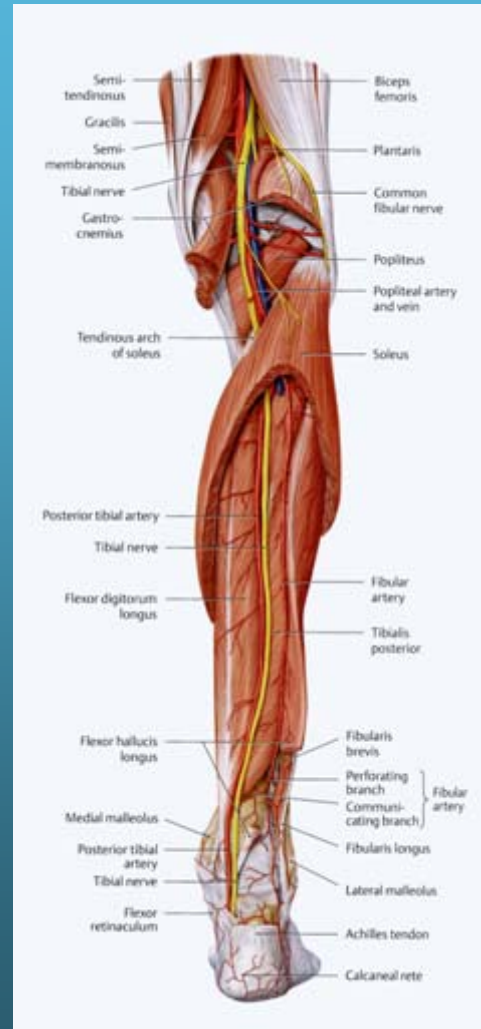
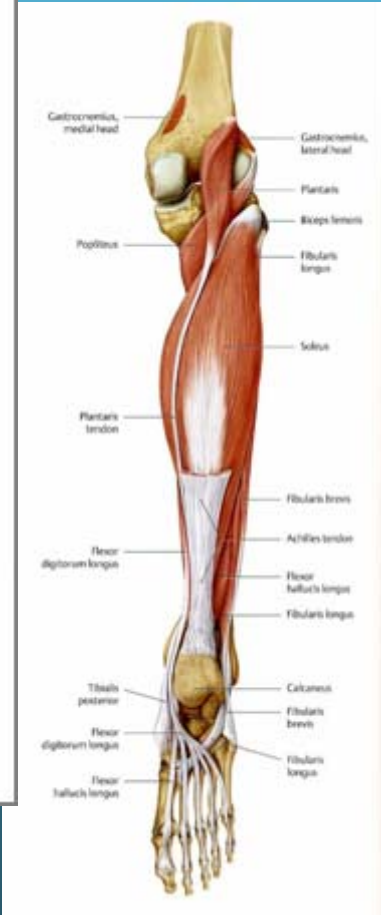


Posterior compartment of the leg

Innervation: tibial n.



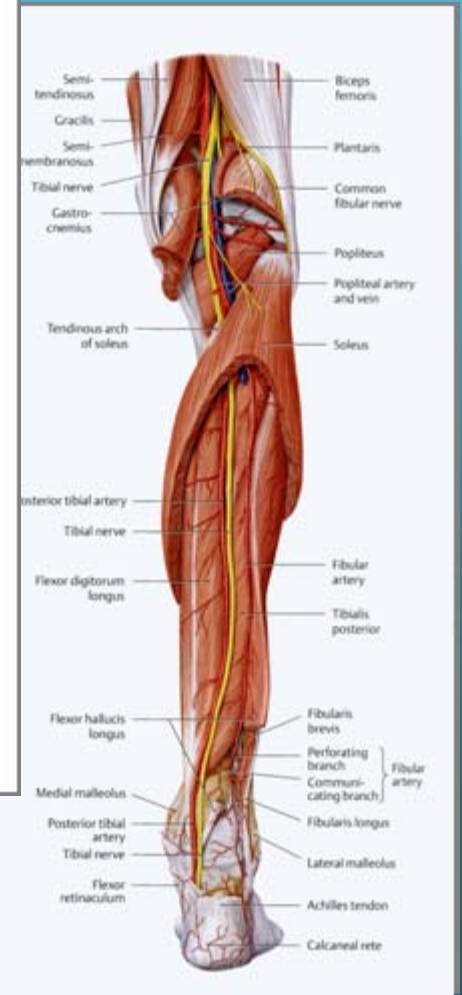
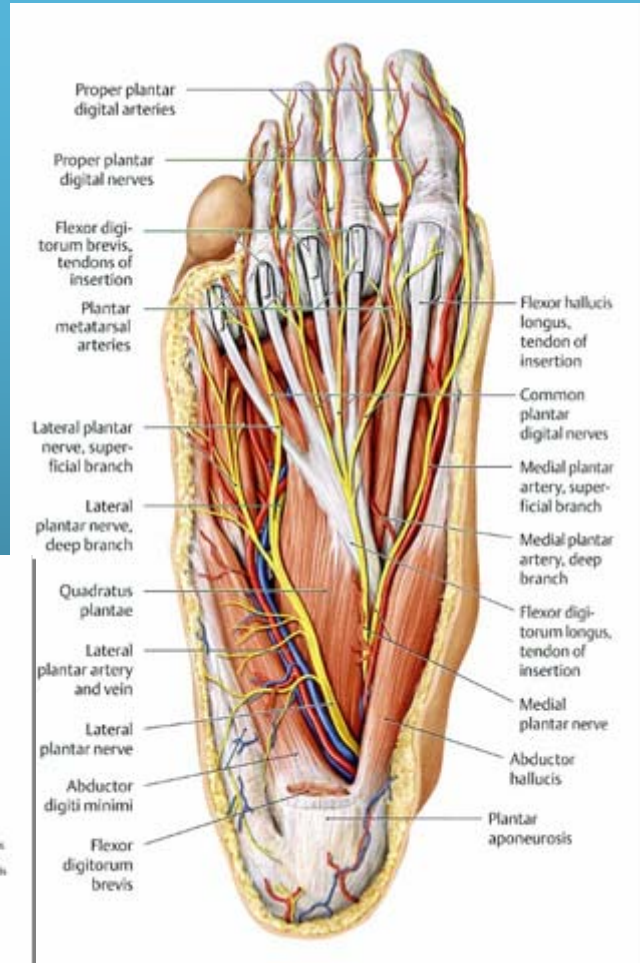
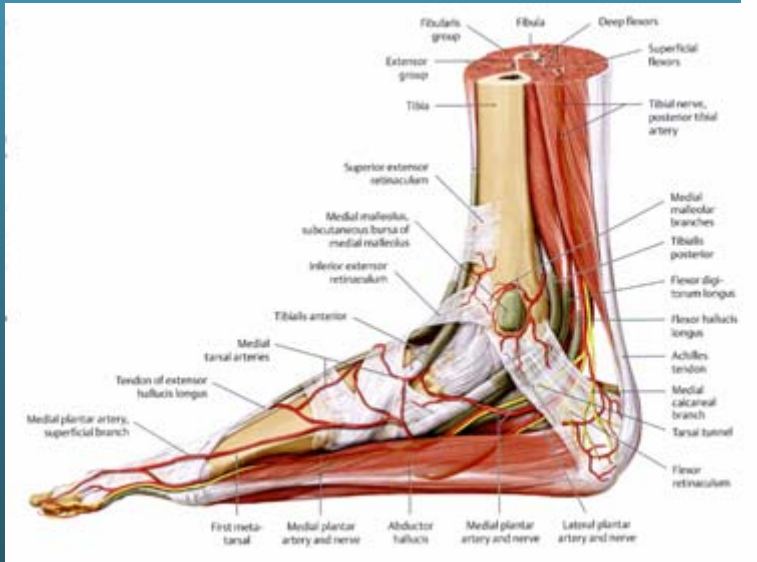
Superficial posterior crural compartment



Deep posterior crural compartment

Plantar surface of the foot

Innervation:
Medial & lateral plantar nerves



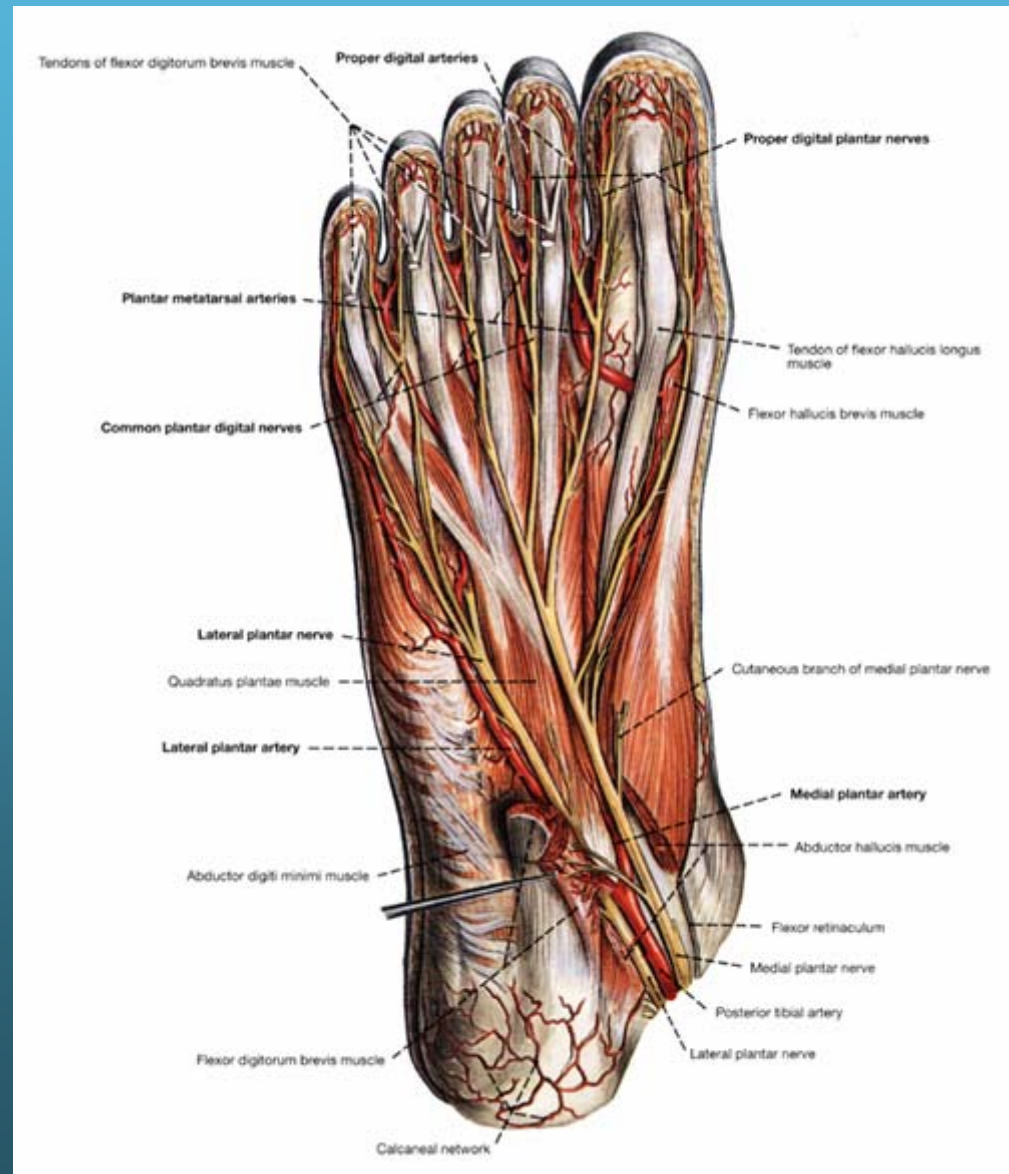
Innervation of intrinsic muscles of the foot

Medial plantar n

- flexor digitorum brevis
- flexor hallucis brevis
- abductor hallucis m
- 1st lumbrical

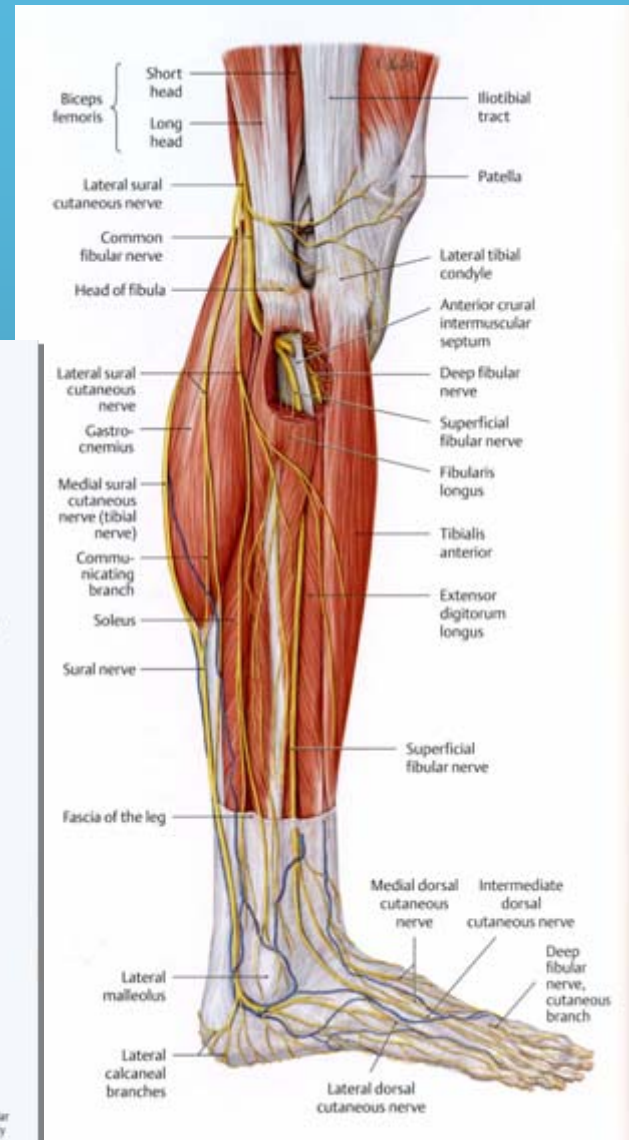
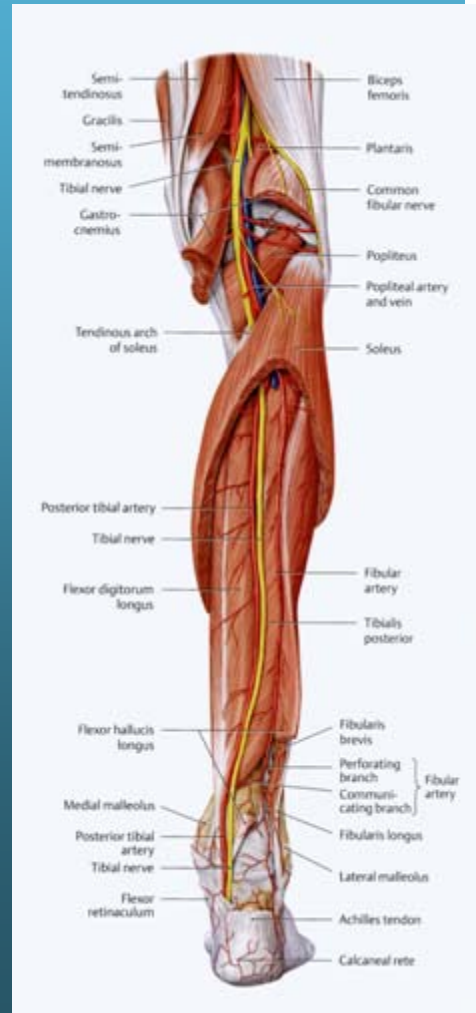
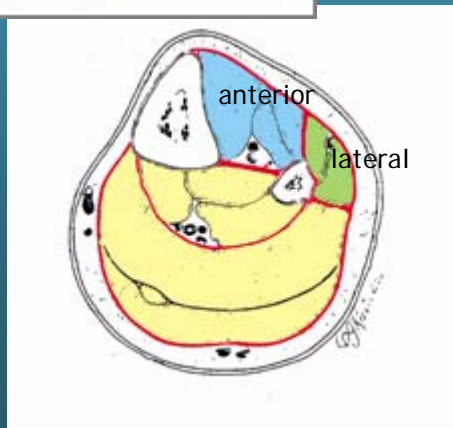
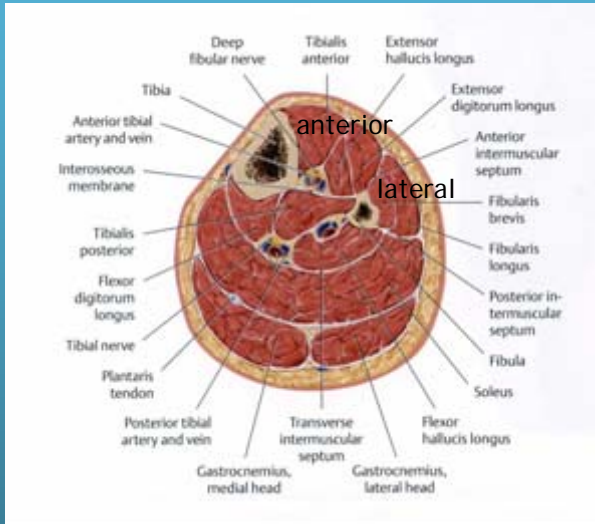
Lateral plantar n

- abductor digiti minimi
- quadratus plantae
- 2nd, 3rd & 4th lumbricals
- adductor hallucis
- Flexor digiti minimi
- dorsal & plantar interossei



Common fibular nerve

Nerve supply to the lateral and anterior crural compartments

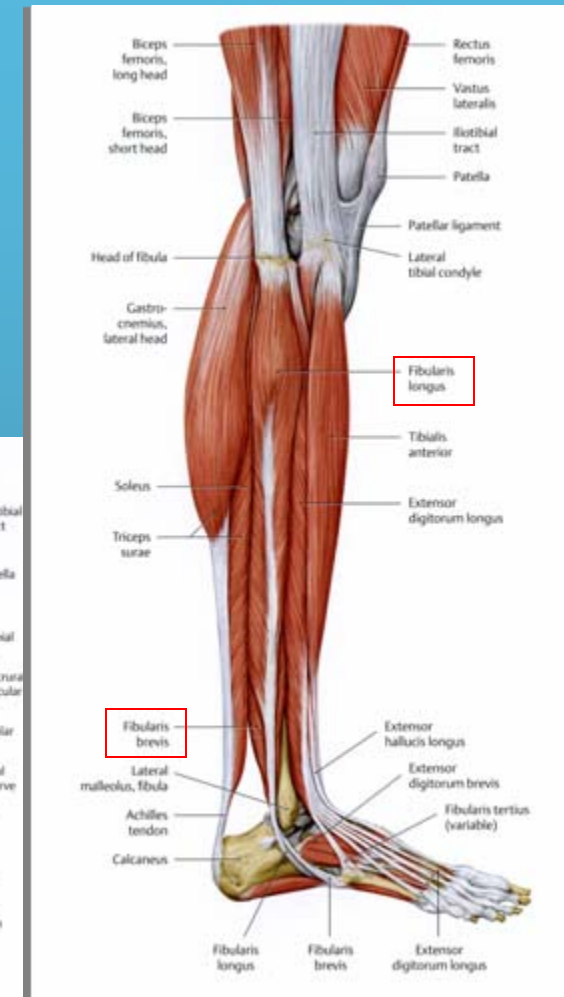
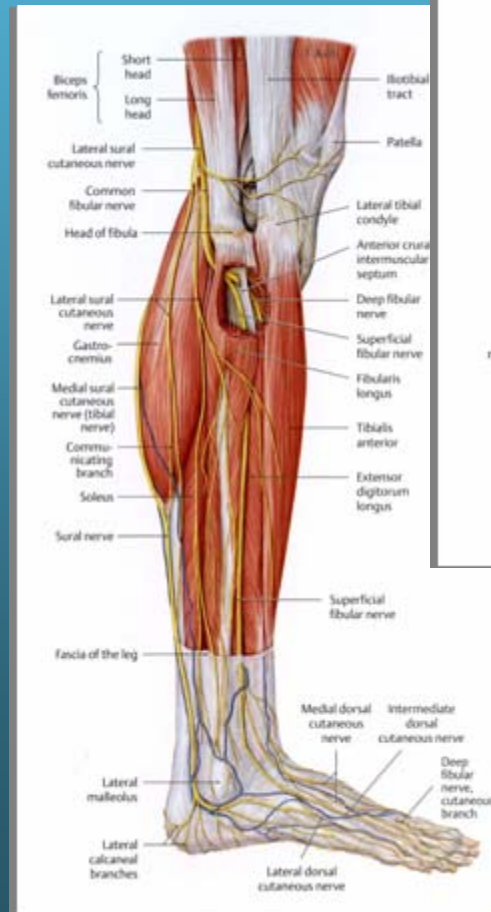
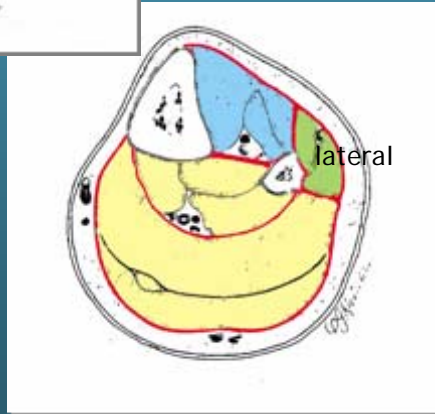
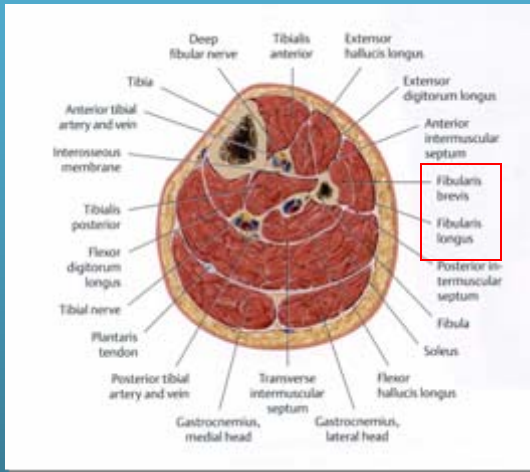


Lateral crural compartment:

Superficial fibular nerve

Fibularis longus

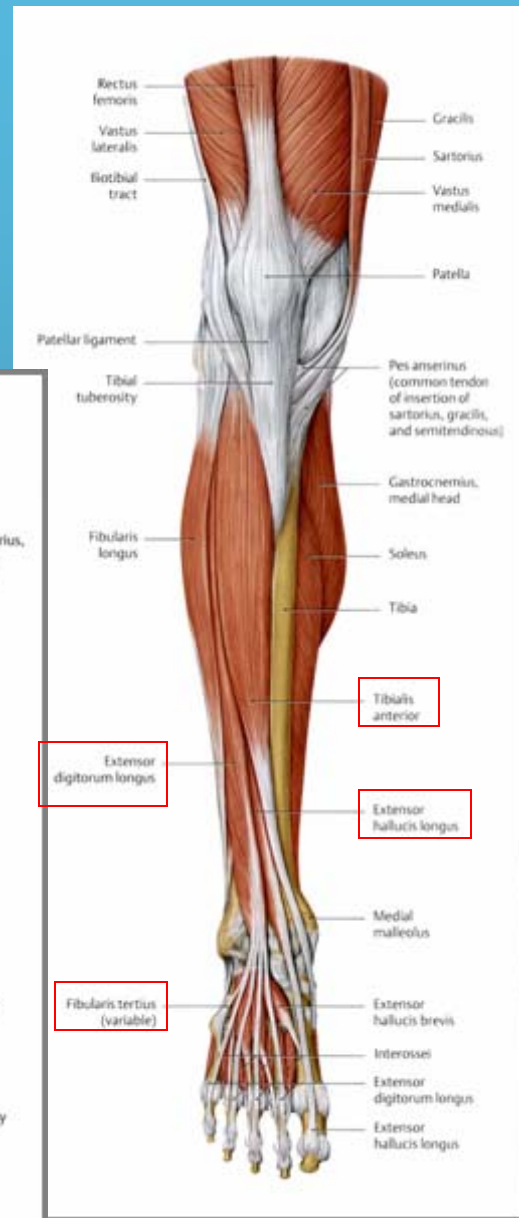
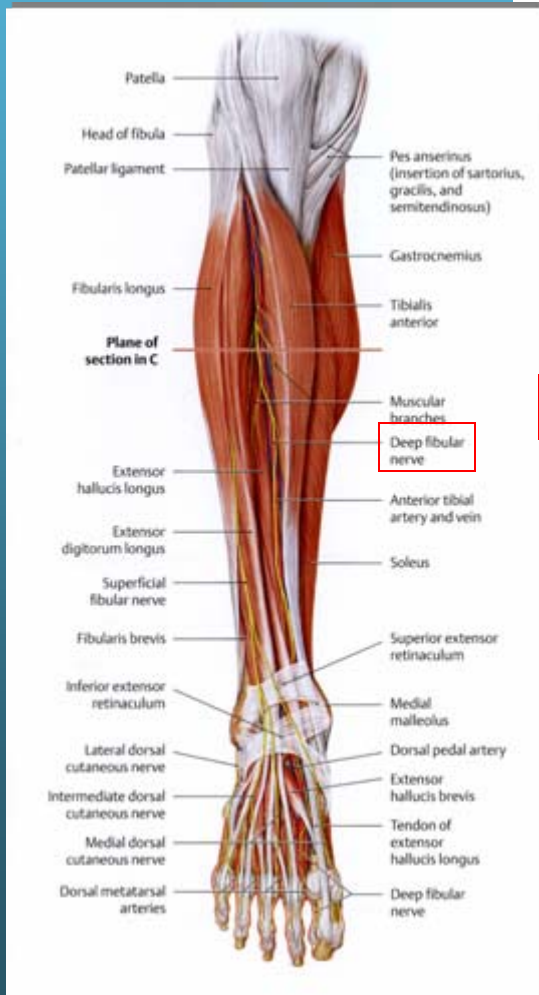
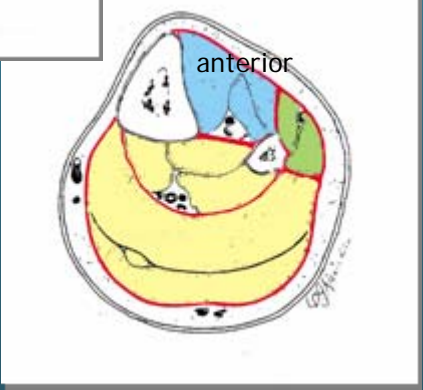
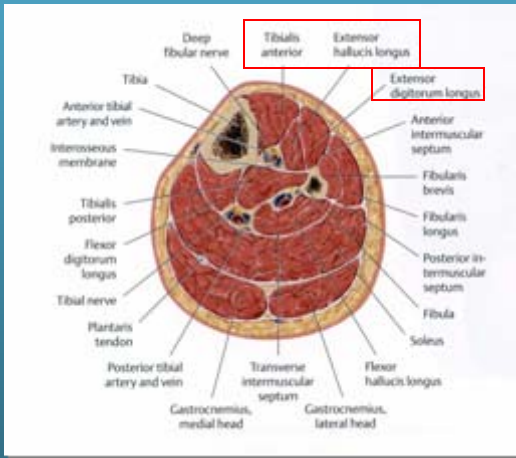
Fibularis brevis



Anterior crural compartment:

Deep fibular nerve

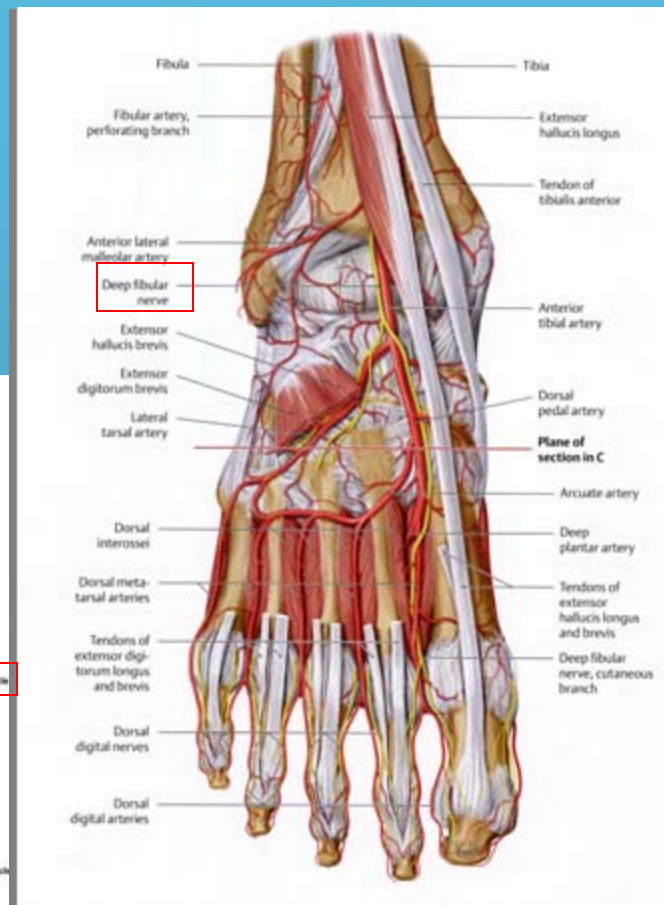
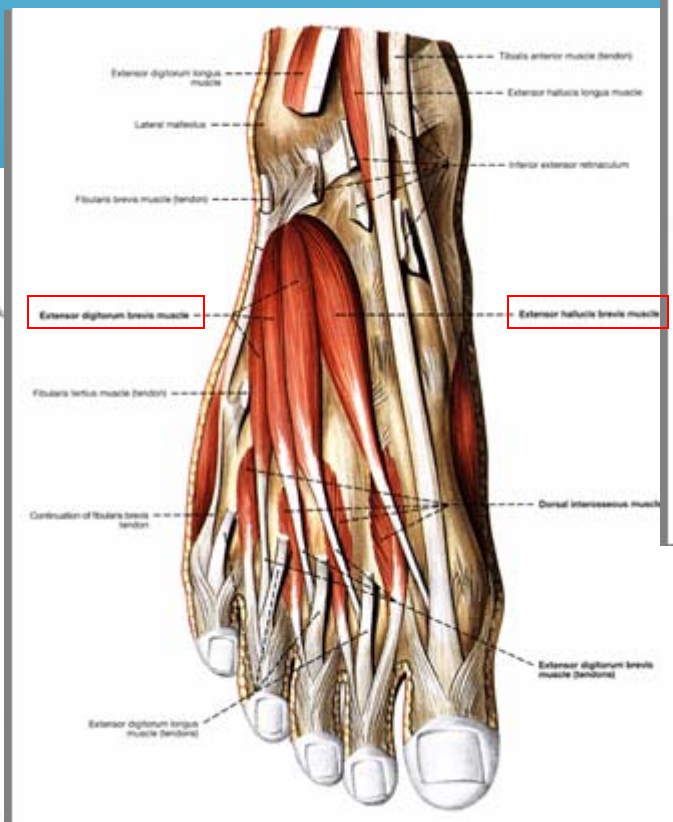
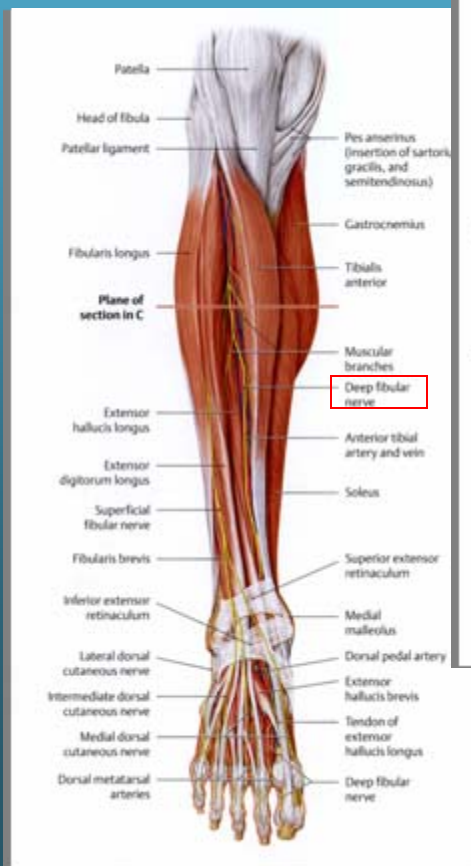
- Tibialis anterior m.
- Extensor hallucis longus m.
- Extensor digitorum longus m.
- Fibularis tertius m.







Dorsum of the foot:

deep fibular nerve

- Extensor hallucis brevis
- Extensor digitorum brevis



Compartmental Innervation of Free Limb

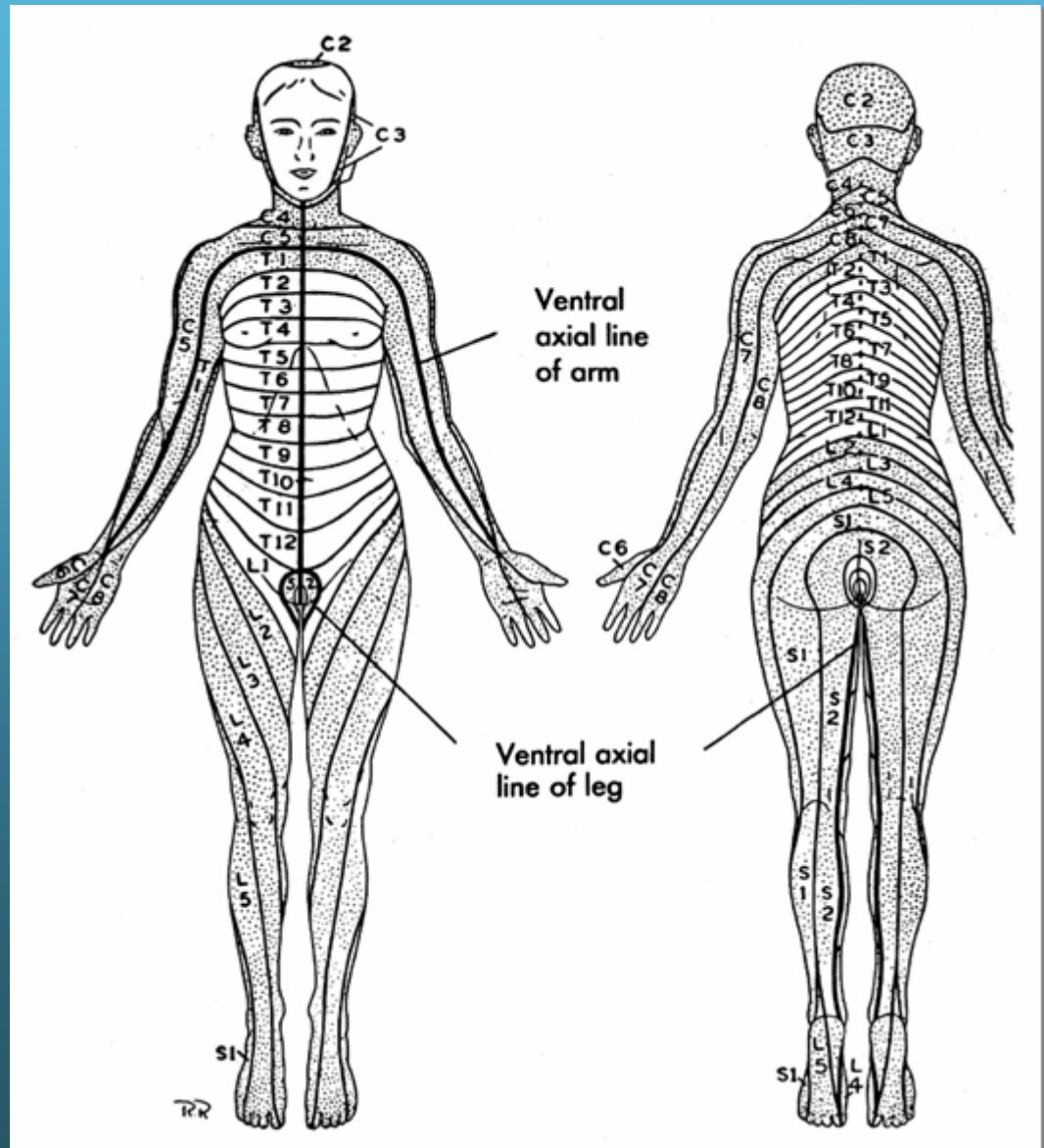
	Anterior compartment	Medial compartment	Posterior compartment	Lateral compartment
Thigh	Femoral n.	Obturator n. adductor magnus - obturator n and tibial n	Tibial division of sciatic n. short head of biceps femoris - common fib. division of sciatic n.	
Leg	Deep fibular n.		Tibial nerve	Superficial fibular n.
Foot	Deep fibular n.		Tibial n. (medial and lateral plantar n.)	

Sensory Innervation of the Lower Limb

Key dermatomes

- ✓ thumb - C6
- ✓ 5th digit of hand - C8
- ✓ nipples - T4
- ✓ umbilicus - T10
- ✓ hip crease - L1
- ✓ great toe - L4
- ✓ 5th toe - S1

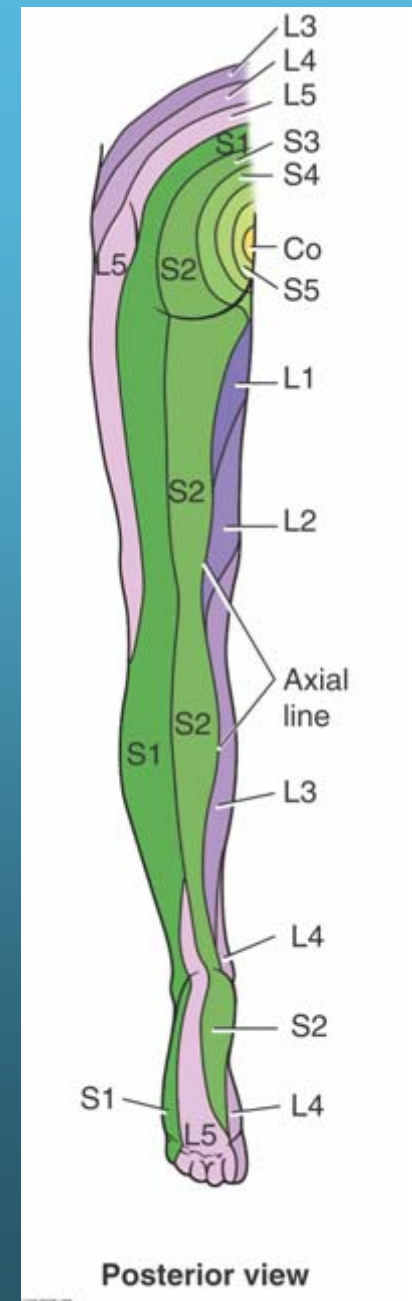
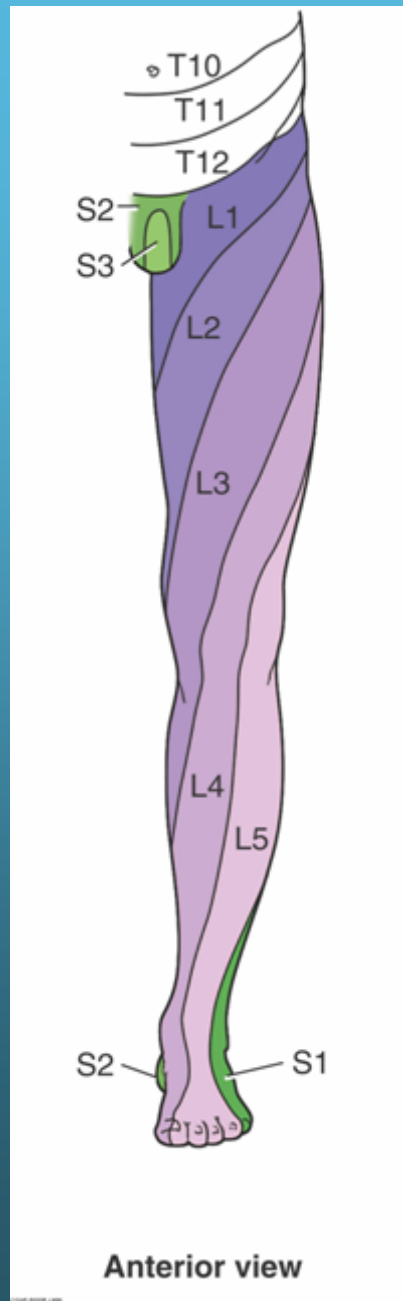
*area of skin supplied by a dorsal nerve root



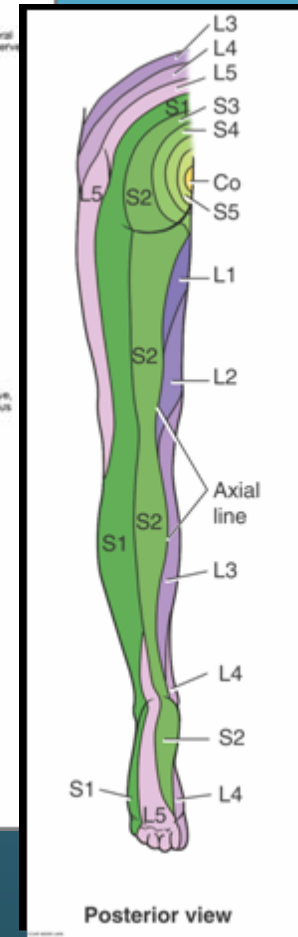
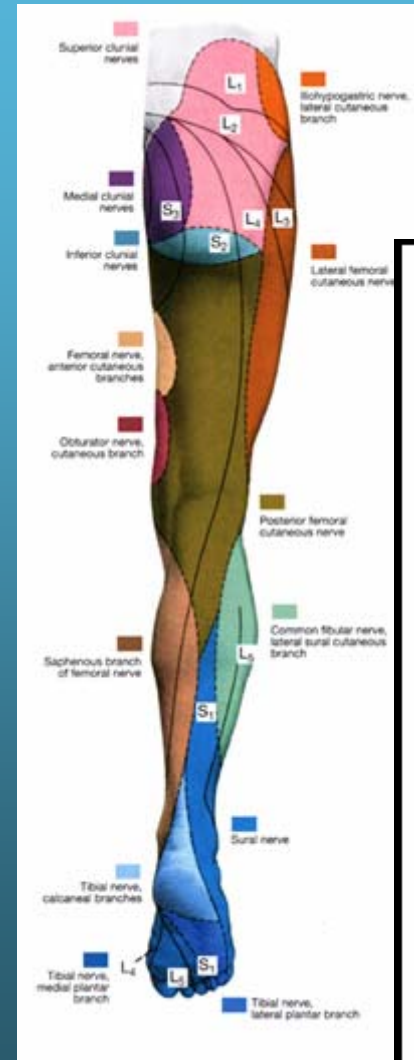
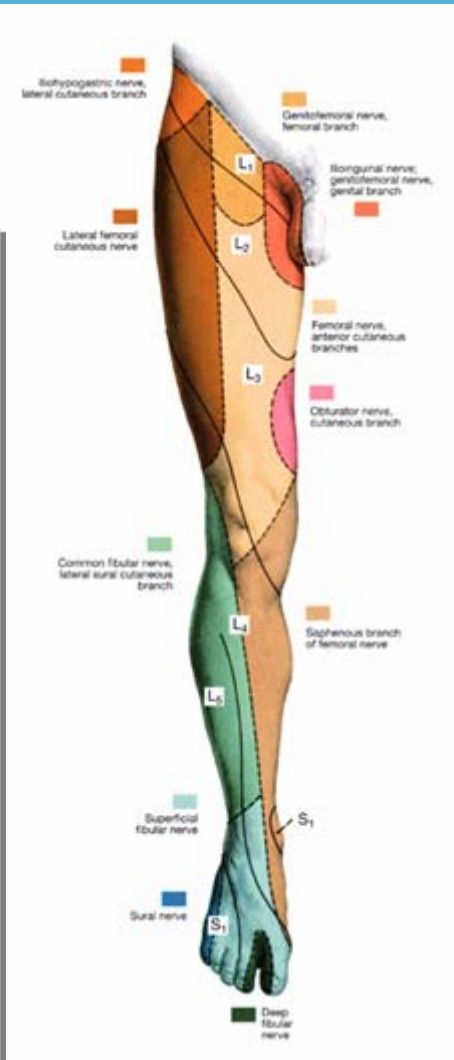
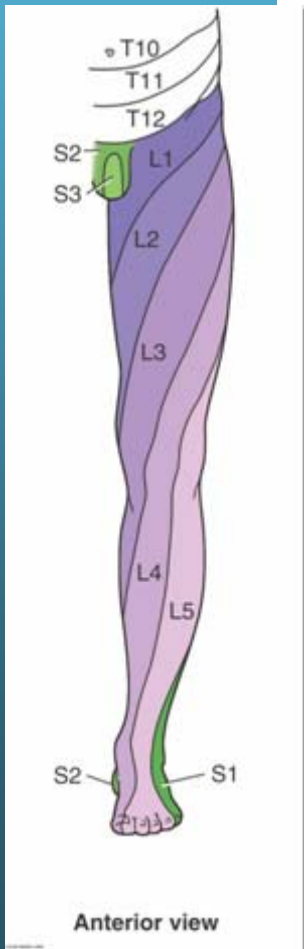
Key dermatomes* of the Lower Limb

- ✓ umbilicus - T10
- ✓ hip crease - L1
- ✓ great toe - L4
- ✓ 5th toe - S1

*area of skin supplied by a dorsal nerve root



Cutaneous Nerve Supply to the Lower Limb



References

- Clemente, C. 1997 Anatomy: A Regional Atlas of the Human Body, 4th edition. Lippincott Williams & Wilkins.
- Rinabesm C,H, 1972. Cunningham's Textbook of Anatomy, 11th edition. Oxford University Press.
- Rosse, C & Gaddum-Rosse, P. 1997. Hollinshead's Textbook of Anatomy 5th edition. Lippincott-Raven
- Schuenke, M et al, 2006 Thieme Atlas of Anatomy: Musculoskeletal System. Thieme.
- S.aby, F., et al. 1994. Gross Anatomy in the Practice of Medicine. Lea & Febiger.