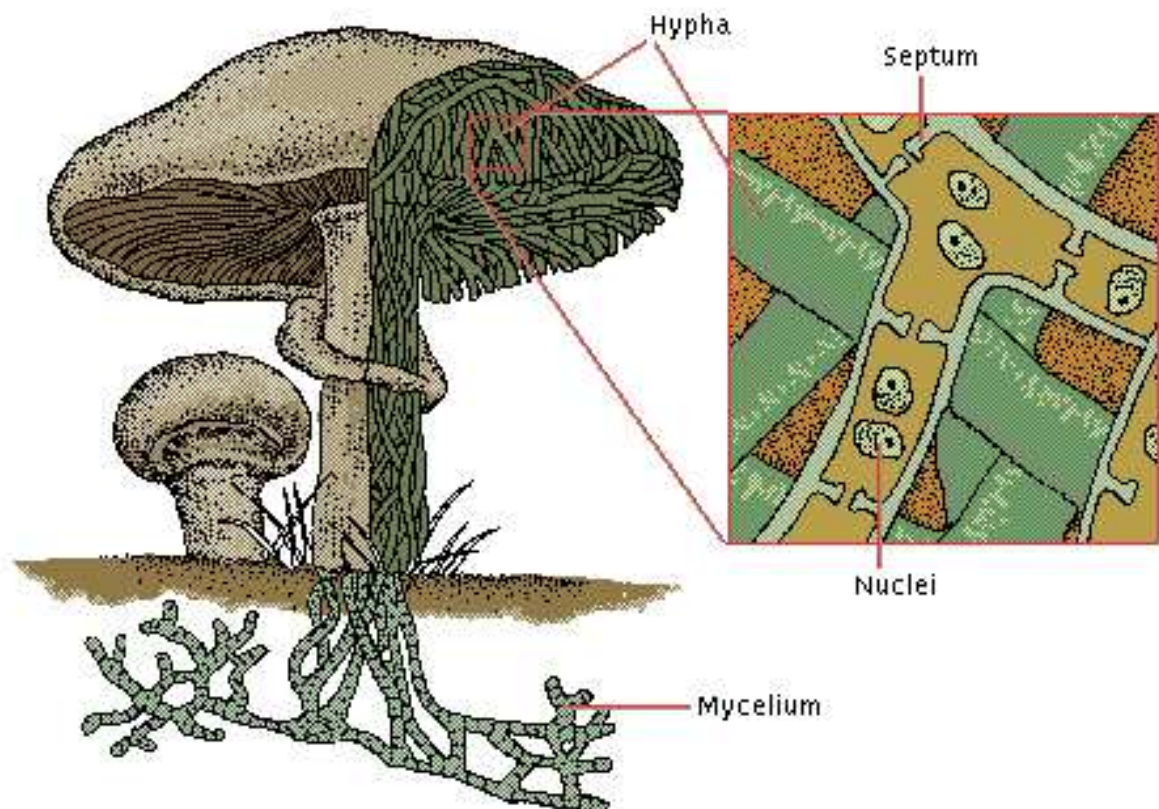


MEDICAL MYCOLOGY

Fungi are eukaryotic protista that differ from bacteria in many ways.

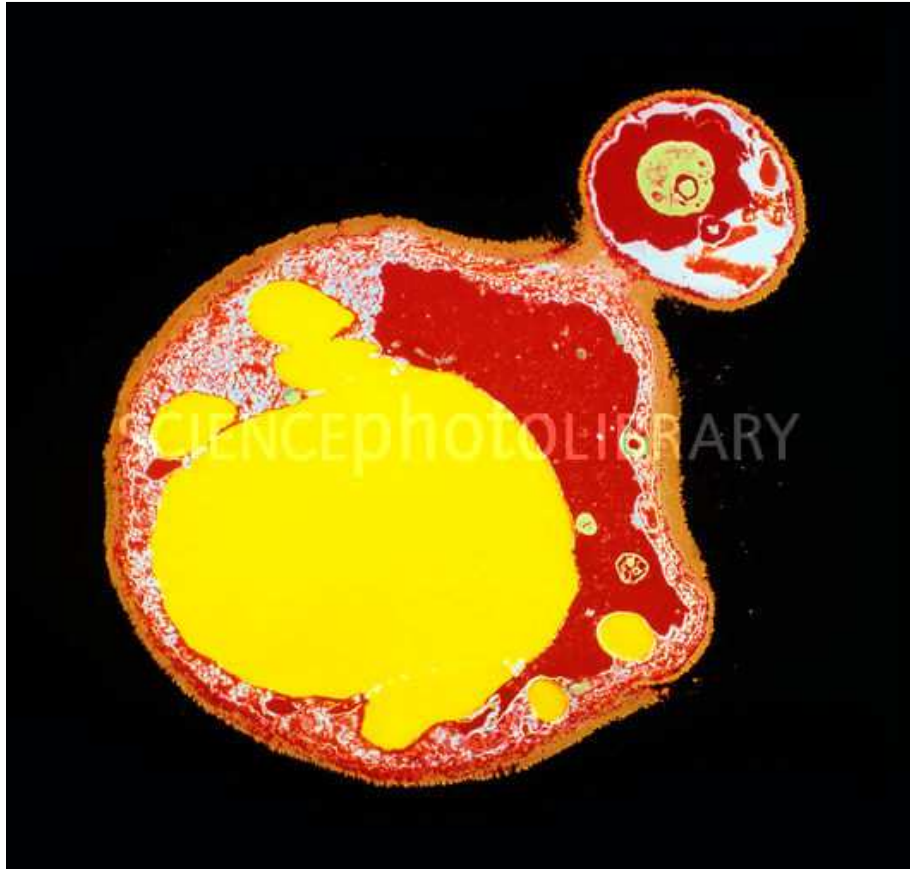Introduction and general structure of fungi:

- Fungi possess **rigid cell walls** containing **chitin, mannan and other polysaccharides**.
- Fungi are **heterotrophic** and cannot make their organic food as plants can, through photosynthesis.
- Fungi are simpler in structure than plants or animals. There is no division of cells into organs or tissues.
- ***The basic structural unit of fungi is either a chain of tubular, filament-like cells (termed a hypha) or an independent single cell.***
- ***In most multicellular fungi the vegetative stage consists of a mass of branching hyphae, termed mycelium.***
- Each individual hypha has a rigid cell wall and increases in length as a result of apical growth.
- ***In the more primitive fungi, the hyphae remain aseptate.***
- ***In the more advanced groups, however, the hyphae are septate* (having holes through which free flow of cytoplasmic material takes place).**



Budding of fungi:

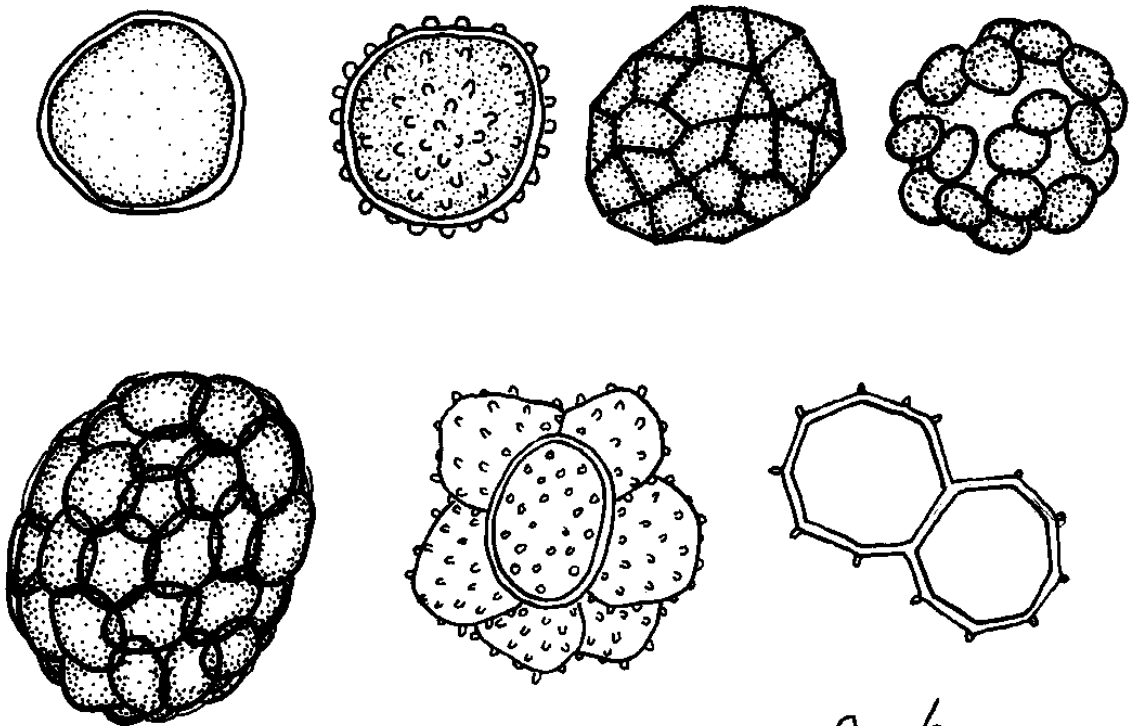
- Many fungi that exist in the form of independent single cells propagate by budding out similar cells from their surface.
- The bud may become detached from the parent cell, or it may remain attached and itself produce another bud. In this way, a chain of cells may be produced.
- Under certain conditions, ***continued elongation of the parent cell before it buds results in a chain of elongated cells, termed a pseudohypha.***



Spores:

- Fungi reproduce by means of microscopic propagules called ***spores***.
- Many fungi produce spores that result from an asexual process. ***Asexual spores*** are generally short-lived propagules that are produced in enormous numbers ***to ensure dispersion to new habitats***.
- Many fungi are also capable of sexual reproduction.
- Some species are ***homothallic***, that is, ***able to form sexual structures within individual colonies***.

- Most, however, are *heterothallic* and **do not form their sexual structures unless two different mating strains come into contact.** Meiosis then leads to the production of the sexual spores.
- In current mycological parlance, the **sexual stage** of a fungus is known as the *teleomorph*, and the **asexual stage** the *anamorph*.

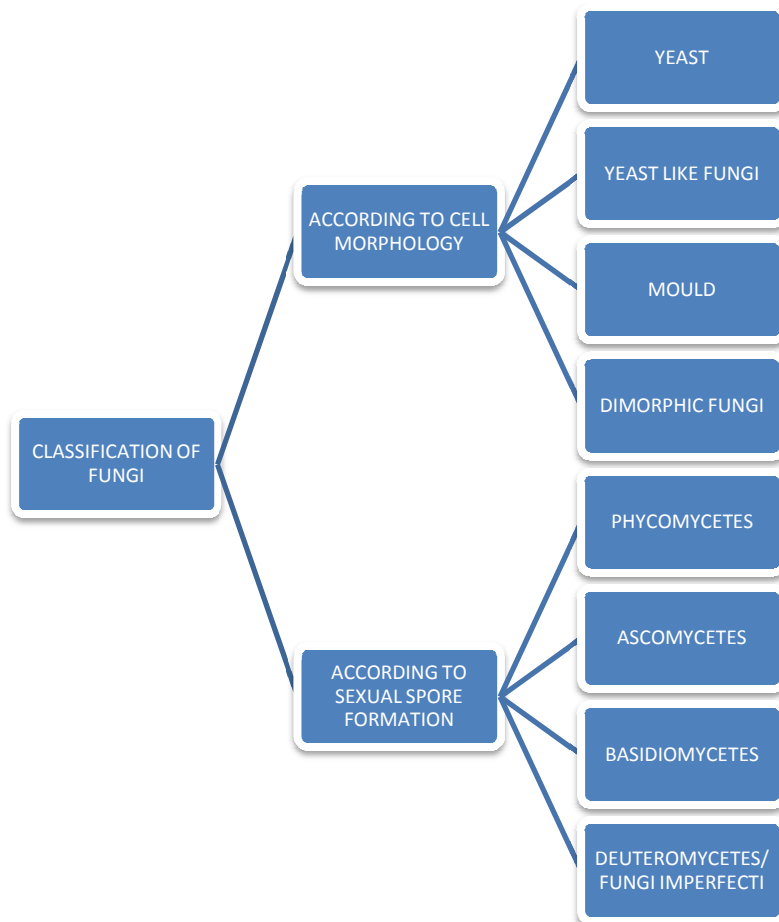


9/9/97

Livingstone © BIODIDAC

Examples of different types of spores

CLASSIFICATION OF FUNGI



According to cell morphology

Yeast: They are unicellular fungi that are spherical in shape and *reproduce by simple budding*.

Ex.- *Cryptococcus neoformans*.

Yeast like fungi: They grow partly as yeast and partly as hyphae.

Ex.- *Candida albicans*.

Moulds: They form true mycelia and *reproduce by forming spores*.

Ex.- *Dermatophytes*.

Dimorphic fungi: In different growth conditions, they grow as yeasts or filaments. In host culture at 37°C they grow as yeasts, whereas in the soil and at 22°C they grow as moulds.

Ex.- Most fungi causing systemic infections.

According to sexual spore formation

Phycomycetes:

- They are lower class of fungi having ***nonseptate hyphae***.
- They form endogenous ***asexual spores***, called ***sporangiospores***, which contain ***swollen sac*** like structure called ***sporangium***.
- They also produce ***sexual spores*** called ***oospores/ zygospores***.



Sporangium of phycomycetes

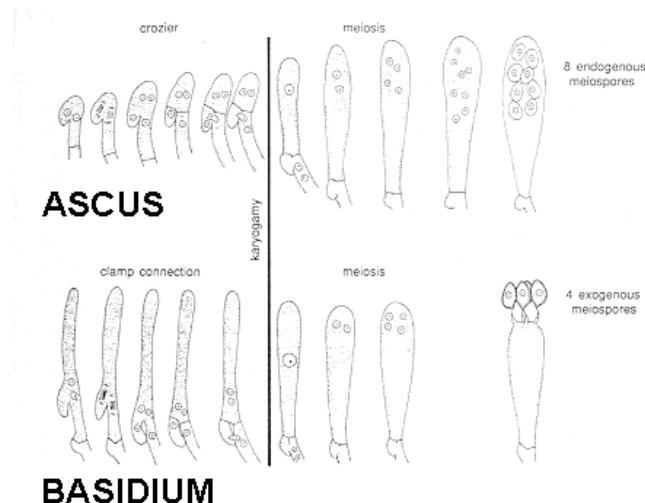
The other 3 classes are higher fungi and they contain ***septate hyphae*** and form ***exogenous asexual spores*** called "***conidia***".

Ascomycetes:

- They contain sexual spores called "***ascospores***" within a sac or ascus.

Basidiomycetes:

- They contain sexual spores called "***basidiospores***" on a basidium/ base.



Deuteromycetes/ Fungi imperfecti:

- It is a provisional group consisting of fungi **whose sexual phases have not been identified.**
- Most fungi of medical importance belong to this group.

GENERAL LABORATORY DIAGNOSIS OF FUNGAL INFECTIONS

It has two parts:

1. Analysis of morphology of the fungus,
2. Analysis of the fungal colony.

Analysis of morphology of the fungus

- At first sample is taken from lesions.
- At first the tissue specimens (**Ex.: skin scrapings**) are treated with 10% KOH. **The purpose being that the alkali digests the cells and other tissue materials, enabling the fungus elements to be seen clearly.**
- Then the KOH treated preparations are seen under microscope with stains like:
 1. **PAS** stain,
 2. **Methanamine silver** stain.
- Then the morphology of the fungus is observed.

Analysis of the fungal colony

- **The commonest culture media used in mycology is Sabourud's glucose agar (pH 5.4).**
- The addition of antibiotics prevents (**cycloheximide**) bacterial contamination and also contamination by various moulds.
- Cultures are routinely incubated at room temperature (22°C) for weeks and at 37°C for days.
- The following colony characteristics are studied:
 1. Rapidity of growth,
 2. Colour,
 3. Morphology and,
 4. Pigmentation of the colony.
- The study of following features are also of diagnostic importance:
 1. Morphology of hyphae,
 2. Spores,

3. Diameter of hyphae,
4. Presence or absence of septa and special structures: They include:
 - a. Spring like helical coils- **Spiral hyphae,**
 - b. Localized swellings by tightly twisted hyphae resembling tennis racquets- **Racquet hyphae.**
 - c. Numerous short branches at the ends of hyphae- **Favic chandelier.**
5. Morphology of asexual spores (conidia): **Microconidia/ macroconidia.**

*****Note: Biochemical and serological tests are rarely employed in mycology.**

FUNGAL INFECTIONS (MYCOSES)

It is usually of 3 types:

1. **Superficial mycoses:**
 - It is more common.
 - Caused by **tinea** and **ringworms** affecting the skin, hair and nails.
 - They have a **specialized capability of digesting keratin.**
 - These are **mild** and **chronic** diseases.
2. **Deep mycoses:**
 - It is less common.
 - Mainly caused by **soil saprophytes.**
 - The disease ranges from **asymptomatic** to **fatal diseases.**
3. **Opportunistic infections:**
 - It occurs in debilitating patients like AIDS/ cancer/ diabetes/ immunocompromized person.
 - It is mainly caused by **avirulent fungus** like Penicillium, Aspergillus, Mucor etc.

SUPERFICIAL MYCOSES

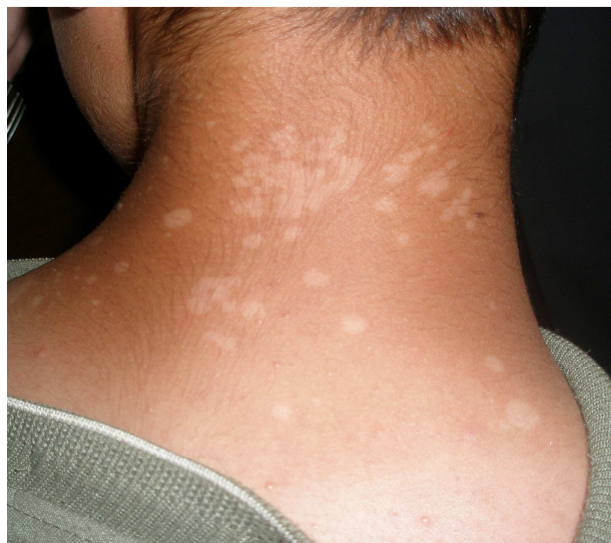- It is of 2 types:
 1. Surface infections and,
 2. Cutaneous infections.

SUEFACE INFECTIONS

- The fungi causing surface infections **live on the dead layers of the skin and its appendages.**
- **They have no contact with the tissue and hence, do not elicit an inflammatory reaction.**
- The only changes produced are **cosmetic effects.**
- **Example:**
 1. Tinea versicolor
 2. Tinea nigra
 3. Piedra

Tinea Versicolor

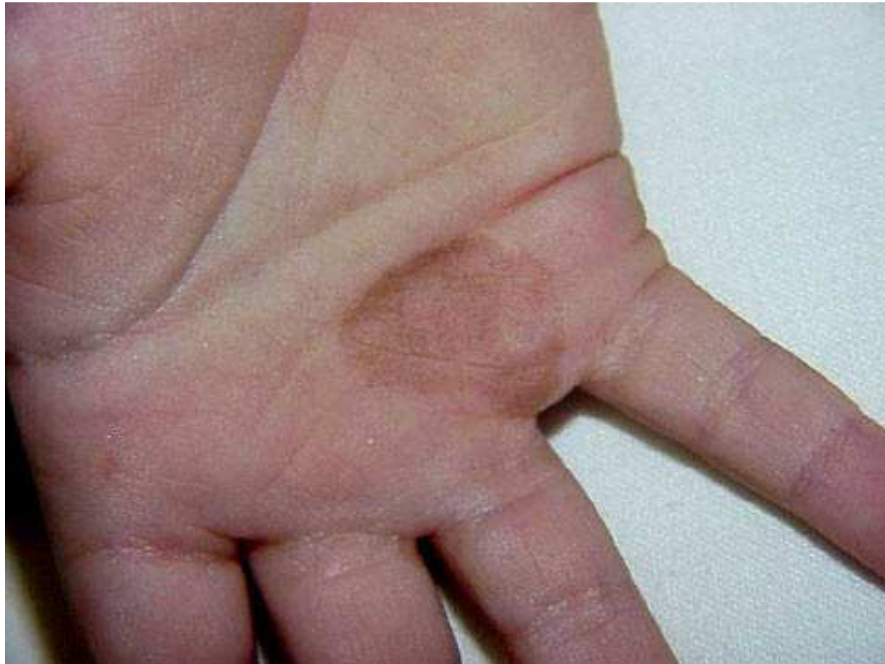- The causative organism is *Pityrosporum orbiculare*.
- It is a chronic and asymptomatic infection.
- It occurs mainly in **young adults.**
- There is involvement of stratum corneum.
- **The infection is characterized by discrete/ confluent macular areas of discoloration and depigmentation of the skin.**
- Examination of skin scrapings shows **yeast like cells with short, branched filaments.**



Infection by Tinea versicolor

Tinea Nigra

- The causative organism is *Clado-sporium wernickii*.
- It is also a localized infection involving stratum corneum.
- It appears mainly on **palms**.
- **It is characterized by black/ brown macular lesions.**
- Examination of skin scrapings shows **brownish, branched, septate hyphae and budding cells.**
- Colonies are **grey/ black.**



Piedra

- The causative organism is *Piedraia hortae* (causing black piedra) and *Tricho-sporon beiglii* (White piedra).
- It is a fungal infection of **hair**.
- **It is characterized by firm, irregular nodules along the hair shaft; the nodules are composed of fungus elements cemented together on the hair.**



Hair infection by piedra

CUTANEOUS INFECTIONS

- The most common of this group is ***Dermatophytoses***, where infection is generally confined to the **cornified layer of the skin and its appendages** and elicits various types of inflammatory and allergic reactions due to the fungus itself or its metabolic products.
- Another type of infection is caused by *Candida*, called ***Candidiasis***, which is a bridge between superficial and deep mycoses. It is generally confined to the **skin and mucosa and may cause systemic disease involving any organ of the body.**

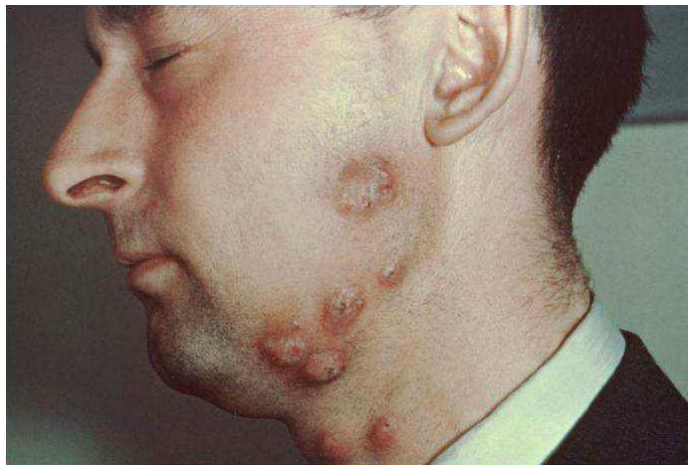
DERMATOPHYTOSES

Causative organisms:

- It is caused by a group of organism called dermatophytes/ ringworm.
- They are closely related to the group of **filamentous fungi**.
- They infect only **superficial keratinized tissues: skin, hair and nails.**
- Dermatophytes have been classified into 3 genera:
 1. ***Trichophyton***,
 2. ***Microsporum***,
 3. ***Epidemophyton***.

Cultural characteristics:

- In lesion, dermatophytes appear as **hyphae** and **arthrospores**.
- In cultures on Sabouraud's agar, they form characteristic colonies consisting of **septate hyphae and 2 types of asexual spores: microconidia and macroconidia.**
- Differentiation into these 3 genera is based on **the nature of macroconidia.**



Infection by dermatophytes

Morphology of different species

Features	Trichophyton	Microsporum	Epidermophyton
Colonies	Powdery/ velvety/ waxy with pigmentation characteristic of different species.	Cotton like/ velvety/ powdery; white to brown pigmentation.	Powdery, with greenish yellow pigmentation.
Microconidia	Scanty in number, generally elongated, with blunt ends.	Scanty in number, not distinctive.	Absent.
Macroconidia	They have distinctive shape in different species and thus help in species differentiation. <i>T.rubrum</i> is the most common species infecting human.	<ul style="list-style-type: none"> • It is the predominant spore form. • They are: <ul style="list-style-type: none"> ✓ <i>large,</i> ✓ <i>multicellular,</i> ✓ <i>spindle shaped;</i> ✓ <i>born singly at the end of hyphae.</i> 	They are: <ul style="list-style-type: none"> ✓ <i>large,</i> ✓ <i>multicellular,</i> ✓ <i>pear shaped,</i> ✓ <i>typically arranged in clusters.</i>
Infects this body part:	Skin, hair and nails.	Skin and hair, not nails.	Skin and nail, not hair.

PATHOGENECITY

- ***Dermatophytes grow only on the keratinized layers of the skin and its appendages and do not usually penetrate living tissues.***
- The mechanism of pathogenicity is not clear.
- But it is thought that the ***fungal products are responsible for eliciting a local inflammatory response.***
- Hypersensitivity reactions results in ***sterile vesicular lesions*** called '***dermatophytids***'. This reaction may be demonstrated by using fungus antigen, ***trichophytin***.

CLINICAL FEATURES

- Clinically, dermatophytes can be classified according to the site of infection. Example:

Species	Site of infection
Tinea corporis	Smooth/ non hairy skin of the body.
Tinea imbricata	Extensive concentric rings of papulosquamous scaly patches.
Tinea cruris	Involvement of groin and perineum.
Tinea barbae	Barbae's itch in bearded areas of face and neck.
Tinea pedis	Athlete's foot
Tinea capitis	Involvement of scalp
Flavus	It is a chronic type of ringworm infection in which <i>dense crusts develop in the hair follicles</i> and leads to <i>alopecia and scarring.</i>

LABORATORY DIAGNOSIS OF DERMATOPHYTOSES

- The routine method of diagnosis is by examination of KOH treated specimens.
- Scrapings are taken from the **edge of ringworm lesions.**
- Selection of infected hair is facilitated by **exposure to UV light. (Wood's lamp)**
- Then the specimen is mixed with 10% KOH on a slide.
- Then after placing a cover slip, the preparation is gently heated to bring about 'clearing'.
- Then the preparation is examined under microscope.
- Microscopy reveals ***branched septate hyphae.*** It also reveals two types of hair infection:
 1. **Ectothrix:** Spores are seen as a sheath surrounding the hair.
 2. **Endothrix:** Spores are seen inside the hair shaft.
- Species identification is possible only after culture. Specimens are inoculated into Sabouraud's agar with antibiotics and cycloheximide and incubated at room temperature. Growth occurs slowly and colonies appear after 1-3 weeks.

Treatment

Topical antifungal agents are effective. And in case of resistant T.rubrum infection, oral Griseofulvin is the drug of choice.

CANDIDOSIS

Infecting agent: Candida albicans, occasionally by other candida species. They are commensals of skin and mucosa.

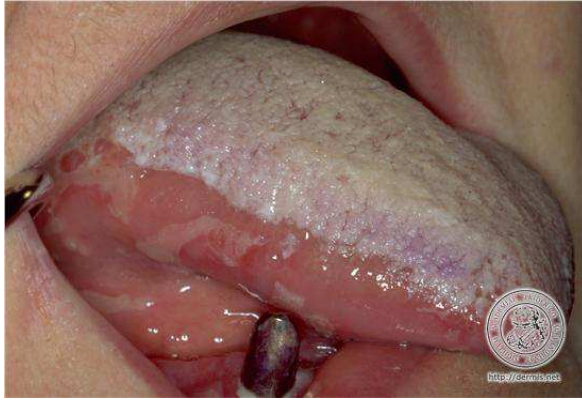Site of infection: Skin, mucous membrane, rarely systemic infections.

Morphology: C.albicans is an ovoid/ spherical budding cell, which produces **pseudomycelium in both culture and tissues.**

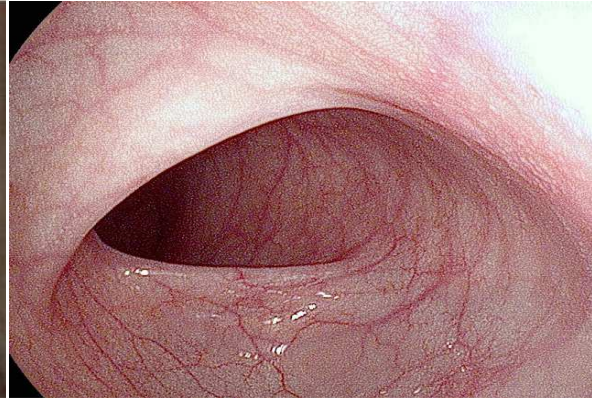
Clinical features:

1. Candidosis is an opportunistic infection.
2. The commonest predisposing condition is **diabetes.**
3. Pictures of various types of Candidosis:

Type	Clinical features
Cutaneous Candidosis (They are of 2 types: Intertriginous and paronychial)	Intertriginous type: <ul style="list-style-type: none"> Erythematous scaling/ moist lesion with sharply demarcated borders. Papular lesions are most prominent.
	Paronychial type: They are seen in occupations where there is frequent immersion of hands in water.
	Sites commonly affected: Where skin is macerated due to perspiration: groin, perineum, axillae, inframammary folds.
Vaginitis Oral thrush	Characterized by an acidic discharge and found frequently in pregnancy. <ul style="list-style-type: none"> Commonly found in bottle fed infants/ ages persons. Creamy white patches appear on tongue/ buccal mucosa that have a red oozing surface on removal.
Intestinal candidosis	<ul style="list-style-type: none"> It is a frequent sequel to oral antibiotic therapy. It may present as diarrhoea not responding to treatment.
Systemic candidosis	<ul style="list-style-type: none"> Septicaemia Meningitis Endocarditis-----→ Leukaemia in immunocompromised persons.
Candida granuloma and chronic mucocutaneous candidosis	<ul style="list-style-type: none"> Serious manifestations in immunodeficient persons.
Broncho-pulmonary	Rare complication of systemic Candidosis.



Candidosis of mouth



Intestinal candidosis

LABORATORY DIAGNOSIS OF CANDIDOSIS

Routine procedure of diagnosis:

Diagnosis is established by microscopy and culture.

Microscopy:

- As candida is normally seen on skin/ mucosa, **only its abundant presence is of significance.**
- ***Demonstration of mycelia forms indicates colonisation and tissue invasion and thus is of great significance.***

Colony characteristics:

- As done routinely, colonies appear ***creamy white, smooth and with a yeasty odour*** in Sabouraud's agar and also in ordinary bacteriological culture medium.
- *C.albicans* forms ***chlamydospores*** on **Corn meal agar** culture at 20°C.

Biochemical tests:

Candida albicans can be identified from other candida species by ***growth characteristics and sugar fermentation tests.***

Rapid diagnosis:

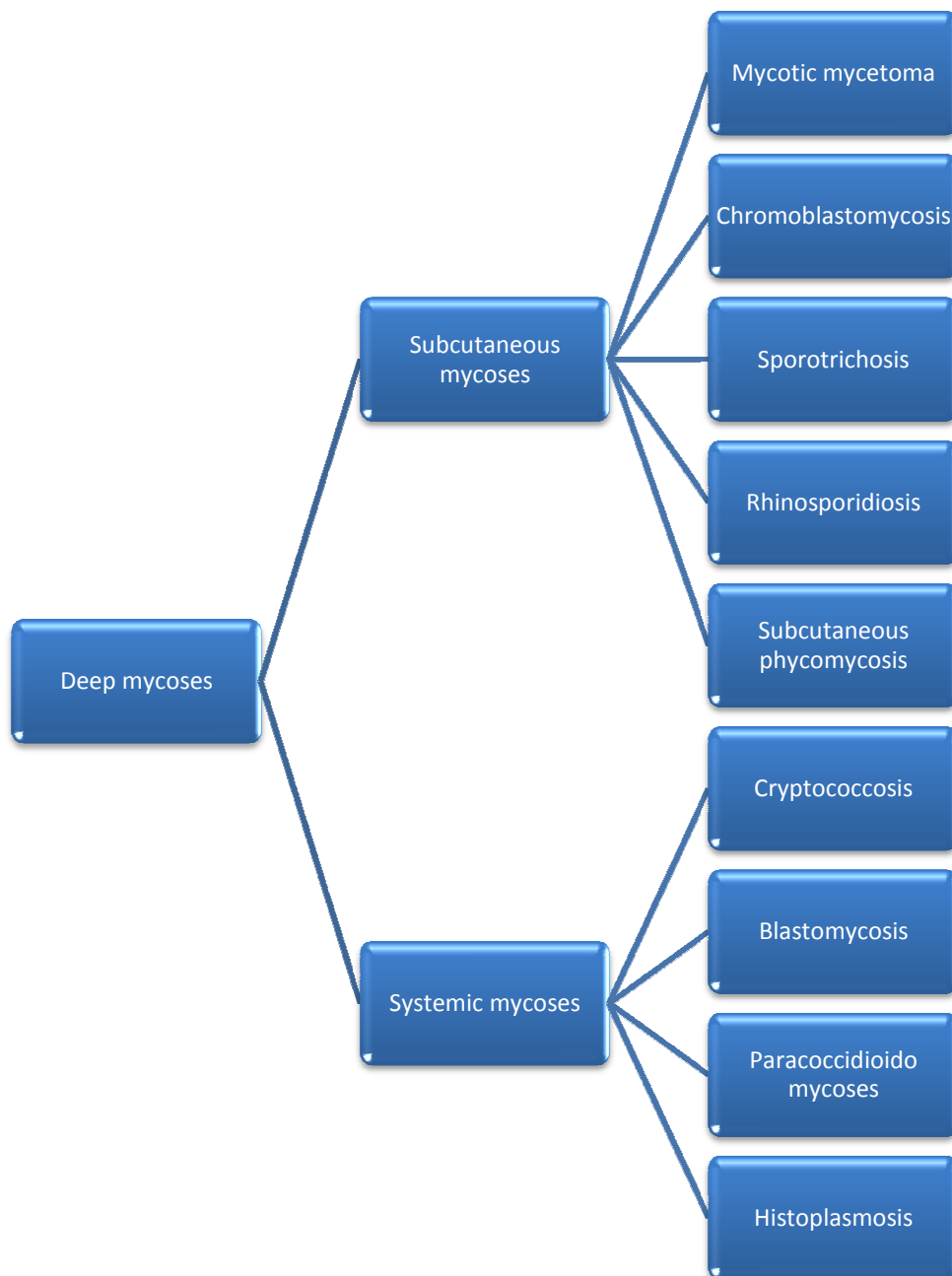
A rapid method of diagnosis is based on **the ability of *C.albicans* to form germ tubes** within 2 hours of incubation in **human serum** at 37°C. It is called ***Reynolds-Braude Phenomenon.***

Other tests:

- Agglutination appears in the sera of patients as well as in normal persons also, thus of no role in diagnosis of candidosis.

- Delayed hypersensitivity to candida is universal (that skin testing with candida extracts is used as a tool of determining functional integrity of cell mediated immunity), so can't be used as a tool of diagnosis of candidosis.

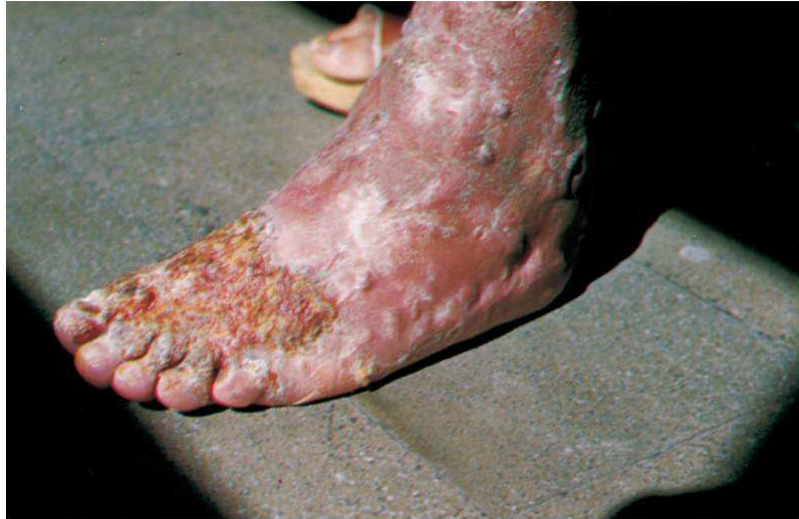DEEP MYCOSES



Mycotic mycetoma

Mycetomas are chronic and slowly progressing infections of the subcutaneous tissue of usually foot.

Copyright © The McGraw-Hill Companies, Inc. Permission required for reproduction or display.



Causative agents:

- A number of actinomycetes and,
- Filamentous fungi.

It should be noted that a similar type of infection occurs with *Staph.aureus*, so it is important to differentiate between these two to initiate the treatment.

Pathogenesis:

- The causative agent enters through **minor trauma**.
- Then the disease begins as a **small subcutaneous swelling of the foot**, which gradually enlarges and invades the **deeper tissue**.
- Then it finally tracks to the surface as **multiple sinuses discharging viscid, seropurulent fluid containing granules**.
- **These granules/ grains are actually microcolonies of the causative agents and their demonstration is of diagnostic value.**

Species differentiation:

The colour of these granules varies with different species causing it:

Colour	Organism
White to yellow	Nocardia asteroides Nocardia brasiliensis Actinomadura madurae Streptomyces somaliensis
Brown to black	Madurella mycetomi Madurella grisea Phialophora jeanselmei
Red	Actinomadura peletierii

CHROMOMYCOSIS

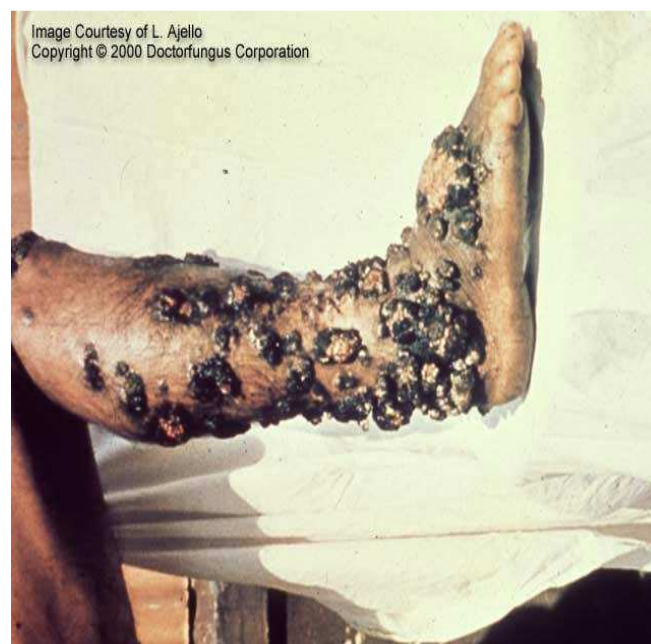This group of disease is caused by some pigmented fungi.

CHROMOBLASTOMYCOSIS:

- It is the most common type of chromomycosis.
- This disease commonly occurs among bare foot agricultural workers and woodcutters.
- It is caused by the following fungi:

Family: Dermatiaceae.

1. **Fonsecaea species:** F.pedrosoi, F.compactum, F.dermatitidis.
2. **Phialophora species:** P.verrucosa
3. **Cladosporium species:** C.carrionii



Chromoblastomycosis due to Fonsecaea

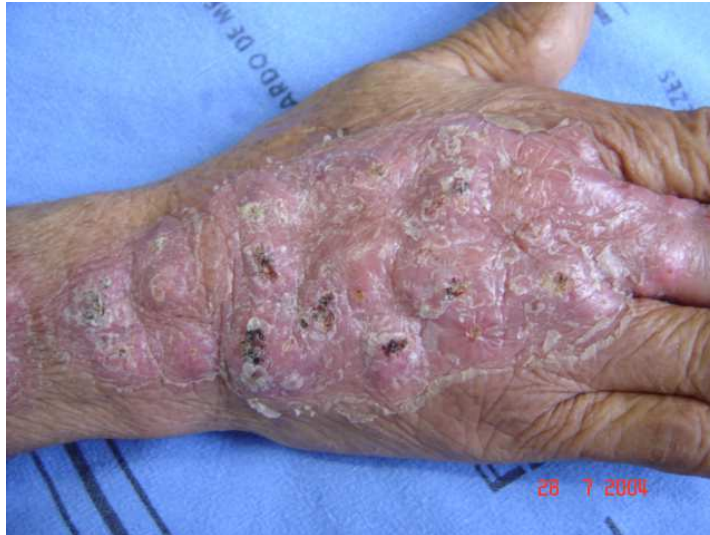- **Pathogenesis:**
 - ❖ The causative agents are soil inhabiting fungi.
 - ❖ They enter the skin by traumatic implantation of usually **feet and lower legs**.
 - ❖ Then the lesion develops slowly around the site of implantation.
 - ❖ These lesions consist of **cutaneous nodules** which resemble as florets of cauliflower.
 - ❖ Histologically, these lesions show the **presence of fungus** as round/ irregular **dark brown yeast like bodies with septae**, called **"sclerotic bodies"**.
- **Diagnosis:**
Diagnosis is done by **demonstration of these sclerotic bodies** in KOH treated specimen/ culture on Sabouraud's agar.

***Other infections caused by family Dermatiaceae:

1. Brain abscess: *Cladosporium bantianum*
2. Subcutaneous/intramuscular lesions with abscesses/cysts: *Phialopspora*.

SPORITRICHOSIS

Points	Description
Caused by:	<i>Sporotrichum schenckii</i> . It is a dimorphic fungi.
Characterized by:	Development of nodules which soften and breaks down to form indolent ulcers.
Location of nodules:	Skin, subcutaneous tissue, lymph nodes of upper limbs .
Pathogenesis:	<ul style="list-style-type: none"> • The fungus is a saprophyte found widely on plants. • They enter the body by thorn pricks/ minor injuries. • Then they spread from the primary site through lymphatics. • Then the characteristic nodules appear.
Morphology of fungus	In infected tissues, the fungus is seen as cigar shapes yeast cells without mycelium . Sometimes, asteroid bodies are seen as a central fungus cell with eosinophilic material around it.
Diagnosis	<ul style="list-style-type: none"> • Diagnosis is made by culture as the fungus is frequently not demonstrable in pus. • <i>Sporotrichum schenckii</i> is a dimorphic fungi, which appears as yeast phase in host tissues/ culture at 37°C and as mycelia phase in soil/ culture at 22°C.



Sporitrichosis of hand

CRYPTOCOCCOSIS

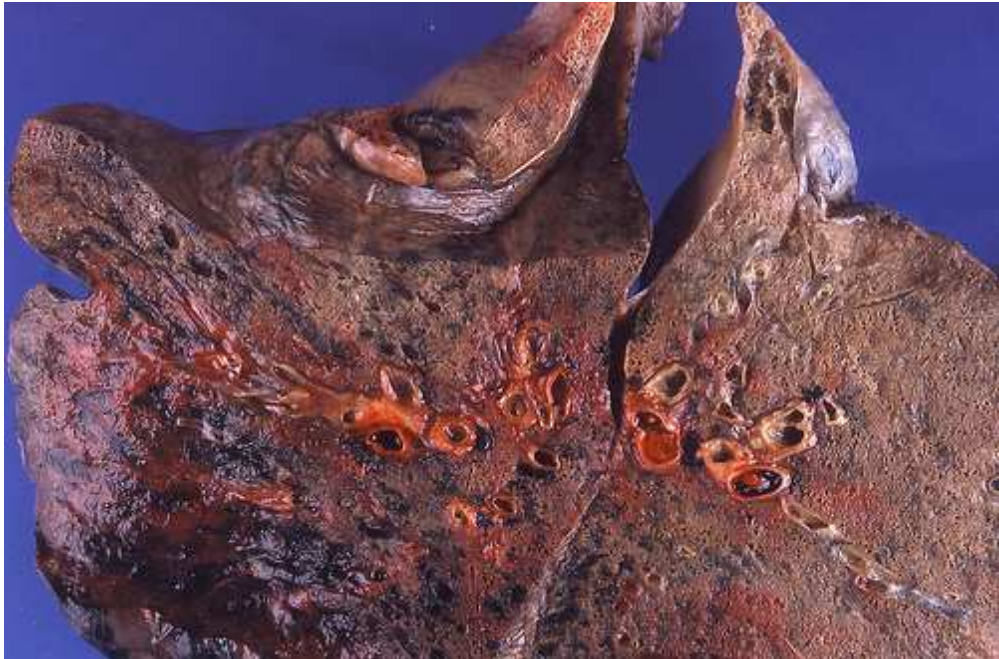It is a subacute/ chronic infection caused by *Cryptococcus neoformans*. It is a soil saprophytic and particularly abundant in the bird faeces.

Morphology:

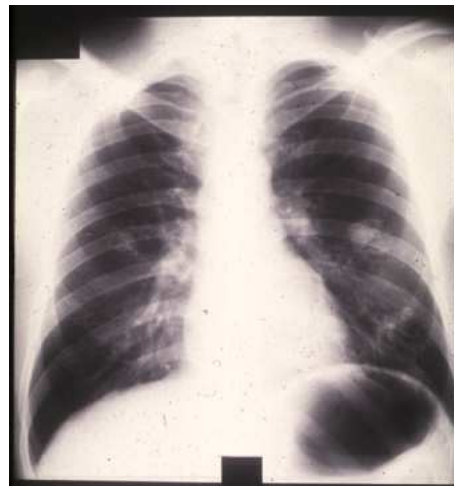- It is a round/ ovoid budding cell.
- It has a prominent polysaccharide capsule.

Pathogenesis:

- Infection is acquired by inhalation but may sometimes be caused by skin or mucosa.
- Most infections are asymptomatic.
- **The disease of great importance is pulmonary cryptococcosis. It may lead to mild pneumonitis. As no calcification occurs, healed pulmonary lesions are not seen radiographically.**



Pulmonary cryptococcosis



Chest X Ray showing cryptococcosis

- Dissemination of virus in the circulation may lead to:
 1. Visceral,
 2. Cutaneous,
 3. Meningeal disease.
- Visceral disease may mimic TB/ Cancer clinically. Bones and joints may be involved.
- Cutaneous disease varies from **small ulcer** to **large granulomas**.

- **Cryptococcal meningitis** is the most serious manifestation and mimic tuberculous meningitis. Its course is slow and progressive, often seen in AIDS.

Diagnosis:

- Diagnosis is established by demonstration of **capsulated, budding yeast cells in the lesions** and by culture.
- The capsules are demonstrated by **Indian Ink preparations**.
- The fungus forms **smooth, mucoid, cream coloured colonies** readily on Sabouraud's agar.
- **The ability to grow at 37°C and to hydrolyse urea help to differentiate between C.neoformans and other non-pathogenic Cryptococcus species.**
- Pathogenicity can be demonstrated by intracerebral/ intraperitoneal injection into mouse, which results in a fatal reaction. Capsulated budding yeast is demonstrated in the brain of the mouse.
- Demonstration of capsular antigen by **precipitation** sometimes becomes valuable in diagnosis of Cryptococcal meningitis.

Some other diseases and their short description

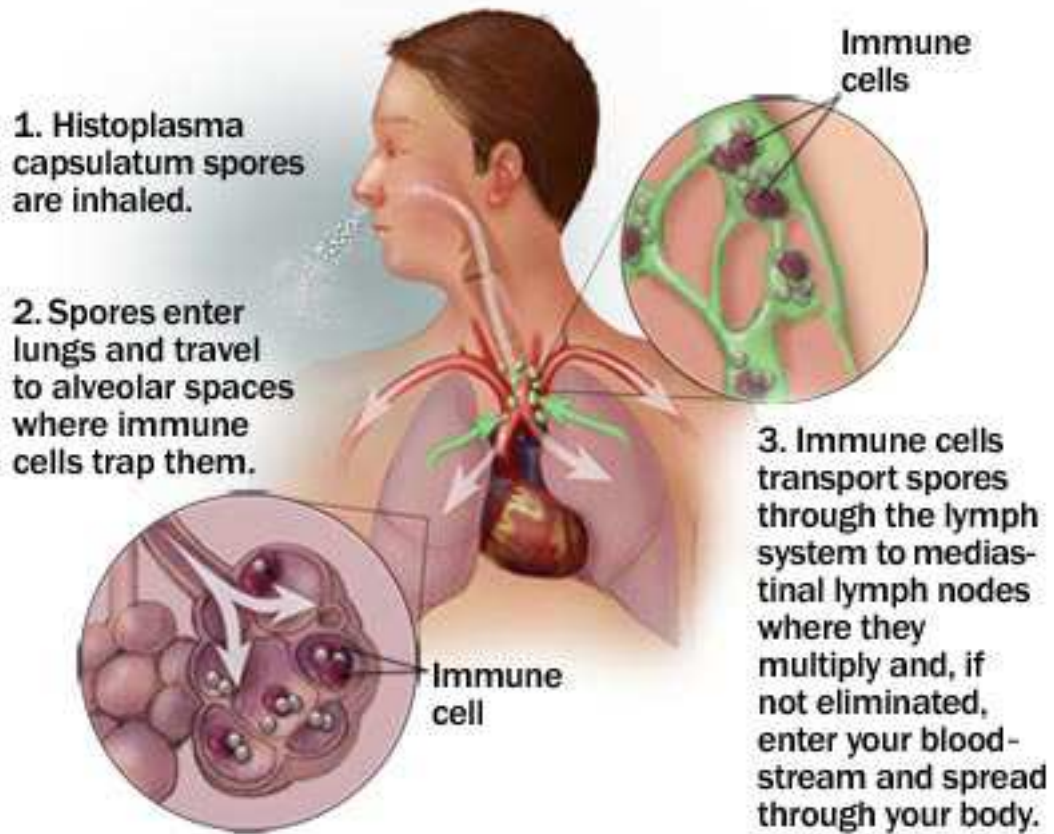
Disease	Blastomycosis	Paracoccidioidomycosis	Coccidioidomycosis
Traits			
Causative organism	<i>Blastomyces dermatitidis.</i>	<i>Paracoccidioides brasiliensis.</i>	<i>Coccidioides immitis</i>
Infection acquired by	Inhalation.	-	Inhalation of dust particle.
Disease in which organs	Lungs and skin.	Buccal and nasal mucosa.	Lung.
Type of disease	Primary infection resembles TB/ histoplasmosis-→ focal/diffuse consolidation/military lesions/ abscess formation. Cutaneous disease on skin/ face/ exposed parts of	Ulcerative granuloma.	Self limited influenza like fever (Valley fever/ desert rheumatism). <1% people develop chronic disease (coccidioidal granuloma) which is highly fatal. It resembles clinically+histologically with

Character of the yeast In tissues and in cultures at 37°C	body->Papules/ secondary nodules which coalesce to form large ulcerative lesions.		disseminated TB.
	The fungus appears as yeast cells with large, thick, double contoured walls; each cell carrying a single basal bud.	The fungus appears as yeast cells with multiple budding.	The fungus appears as mycelial form in both 37°C and 22°C; as yeast in tissues- → Yeast form having thick double refractile cell wall and filled with endospores.

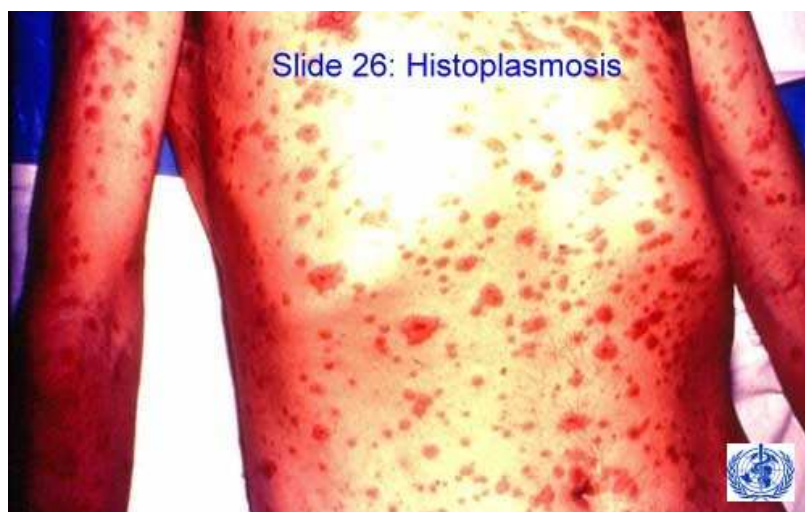HISTOPLASMOSIS

Points	Description
Causative organism	<i>Histoplasma capsulatum</i> .
Morphology of fungus	<ul style="list-style-type: none"> It is a dimorphic fungus-→ In tissues it is present inside phagocytic cells as yeasts. On culture, mycelia form develops with large thick walled spherical spores with finger like projections (tuberculate spores). The demonstration tuberculate spores is diagnostic.
Natural habitat of fungus	<ul style="list-style-type: none"> Soil Rotting trees Bird faeces
Pathogenesis	<ul style="list-style-type: none"> The large majority of infection is asymptomatic, they heal, leaving an area of military calcification as occurs in TB. Disseminated histoplasmosis occurs in a small proportion of individuals with involvement of RE system and is highly fatal: <ol style="list-style-type: none"> Lymphadenopathy Fever Anemia Hepatosplenomegaly.
Diagnosis	<ul style="list-style-type: none"> Specimen: <ol style="list-style-type: none"> Smears of blood Bone marrow Biopsy of lymph nodes Serodiagnosis: <ol style="list-style-type: none"> Latex Agglutination

- 2. Complement fixation test
- 3. Precipitation tests
- Delayed hypersensitivity is demonstrated by skin testing with **histoplasmin**.



© Mayo Foundation for Medical Education and Research. All rights reserved.



Disseminated histoplasmosis

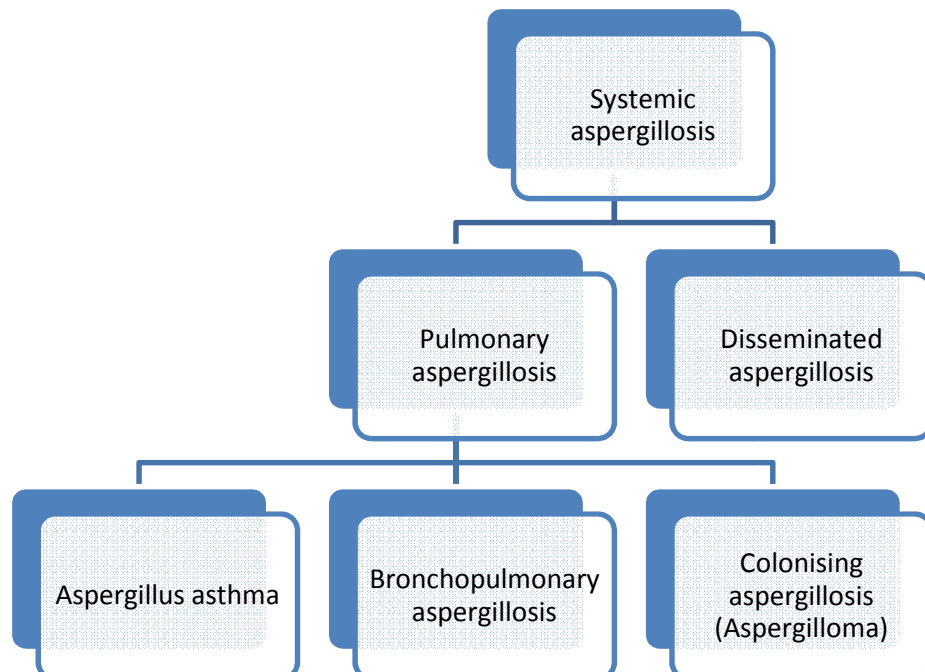
OPPORTUNISTIC INFECTIONS

These are saprophytic fungi, don't usual pathogens of human. But now a days they are very much important in medical mycology for mainly 2 reasons:

1. They are common laboratory contaminants.
2. They can cause serious, even fatal diseases in immunocompromized, debilitated, aged patients, and patients with AIDS.
3. The first group of laboratory contaminants includes *Aspergillus*, *Penicilium* and *Mucor*.
4. The second group of opportunistic infectants includes *Aspergillus* and *Mucor*.

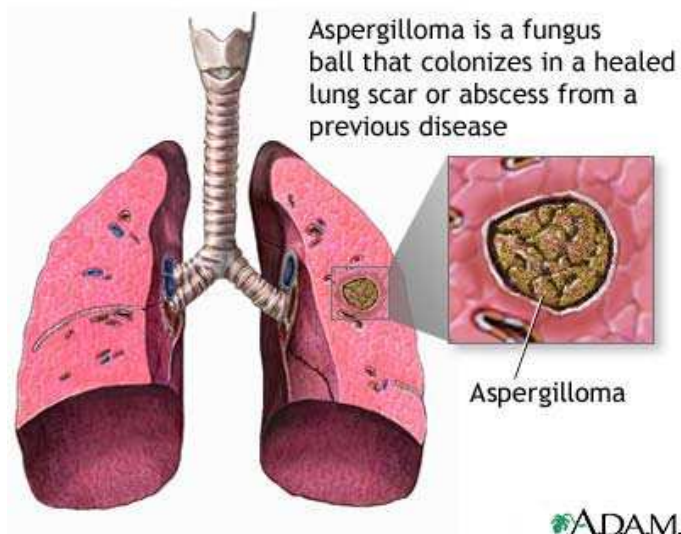
ASPERGILLOSIS

- **The commonest human disease caused by aspergillus is otomycosis.**
- Systemic aspergillosis occurs in the following clinical types:



- Aspergillus asthma occurs following **sensitisation to inhaled aspergillus spores.**
- In bronchopulmonary aspergillosis, the **fungus grows within the lumen of bronchioles** and can be demonstrated in the sputum.

- Colonising aspergillosis usually develops in **pre-existing pulmonary cavities**, such as in TB or cystic disease. Here the fungus grows into large balls called **aspergilloma**.



- **Surgical treatment is the only option as it may cause massive hemoptysis.**
- Disseminated aspergillosis occurs usually in patients on prolonged treatment with antibiotics, steroids or cytotoxic drugs.
- It may involve:
 1. Brain
 2. Kidney and,
 3. Any other organ.

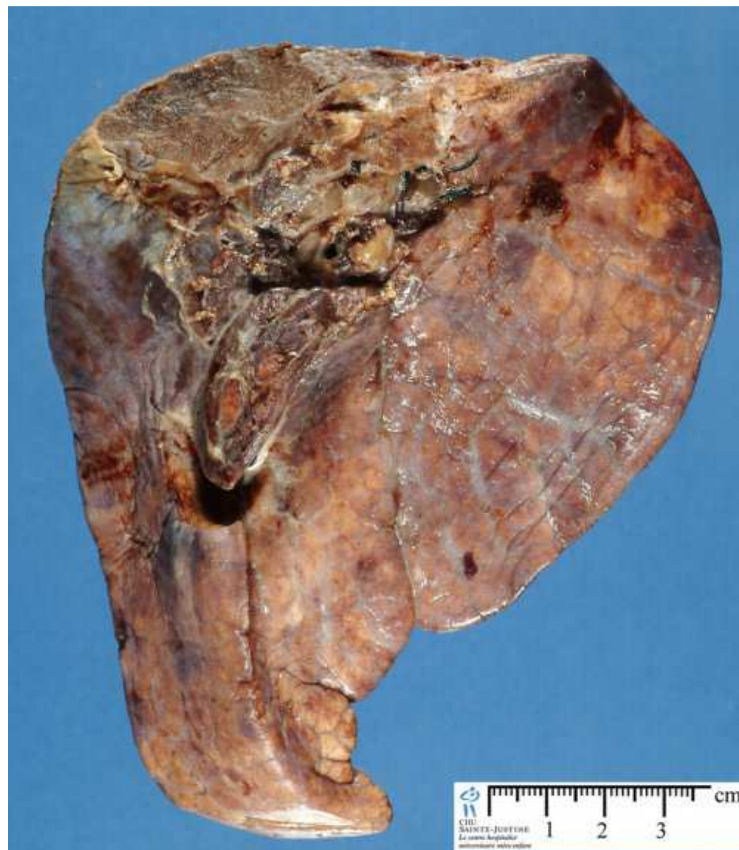Diagnosis: Laboratory diagnosis of aspergillosis is made by microscopic examination and culture. Identification of *Aspergillus* is easy, **it has septate hyphae**. Asexual **conidia are arranged in chains** and carried on elongated cells called **sterigmata**.

Penicilliosis

- It is a very rare opportunistic pathogen.
- *P.marneffe* is one important species causing infection in HIV infected persons.

MUCORMYCOSIS

- It is an invasive disease caused by species of:
 1. Rhizopus,
 2. Mucor,
 3. Absidia.
- These species are usually avirulent, and may cause invasive diseases only when host resistance is extremely low.
- **It was a rare complication of diabetes and other diseases but now a days, its incidence has been highly increased due to extensive use of antibiotics, steroids and anticancer drugs.**
- The primary site of infection is the ***upper respiratory tract/ nose, also the lung*** where the spore germinates and mycelium invades the adjacent tissues:
 1. The orbit
 2. The sinuses and,
 3. The brain.



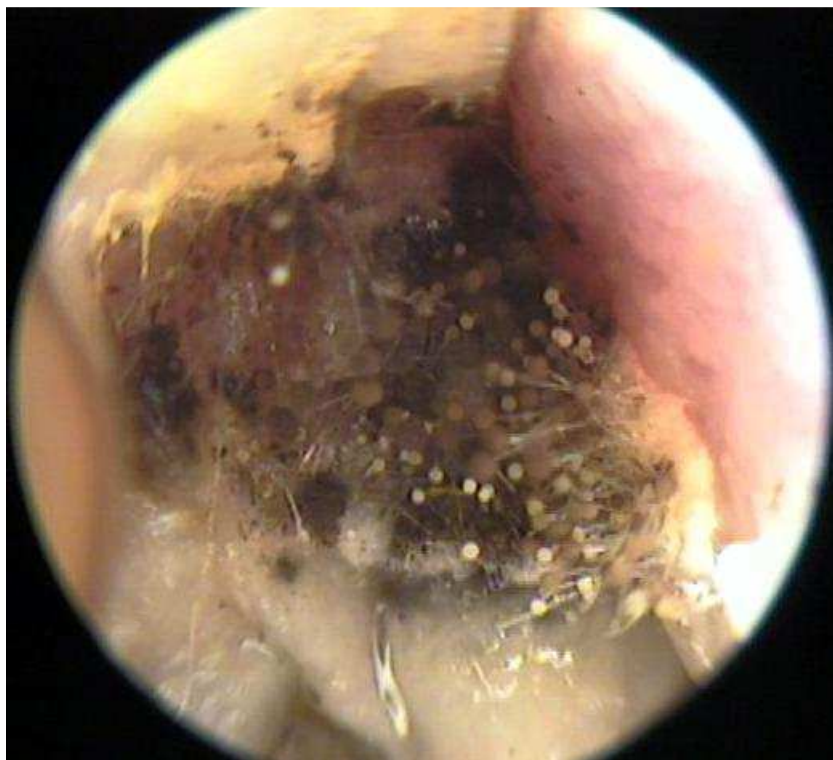Pulmonary mucormycosis

- When primary disease occurs in the lung, it becomes fatal by causing **thrombosis and infarction**.
- Diagnosis is made by histological examination of autopsy material, where it shows **presence of broad and nonseptate hyphae**.
- Species is detected by following chart:

Rhizopus	Having rhizoids.
Mucor	Branched sporangiospores.

OTOMYCOSIS

- It is a fungal infection of **external ear**.
- It is a very common infection.
- It is usually caused by *Aspergillus niger* and *A.fumigatus*.
- The symptoms are:
 1. Itching,
 2. Pain,
 3. Deafness.

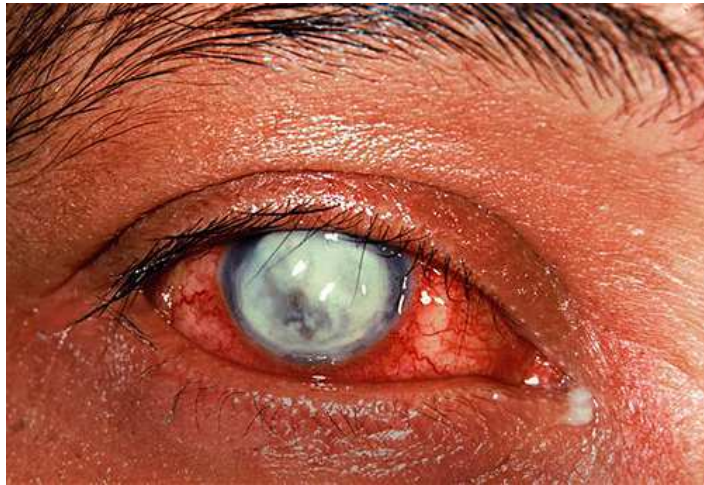

Otomycosis

- Secondary bacterial infection by *Pseudomonas* and *Proteus* may occur.

OCULOMYCOSIS

- The clinical disease is an **ocular infection** named as **mycotic keratitis**.
- It usually follows **corneal trauma**.
- Fungal spores colonise the injured tissue and elicit an inflammatory reaction, leading to **formation of ulcer and endophthalmitis**.



Oculomycosis

*****Mycotic poisoning:**

- Many fungi form poisonous toxins named as **mycotoxins**.
 - The best known mycotoxin is **aflatoxin** produced by ***Aspergillus flavus***.
 - These fungi are frequently present in groundnuts, pea and corn.
 - It is highly toxic and having carcinogenic potentials.
 - **Ergotoxins** are produced by ***Claviceps purpurea*** living on rye.
-