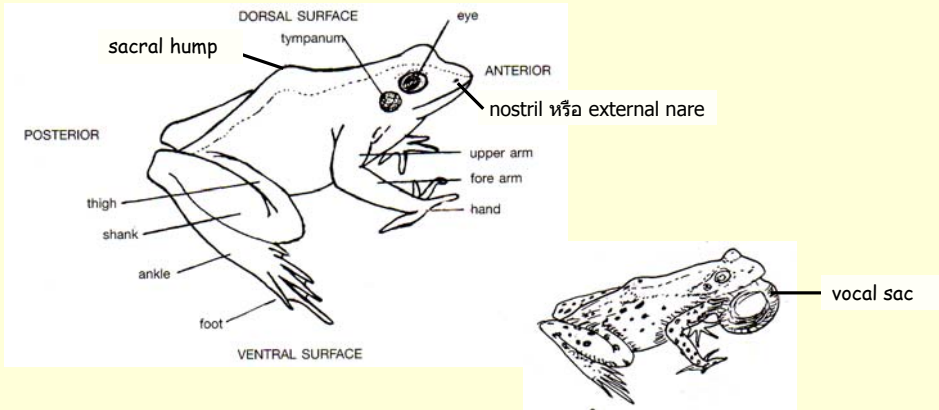


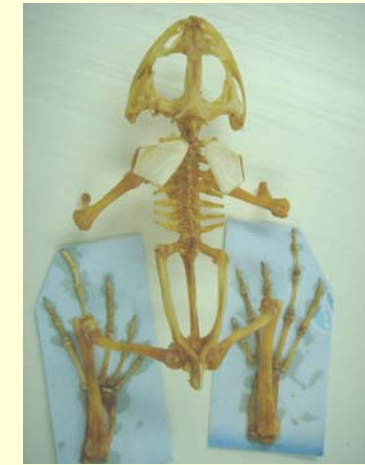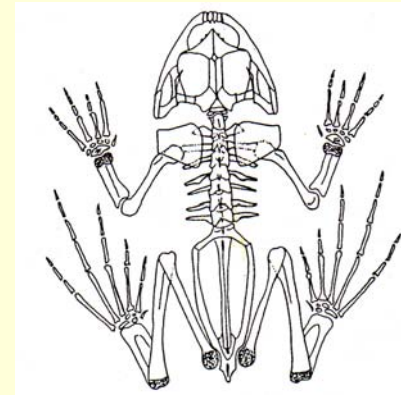
External feature, skeleton and muscle

external morphology

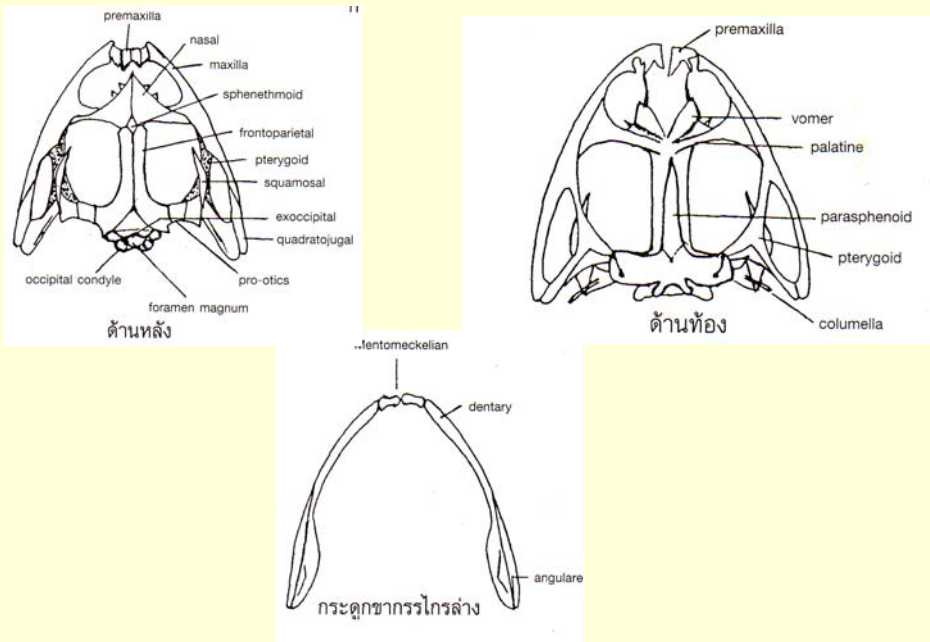
1. Upper eyelid
2. Lower eyelid
- 2.1 nictitating membrane



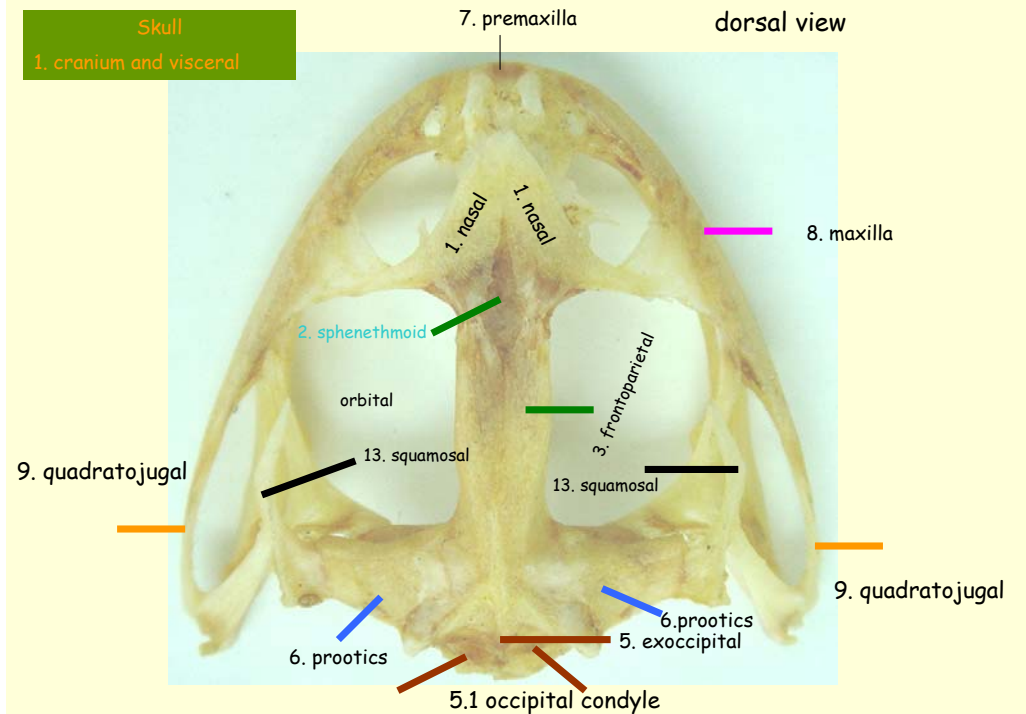
skeletal system



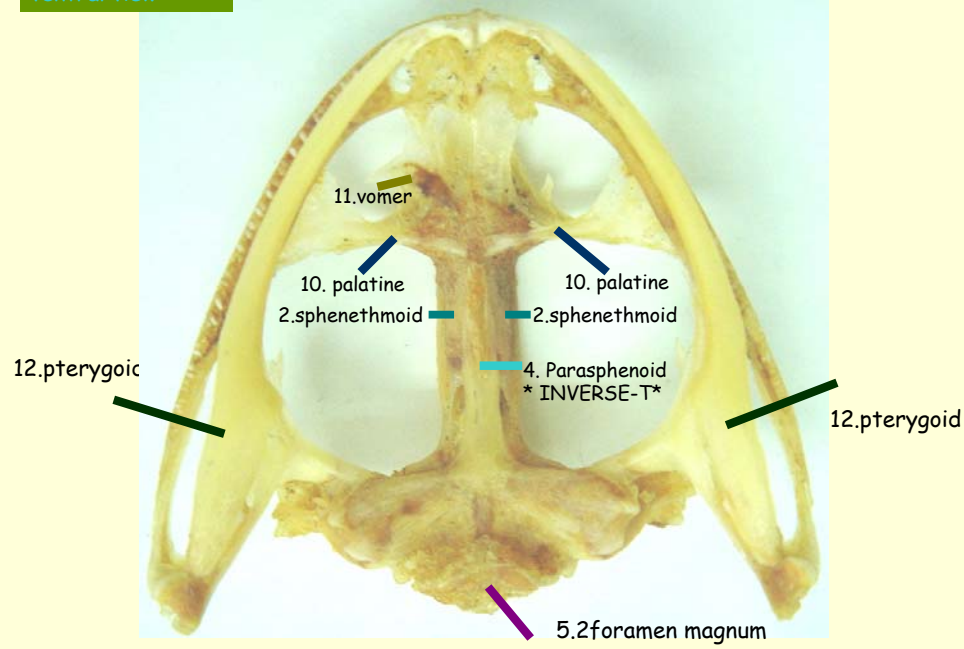
กระดูกกะโหลก



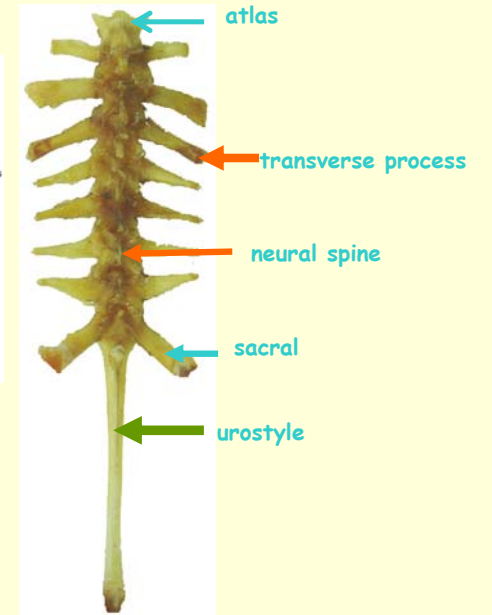
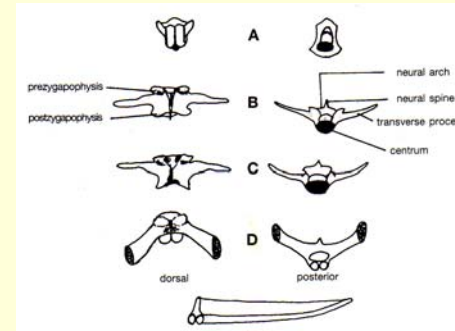
Skull
1. cranium and visceral



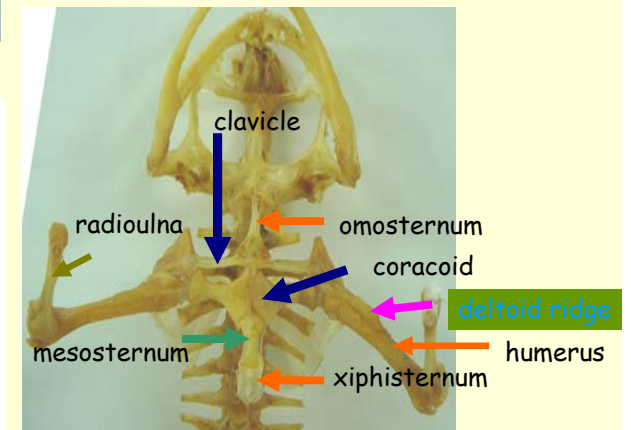
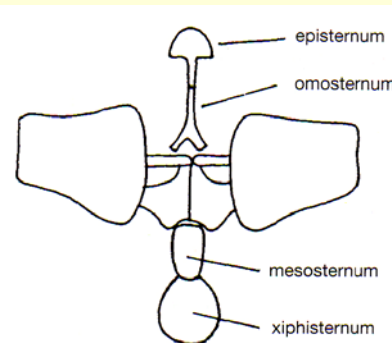
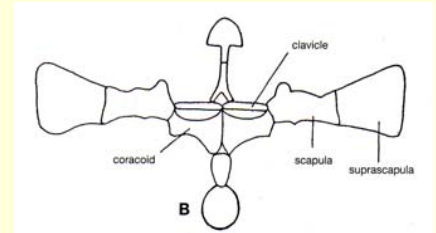

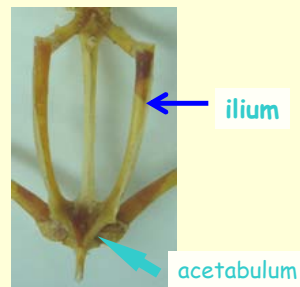
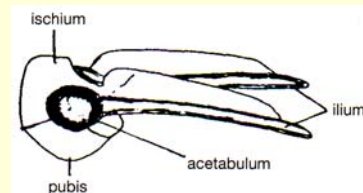
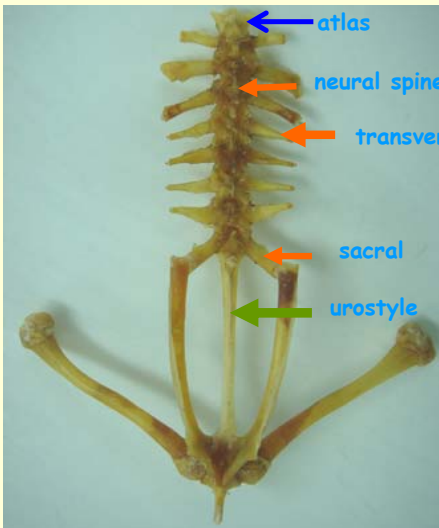
ventral view



Vertebral column



vertebral column and pelvic girdle



hind limb

