



Scalp

Dr. Heba Kalbouneh

Associate Professor of Anatomy and Histology

Scalp

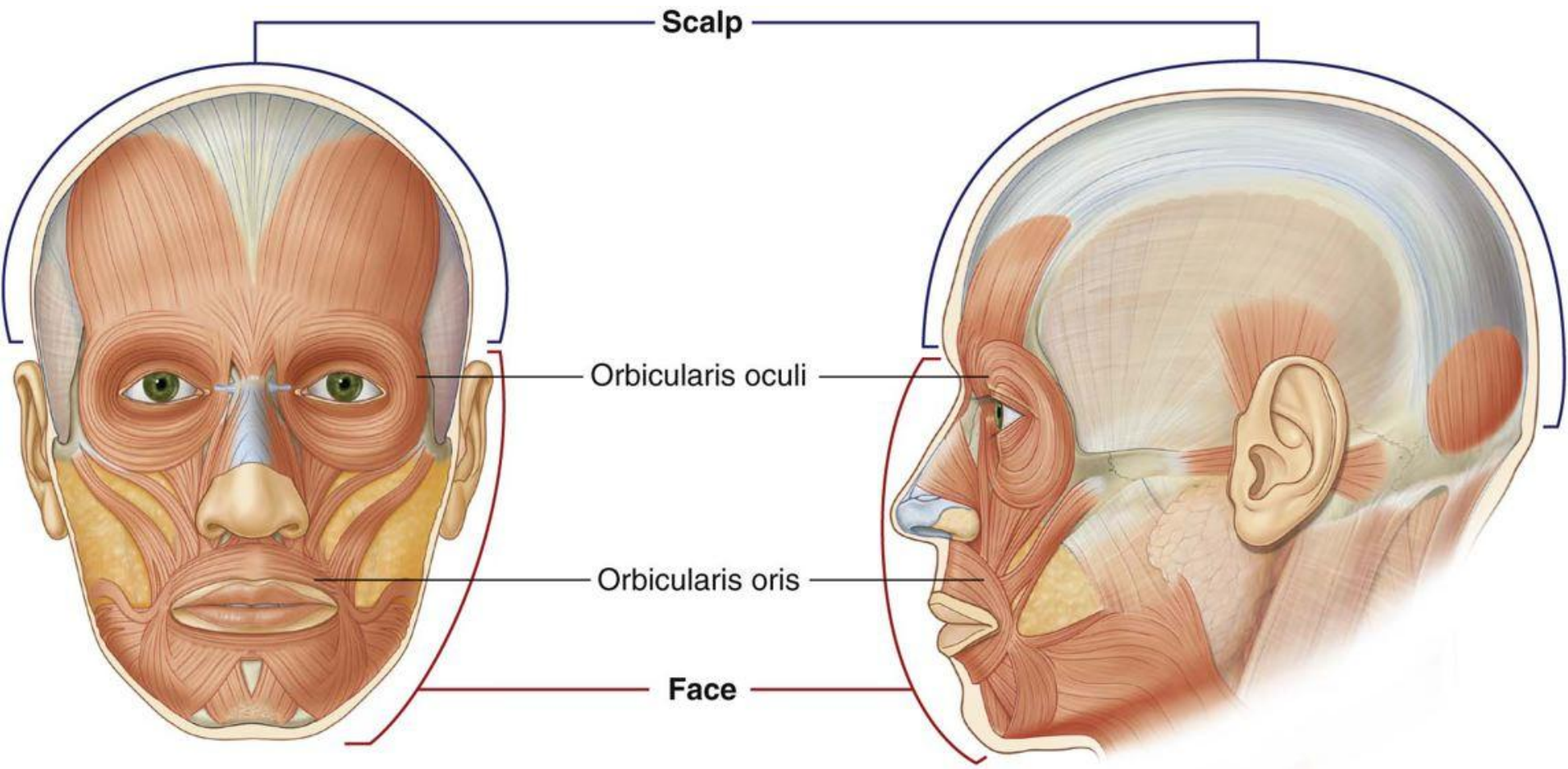
- It is the soft tissue that covers the skull cap
- Extension:

Front: superciliary arch

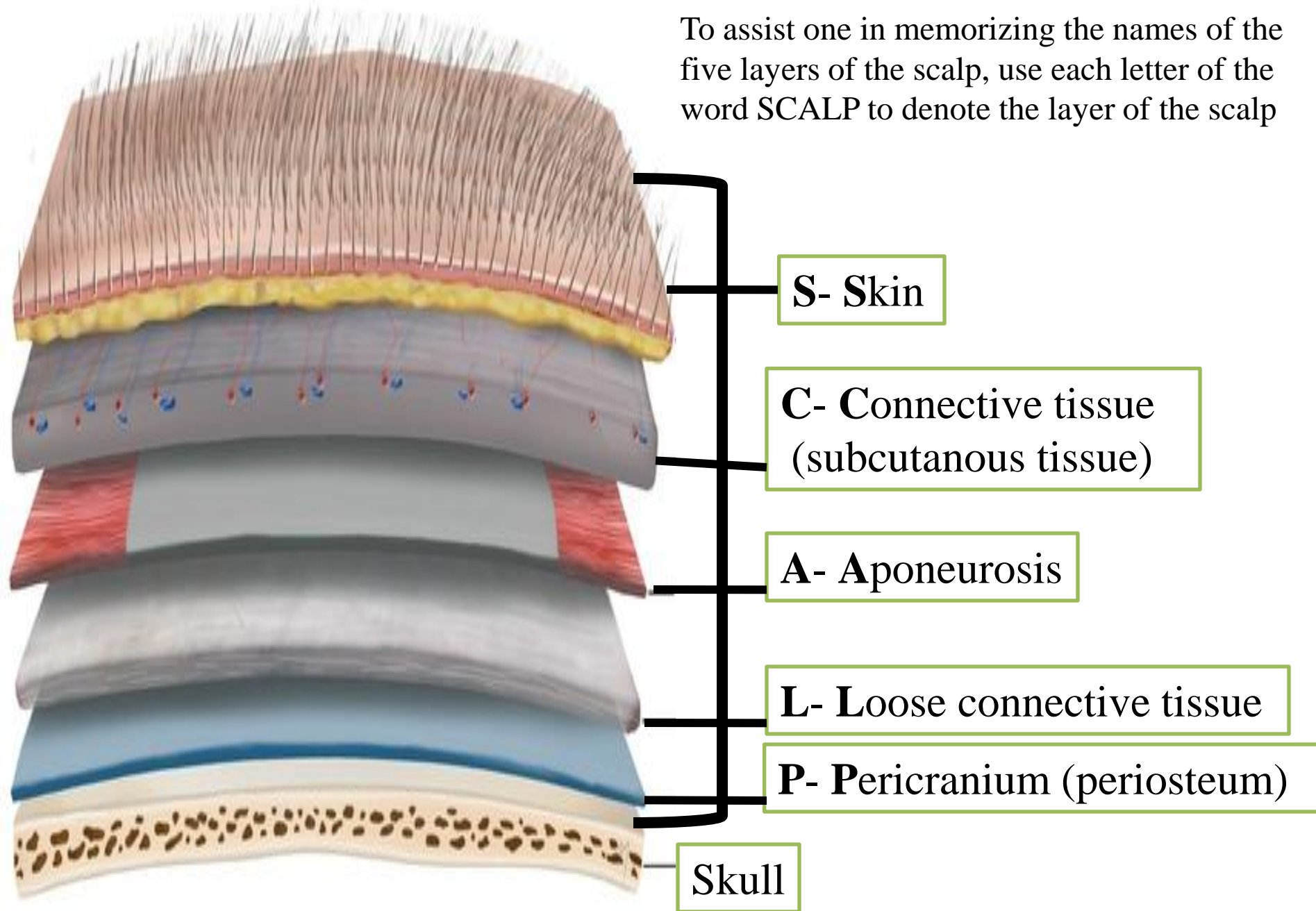
Back: superior nuchal line

Sides: zygomatic arch

Highest point of the scalp is called **Vertex**



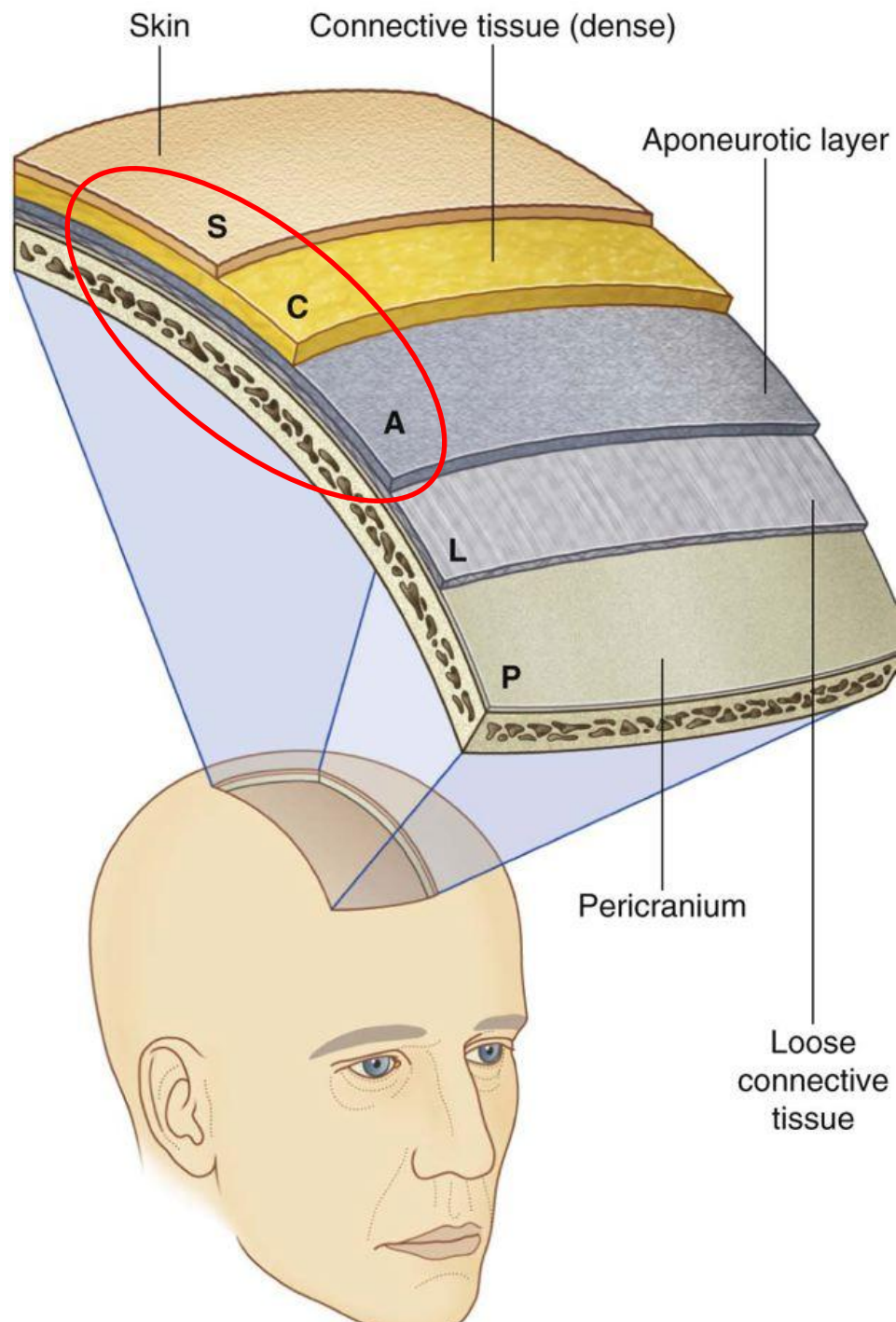
To assist one in memorizing the names of the five layers of the scalp, use each letter of the word SCALP to denote the layer of the scalp

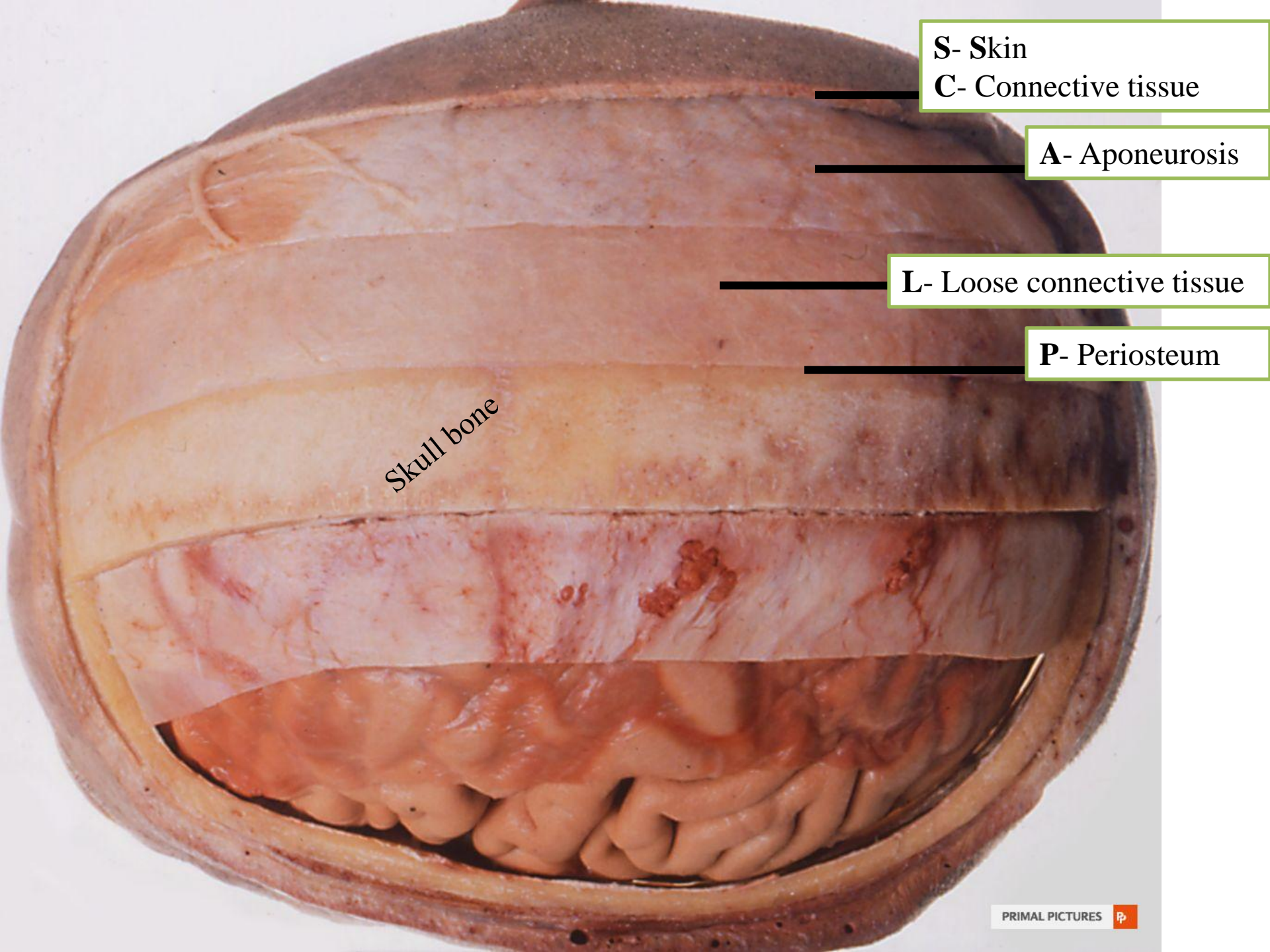


The SCALP consists of five layers:

- S- Skin
- C-Connective tissue (dense)
- A-Aponeurotic layer
- L-Loose connective tissue
- P-Pericranium

The first three of which are intimately bound together and move as a unit





S- Skin
C- Connective tissue

A- Aponeurosis

L- Loose connective tissue

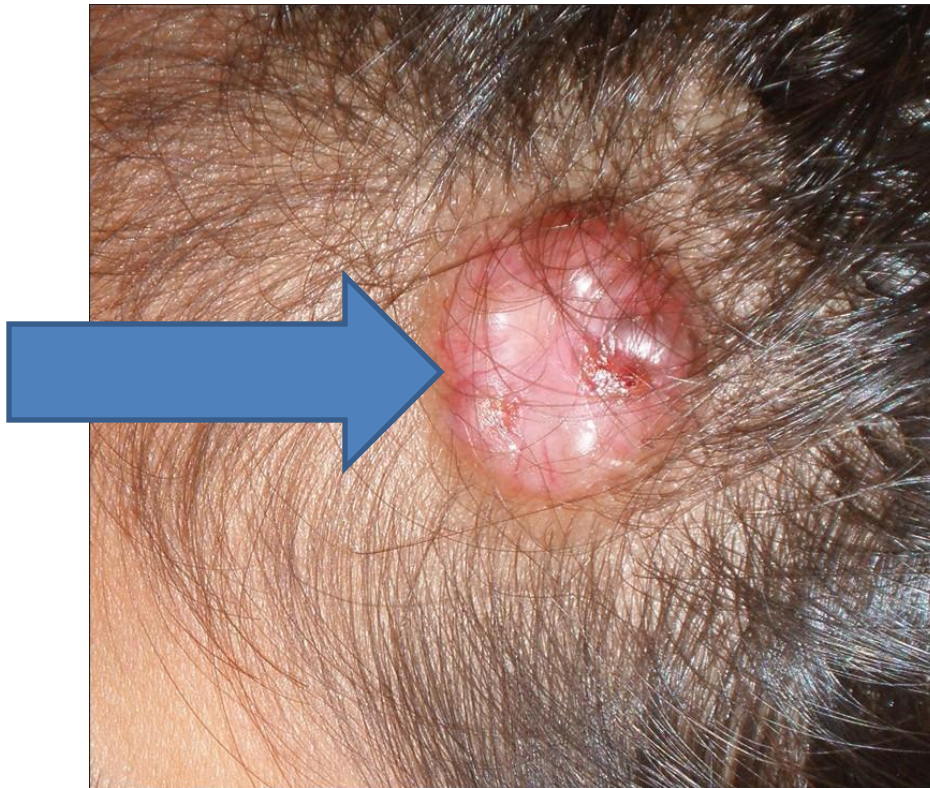
P- Periosteum

Skull bone

1- Skin

✓ Rich in **hair follicles, sebaceous glands and eccrine sweat glands**

Scalp is a common site for sebaceous cysts



2- **Connective tissue**

Made of fibrous septa which unite the skin to the underlying aponeurosis

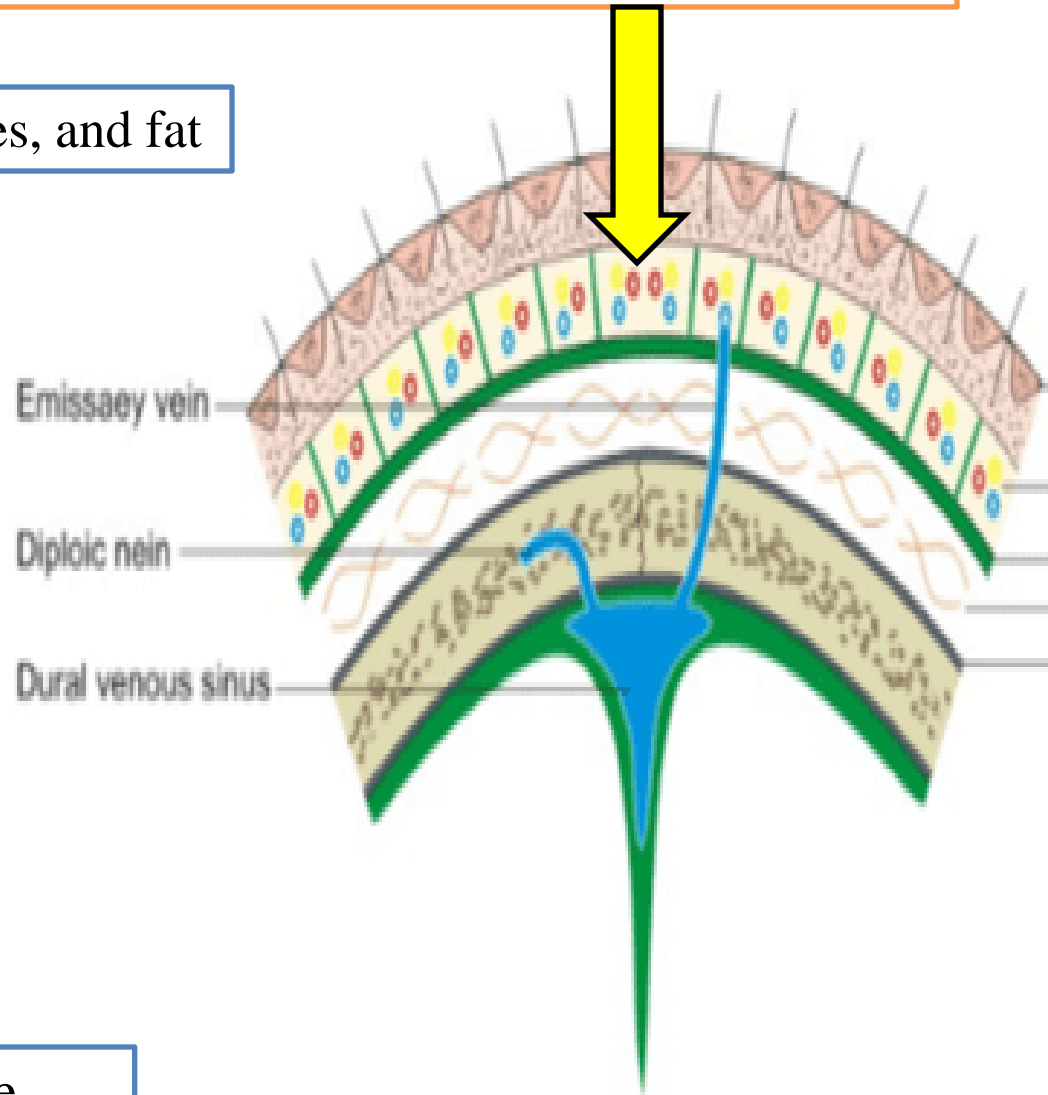
Contains numerous blood vessels, nerves, and fat

Thus wounds of the scalp bleed profusely but heal very rapidly

It is often difficult to stop the bleeding of a scalp wound

The blood vessels do not retract and close when lacerated because the connective tissue in which they are found holds them open

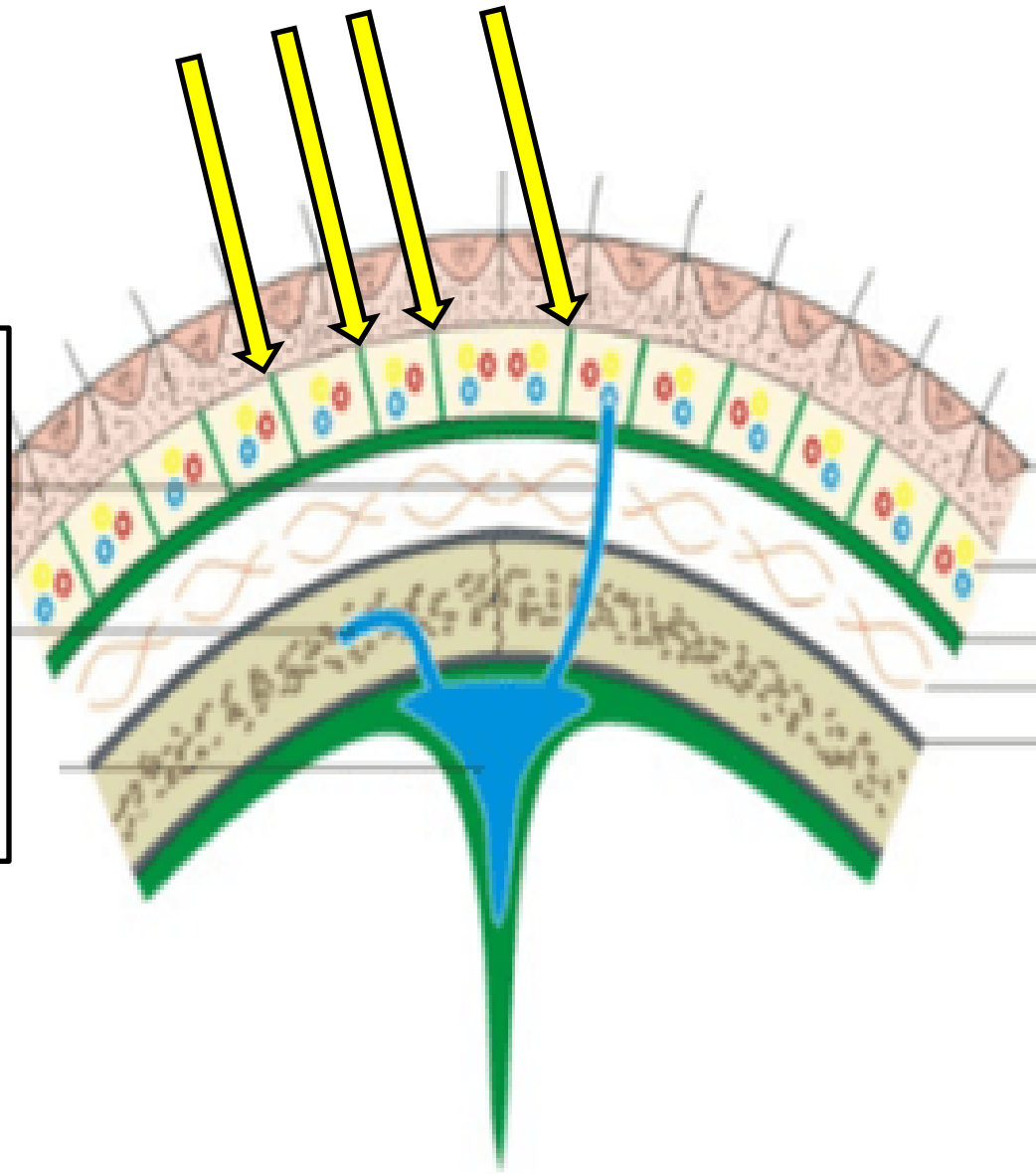
Local pressure applied to the scalp is the only satisfactory method of stopping the bleeding



Fibrous septa



- 1- Unite the skin to the underlying aponeurosis of the occipitofrontalis muscle
- 2- Divide the connective tissue layer into small compartments
- 3- Hold the cut blood vessels open (in case of scalp wound)



Emissary veins

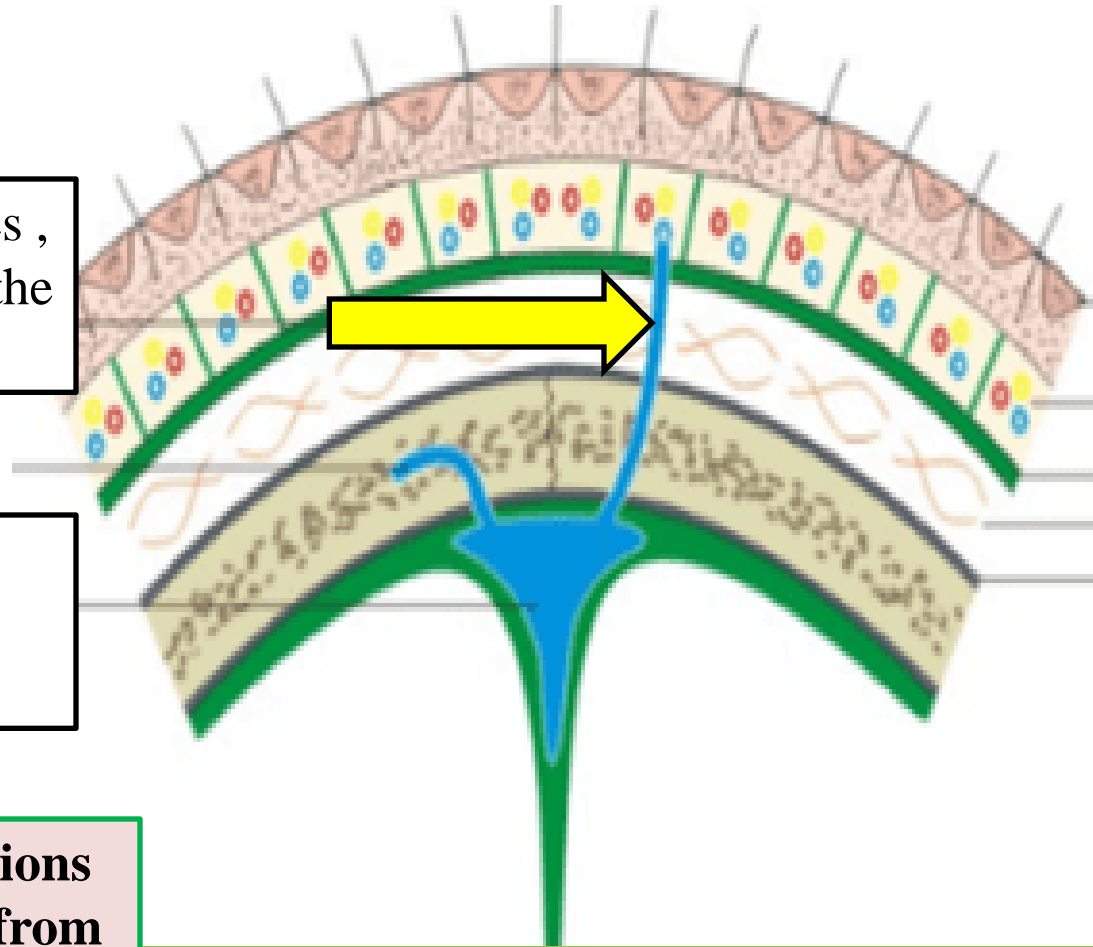


Emissary veins: are devoid of valves , connects the veins of the scalp with the intracranial venous sinuses

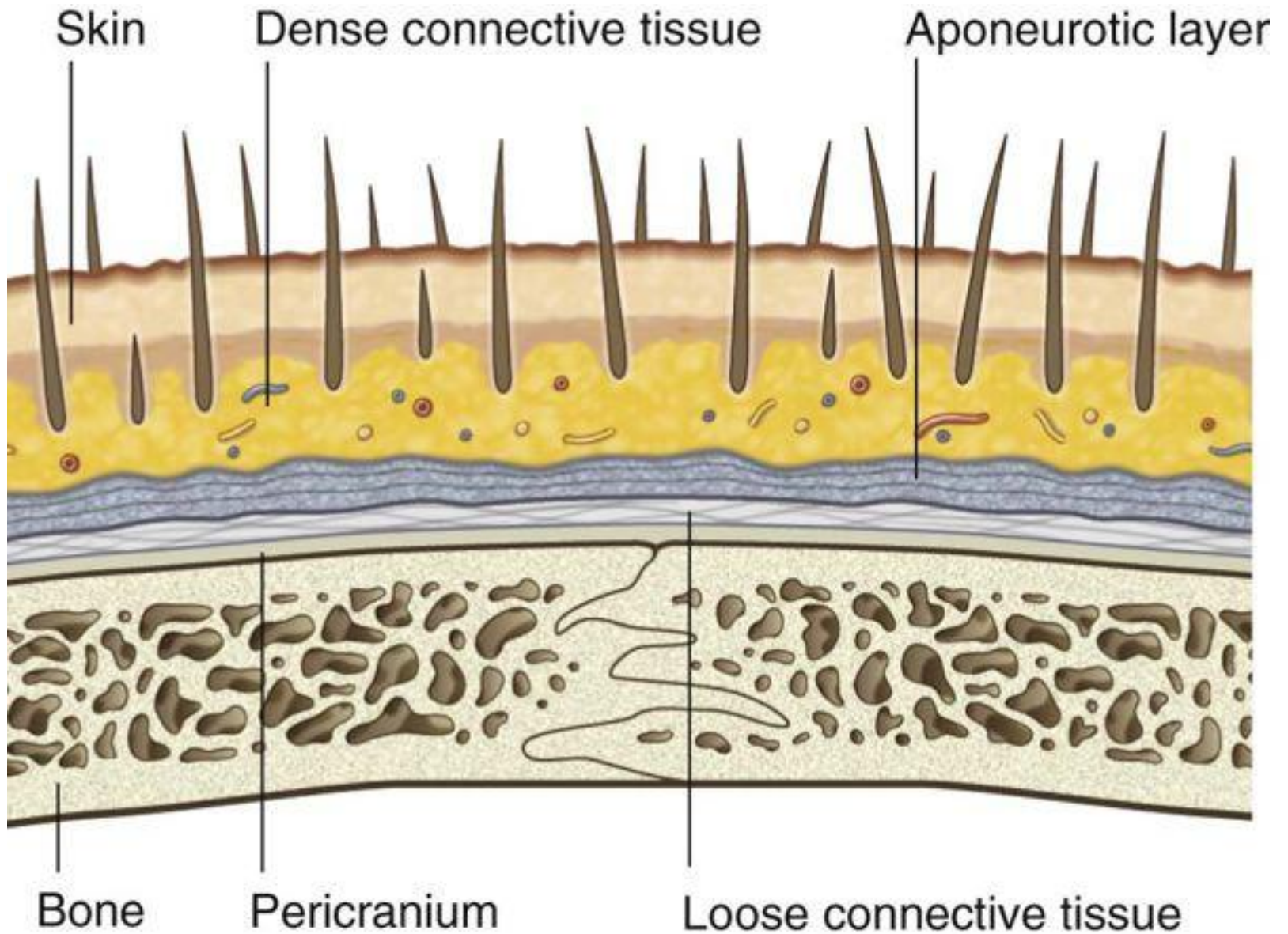


- 1- Equalize the pressure between intracranial and extracranial veins
- 2- Selective cooling of the head

!!!!!!! Serve as routes where infections are carried into the cranial cavity from the extracranial veins to the intracranial veins.



Emissary veins connect the veins outside the cranium to the venous sinuses inside the cranium

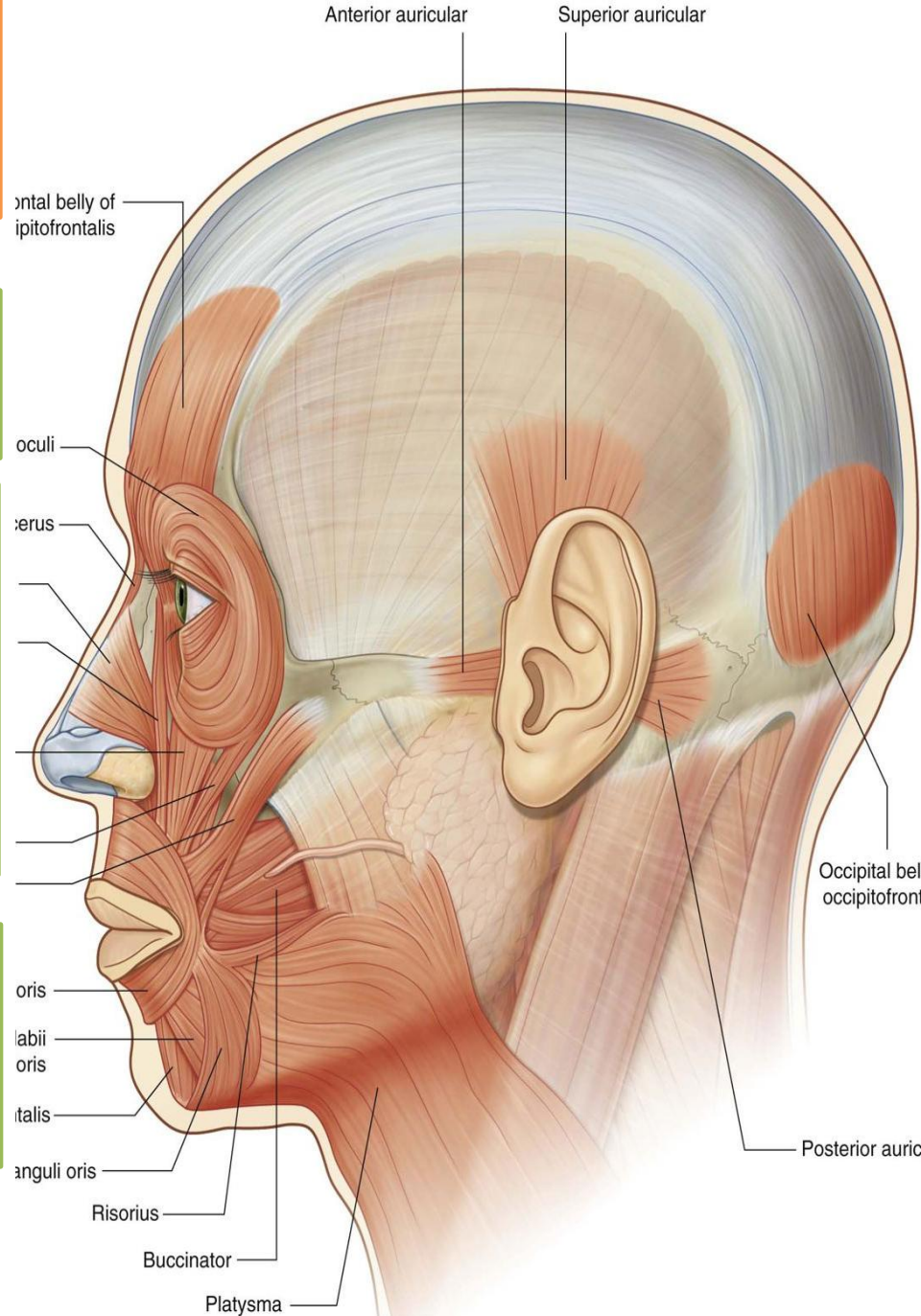


3- Epicranial aponeurosis (Galea aponeurotica)

Consists of the occipitofrontalis muscle

Occipitofrontalis has a frontal belly anteriorly and an occipital belly posteriorly and an aponeurotic tendon connecting the two

The lateral margins of the aponeurosis are attached to the temporal fascia



Muscles of the Scalp

Occipitofrontalis

Origin:

Frontal belly: skin of the eyebrows

Occipital belly: highest nuchal line/
superior nuchal line

Insertion:

Epicranial aponeurosis

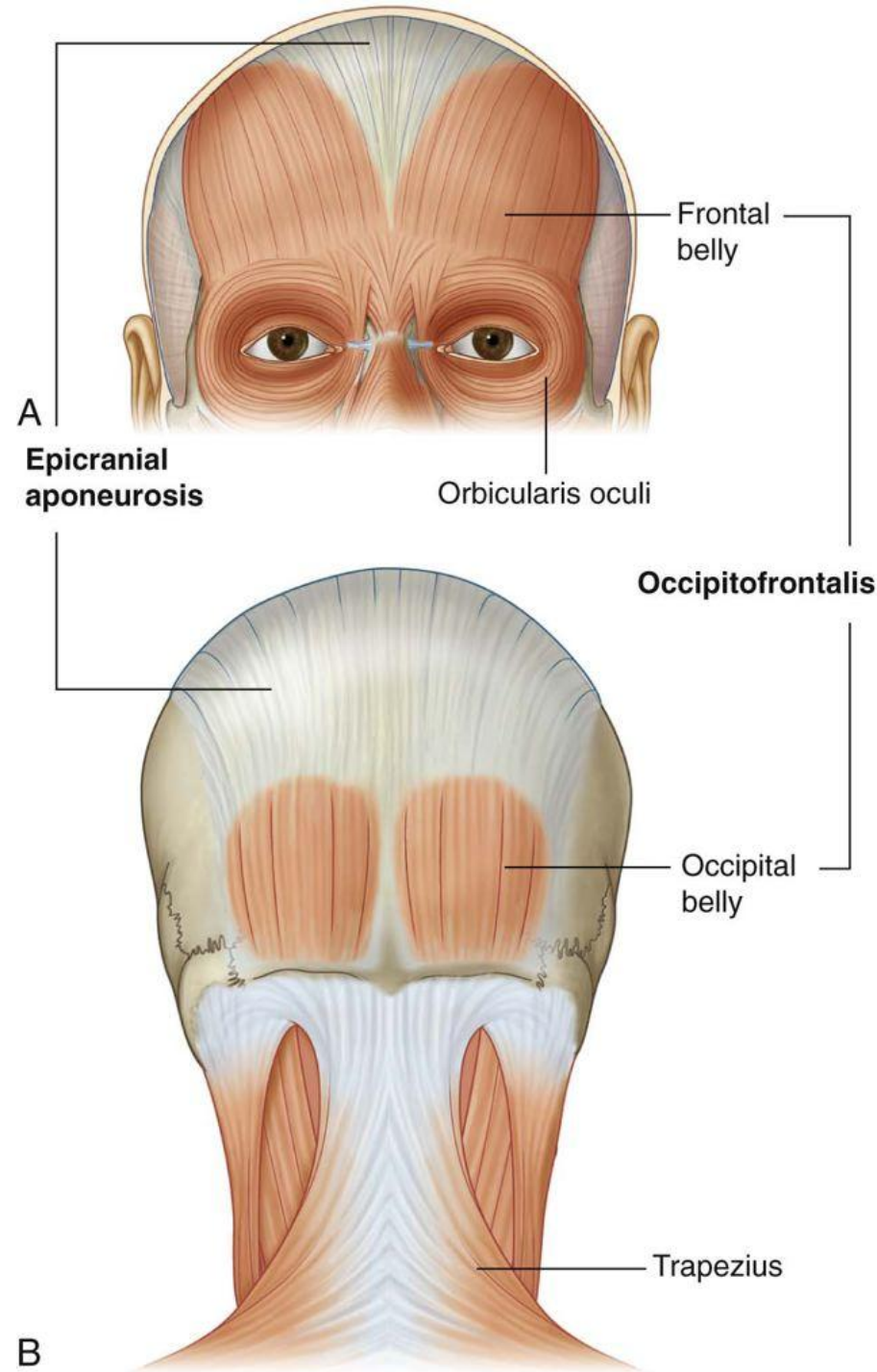
Nerve supply:

Facial nerve
(temporal and posterior auricular
branches)

Action:

Moves scalp on skull

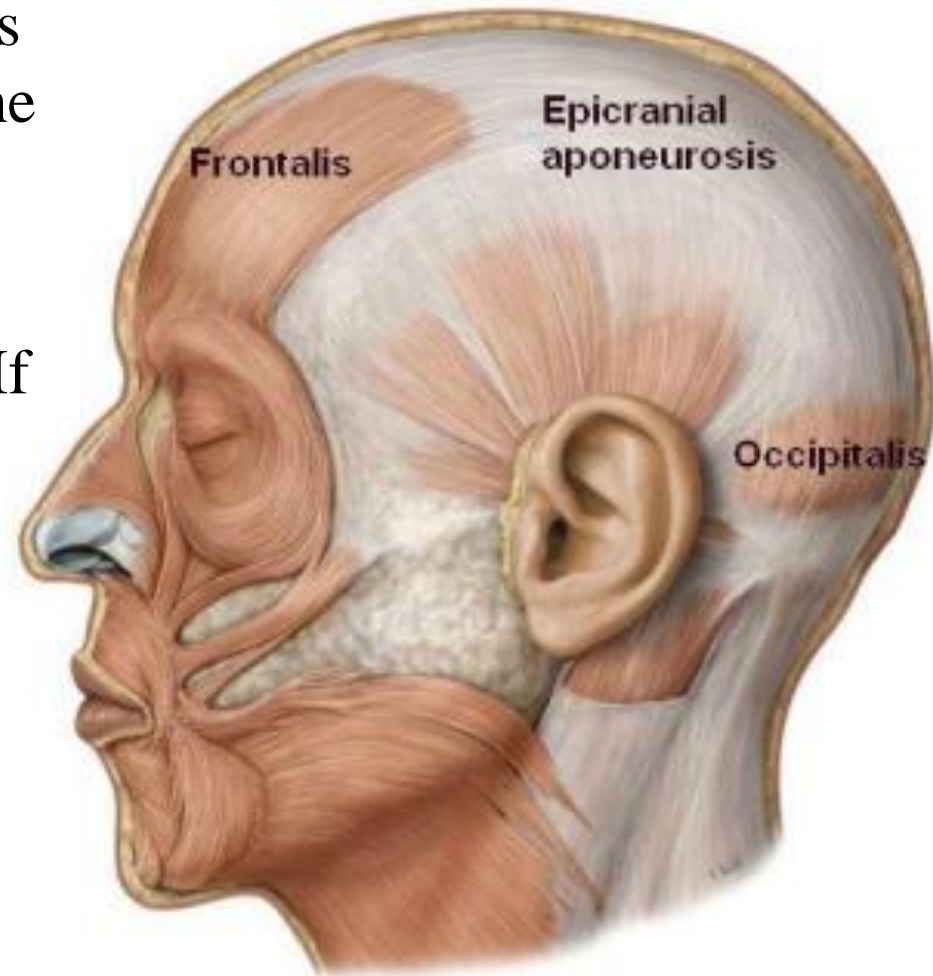
The frontal bellies of the occipitofrontalis
can raise the eyebrows in expressions of
surprise or horror (wrinkling of forehead).



The tension of the epicranial aponeurosis, produced by the tone of the occipitofrontalis muscles, is important in all deep wounds of the scalp.

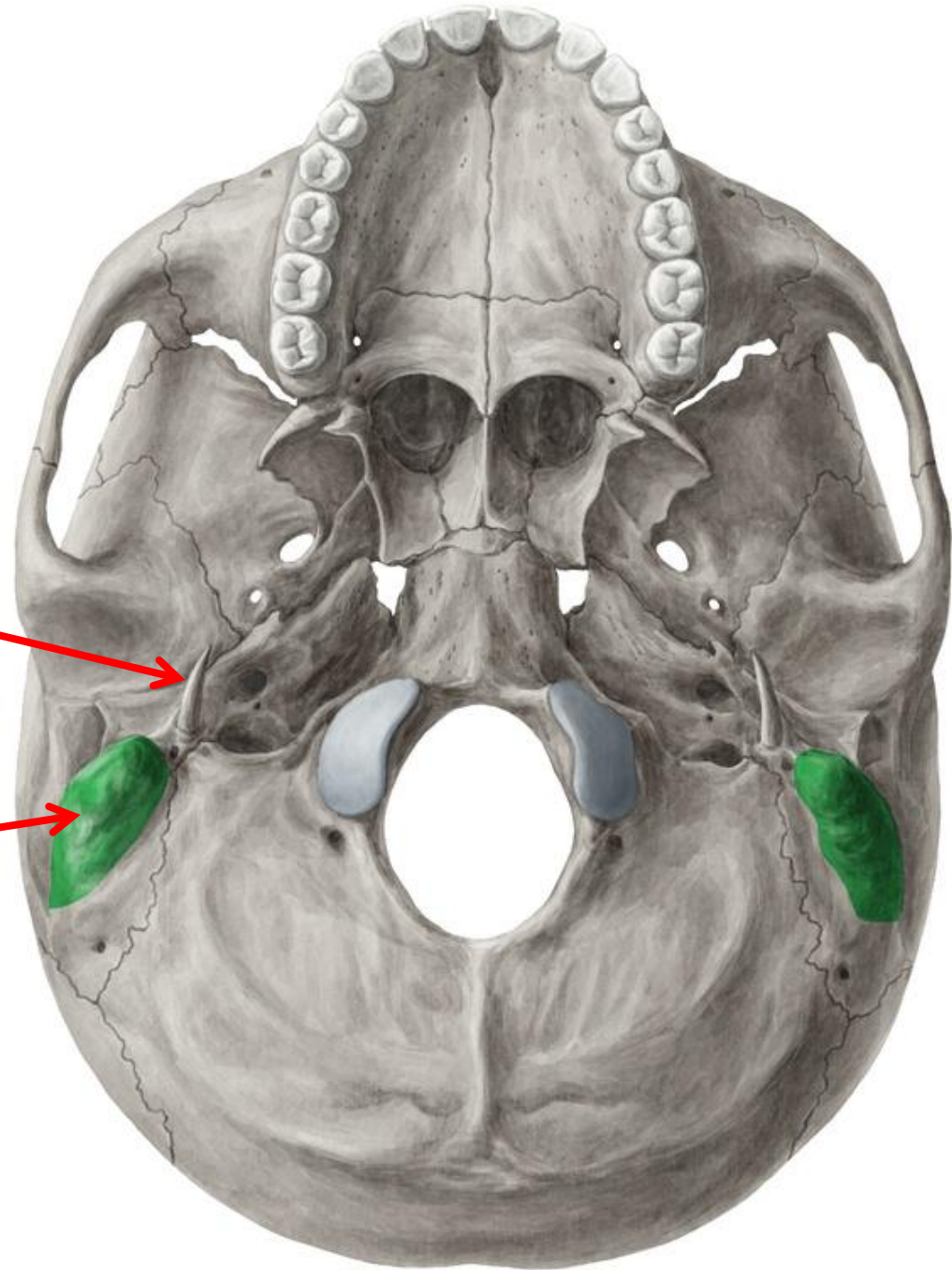
The aponeurosis connects the frontalis and occipitalis muscles. If it is cut coronally, contraction of the muscle usually gapes the wound

For satisfactory healing to take place, the opening in the aponeurosis must be closed with sutures

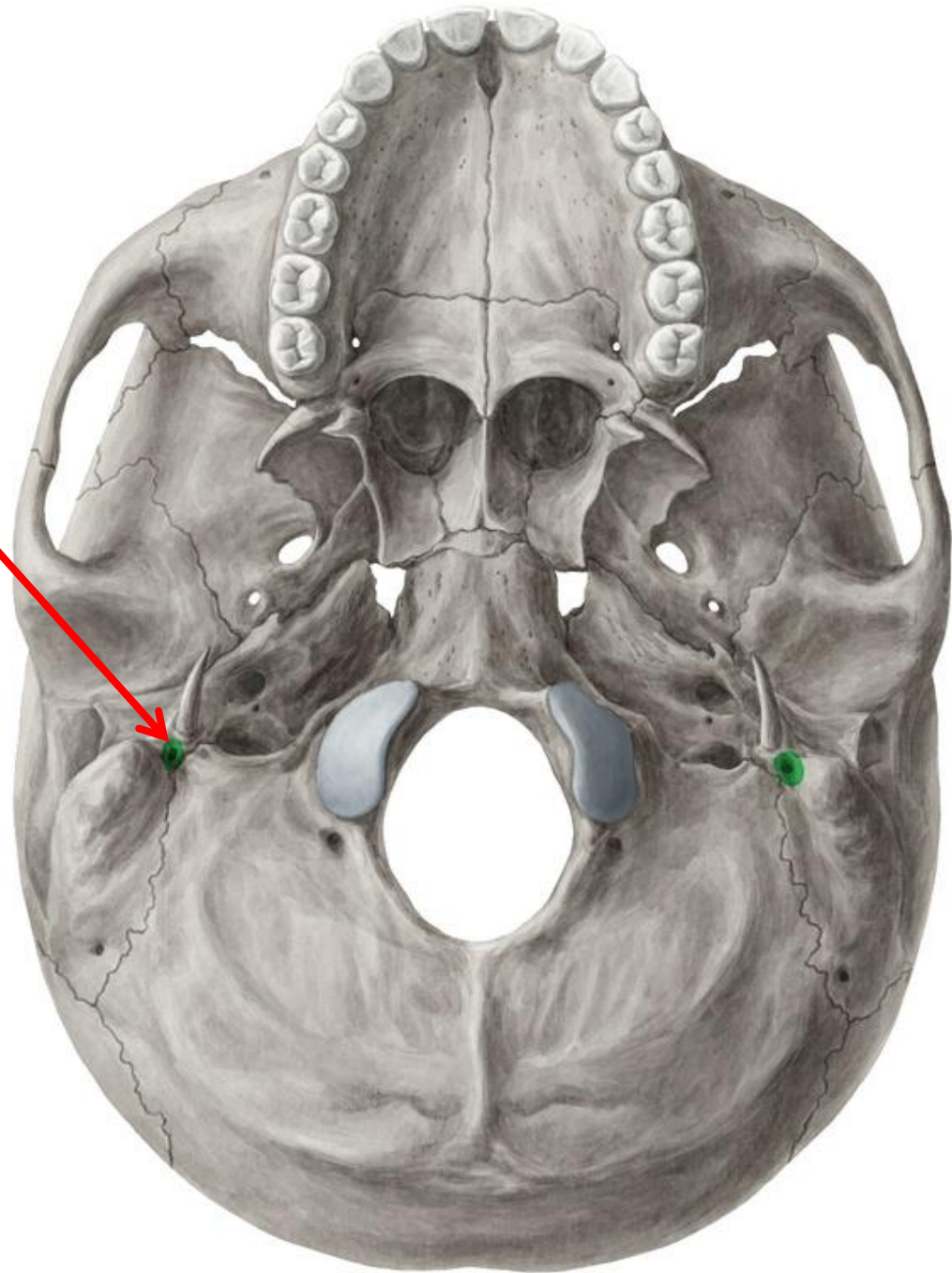


Styloid process of the temporal bone

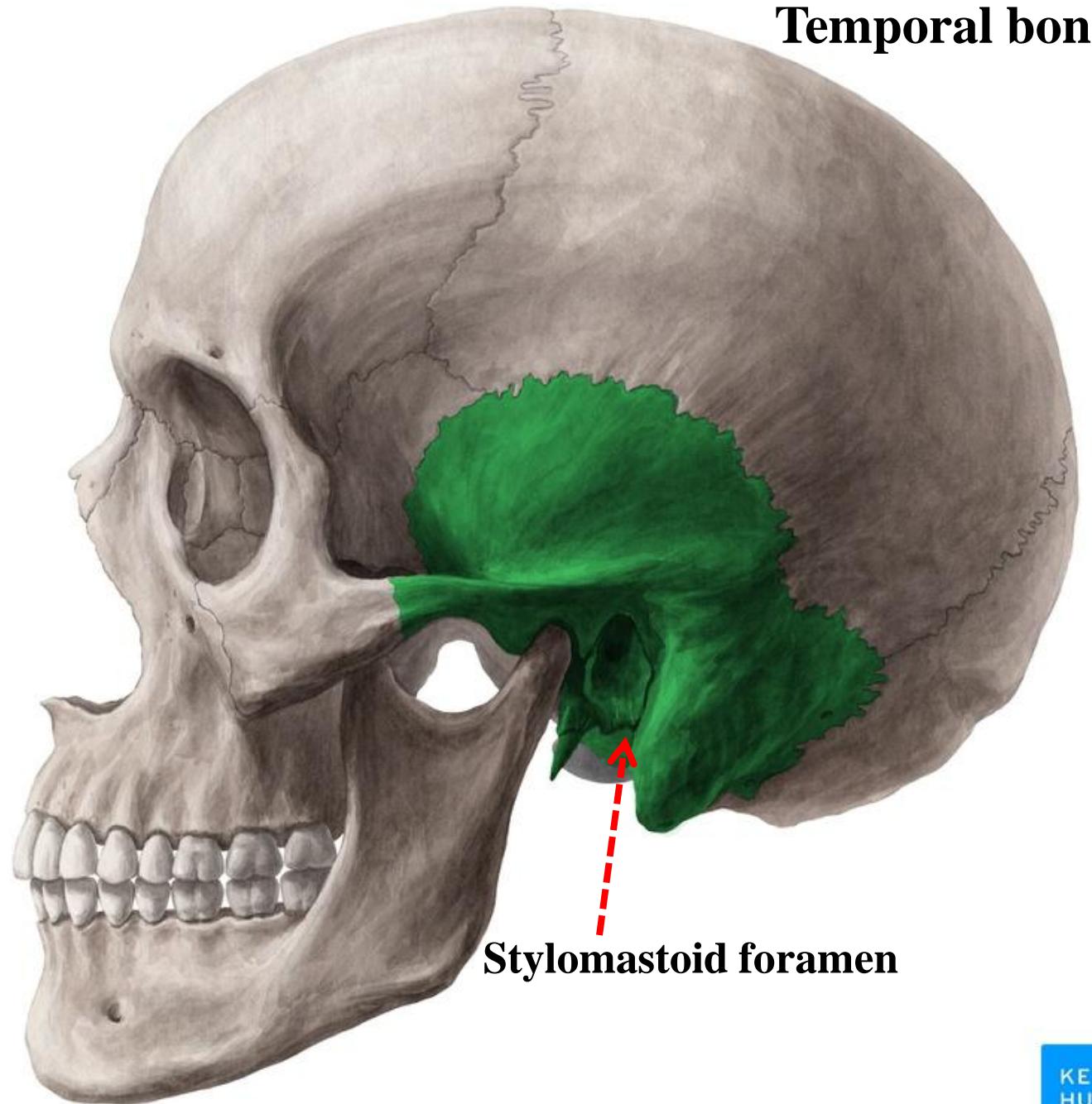
Mastoid process



The **stylomastoid foramen** In the interval between the styloid and mastoid processes



Temporal bone

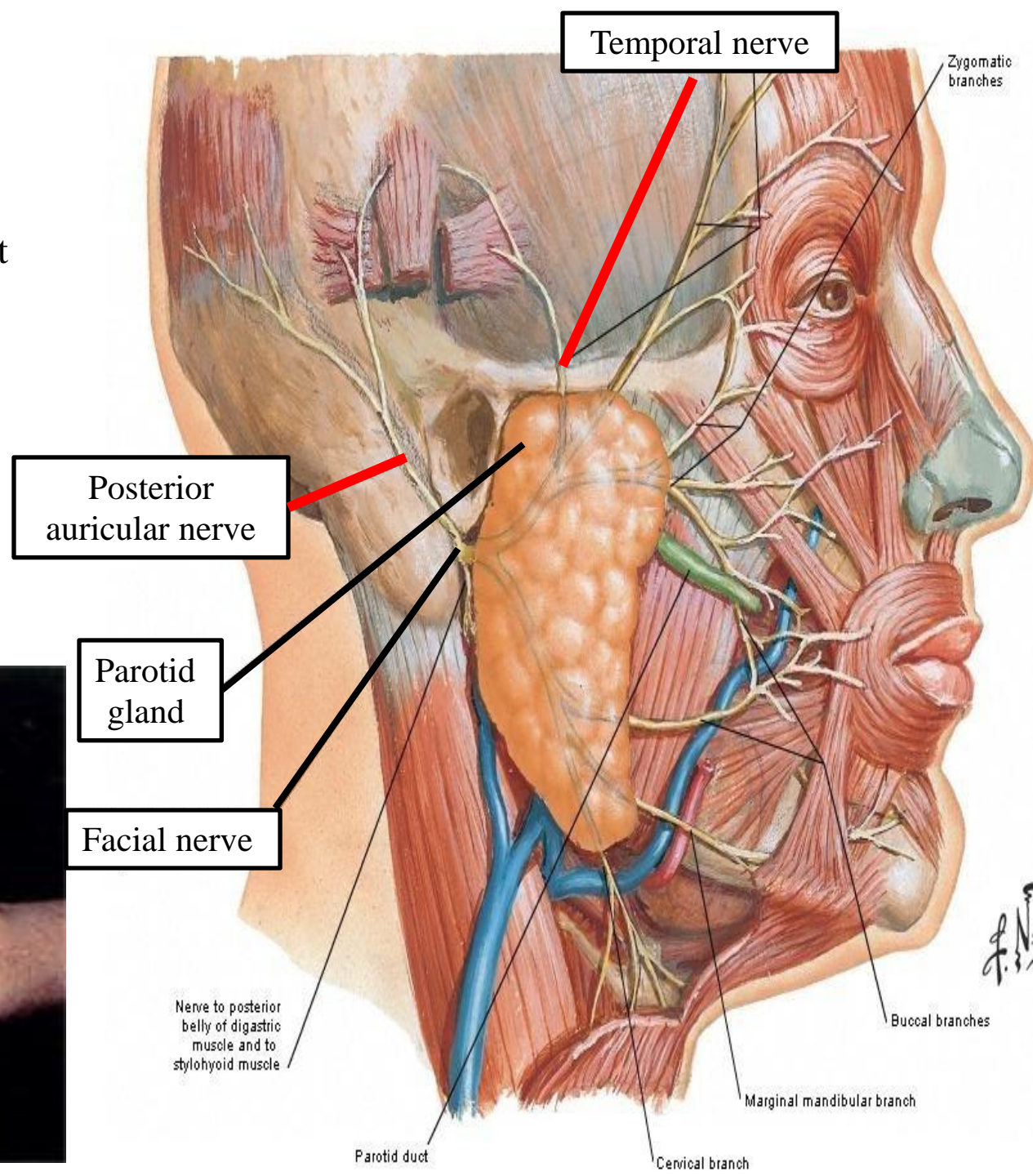
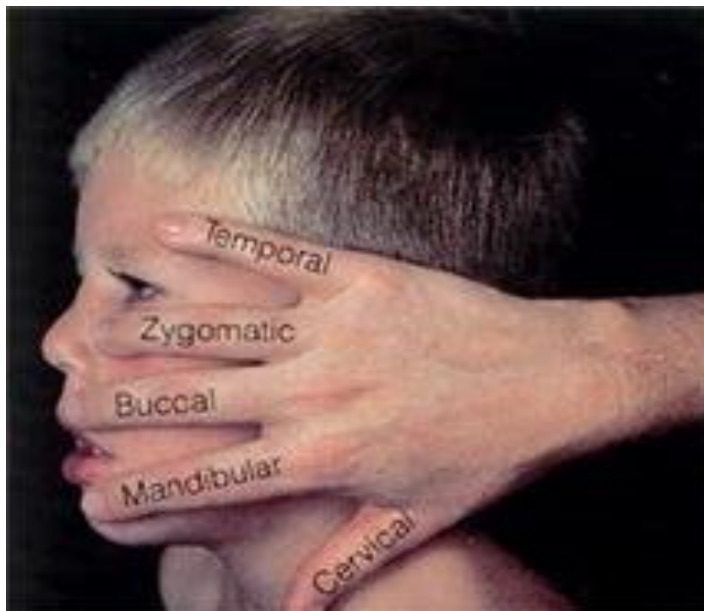

Stylomastoid foramen

Facial Nerve

As the facial nerve runs forward within the substance of the parotid salivary gland it divides into its five terminal branches:

- 1-The temporal
- 2-The zygomatic
- 3-The buccal
- 4-The mandibular
- 5-The cervical



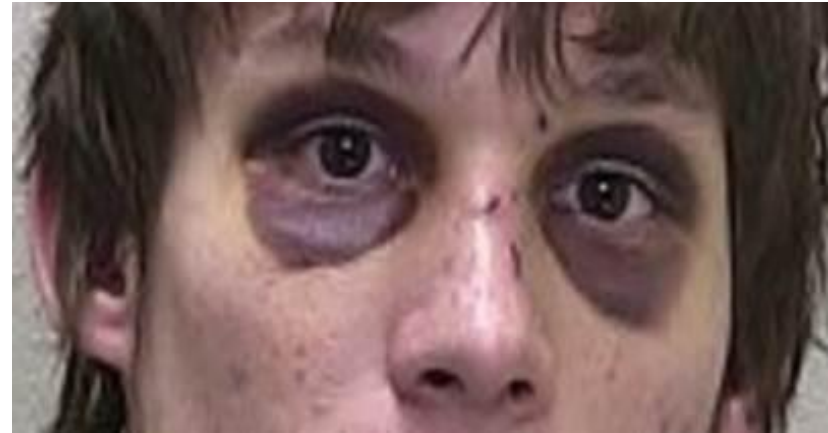4- Loose areolar tissue

The subaponeurotic space is the potential space beneath the epicranial aponeurosis and is filled with loose areolar tissue

Remember the attachment of Epicranial aponeurosis layer!!!
Frontalis muscle has no bony attachment



Blood accumulates in this layer spreads over the entire extent of the aponeurosis reaching the eyelid and presents as a **black eye**



Blow on the skull

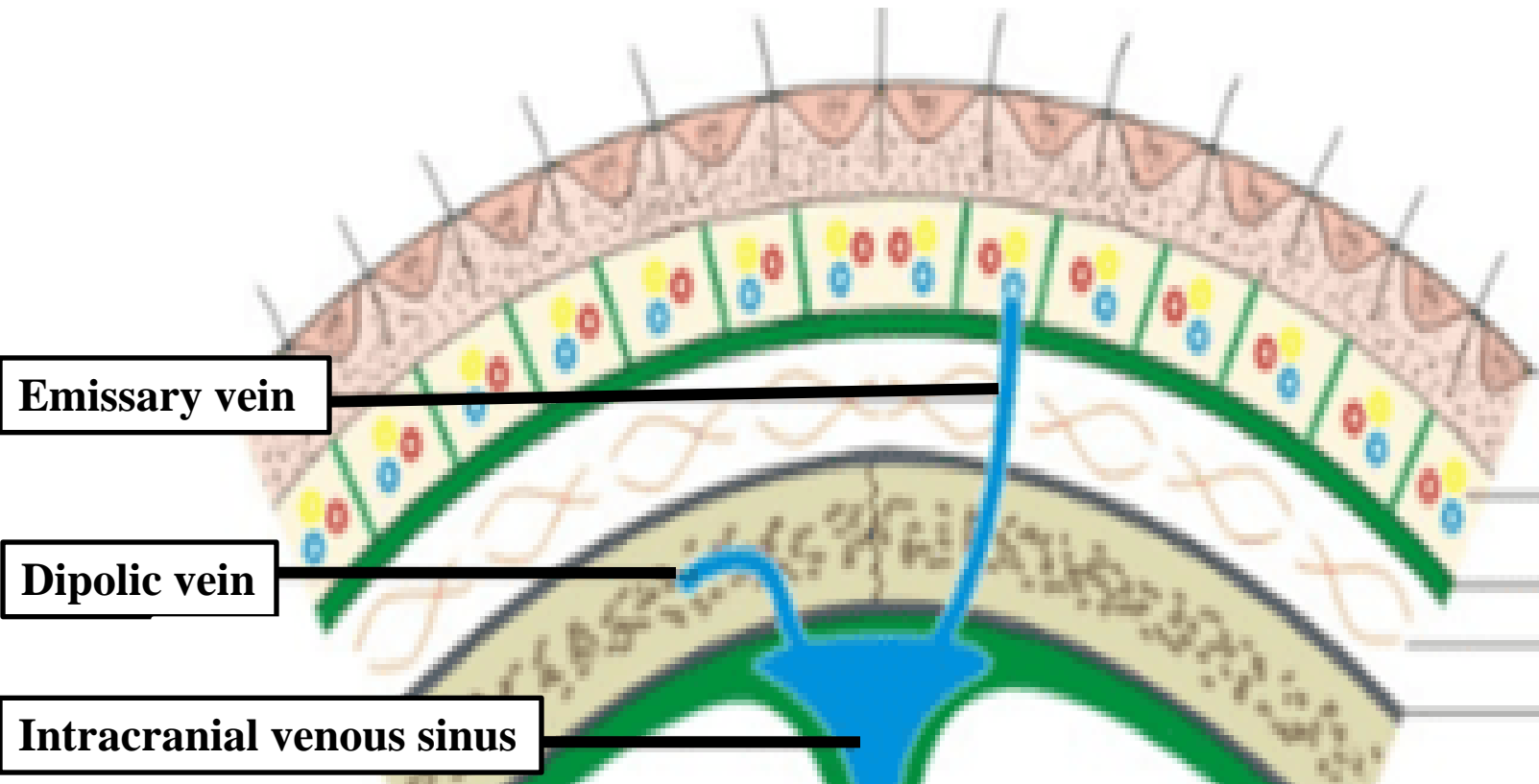
Hemorrhage in the 4th layer of the scalp may cause raccoon eye

The subaponeurotic space contains **emissary veins**

This layer is called the **dangerous area of the scalp**

Infections in the subaponeurotic space can spread to intracranial venous sinuses through emissary veins (valveless)

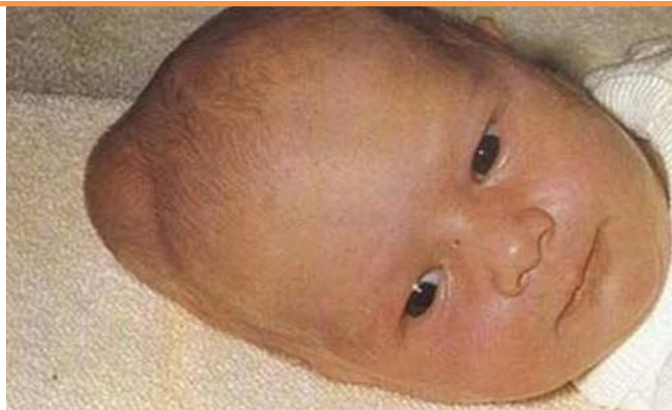Infection spreads by the emissary veins (valveless) to the skull bones, causing osteomyelitis



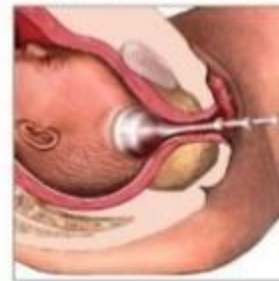5-Pericranium

- Is the periosteum covering the outer surface of the skull bones.
- Removable, except in the area of sutures
- The periosteum on the outer surface of the bones becomes continuous with the periosteum on the inner surface of the skull bones at the sutures .

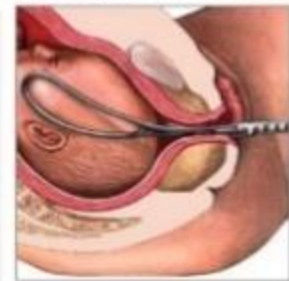THEREFORE if there is any fluid collection beneath the pericranium (Cephalhaematoma/ subperiosteal hematoma) it will take the shape of the related bone



Vacuum-assisted birth



Forceps-assisted birth



Nerve supply of the scalp

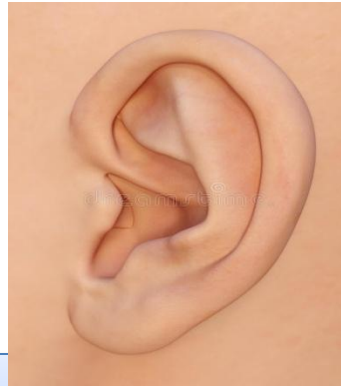

Nerve supply of the scalp

10 sets of nerves on each side of the scalp

5 in front the auricle

5 behind the auricle



4 sensory
1 motor

4 sensory
1 motor

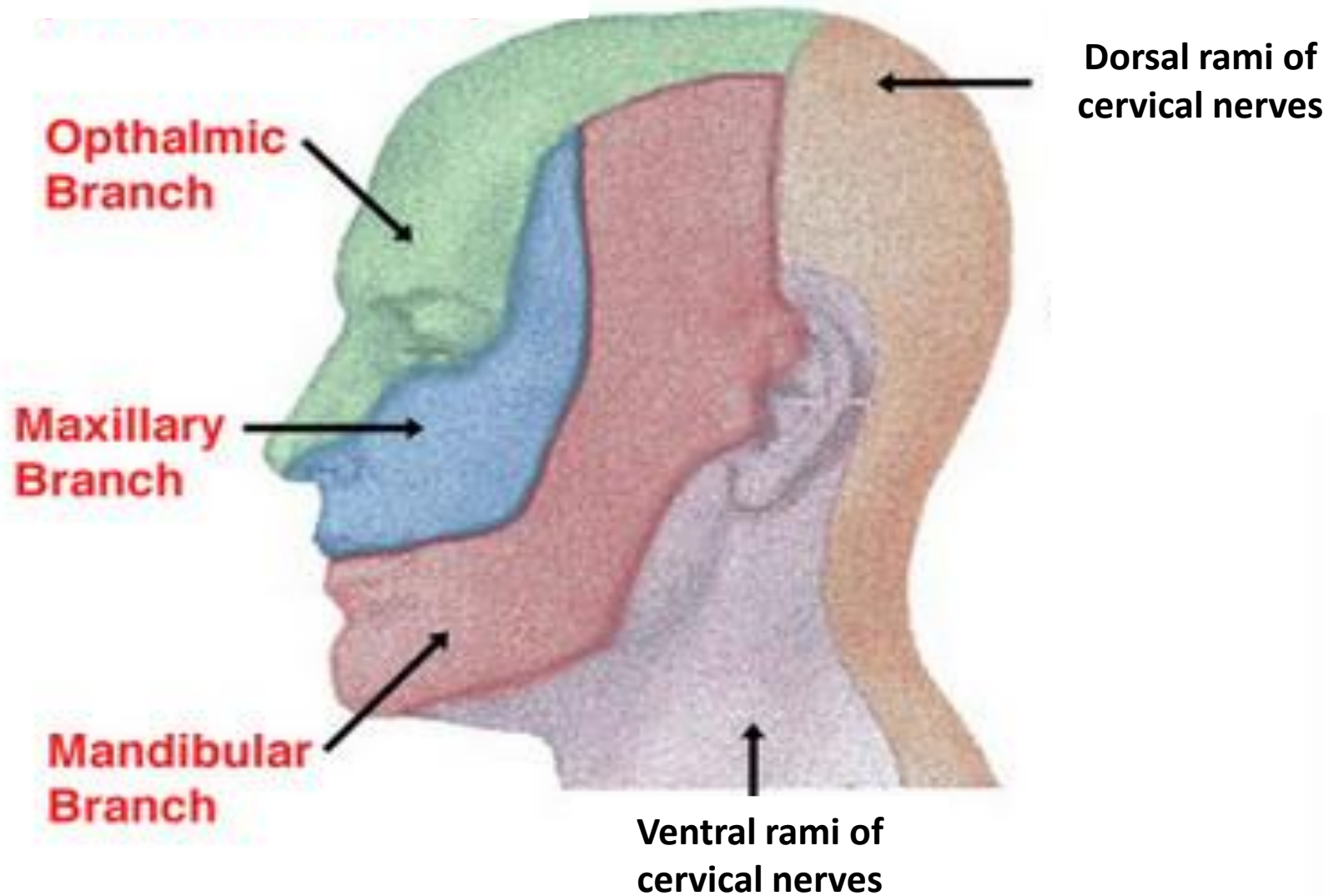
Nerves **in front** the auricle

- 1- Supratrochlear nerve
- 2- Supraorbital nerve
- 3- Zygomaticotemporal nerve
- 4- Auriculotemporal nerve
- 5- **Temporal branch of facial nerve**

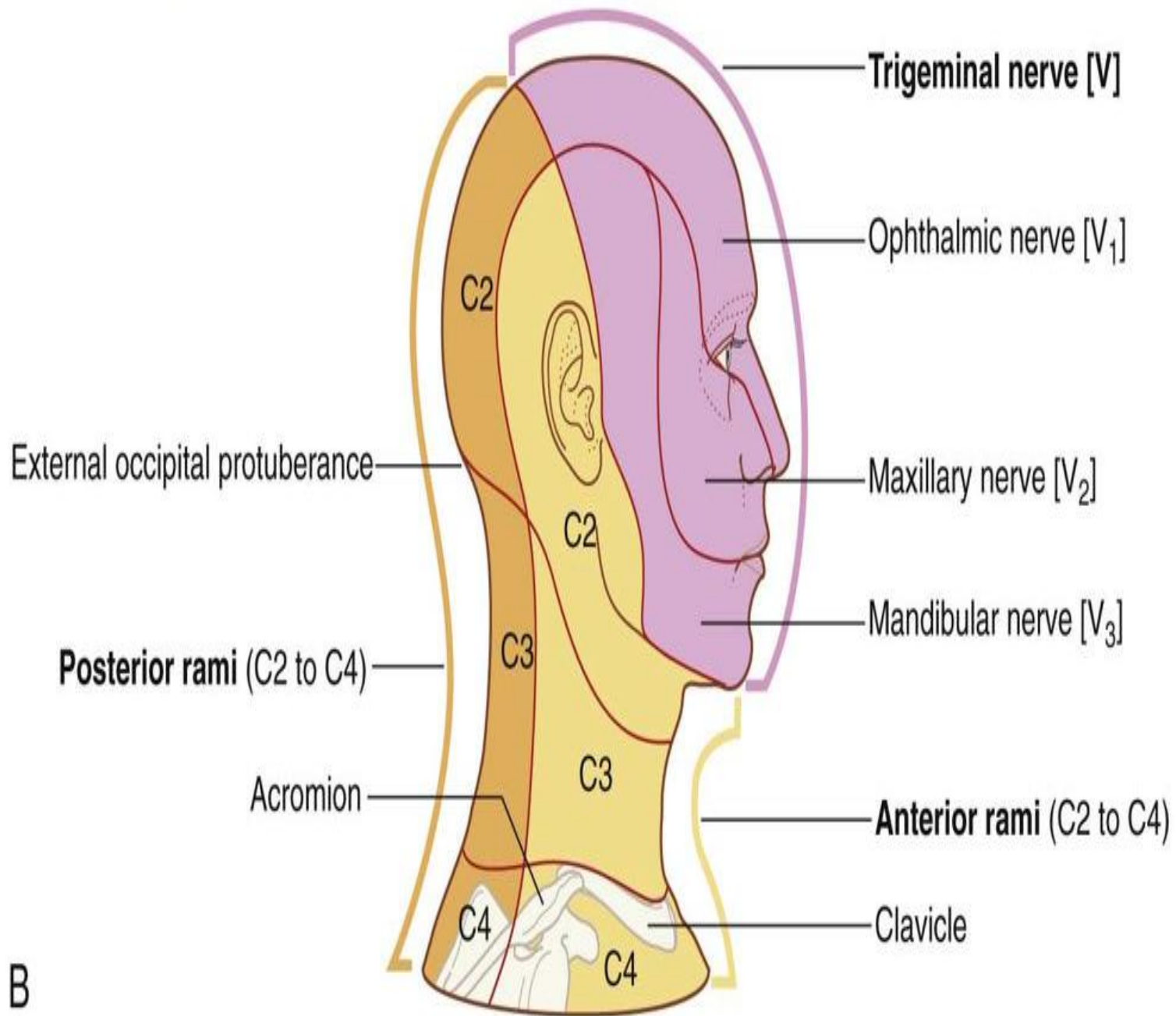
Nerves **behind** the auricle

- 1- Great auricular nerve (ant rami C2 C3)
- 2- Lesser occipital nerve (ant rami C2)
- 3- Great occipital nerve (post rami C2)
- 4- Third occipital nerve (post rami C3)
- 5- **Posterior auricular branch of facial nerve**

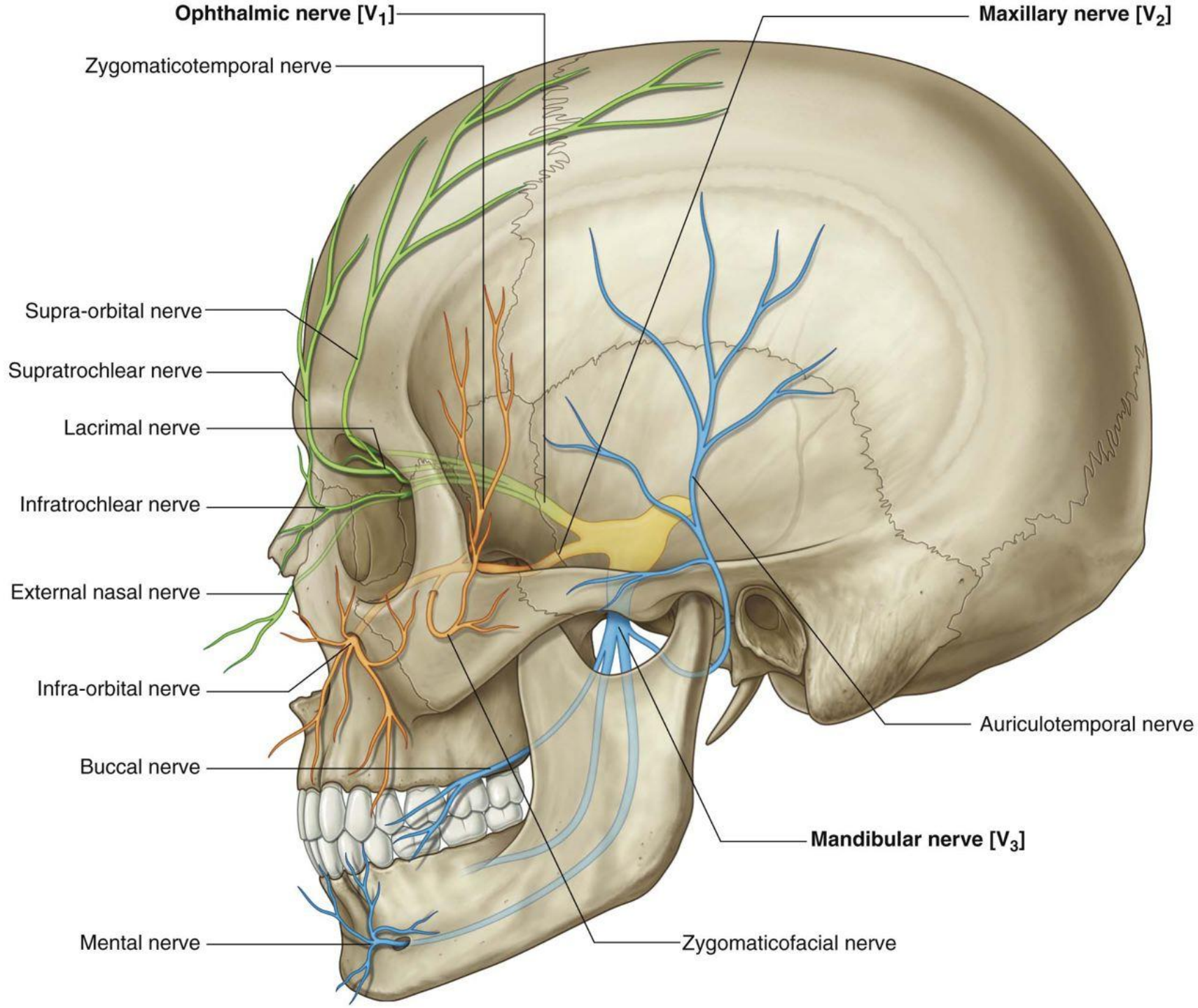
Nerve supply of the scalp



A



B



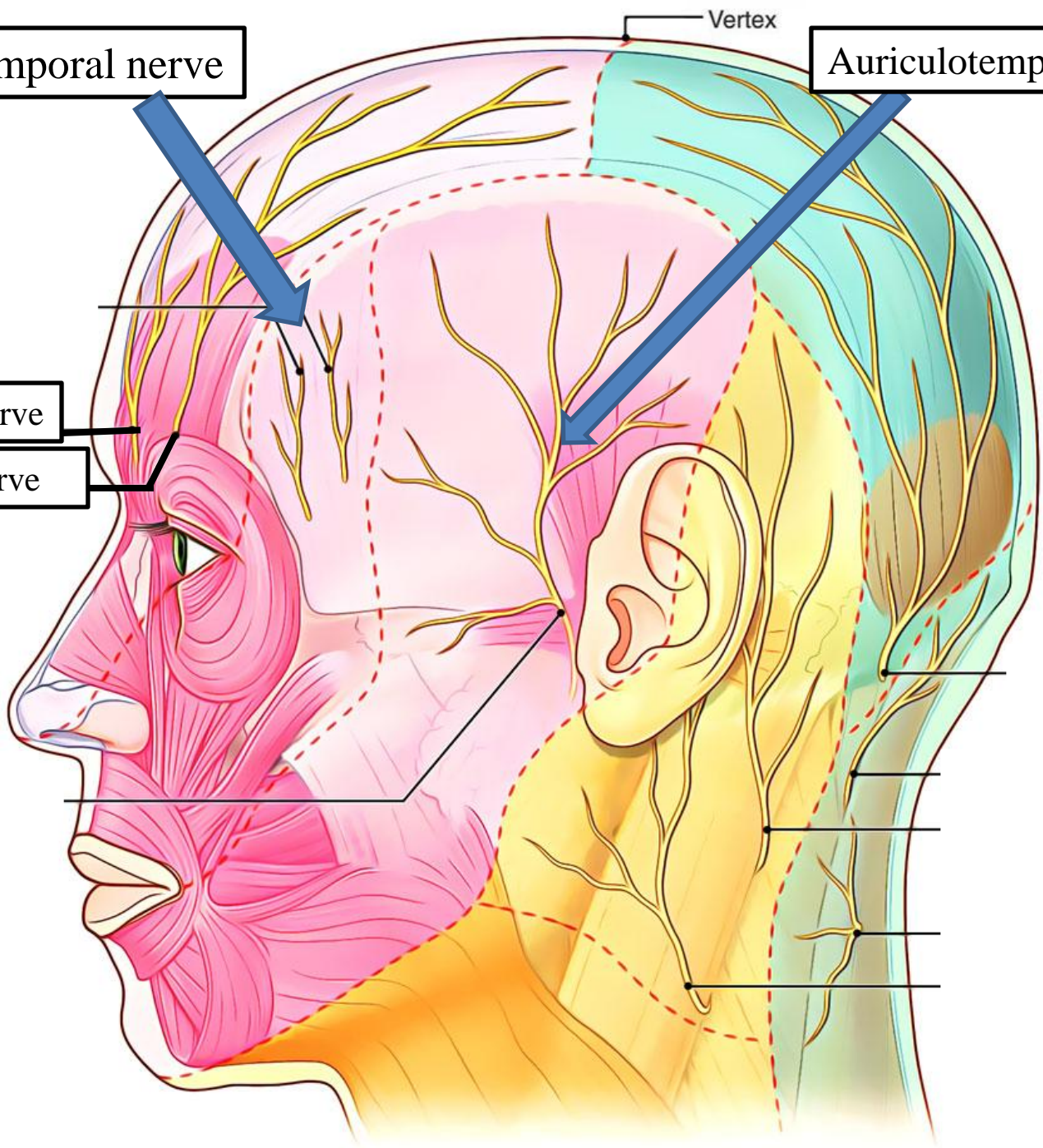
Zygomaticotemporal nerve

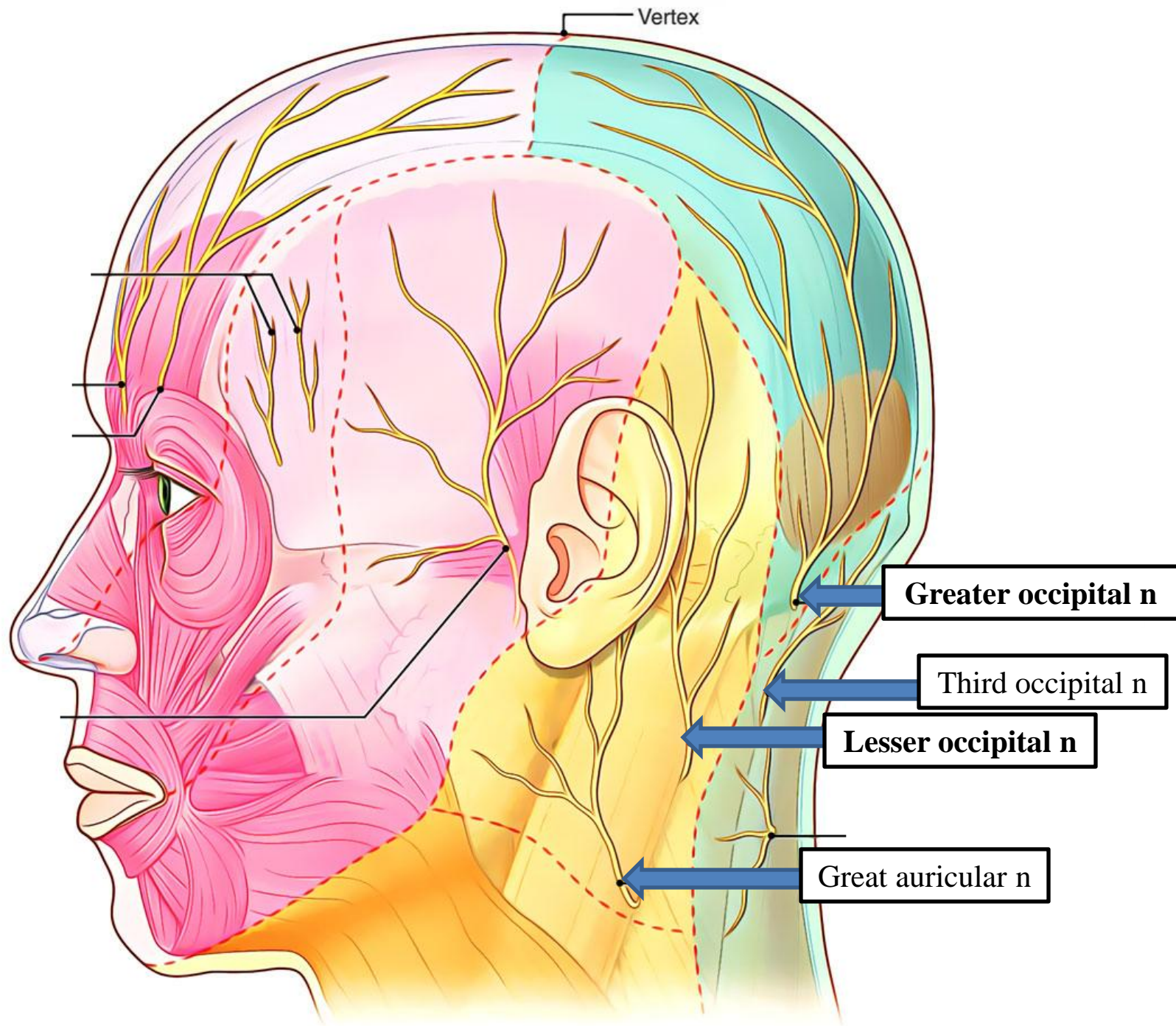
Auriculotemporal nerve

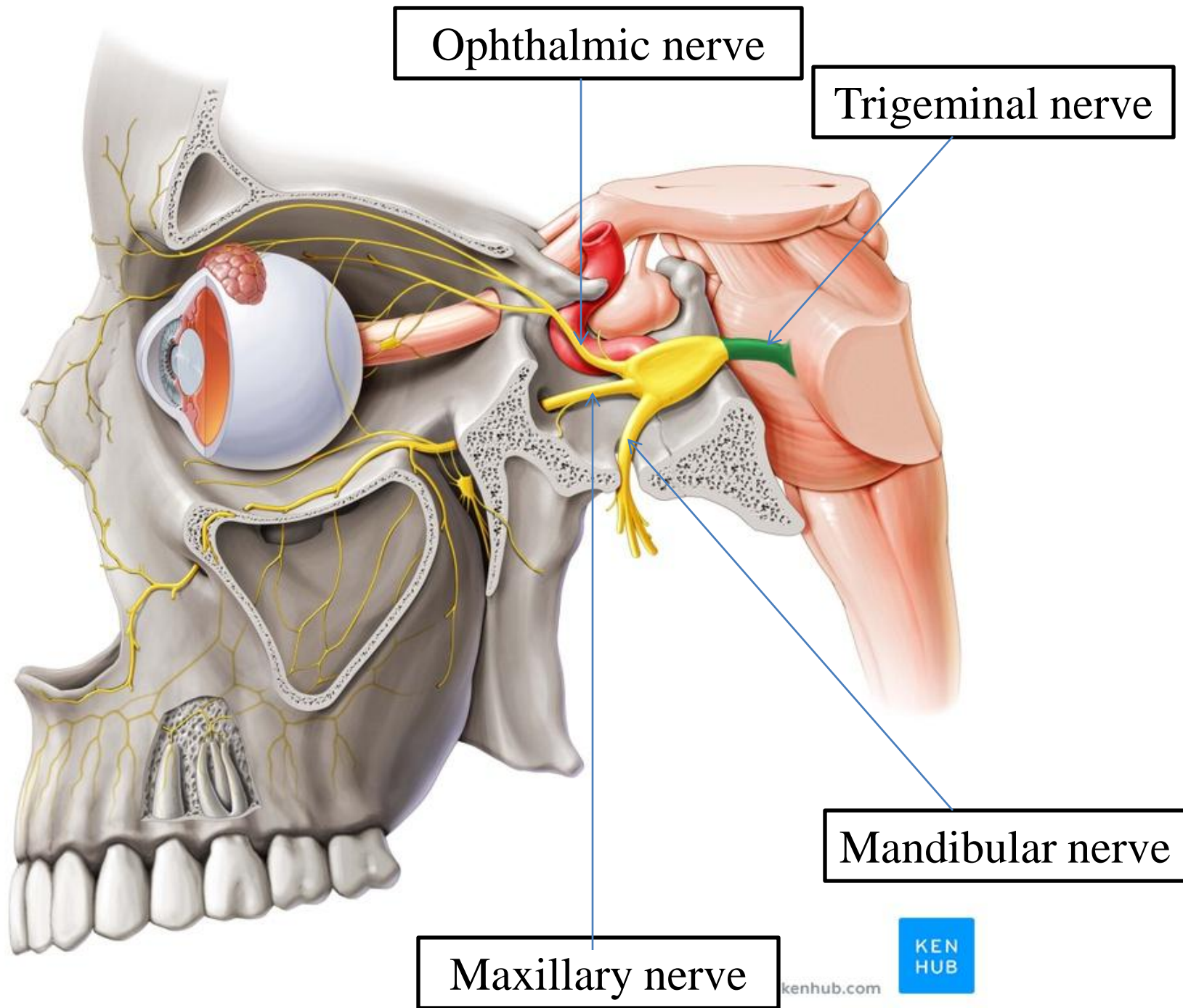
Vertex

Supratrochlear nerve

Supraorbital nerve







Ophthalmic nerve

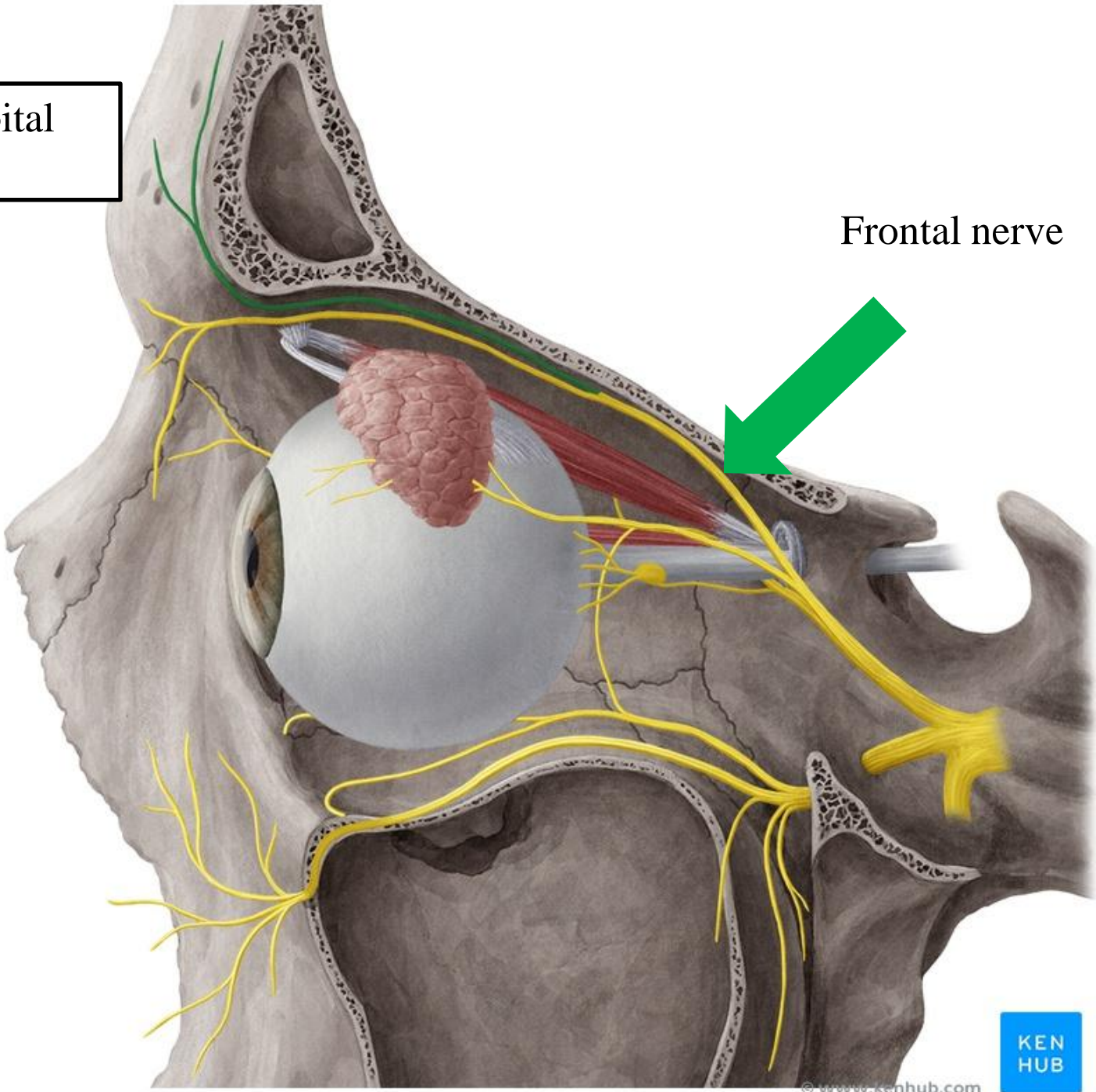
Trigeminal nerve

Mandibular nerve

Maxillary nerve

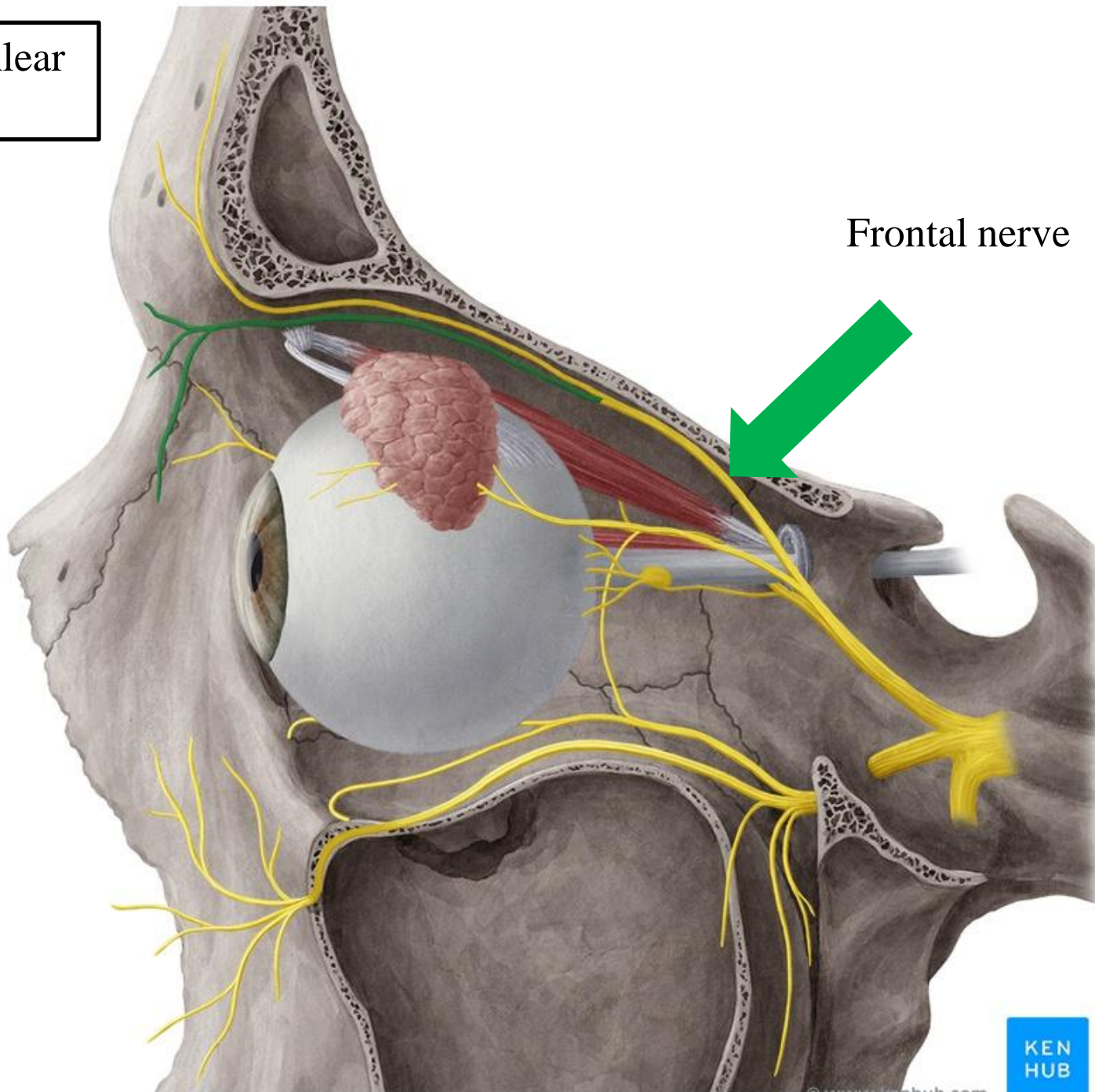
Supraorbital
nerve

Frontal nerve

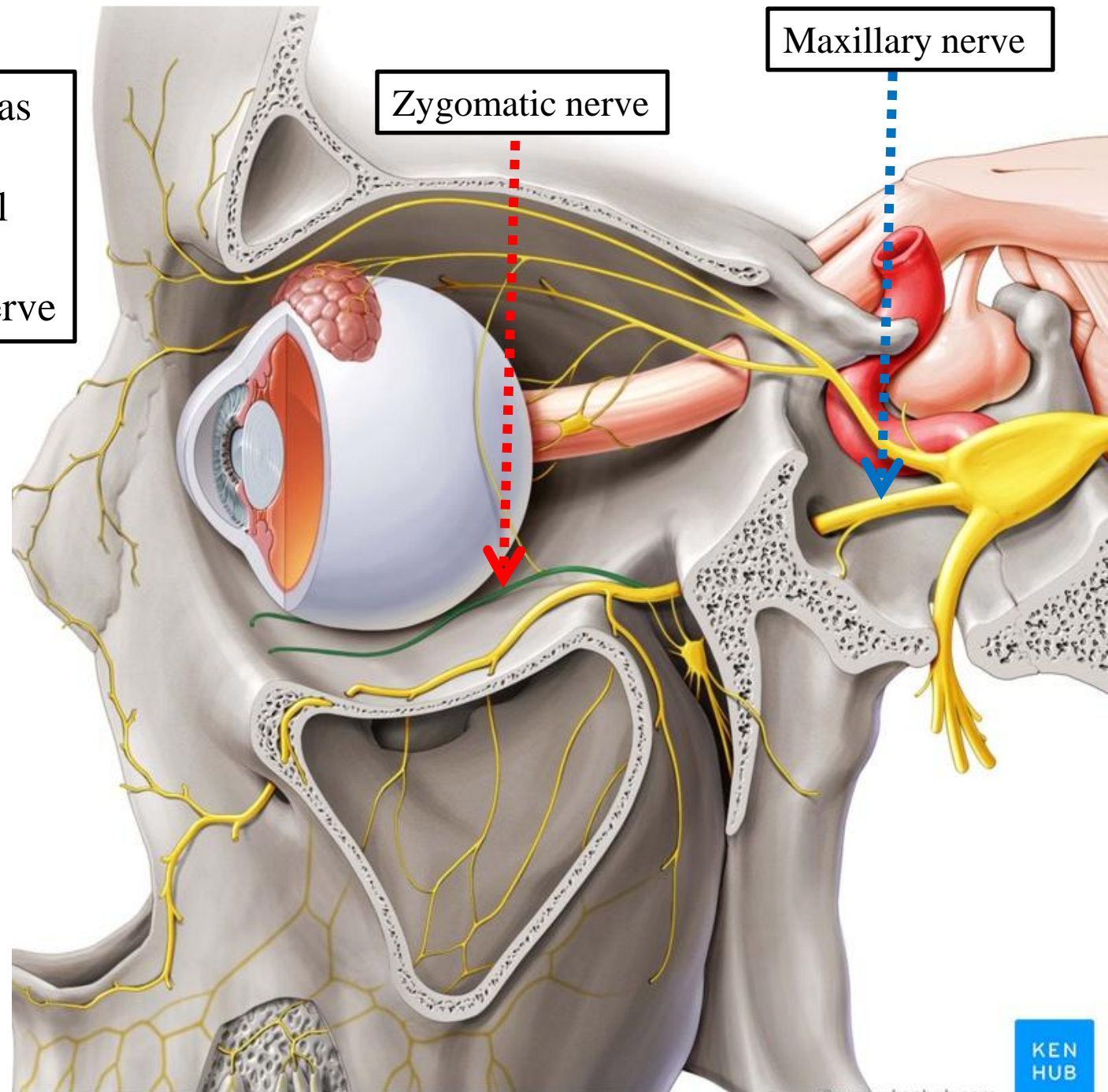


Supratrochlear
nerve

Frontal nerve



The zygomatic nerve has two branches:
1- Zygomaticotemporal nerve
2- Zygomaticofacial nerve

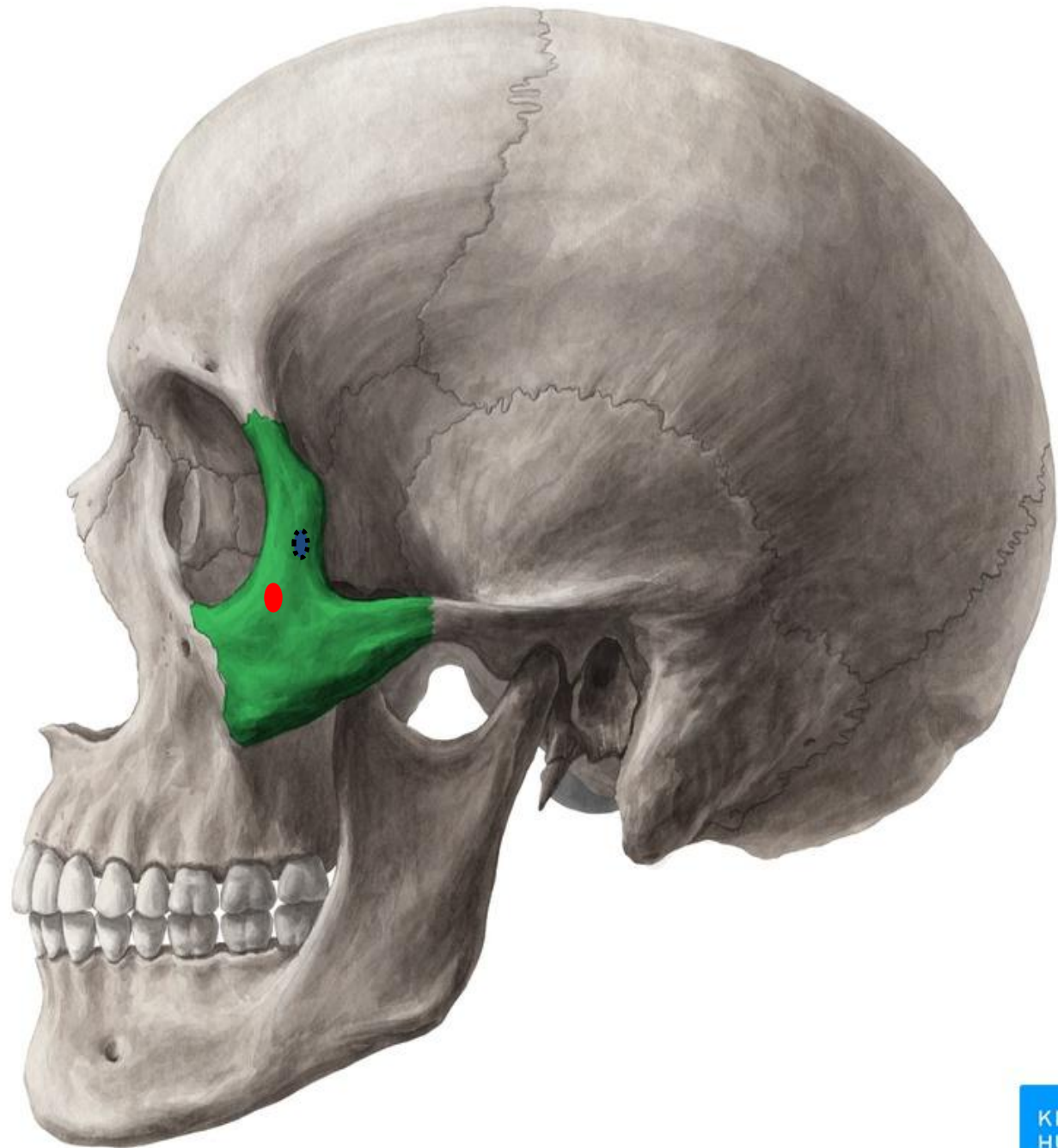


1- The zygomaticotemporal nerve

- A branch of the zygomatic nerve (maxillary nerve)
- Emerges in the temporal fossa through a small foramen on the posterior surface of the zygomatic bone. It supplies the skin over the temple
(Zygomaticotemporal foramen)

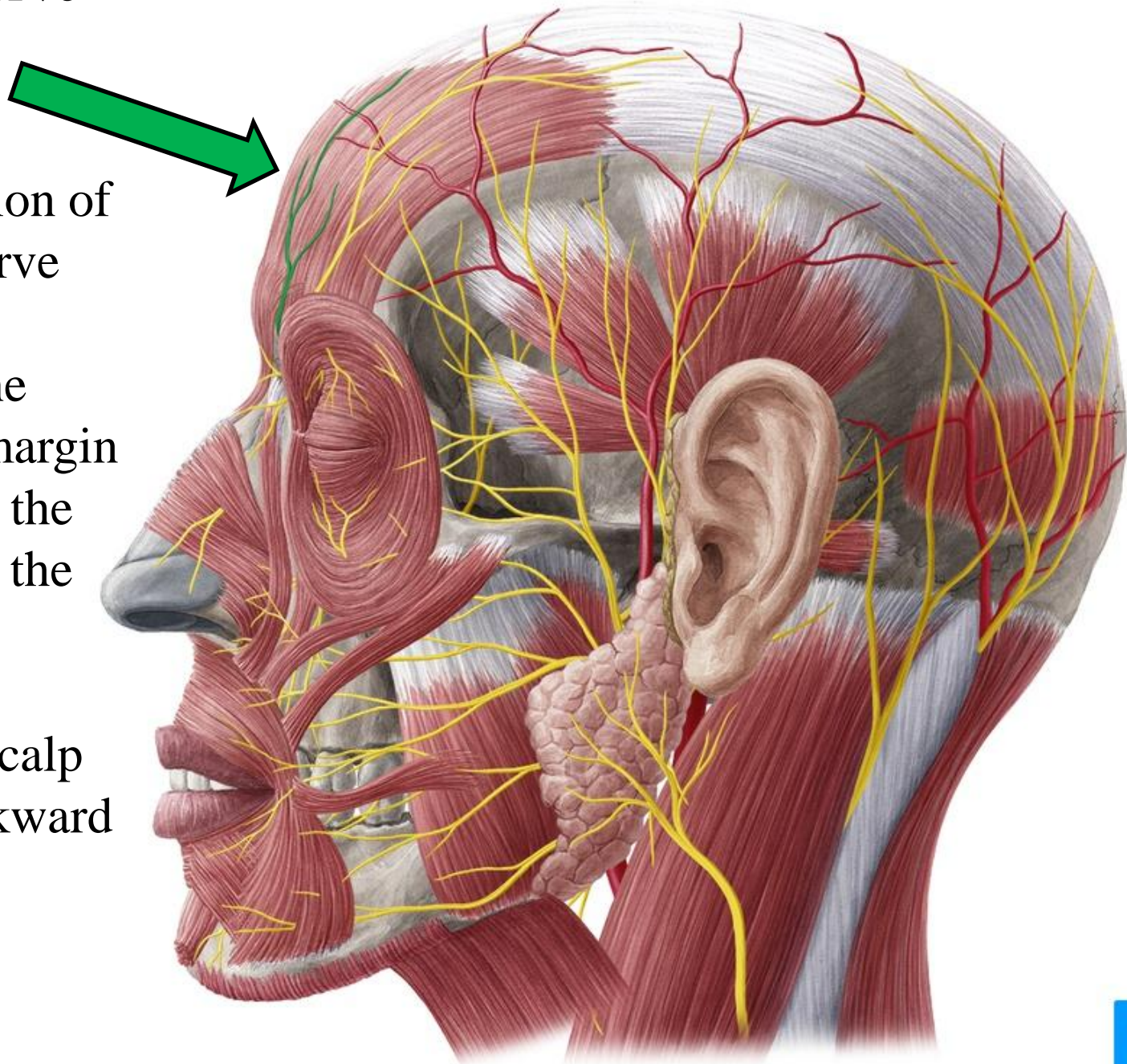
2- The zygomaticofacial nerve

- A branch of the zygomatic nerve (maxillary nerve)
- Passes onto the face through a small foramen on the anterior side of the zygomatic bone. It supplies the skin over the prominence of the cheek
(Zygomaticofacial foramen)



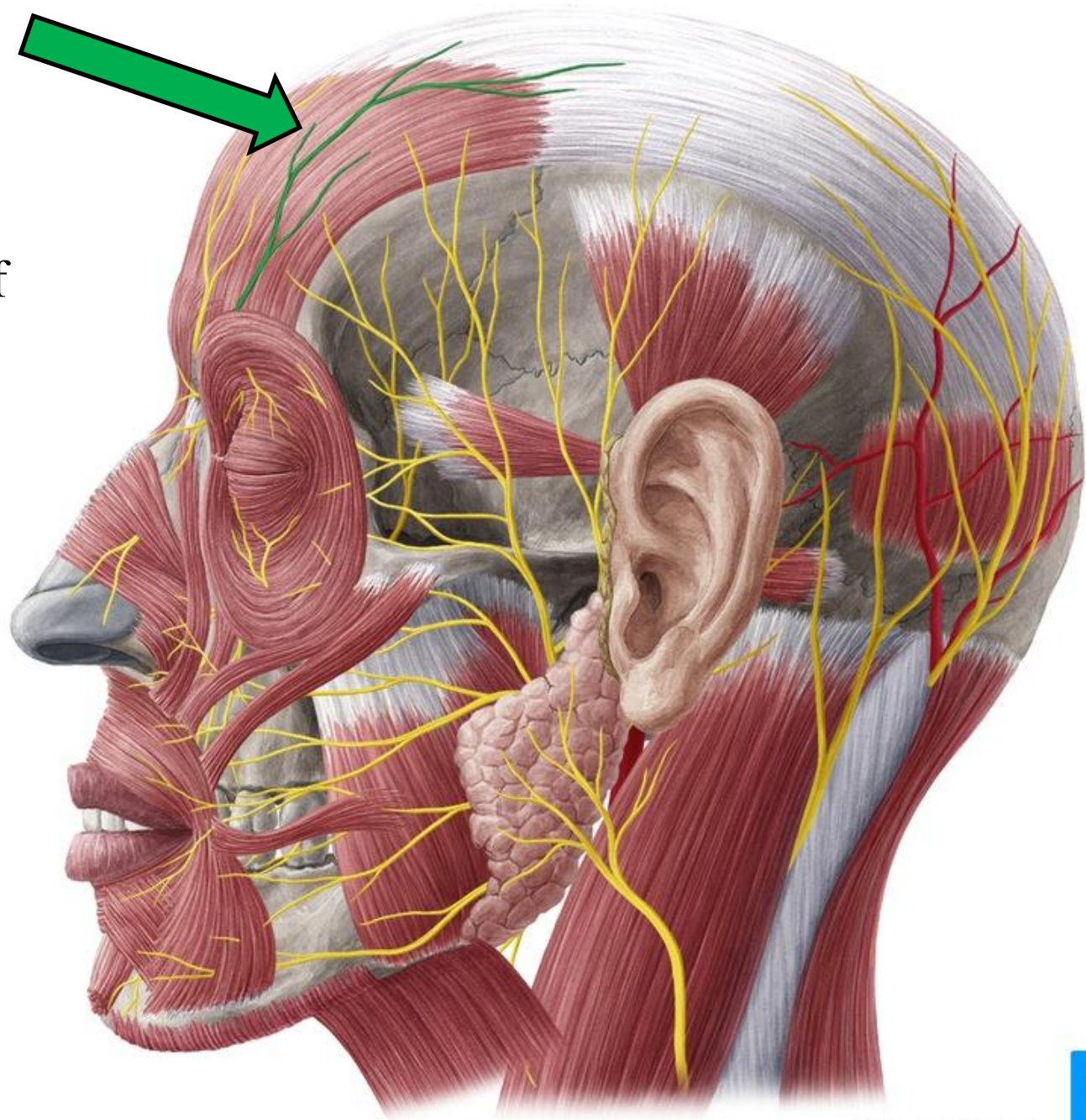
Supratrochlear nerve

- A branch of the ophthalmic division of the trigeminal nerve
- Winds around the superior orbital margin and ascends over the forehead close to the median plane
- It supplies the scalp nearly as far backward as the vertex.



Supraorbital nerve

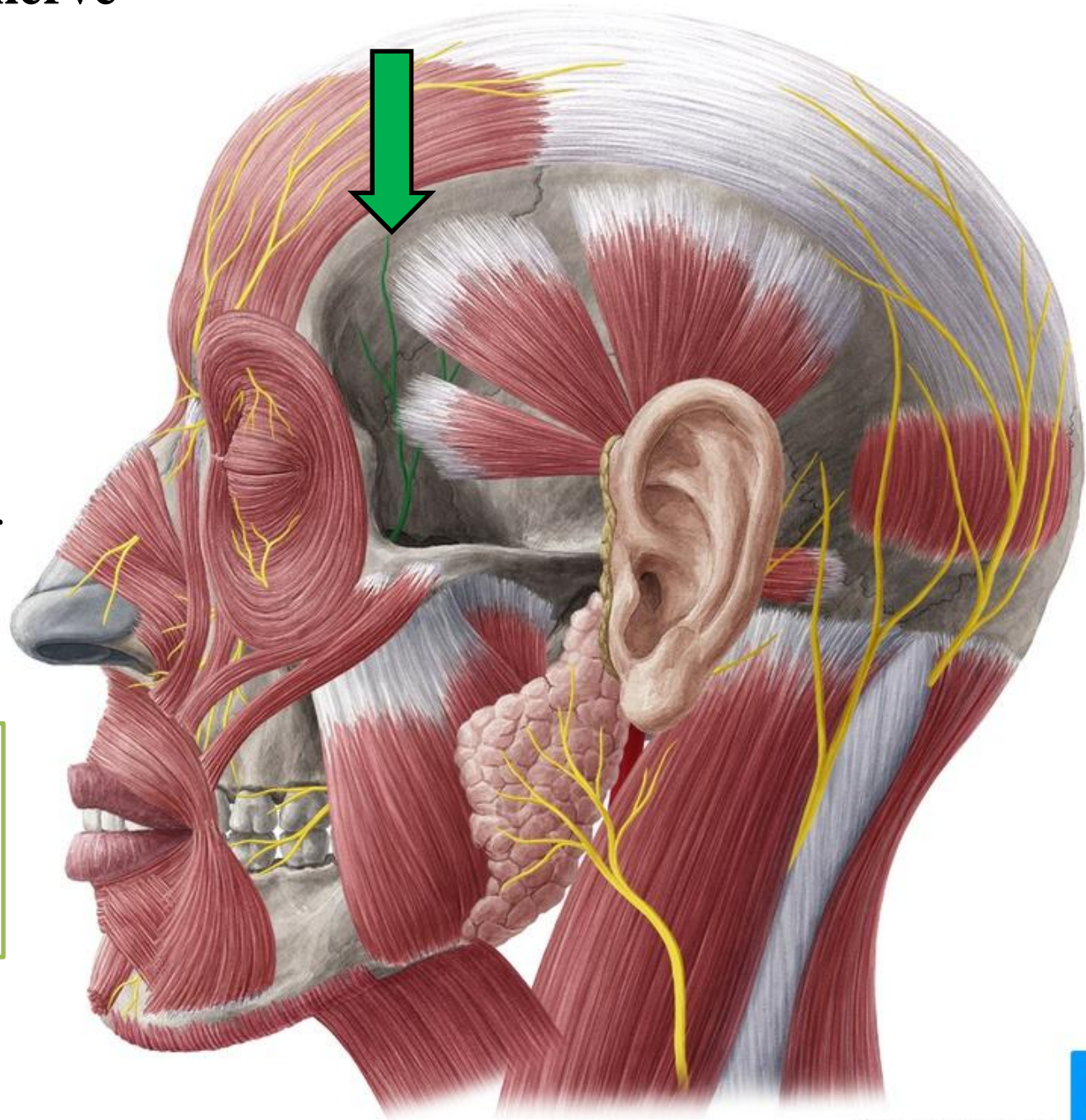
- A branch of the ophthalmic division of the trigeminal nerve
- Passes through the supraorbital foramen and ascends over the forehead
- It supplies the scalp as far backward as the vertex.



Zygomaticotemporal nerve

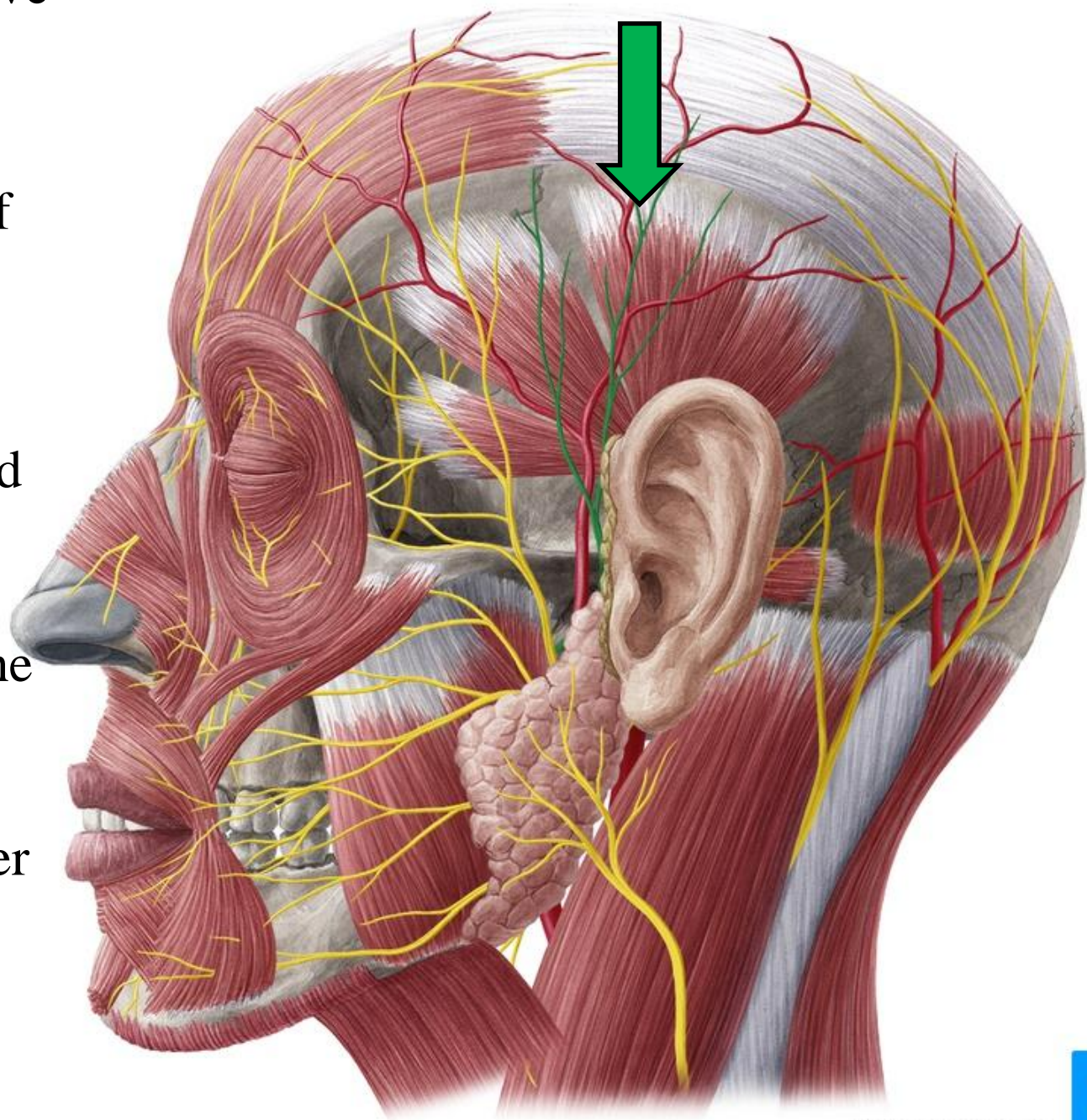
- A branch of the maxillary division of the trigeminal nerve
- Supplies the skin over the temporal region

Zygomaticotemporal foramen (present on the posterior surface of zygomatic bone)



Auriculotemporal nerve

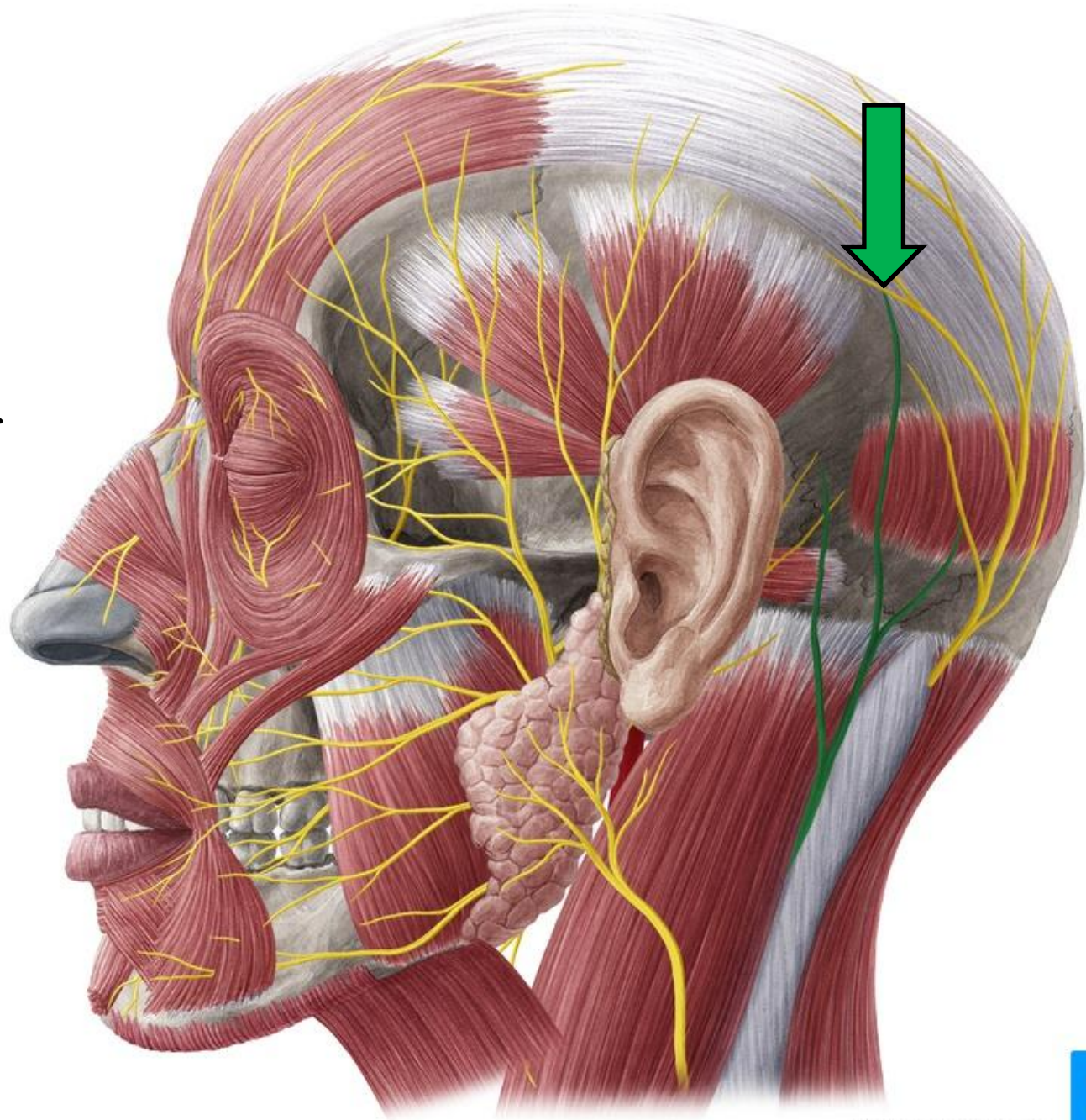
- A branch of the mandibular division of the trigeminal nerve
- Emerges from the upper border of parotid gland
- Ascends in front of the auricle
- Supplies the skin over the temporal region.



Lesser occipital nerve

-A branch of the cervical plexus (C2)

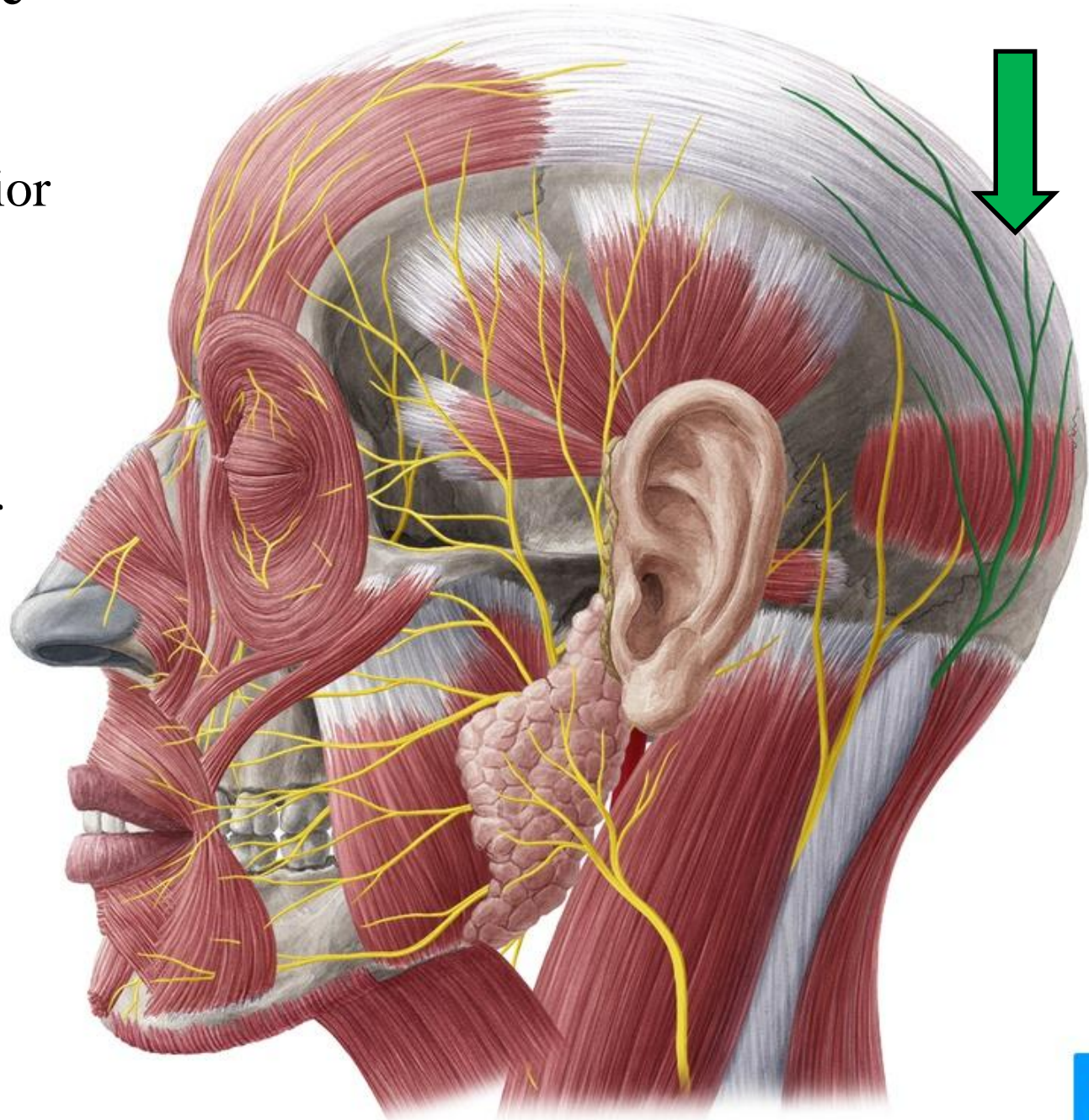
- Supplies the skin over the lateral part of scalp behind the auricle



Greater occipital nerve

-A branch of the posterior ramus of the second cervical nerve (C2)

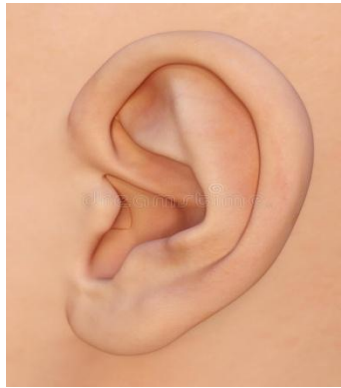- Supplies the skin over the back of scalp as far forward as the vertex



Blood supply of the scalp

5 sets of arteries on each side of the scalp

3 in front of the auricle

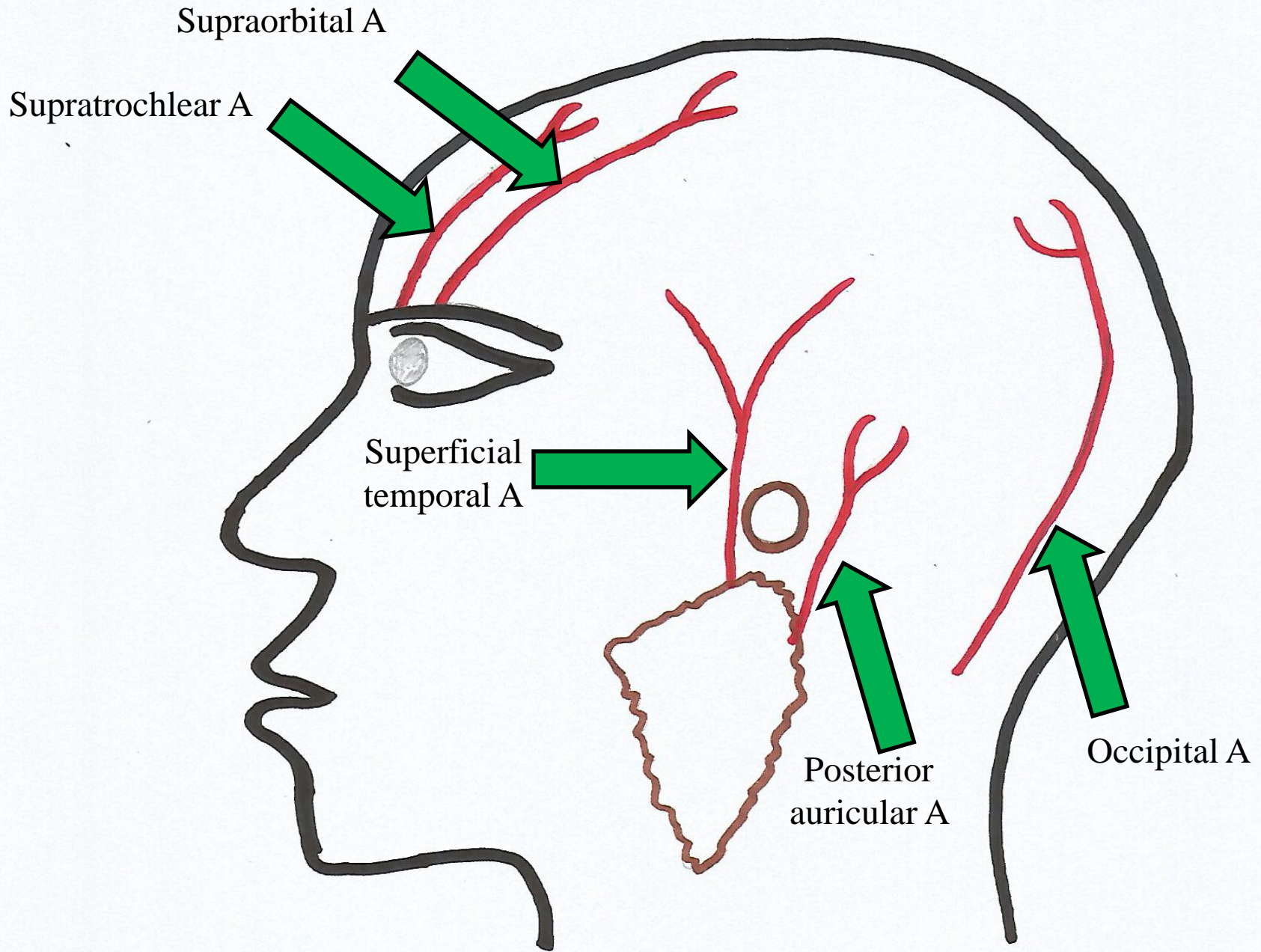


2 behind the auricle

Out of 5

2 arteries (indirectly from internal carotid artery)

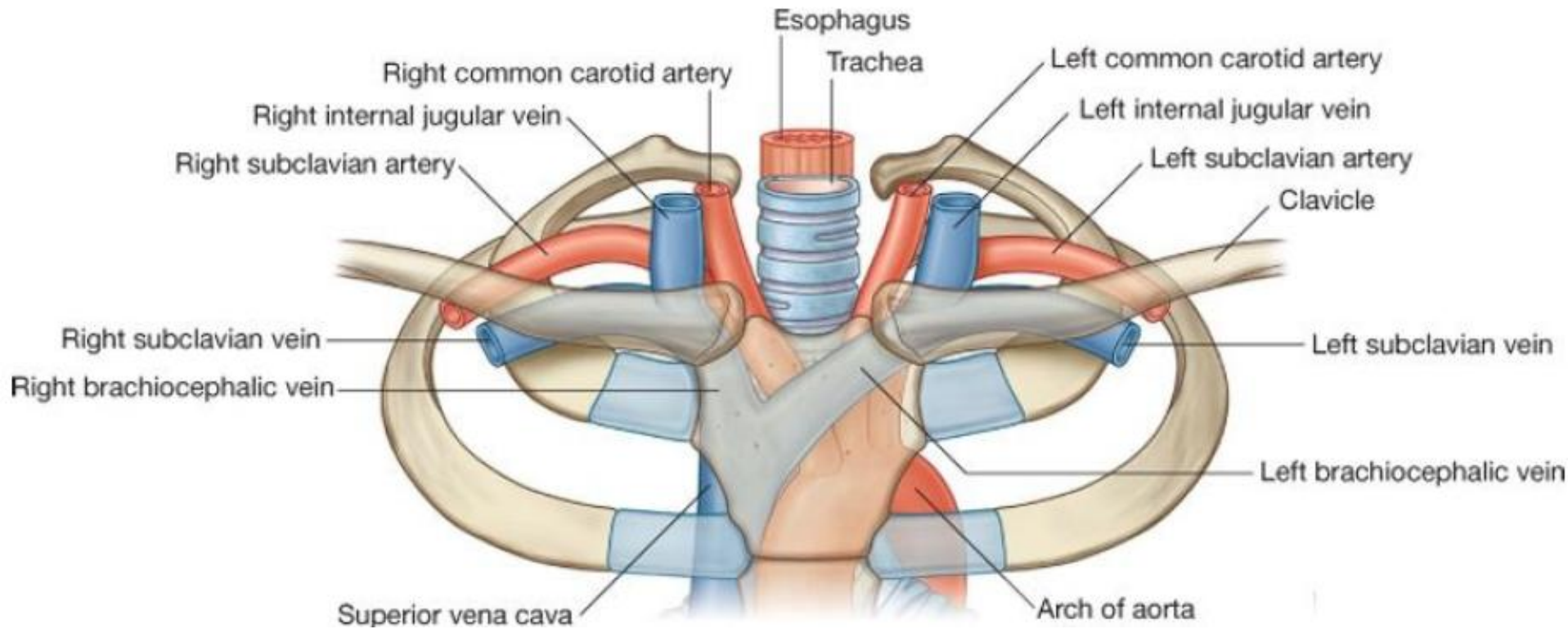
3 arteries (directly from the external carotid artery)



Blood supply of the scalp

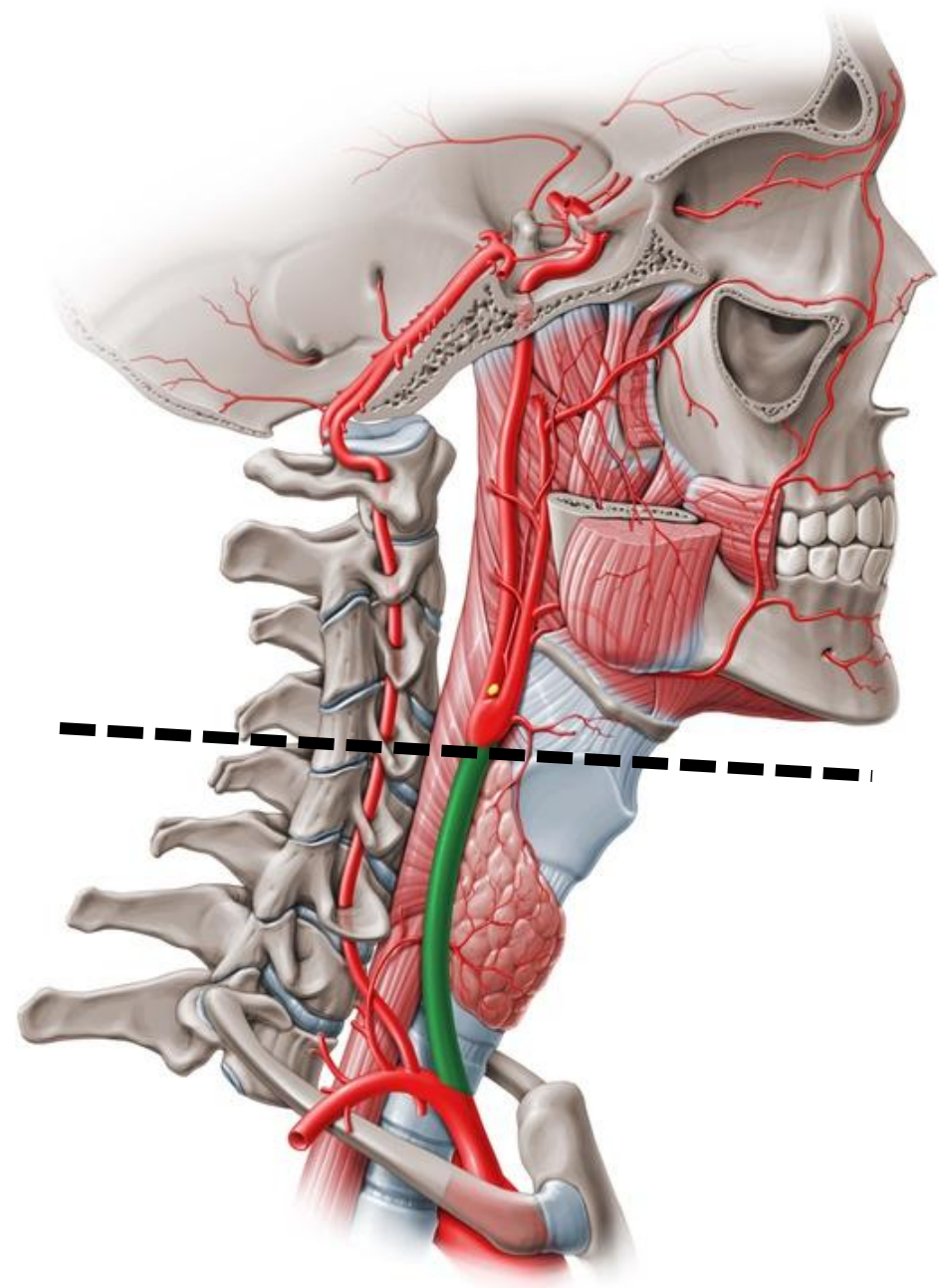
- 1- Supratrochlear-----Ophthalmic artery-----ICA
- 2- Supraorbital -----Ophthalmic artery-----ICA
- 3- Superficial temporal artery-----ECA
- 4- Posterior auricular artery-----ECA
- 5- Occipital artery-----ECA

Common carotid artery



- Right common carotid: from the brachiocephalic artery
- Left common carotid artery: from arch of the aorta
- **Begins:** sternoclavicular joint
- **Ends:** upper border of the thyroid cartilage (C4).
- **Divisions:** External and internal carotid arteries

Common carotid artery



Internal carotid artery

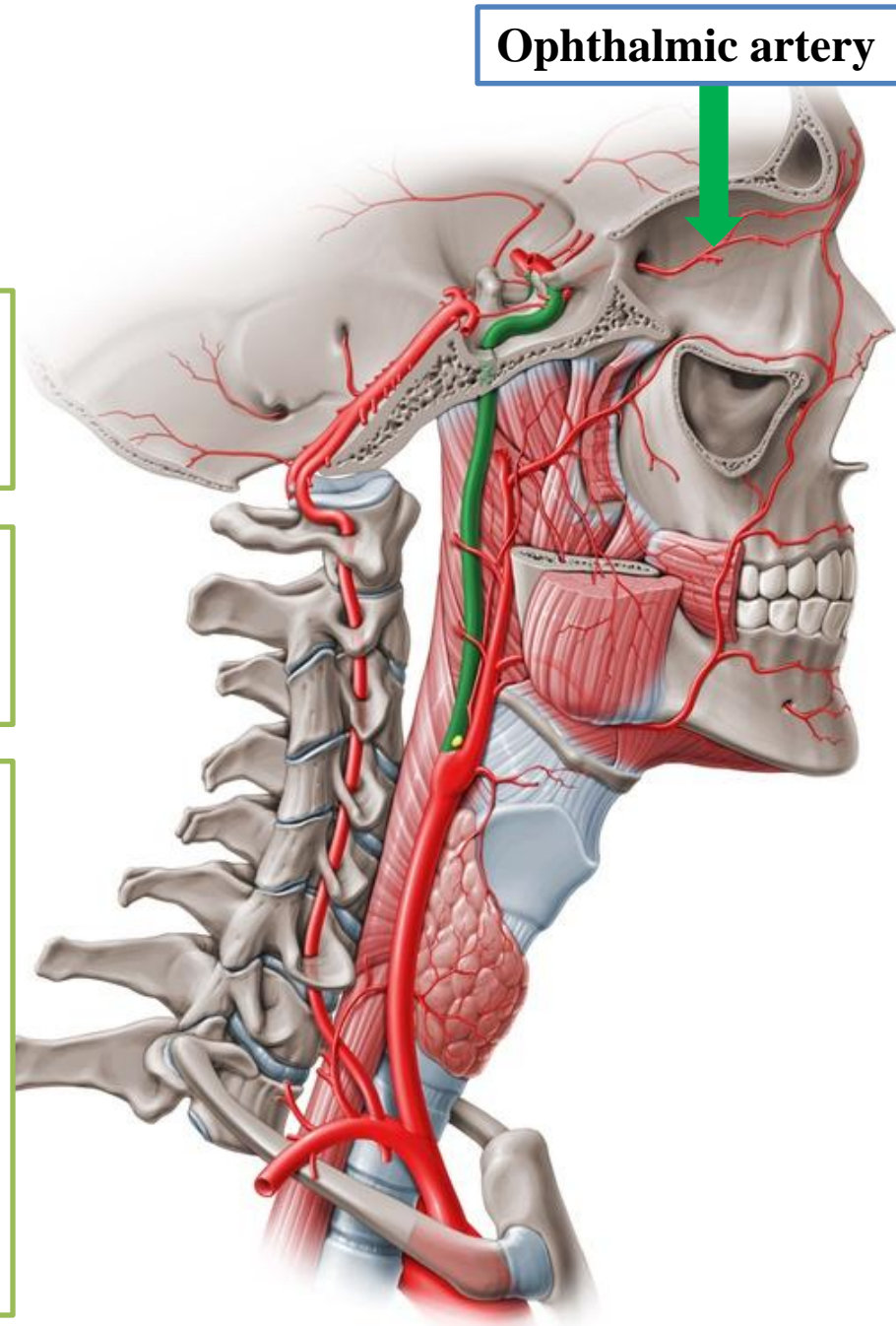
Has no branches in the neck

Enters the carotid canal in the skull

Ophthalmic artery is one of its branches

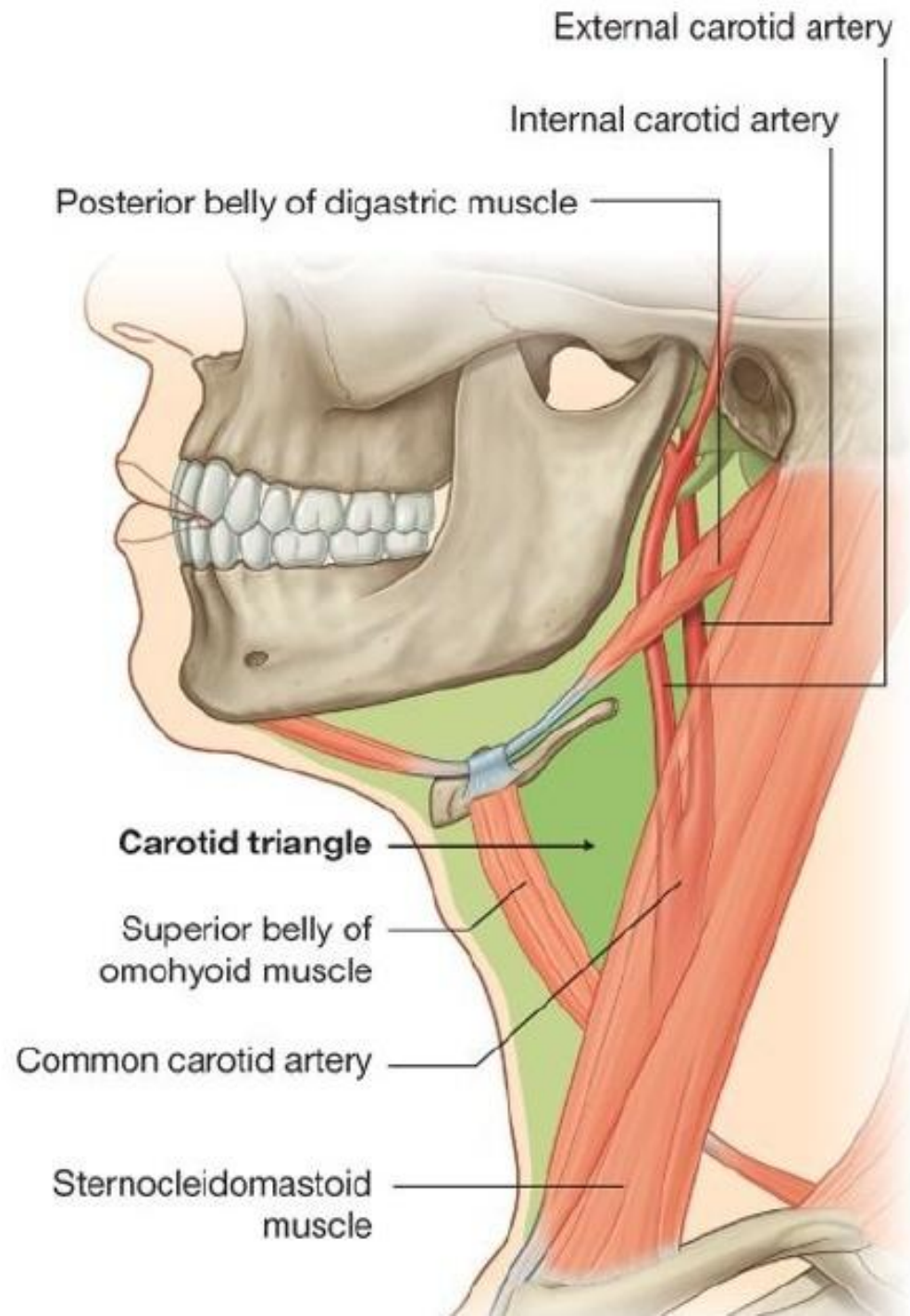
Ophthalmic artery enters the orbit through optic canal

It gives two branches:
1- Supraorbital artery
2- Supratrochlear artery



External carotid artery

Medial to the internal carotid artery, then passes backward and lateral to it.



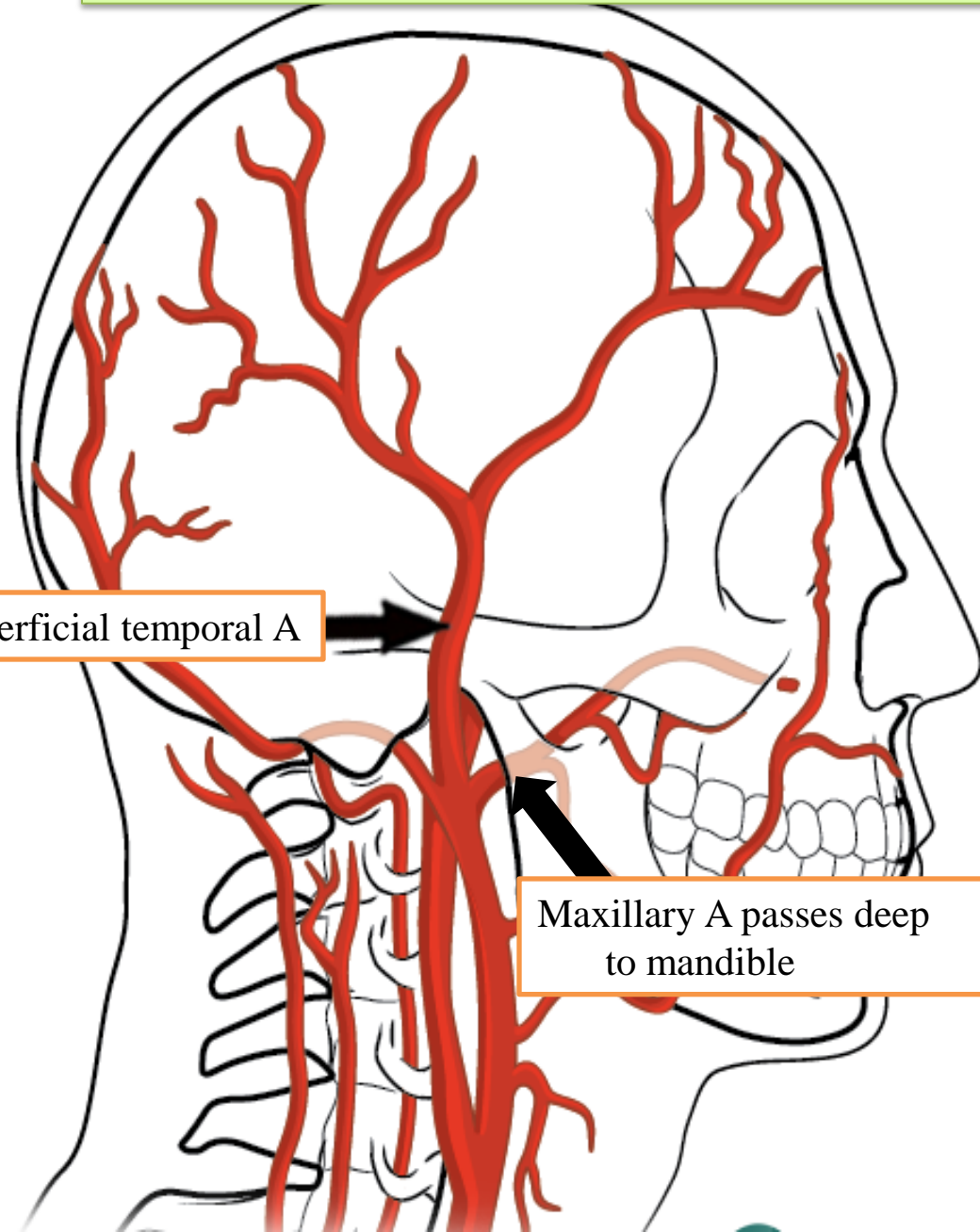
Some American Ladies Find Our Petra So Magnificent

External carotid artery

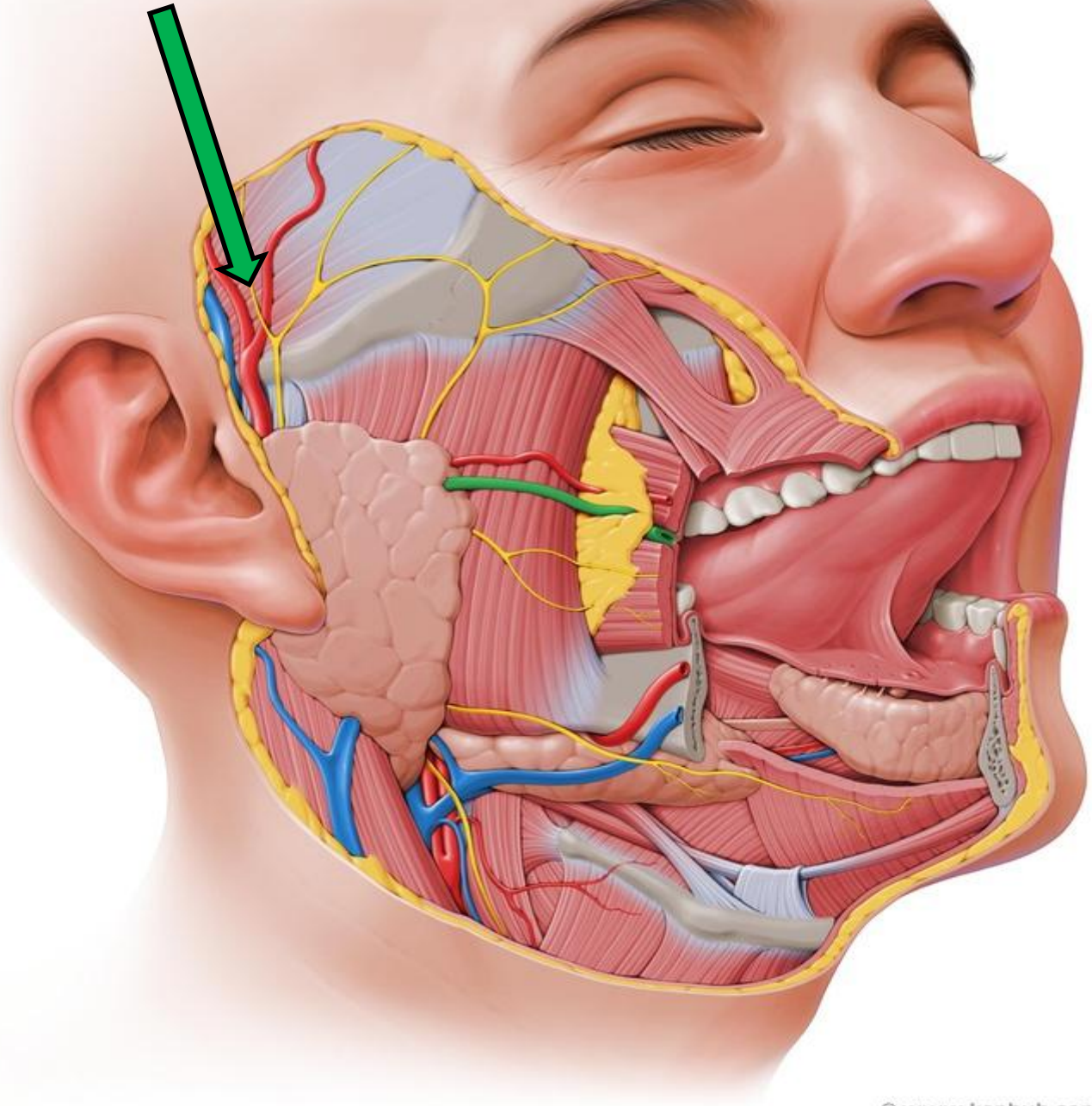
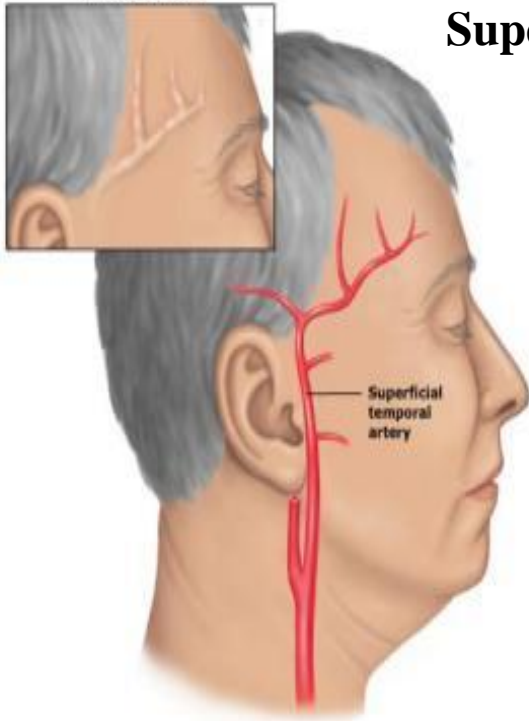
❖ Branches:

- a. Superior thyroid artery
- b. Ascending pharyngeal artery
- c. Lingual artery
- d. Facial artery
- e. **Occipital artery**
- f. **Posterior auricular artery**
- g. **Superficial temporal artery**
- h. **Maxillary artery**

These are the two terminal branches of ECA



Superficial temporal artery

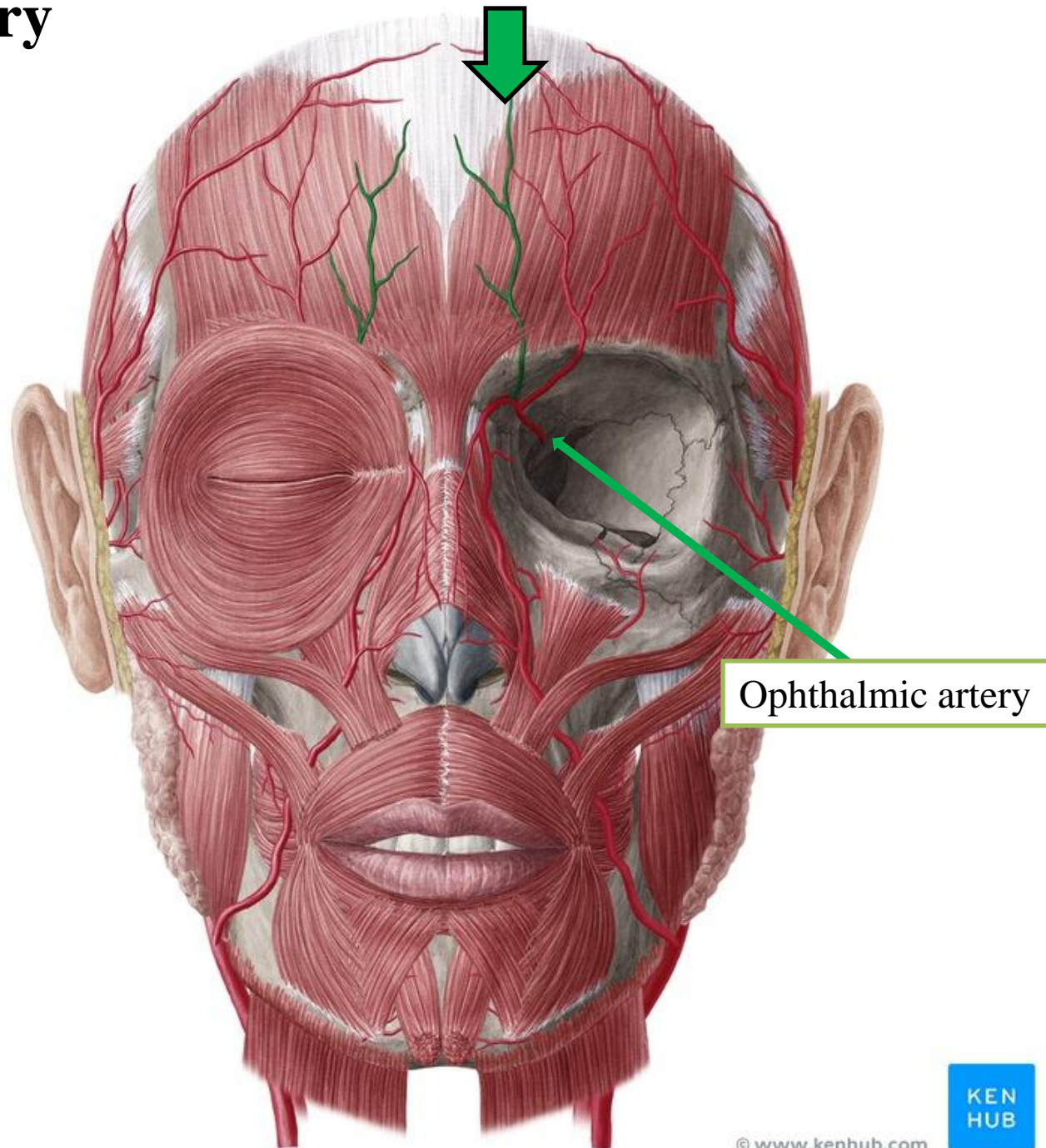


❖ The external carotid artery terminates as two branches (within the parotid gland):

1. Maxillary artery passes deep to mandible
2. **Superficial temporal artery** emerges from the upper border of parotid gland

Supratrochlear artery

- A branch of ophthalmic artery
- Ascends over the forehead in company with the supratrochlear nerve
- Supplies the upper eyelid, and the skin of the forehead and the scalp.



Ophthalmic artery

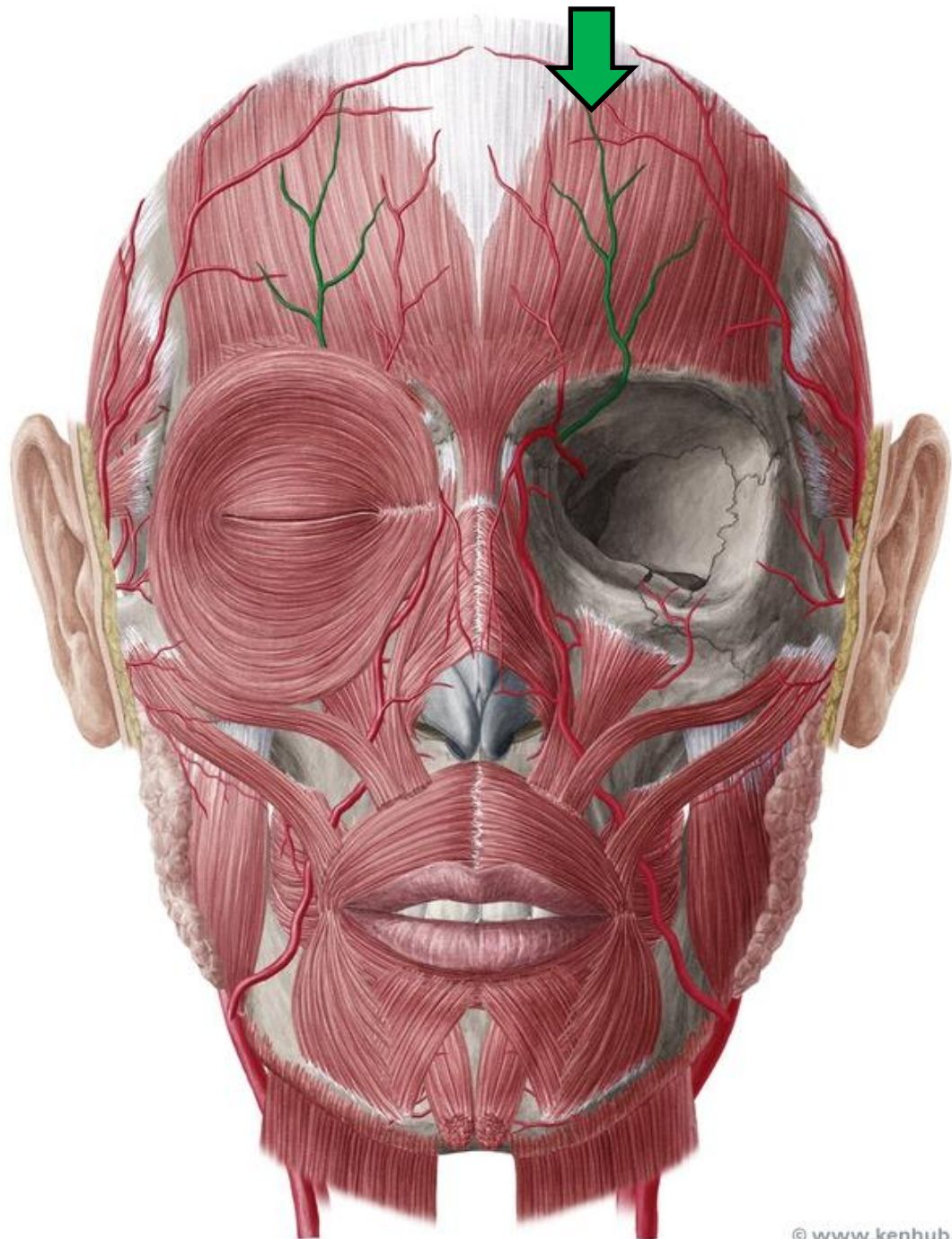
Supraorbital artery

-A branch of ophthalmic artery

-Passes through the supraorbital foramen

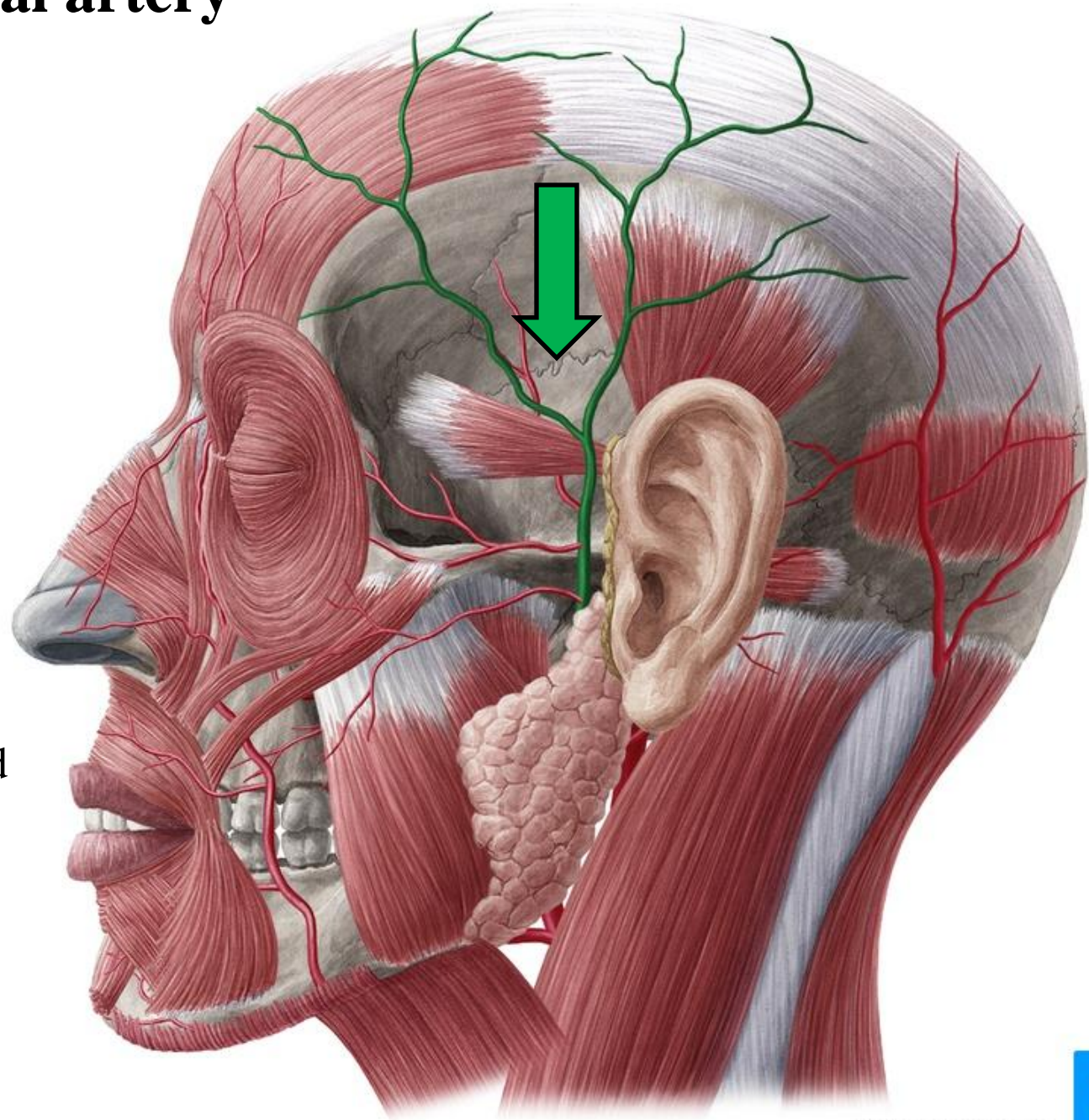
-Ascends over the forehead in company with the supraorbital nerves

-Supplies the upper eyelid, and the skin of the forehead and the scalp.



Superficial temporal artery

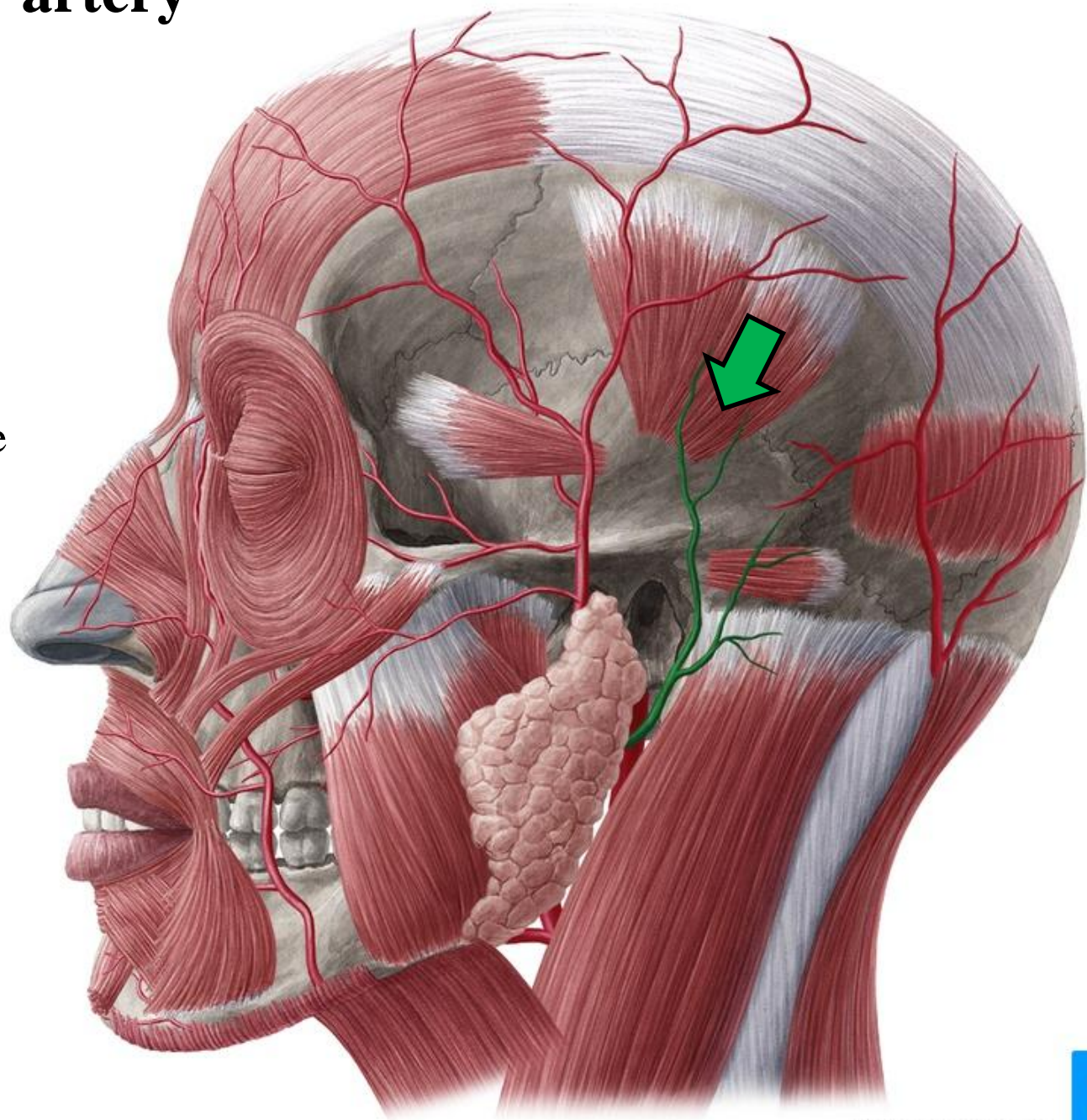
- The smaller terminal branch of the external carotid artery
- Ascends in front of the auricle
- Crosses over the root of zygomatic arch (pulse)
- It divides into anterior and posterior branches, which supply the skin over the frontal and temporal regions.



Posterior auricular artery

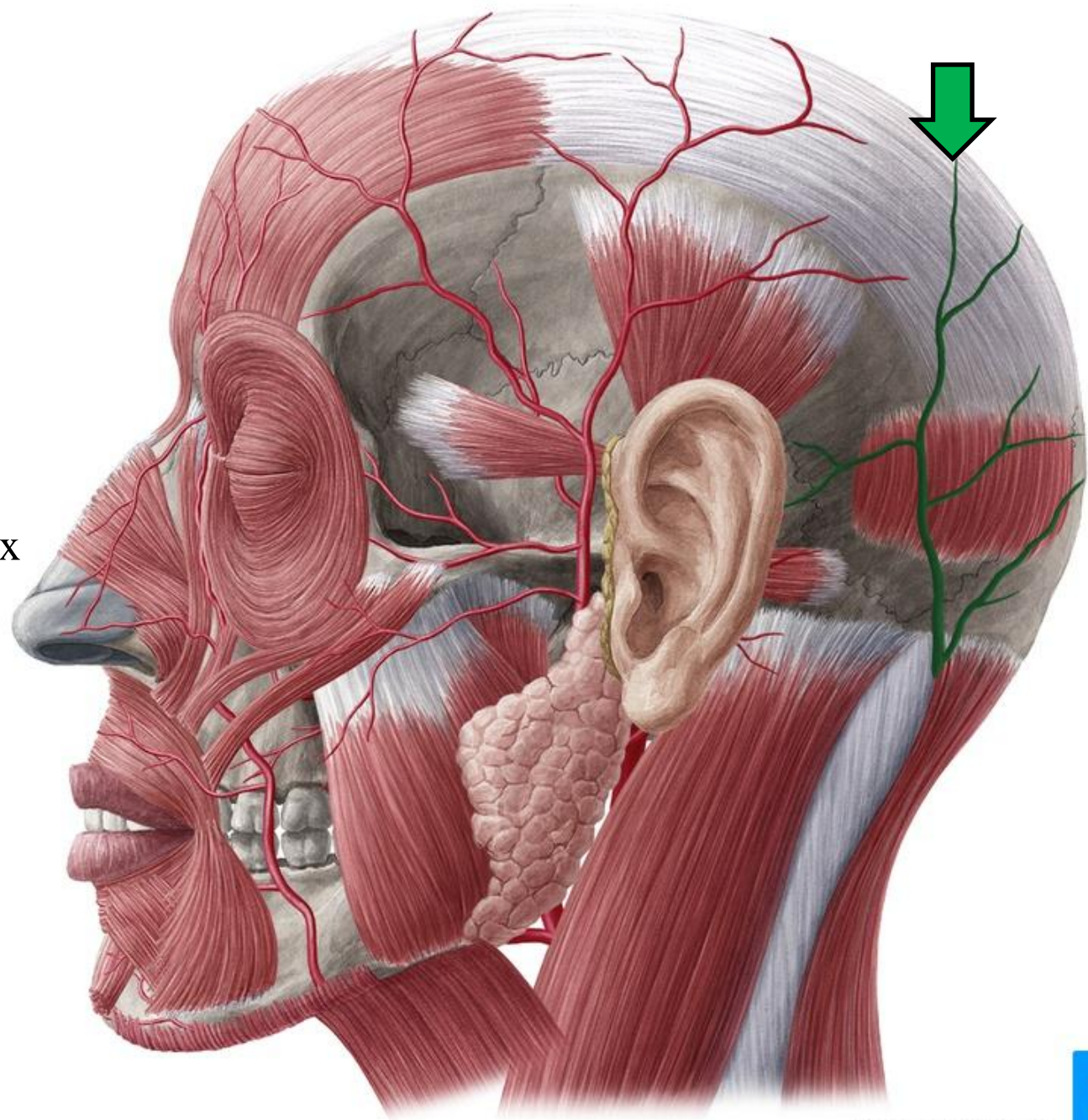
-A branch of External carotid artery

-Ascends behind the auricle to supply the lateral part of scalp behind the auricle



Occipital artery

- A branch of External carotid artery
- Supplies the skin over the back of the scalp and reaches as high as the vertex



Anatomically, it is useful to remember in an emergency that all the superficial arteries supplying the scalp ascend from the face and the neck. Thus, in an emergency situation, encircle the head just above the ears and eyebrows with a tie, shoelaces, or even a piece of string and tie it tight. Then insert a pen, pencil, or stick into the loop and rotate it so that the tourniquet exerts pressure on the arteries




Figure 3-11. Cravat bandage applied to head illustrated A thru C.