

Alveolar Growth Stimulated by Periodontally Accelerated Osteogenic Orthodontics

This article was published in the following Scient Open Access Journal:
Journal of Dental and Oral Health

Received February 18, 2017; Accepted March 04, 2017; Published March 14, 2017

López Buitrago Diego Fernando^{1*} and
Benjumea Marulanda Neftali Joaquin²

¹Universidad Autónoma de Manizales, Colombia. Specialist in Management Applied to Health Services, Pontificia Universidad Javeriana, Colombia. Specialist in Orthodontics and Maxillary orthopedics, Universidad Militar Nueva Granada- Fundación CIEO, Colombia. Assistant Professor, Universidad del Valle, Cali, Colombia

²Fundación Universitaria San Martín, Colombia. Specialist in Maxillofacial Surgery, Pontificia Universidad Javeriana, Colombia. Second year Resident, Graduate Orthodontics Program, Universidad del Valle, Colombia

Abstract

Purpose: This article presents a literature review and the clinical case of a 46 year woman with left unilateral posterior crossbite and vertical hypoplasia, successfully treated by stimulation of transverse and vertical alveolar growth.

Subject and Method: The patient was treated by periodontally accelerated osteogenic orthodontics (PAOO), including corticotomy, micro-osteoperforations and bone graft with lyophilized particles of 300-600 µm.

Results: The amount of expansion obtained in first premolar teeth was 2.25 mm; in second premolar were 2, 25 mm; in first molar was 1.36 mm and in second molar was 3.25 mm. The axial inclination of posterior teeth post-treatment shows that the teeth are not extruded from their cortical while the expansion is produced and there is no over inclination of the crowns. Time of treatment: 12 months.

Discussion: Periodontally accelerated osteogenic orthodontics, through corticotomy, micro-osteoperforations and bone graft, accelerated the orthodontic dental movement, solving the case promptly as confirmed by other authors.

Conclusion: The alveolar stimulus through the PAOO is a procedure that allows the alveolar transverse growth without producing harmful effects to the periodontium and without affecting the inclination of the maxillary posterior teeth.

Keywords: Corticotomy, Crossbite, Maxillary transverse deficiency, Osteogenic orthodontics, PAOO, Orthopedic maxillary expansion, Periodontics

Introduction

Posterior crossbite is a malocclusion characterized by the absence of transverse correlation in the occlusion due to a skeletal discrepancy or an inadequate dentoalveolar relationship that, in both cases, reverts the occlusal relationship, with the upper vestibular cuspids in the occlusal inferior plate [1]. This condition can be unilateral or bilateral and includes at least one posterior tooth. It is frequently associated to transverse collapse of the maxilla about the mandible. The reported prevalence of this malocclusion is 8.7 - 23.3%. It is common to find functional unilateral posterior crossbite cases due to changes in mandibular position [2] and this increases the frequency to 67-79% [1]. When the posterior crossbite is functional, there is an altered condylar position, with the condyle of the same side affected by crossbite tending to be forced to an upper and posterior direction, as the contralateral condyle is antero-inferiorly distracted in relation to the glenoid cavity [2]. Posterior crossbite is also related to functional asymmetries, dental, skeletal or a combination of them both.

Orthopedic maxillary expansion (OME) was described 145 years ago by Angell [3]. Currently OME is a procedure to treat maxillary transverse deficiencies, only for orthopedic treatment in growing patients or combined with orthodontic treatment. However, the ideal chronology for this kind of treatment depends not only of the patient age or dentition stage but also of the skeletal state of development [2]. Therefore, the prognosis differs according to the kind of intervention and the patient characteristics [3]. The OME has adverse effects when it is intended in skeletal mature patients, due to vestibular overinclination of maxillary posterior teeth that press the roots against the cortical bone causing retraction of gingival tissues by apical migration of vestibular alveolar bone, creating dehiscences and root resorption [3]. Additionally it causes a descent of maxillary palatal cuspids that increases the curve of Wilson and therefore,

*Corresponding Author: LOPEZ BUITRAGO Diego Fernando, DDS, Carrera 100 No 5-169 Oasis Unicentro Mall, Office: 407C. Cali, Colombia, Tel: (572) 331 7777 - 315 7777 - 331 6738, Email: dr.diegolopez10@gmail.com

induces the presence of premature contacts and occlusal interferences [3]. Finally, the maxillary molar axis is projected divergent to occlusal forces during the cinematic masticatory activity, causing masticatory deficiency.

Furthermore, maxillary constriction causes retroposition of the tongue that narrows the oropharyngeal airway, contributing to the production of obstructive sleep apnea and occlusal alterations related to the characteristic posterior crossbite [4]. Taking all this into account, the recommended therapeutic approaches to correct the maxillary transverse discrepancy in adult patients, include:

1. LeFort I segmentary osteotomy for reposition of individual segments to a wide transverse dimension [3].
2. Surgically assisted rapid maxillary expansion (SARME) [3].
3. Corticotomy plus osteogenic orthodontics periodontally accelerated using a transverse expander [5].

The criteria to choose among these options should be well defined and based on standardized protocols. But they lack validation with clinical trials, and thus the treatment option is decided by surgeon preferences and positive results obtained by clinicians. In any case, it is clear that patients today prefer the less invasive procedure, less vulnerable with his/her lifestyle [6].

The separated contemporary of therapeutic option to stimulate acceleration of bone remodelling by corticotomy and/or osteoperforations was first suggested by Kole in 1959 [7]. Considered that resistance to dental movement was mainly offered by the cortical bone plates and therefore, the disruption of its continuity could accelerate the orthodontic movement. These procedures included lifting a mucoperiosteal flap to expose alveolar bone, followed by interdental incisions through cortical bone penetrating bone marrow. Subapical horizontal cuts connected interdental cut as in osteotomy, penetrating the full alveolar width. Kole [7] considered that bony blocks move as individual teeth causing less resorption and reducing retention time. Duker [8] in 1975 applied Kole technique [7] in six Beagle dogs to evaluate the acceleration of dental movement by corticotomy, but performing the interdental cuts at 2 mm from the alveolar crest bone level in order to avoid periodontal damage. Frost in 1983 [9] was the first to correlate the size of the injury with the intensity of response, describing the so called Regional acceleratory phenomenon (RAP). Suya in 1991 [10] reported the outcome of orthodontic treatments assisted by corticotomy performed in 395 Japanese adults, using a modified Kole [7] technique and horizontal corticotomy to join the interdental cuts instead of osteotomy. He reported that the acceleration of movement is high during the first six months and the total time of treatment is significantly reduced.

In the present century Wilcko brothers in 2001 [11], incorporated to Kole - Suya technique, the use of interdental osteoperforations to increase the lesion and the RAP effect. They named this new procedure as Accelerated osteogenic Orthodontics (AOO). In 2009 [7] the same authors suggested an innovative strategy combining corticotomy with bone grafts in the injured zone, which they named Periodontally accelerated osteogenic orthodontics (PAOO). This technique combines the full thickness flap with vestibular and palatal corticotomies, interdental osteoperforations and bone graft [11]. The bone graft is of freeze-dried, demineralized bone or bovine bone,

directly applied on corticotomies. The orthodontic movement is initiated after surgery and the authors report that the total time of treatment was reduced to a third of the time required by conventional orthodontics. Furthermore, they considered the technique as effective, safe, predictable, associated with less root resorption and likely to reduce the need of orthognatic surgery [5,11].

From the biological point of view, the corticotomy potentiates the normal healing process by triggering the RAP that accelerates 2 to 10 times the normal physiologic healing. RAP is initiated a few days after the injury, its peak is reached 1-2 months after and persists even 4 to 6 months [11]. The surgery causes a substantial increase of cortical bone demineralization, which is transitory irreversible condition [11-14] accompanied by osteopenia (temporal reduction of bone density) and changes the centre of resistance of tooth or group of teeth to be moved, allowing a rapid body movement, because the teeth are supported by trabecular bone and there is less resistance against movement [15,16]. When the RAP disappears, the osteopenia disappears as well and the normal spongy bone is radiographically evidenced again. When dental movement is completed, the environment created favours alveolar remineralization [11].

The surgical procedure including corticotomy, interdental osteoperforations and bone graft is indicated to augment bone volume avoiding the risk of dehiscence and fenestration when vestibular dental translation is stimulated, while avoiding as well any periodontal damage. Therefore, it improves the prognosis of the alveolar expansion procedure [5,11,15].

Following the surgical procedure, the expanding appliance is installed to activate the dento-alveolar translation movement. The expanding appliance may be Hass, Hyrax, Quad-helix [12] or just a conventional orthopedic expansion screw providing palatal compression of maxillary teeth pushing them to vestibular.

Literature reports indicate different ways to stimulate alveolar growth in three dimensions by using these procedures. Wilcok in 2008 [11] and Lopez in 2014 [5] reports the treatment of maxillary transverse deficiency by maxillary orthopedic expansion plus alveolar decortication and periodontally accelerated osteogenic orthodontics, that successfully corrected the maxillary transverse deficiency plus dehiscence and /or fenestration areas correction and acceleration of dental movement.

For sagittal correction, Wilcok in 2008 [11] also reports the use of alveolar corticotomy in zone of upper and lower incisors in a 14 year old male patient presenting moderate dental crowding. He could increase the vestibular alveolar bone width in the zone of incisors and Oliveira in 2010 [15] reports the case of a 37 year old woman with extrusion of teeth 26 and 27, treated by selective corticotomies in those teeth to intrude them.

Description of the procedure

The surgery may be performed under local anesthesia, with or without sedation. The clinical preparation must follow the same protocol applied for any oral surgery procedure. The crevicular incision is performed buccal and lingual extended to at least 2 -3 teeth of the area being treated. Then, a full thickness flap is lifted on the buccal and palatal surface, beyond the dental apex if possible.

The vertical corticotomies are performed between the teeth

using a round diamond bur, size 2 or a piezoelectric device to avoid any dental root damage. Vertical corticotomy should be extended up 2 mm of the alveolar bone crest to avoid any periodontal defect [12]. The cuts are connected in buccal beyond the dental apex, by horizontal corticotomies. Cortical perforations are made between the corticotomies, to enhance the injury and blood supply to the bone graft [11].

The bone graft material may be autograft, allograft or a combination of them. The graft is placed on decorticated areas only in buccal surface [11]. It is convenient to avoid an excessive amount of bone because this makes difficult the flap repositioning that may induce a dehiscence [11]. The flap is sutured with 4-0 suture preserving the interdental papilla. Post-surgical care is the same applied to any oral surgery procedure. Antibiotics, analgesic and oral rinse must be used by the patient. The sutures are removed after 2 weeks.

Three to five days after the procedure, the expansion appliance is delivered, activated by 5/4 turn every week for eight weeks [5] and then removed to initiate the orthodontic treatment aiming to obtain the other objectives of vertical and sagittal alveolar stimulation [11].

Clinical Case

Patient: 46 year old, white woman. The main complaint was described as: "I dont have a good bite, also I dont like my smile and that affects me emotionally". Antecedents of advance mentoplastia not referred in the anamnesis. The clinical examination did not indicate any current disease contraindicating the orthodontic or surgical treatment.

Facial Analysis

Patient with facial asymmetry of the inferior third, in smile, described by occlusal plane inclination to the left, lip commissure asymmetry, more dental exposition in the first quadrant, exposed buccal corridors in the second quadrant and lack of smile consonance. No mandibular deviation present. Convex profile, flat forehead, open nasolabial angle with mild biprochelia, adequate upper and medium third facial projection, flat nasal dorsum, sagittal class I (Figure 1).

Dental Analysis

Dental midlines coincident between them and with the

facial midline. Adequate overjet and overbite with good anterior relation, canine and molar right side relationship class I, left canine relationship class I. Left posterior crossbite extended from mesial canine to distal second molar; ipsilateral, without mandibular laterodeviation (Figures 1A-1F).

Periodontal Analysis

Mild loss of attachment in teeth 23, 24, 36, 33, 44 and 45; and moderate in 34 and 35. Irregularity in Zenith points.

Radiographic Analysis

In the panoramic radiograph (Figure 2A) it is observed skeletal symmetry of size of the mandibular body and ramus, intraradicular opacity of maxillary right first premolar, upper incisors, second and third lower left molars, second premolar and first molar lower right, compatible with conventional root canal treatment, absence of 18, 28 and 48 teeth. Apical Radiopacity of lower left canine and lower right first premolar compatible with presence of osteosynthesis wire from genioplastia performed to the patient. In the profile radiograph (Figure 2B) it was observed good inclination and projection of upper and lower incisors and adequate menton projection. Posteroanterior radiograph evidences occlusal plane canting, due to maxillary canting with the first quadrant having more vertical alveolar bone than the second quadrant (Figure 2C).

Tomographic pre-treatment Analysis

Cone Beam tomography of the whole facial skeletal complex, shows vertical hypoplasia of second quadrant. The following measurements were taken in the pre and post treatment tomography:

1. Transversal measurement in millimeters of midline to palatal Surface of premolars and maxillary left molars.
2. Evaluation of axial inclination in degrees, following the axial angle tooth with respect to the horizontal coordinate in premolars and maxillary left molars (Figures 3A-3C) (Table 1).

Objectives of treatment

- To improve the esthetic self-perception of the patient.
- To correct posterior left crossbite.
- Re-establish periodontal architecture.
- Maintain molar and canine sagittal relationship.
- Eliminate occlusal trauma.

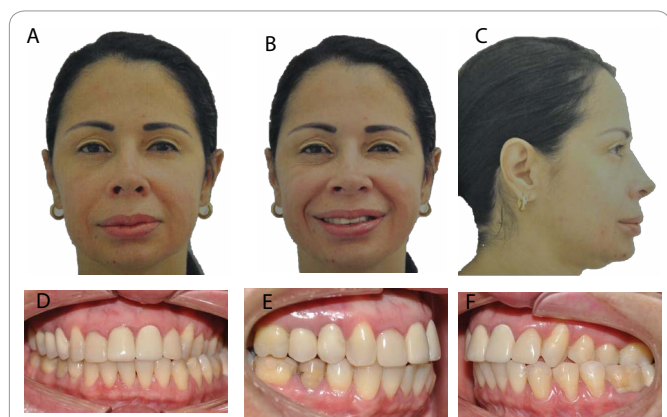

Figure 1: Extraoral initial photographs and intraoral initial photographs
A. Frontal resting, B. Frontal smiling, C. Profile, D. Frontal, E. Right lateral, F. Left lateral.

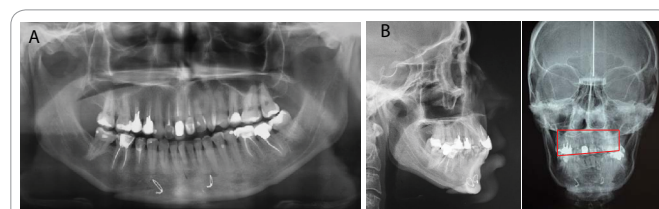


Figure 2: Radiographic Analysis
A. Panoramic Radiograph (Observe the difference in the height of the posterior occlusal planes right and left).
B. Profile Radiograph.
C. Postero-anterior radiograph (it is appreciated the irregular polygon conformation due to difference in alveolar bone height causing maxillary canting).

Tooth	T1 measurement in mm from the midline to palatal face	T2 measurement in mm from the midline to palatal face	DIFFERENCE T2 – T1 (mm)
24	12.50	14.75	2.25
25	16.50	18.75	2.25
26	17.25	18.61	1.36
27	19.00	22.25	3.25

Table 1: Transverse measurements T1 vs T2 and Difference.

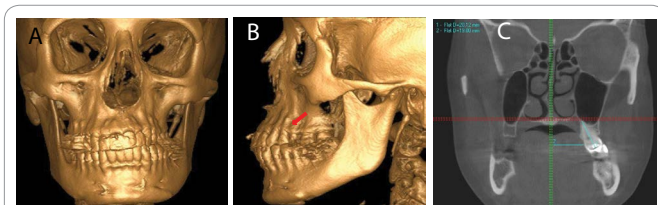


Figure 3: Tomographic pre-treatment.

A. Frontal: Cone Beam craniofacial tomography. It is observed the maxillary cant, dehiscence in the second quadrant and root projection against vestibular cortical vestibular.

B. Left Side (the arrow show the degree of dehiscence).

C. Tomographic measurement and angulation of tooth 27. T1: Pre-treatment

Evolution of the treatment

The patient was referred to the Oral and maxillofacial surgery service, where it was performed the procedure described above, under local anesthesia in the second quadrant. Vestibular and palatine interdental corticotomies were made. Additionally, micro-osteoperforations were performed by vestibular using long handle, round, carbide 701 bur, equivalent to a diameter of 0.5 mm, to enhance the injury and thus the RAP. The graft was cortico-spongy bone, mineralized particles 300 to 600 micrometer, lyophilized, from the Miami University tissue Bank®. The flap was sutured in position, with Vicryl Ethicon® 4-0, preserving the interdental papilla, using vertical mattress sutures (Figures 4A-4E). During the surgery was evident the dehiscence, product of the apical migration of alveolar bone, clinically manifested as gingival retractions and loss of periodontal attachment.

Three days after the surgery, the expansion device was placed, with unilateral orthopaedic expansion screw of 7 mm (Dentaurum®), cemented by bands to first molar upper right and second molar upper left and with retention hooks in first premolar upper left, second premolar upper left and second molar upper left. The screw was activated with 5/4 turn once a week for eight weeks (Figure 5). After that time it was removed and the orthodontic treatment was initiated using a system of interactive

self-ligation brackets (In Ovation Clear prescription CCO, Dentsply GAC). The sequence of arches used was: *Sentalloy* 0.014 and 0.018, *Bio Force* 0.020/0.020, steel 0.019/0.025 and *Braided* 0.019/0.025 upper and lower. It was used a temporary anchorage device (TAD) in vestibular of the third quadrant, between second premolar and first molar. This absolute anchorage allowed the stimulation of vertical growth of the second quadrant by elastic mechanics. (Figures 6A-6D).

After 12 months, the appliances were removed and removable retainers were placed. After 24 months of retention the results are stable (Figures 7A-7I).

After removing the appliances a new cone beam tomography was taken. It is observed that although there is a vestibular dental displacement in the second quadrant, the roots were not out of the cortical and there is no increment of dehiscence. On the contrary, periodontal architecture and bone support are improved. In the second time (T2) the measurements were taken in mm for the expansion obtained and in degrees for axial inclination (Figure 8A) (Table 2).

Transverse and axial measurements in T1 vs T2 were compared and the respective differences are shown in Table 1 and Table 2. T1 measurements refer to transverse width and axial inclination of posterior teeth before the treatment; T2, are the respective results after treatment.

The post-treatment tomography (Figures 9A and 9B) shows evidence of correction of vertical cant in the second quadrant, improving the vertical hypoplasia and obtaining symmetry A) Frontal View, B) Left lateral view (improving the dehiscences).

Treatment Outcome

Total correction of posterior left crossbite without altering the relationship between first and four quadrants. In table 2 are shown the measurements of the expansion obtained between T1 (pre-treatment) and T2 (post-treatment) and its difference. The amount of expansion obtained in first premolar was 2.25 mm, in second premolar was 2, 25 mm, in first molar was 1.36 mm and in second molar was 3.25 mm. The axial inclination of posterior

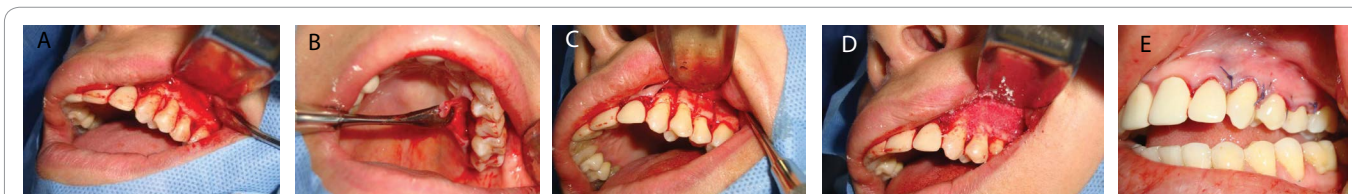

Figure 4: Patient's surgery

A. Lifting of full thickness vestibular flap.

B. Lifting of full thickness palatal flap.

C. Vestibular and palatal corticotomies

D. Placement of particulate bone graft lyophilized, 300 - 600 micrometer, from Miami University tissue Bank®

E. Reposition of graft and suture

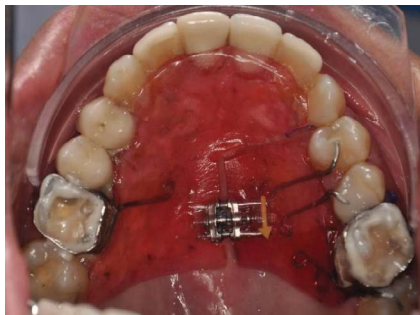

Figure 5: Cementation of plate with unilateral expansion screw, 3 days after surgical intervention.

teeth post-treatment shows that the teeth are not extruded from their cortical while the expansion is produced and there is no over inclination of the crowns. The inclination was maintained in first premolar upper left and first molar upper left, improved in second molar upper left and increased only in second premolar upper left, a tooth that had a previous palatal rotation, therefore

Tooth	AXIAL angulation of palatal plane T1	AXIAL angulation of palatal plane T2	DIFFERENCE T2 – T1
24	92°	93°	1°
25	89°	100°	11°
26	84°	84°	0°
27	117°	108°	-9°

Table 2: Difference in axial angulation T1 vs T2

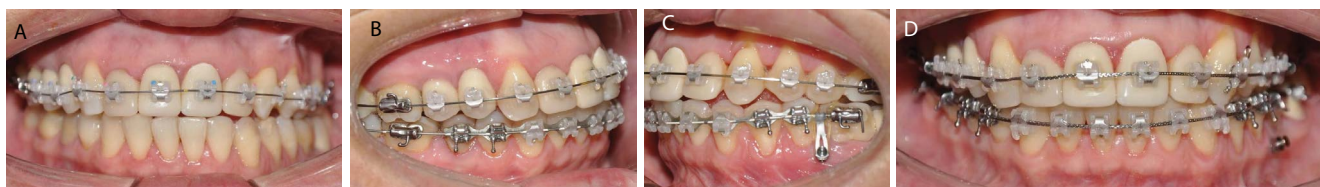

Figure 6: Sequence of orthodontic's wires with superelastic arches and TAD between 36 and 35.

- A. Cementation upper brackets and arch
- B. Lateral right side photograph.
- C. Lateral left side photograph. TAD placement between 36 and 35
- D. Upper and lower braided Arches

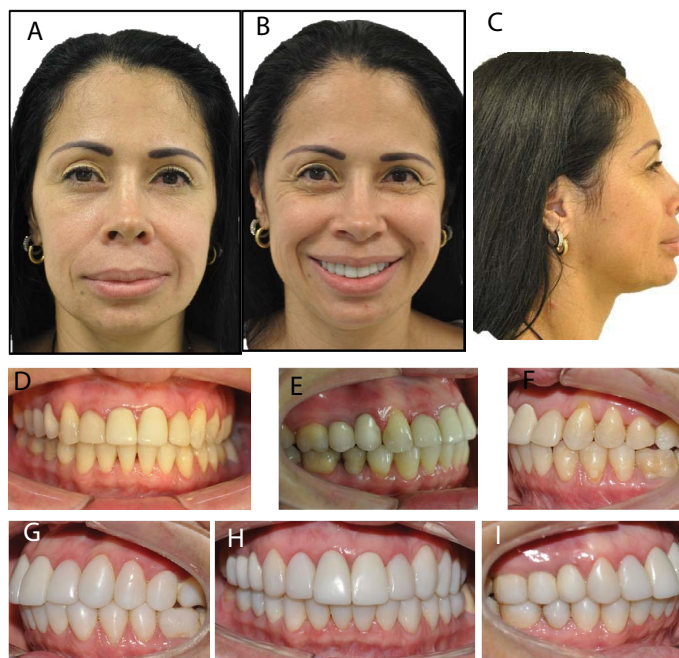

Figure 7: Extraoral final photographs and intraoral final photographs.

- A. Frontal, resting
- B. Frontal smiling
- C. Profile.
- D. Frontal
- E. Right lateral
- F. Left lateral
- G. Retention after 24 months, the patient decided to receive esthetic veneers frontal
- H. Right lateral
- I. Left lateral

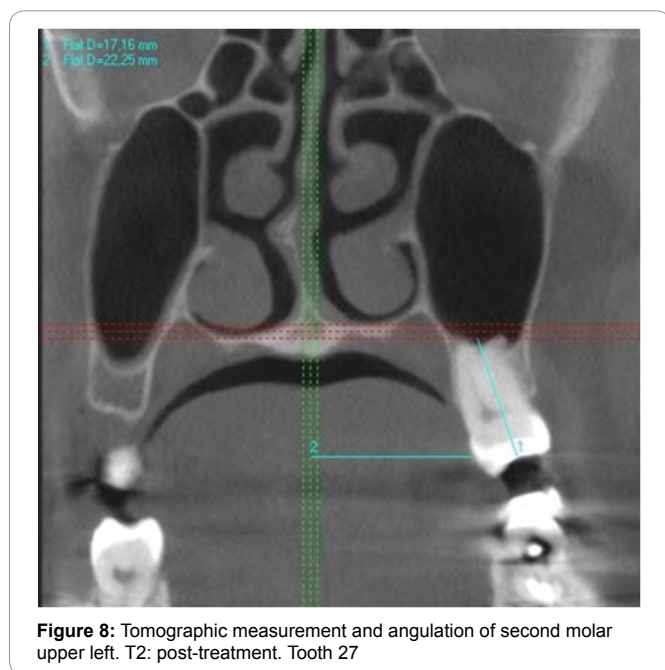


Figure 8: Tomographic measurement and angulation of second molar upper left. T2: post-treatment. Tooth 27

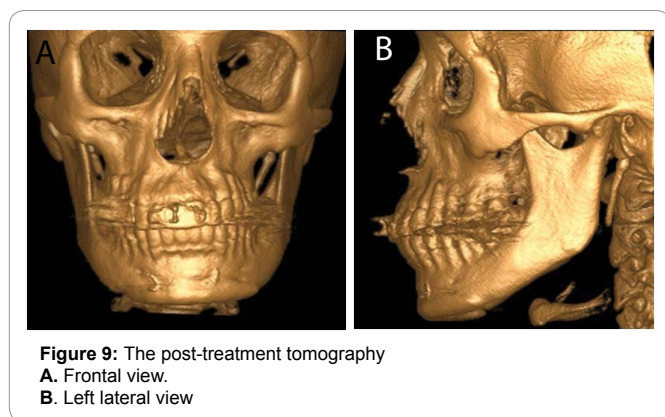


Figure 9: The post-treatment tomography
A. Frontal view.
B. Left lateral view

the change was positive. It was achieved the canine bilateral desocclusion, coupling of anterior teeth with adequate overbite and overjet, eliminating occlusal trauma and correcting vertical hypoplasia of the second quadrant, correction of maxillary cant and in general obtaining a positive impact on smile expression. The periodontal tissue shows an adequate level of attachment, and improvement of periodontal architecture. The patient was pleased with the esthetic smile results and functional bite results. The total time of treatment was 12 months.

Discussion

During the last three decades maxillary expansion has attained popularity between orthodontists as an important orthopedic complement in treatments with fixed appliances [17]. Expansion protocols have been recommended to treat cross-bite, dental crowding, leveling of the curve of Wilson, aid to the eruption of permanent canine teeth, increase the size of nasal airway and reduction of antiesthetic buccal corridors [18]. Orthopaedic expansion is considered the best orthodontic option in cases of dentoalveolar discrepancies and maxilla-mandibular transverse deficiencies [19]. But, maxillary orthopedic expansion may cause

undesired effects when it is performed in skeletal mature patients, including lateral inclination of posterior teeth with extrusion, periodontal ligament compression, vestibular root resorption, buccal cortical fenestration, palatal tissue necrosis, inability to open palatal median suture, pain and lack of stability [20]. Therefore, authors like Suri, et al. [20] consider that patient age and gender, specifically skeletal age, are the most relevant criteria to decide whether to treat the patient by surgically assisted maxillary orthopedics. After 16 to 18 years this alternative of treatment may be carefully considered [20]. Mommaerts [21] states that orthopedic maxillary expansion is indicated for young patients over 12 years, but over 14 years, corticotomies are essential to free resistance areas resistant to expansion [21]. Other authors as Handelman [22] challenge these concepts, suggesting that patients with maxillary width deficiency may be treated by nonsurgical assisted maxillary expansion, accepting that the expansion obtained is dentoalveolar and it is not including separation of the palatal median suture.

Vanarsdall [23] states that maxillary transverse deficiencies in children treated rapid maxillary expansion may cause dehiscence, gingival and bone recession [23]. Anyway, it is accepted that, in surgically assisted expansion as well as in maxillary expansion in adult patients, there is no stimulus for alveolar overgrowth at vestibular level in upper posterior teeth [24].

Wilcko [11] in his evidence based analysis consider the scientific perspective for periodontally accelerated osteogenic orthodontics. The technique provide a net increase in the alveolar bone volume when bone is added in the vestibular zone of the dentoalveolar region to be expanded, plus the acceleration of dental orthodontic movement by the regional phenomenon triggered by inter-radicular corticotomies. With this combined technique, teeth may be moved further than with traditional orthodontics [25], and the alveolar volume may be increased afterwards to cover dehiscence in the vestibular surfaces as presented in this case, improving the level of attachment of periodontal tissues [25].

In the protocol for nonsurgical expansion suggested by Handelman [26], the appliance used (Haas expander) is more voluminous, the activation is done every other day, but may increase depending of the patient's age and the amount of bone loss or gingival recession. The appliance is used for 12 weeks after the last activation to allow bone remodelling and after its removal is used acrylic palatal retainer for at least 3 months more, after the initial orthodontic treatment [26].

In the case hereby described it was used unilateral orthopedic expansion screw of 7 mm, activated by 5/4 turn once a week for 8 weeks to correct the cross-bite. Then, it was initiated the orthodontic treatment with the biomechanics necessary to obtain the vertical and/or sagittal objectives of treatment. Comparing the results obtained regarding expansion and axial inclination of crowns, there was not the crown undesired change as reported by Handelman [24] in his nonsurgical clinical cases. It was possible to obtain the vertical increase in the second quadrant with the assistance of the inferior TAD, elastic mechanics and corticotomy as reported by Oliveira [15].

The total time of treatment in the present case was 12 months, that is significantly reduced as compared to the time reported by Wilcko [11] for conventional orthodontics, that is approximately 2 to 2.5 years. Altogether, it is observed in this case an outcome more efficient concerning the esthetic, occlusal, periodontal and functional results. There was not development of diastema at the level of incisors that may affect the esthetic as in

cases of disjunction [22]. Nevertheless it must be considered that this treatment involves the risks of any surgical procedure, and demands more time available for surgery and recovery as well as expenses [27]. One of the disadvantages of the surgical technique not evidenced in our case is the development of the gingival recession resulting from the elevation of flap and orthopedic expansion with appliances for disjunction. Although Wilcko [25] reports as a disadvantage the possible delay of the dental movement with the use nonsteroidal anti-inflammatory drug analgesics after surgery, in this case, we had an acceleration of the dental movement product of the fast activation and RAP. Also disadvantages of the surgical procedure may be a dental and pulp damage caused by corticotomy [25]. During the placement of the bone may present the risk of infection and this not be accepted by the patient. This infection process may have a greater risk of not be accepted in cases of allografts than autograft, which has not occurred in our patient with the use of the allograft.

Corticotomy may become a recommended procedure in the alveolar expansion cases because it is predictable, effective and safe, both to accelerate dental movement and to achieve complex movements [28]. Aristizabal [29] in a pilot study summarizes the clinical and systemic effects of corticotomies as part of the periodontally accelerate osteogenic orthodontics, concluding that it is more rapid and effective, compared to his control patients.

Conclusion

Periodontally accelerated osteogenic orthodontics, including corticotomies, micro-osteoperforations and bone graft, is a multidisciplinary option of treatment that aids to stimulate alveolar bone growth in the three planes of space, successfully solving malocclusion cases of posterior unilateral crossbite in a relatively short time.

Conflict of Interest

The authors declare that there is no any conflict of interest in this investigation.

References

1. Ferro F, Spinella F, Lama N. Transverse maxillary arch form and mandibular asymmetry in patients with posterior unilateral crossbite. *Am J Orthod Dentofacial Orthop.* 2011;140(6):828-838.
2. Langberg B, Arai K, Miner RM. Transverse skeletal and dental asymmetry in adults with unilateral lingual posterior crossbite. *Am J Orthod Dentofacial Orthop.* 2015;127(1):6-15.
3. Lokesh S, Pareja T. Surgically assisted rapid palatal expansion. A literature review. *Am J Orthod Dentofacial Orthop.* 2008;133(2):290-302.
4. Zhao Y, Ng uyen M, Gohl E, Mah James, Sameshima G, Enciso R. Oropharyngeal airway changes after rapid palatal expansion evaluated with cone-beam computed tomography. *Am J Orthod Dentofacial Orthop.* 137(4 Suppl):S71-78.
5. Lopez D, Jaramillo IC. Maxillary Orthopedic Expansion with Periodontally Accelerated Osteogenic Orthodontics. *Univ Odontol.* 2014;33(70):157-174.
6. Al-ouf K, Krenkel C, Hajeer CM, Sakka S. Osteogenic uni- or bilateral form of the guided rapid maxillary expansion. *J Craniomaxillofac Surg.* 2010;38(3):160-165.
7. Kole H. Surgical operations on the alveolar ridge to correct occlusal abnormalities. *Oral Surg Oral Med Oral Path.* 1959;12(5):515-529.
8. Duker J. Experimental animal research into segmental alveolar movement after corticotomy. *J Maxillofac Surg.* 1975;3:81-84.
9. Frost HM. The regional acceleratory phenomenon: a review. *Henry Ford Hosp Med J.* 1983;31(1):3-9.
10. Suya H. Corticotomy in orthodontics. In: Hosl E, Baldauf A, editors. *Mechanical and Biological Basis in Orthodontic Therapy.* Huthig Buch Verlag; Heidelberg, Germany. 1991;207-226.
11. Wilcko MT, Wilko WM, Bissada NF. An evidence-based analysis of periodontally accelerated orthodontic and osteogenic techniques: a synthesis of scientific perspective. *Seminars Orthod.* 2008;14(4):305-316.
12. Huynh T, Kennedy DB, Joondeph DR, Bollen AM. Treatment response and stability of slow maxillary expansion using Haas, hyrax, and quad-helix appliances: A retrospective study. *Am J Orthod Dentofacial Orthop.* 2009;136(3):331-339.
13. Moyers, RE, van der Linden, FP, Riolo, ML, McNamara, JA. In: *Standards of Human Occlusal Development: Monograph No. 5-Craniofacial Growth Series.* Center for Human Growth and Development, University of Michigan, Ann Arbor, Mich. 187. 1976.
14. Handelman CS. Nonsurgical rapid maxillary alveolar expansion in adults: a clinical evaluation. *Angle Orthod.* 1997;67(4):291-305.
15. Douglas D, Franco de Oliveira B, Villamarim R. Alveolar corticotomies in orthodontics: Indications and effects on tooth movement. *Dental Press J Orthod.* 2010;15(4):144-157.
16. Alikhani M, Raptis M, Zoldan B, et al. Effect of micro-osteoperforations on the rate of tooth movement. *Am J Orthod Dentofacial Orthop.* 2013;144(5):639-648.
17. McNamara J, Sigles L, Franchi L, Guest S, Baccetti T. Changes in occlusal relationships in mixed dentition patients treated with rapid maxillary expansion. *Angle Orthod.* 2010;80(2):230-238.
18. McNamara JA. Maxillary transverse deficiency. *Am J Orthod Dentofacial Orthop.* 2000;117(5):567-570.
19. Malkoç S, Iseri H, Durmus E. Semirapid maxillary expansion and mandibular symphyseal distraction osteogenesis in adults: a five-year follow-up study. *Semin Orthod.* 2012;18(2):152-161.
20. Velasquez P, Benito E, Bravo L. Rapid maxillary expansion. A study of the long-term effects. *Am J Orthod Dentofacial Orthop.* 1996;109(4):361-367.
21. Mommaerts MY. Transpalatal distraction as a method of maxillary expansion. *Br J oral Maxillofacial Surg.* 1999;37(4):268-272.
22. Handelman C. Palatal expansion in adults: the nonsurgical approach. *Am J Orthod Dentofacial Orthop.* 2011;140(4):462-466.
23. Vanarsdall RL. Orthodontics and periodontal therapy. *Periodontol.* 1995;9:132-149.
24. Handelman CS, Wang L, BeGole EA, Haas AJ. Nonsurgical rapid maxillary expansion in adults: report on 47 cases using the Haas expander. *Angle Orthod.* 2000;70(2):129-144.
25. Wilcko WM, Wilcko T, Bouguot JE, Ferguson DJ. Rapid orthodontics with alveolar reshaping: two case reports of decrowding. *Int J Periodontics Restorative Dent.* 2001;21(1):9-19.
26. Handelman CS. Adult nonsurgical maxillary and concurrent mandibular expansion; treatment of maxillary transverse deficiency and bidental arch constriction. *Semin Orthod.* 2012;18(2):134-151.
27. Lanigan DT, Mintz SM. Complications of surgically assisted rapid palatal expansion: review of the literature and report of a case. *J Oral Maxillofac Surg.* 2002;60(1):104-110.
28. Long H, Pyakurel U, Wang Y, Liao L, Zhou Y, Lai W. Interventions for accelerating orthodontic tooth movement. A systematic review. *Angle Orthod.* 2013;83(1):164-171.
29. Aristizabal JF, Bellaiza W, Ortiz M, Franco L. Clinical and Systemic Effects of Periodontally Accelerated Osteogenic Orthodontics: Pilot Study. *Int J Odontostomat.* 2016;10(1):119-127.