

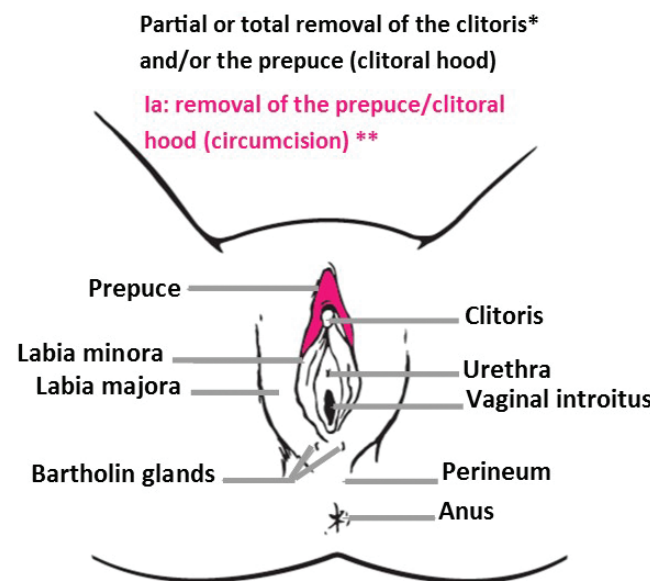
Female Genital Mutilation/Cutting (FGM/C)

A Visual Reference and Learning Tool for Health Care Professionals

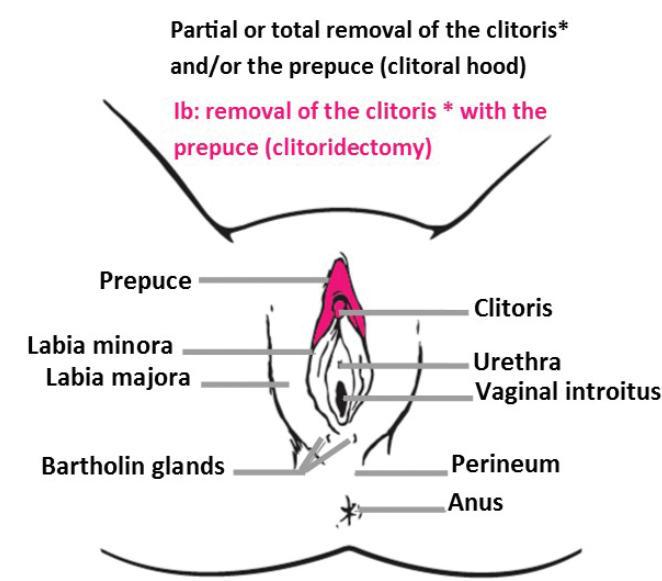
Type I:

Partial or total removal of the clitoris* and /or prepuce

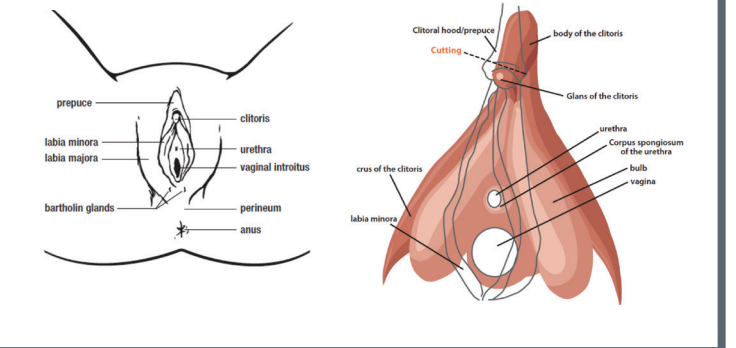
FGM/C Type Ia



FGM/C Type Ib



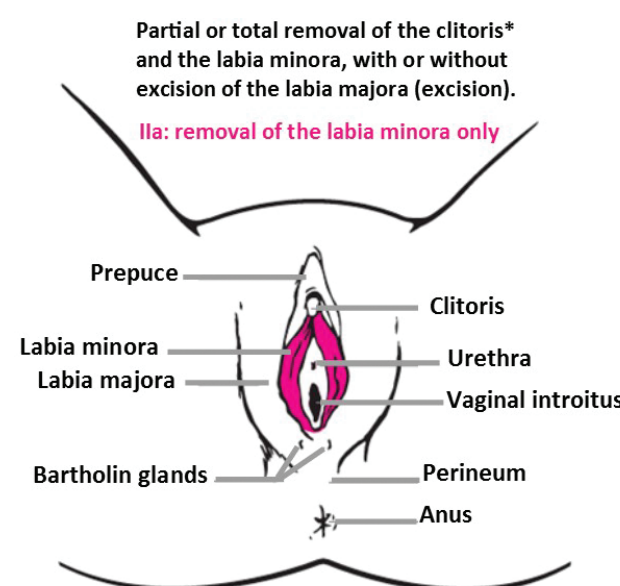
*In the World Health Organization classification, when there is reference to removal of the clitoris, only the glans or the glans with part of the body of the clitoris is removed. The body or part of the body and the crura of the clitoris remain intact as well as the bulbs, two other sexual erectile structures.



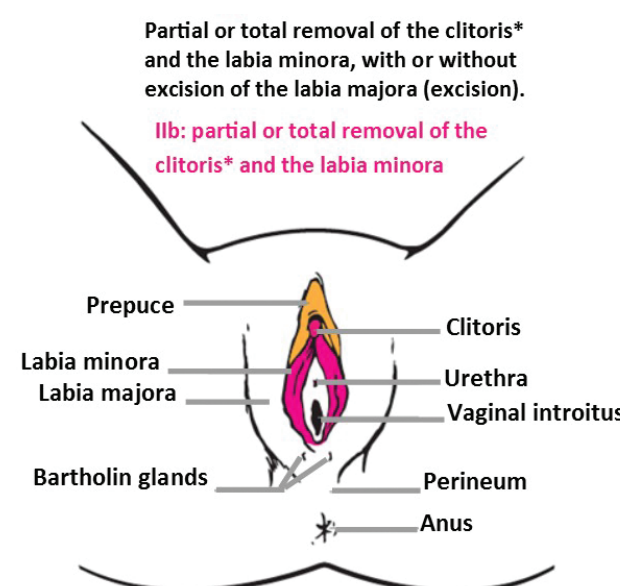
Type II:

Partial or total removal of the clitoris* and labia minora, with or without excision of the labia majora

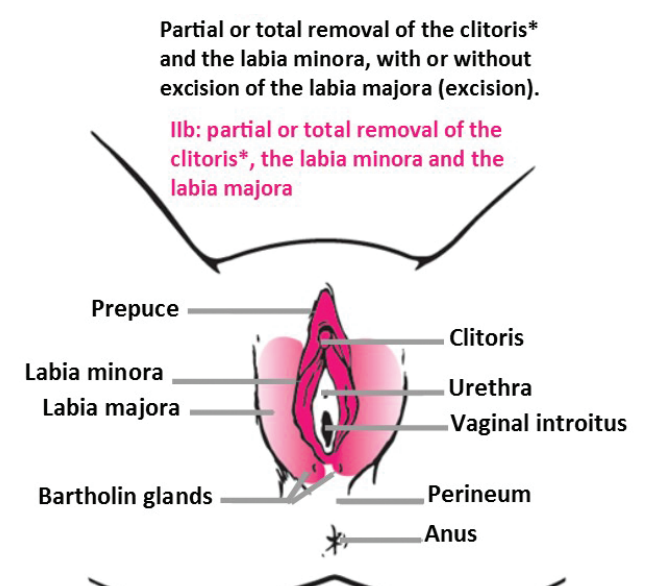
FGM/C Type IIa



FGM/C Type IIb



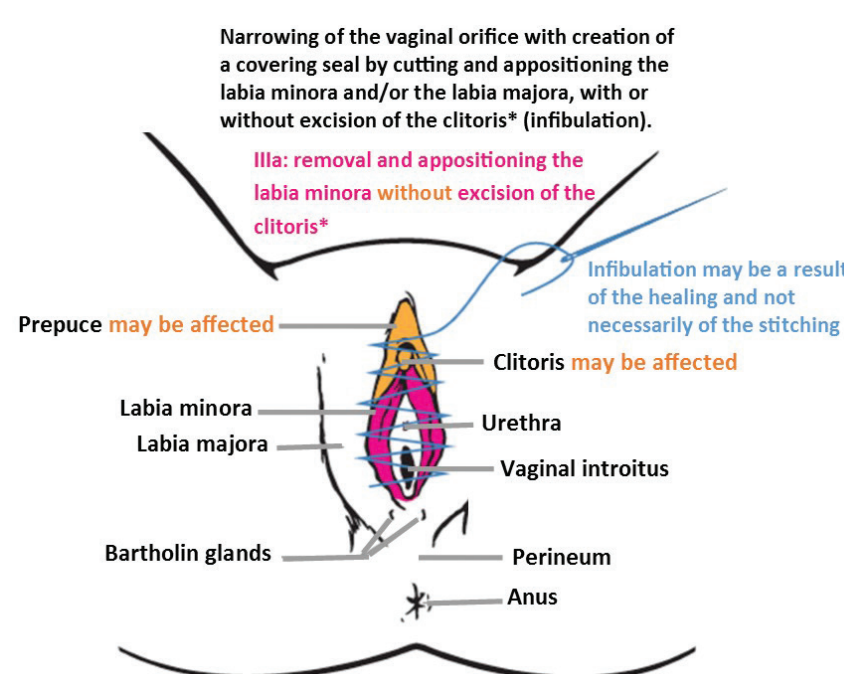
FGM/C Type IIc



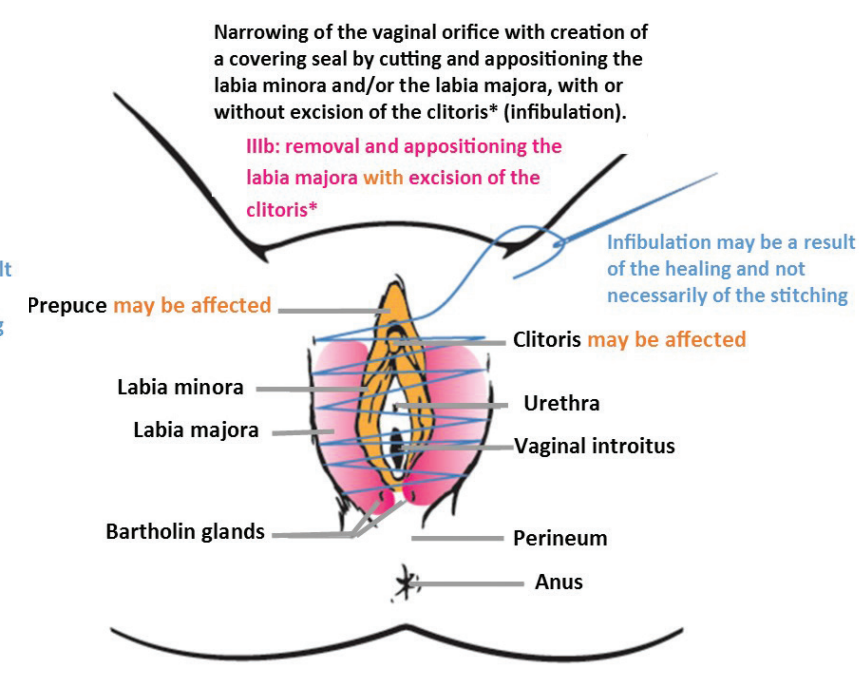
Type III:

Narrowing of the vaginal orifice with the creation of a covering seal by cutting and appositioning the labia minora and/or the labia majora, with or without excision of the clitoris (infibulation)

FGM/C Type IIIa



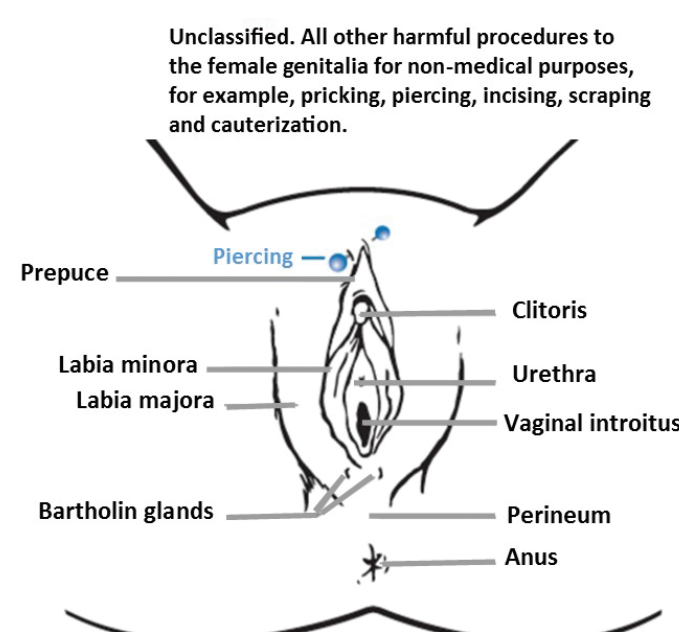
FGM/C Type IIIb



Type IV:

All other harmful procedures to the female genitalia for non-medical purposes, for example: pricking, pulling, piercing, incising, scraping and cauterization

FGM/C Type IV



This is a visual reference learning tool on female genital mutilation/cutting (FGM/C). We envision that the visual reference can be used as a standalone guide for patient management and can be consulted by caregivers when unsure on the type of FGM/C diagnosed. The guide and accompanying text can facilitate training of health care providers globally in accurate diagnosis for both clinical management, patient-provider communication, and accurate recording and reporting to governments where required. This reference tool also could be integrated into surveys for monitoring the prevalence of FGM/C types and subtypes.

Adapted with permission from Jasmine Abdulcadir, MD, Lucrezia Catania, MD, Michele Jane Hindin, PhD, Lale Say, MD, Patrick Petignat, MD, and Omar Abdulcadir, MD, Female Genital Mutilation: A Visual Reference and Learning Tool for Health Care Professionals, Obstet Gynecol. 2016 Nov;128(5):958-963.

Acknowledgment

This research was supported by funding from the US Department of Health & Human Services, Office on Women's Health (HHS, OWH), award ASTWH160045 (C. Johnson-Agbakwu, PI.). The content is solely the responsibility of the authors and does not necessarily represent the official views of HHS or OWH.



Scan this image to view Video on your smartphone

Defibulation: During Pregnancy (Antepartum or Intrapartum) or Gynecologic Care

Defibulation is a procedure that opens the vulvar scar tissue, exposes the introitus, and creates new labia. Defibulation is recommended for infibulated women who suffer from genito-urinary complications, and/or dyspareunia and allows physiological delivery and gynecological procedures. Surgery can be performed under general, local or regional anesthesia. Pregnant women should be defibulated during their second trimester or during labor, under local or regional anesthesia. During labor, defibulation can be performed during the first stage (preferably).

Contraindications

- Refusal of the woman
- Tissue cannot be lifted and incised

Equipment Needed

- Sterile gloves
- Disinfection prep
- 10 cc syringe
- 22 or 25 g needle for injection
- EMLA cream (before applying local anesthetic injection)*
- Local anesthetic injection (1% Xylocaine, 0.25% Bupivacaine HCL and Epinephrine 1:200,000)
- Scalpel or straight Metzenbaum scissors or curved Mayo scissors (depending on the thickness of the scar tissue)
- Adson plain or rat-toothed tissue forceps
- Needle driver
- 4-0 monocryl or vicryl suture on SH needle
- Suture scissors
- Mosquito clamp

* if defibulation is performed under local anesthesia

Pre-operative Counseling

- Education on anatomy and physiology before and after defibulation (e.g. false beliefs on infibulated and defibulated external genitals, virginity, sexuality, and genital self-image)
- Information on anesthesia (local, locoregional or general), surgery, advantages and follow-up
- Agreement on the opening (up to 1 cm above the urethra or up to the clitoris)
- Reassurance on intraoperative and postoperative pain (not the same as for original FGM/C)
- If during pregnancy give the woman/girl the choice of undergoing defibulation during pregnancy (2nd trimester) or labor (first phase)

Defibulation

- Palpate the clitoris and assess where the urethral meatus might be
- Place a finger or a Mosquito clamp under the cutaneous bridge of the defibulation and tent it outward. Additional orifices can be present along the infibulation scar
- To avoid labial asymmetry, make sure you decide on the central line of incision before tenting up on the skin of the infibulation. You can then draw this line
- Incise with scissors (or a scalpel) along the midline and proceed from inferiorly to superiorly, up to the level agreed upon with the patient, uncovering the urethral meatus (partial) or the clitoral region (total defibulation)
- Be careful not to injure the urethral meatus and the clitoris or clitoral stump. In case of adhesions, a urinary catheter can be introduced for the duration of the surgery as soon as the urethra is accessed
- When performing defibulation during labor (In the absence of an epidural), incise the scar during the pain peak of a uterine contraction
- Reconstruct the labia majora and/or minora by suturing the edges of the defibulated infibulation with continuous or separated stitches

Postoperative Care

- Follow-up care within the first 1-2 weeks, and then again at 4-6 weeks. Explain the changes experienced (e.g. faster micturition) and that sexual intercourse can be resumed after 4-6 weeks and/or when it is suitable for both the patient and partner
- Prescribe local estrogen cream to apply to the vulva in the first few weeks to help promote tissue healing and reduce labial adhesion/agglutination. Advise the client on local vulvar hygiene and daily manual detachment of the labia to avoid spontaneous adhesion
- Provide analgesia (acetaminophen and ibuprofen)
- Good hydration and micturition under a water jet can help reduce burning caused by the urine passing on the defibulated area. Sitz baths are advised

CPT Codes:

- 13131** Defibulation (general procedure code)
Repair of complex procedures on integumentary system
- 56441** Lysis of labial adhesions
- 56800** Plastic repair of introitus

FGC Diagnosis	ICD-10
FGM/C Unspecified	N90.810
Type I	N90.811
Type II	N90.812
Type III	N90.813
Other FGM/C	N90.818

*for complicated procedures add -22 modifier and document additional work

Counseling

Reinfibulation is the practice of sewing the external labia back together after defibulation. Reinfibulation is illegal in some countries. It is not recommended by FIGO and WHO.

Antepartum Care

- Use a certified interpreter in case of language barriers
- Take time for the consultation
- Discuss the respective changes occurring after delivery and defibulation (e.g. in micturition, menstruation, genital appearance, and sex) using illustrations
- Clarify the advantages of performing defibulation
- Explore patient beliefs, fears, and myths regarding uncut and defibulated genitalia
- Provide correct information respectfully (e.g. defibulated genitalia are not "wide and open"; faster micturition is not "vulgar")
- If possible, with the woman's agreement, include the partner in the discussion, and encourage an exchange of views by the couple
- Explain that reinfibulation is not in the patient's and her partner's best interests in terms of health (urogynecologic, obstetric, and sexual complications)
- Explain the medico-legal recommendations

Intrapartum Care

- During intrapartum defibulation, respect the woman's choice regarding the level of opening (partial or total defibulation)
- In case of a supra-clitoral or supra-urethral tear, reconstruct the vulvar anatomy in the most physiological way, leaving the urethral meatus and the vaginal orifice uncovered; avoid asymmetries of the labia
- Explain to the woman each of the different procedures she underwent (e.g. perineal tear, episiotomy, and defibulation)

Postpartum Care

- Use a certified interpreter in case of language barriers
- Take time for the consultation
- During the postpartum check, explore the woman's feelings regarding the new appearance and physiology of her genitalia
- Repeat explanations on possible false beliefs and myths
- Do not focus only on reinfibulation, but also care for the woman's overall health, including breastfeeding, contraception, sexual health, and postpartum incontinence
- Propose pelvic floor training and explain the advantages, including a better perineal tone and self-knowledge of her own genitalia
- If possible, with the woman's agreement, include the partner in the discussion, and encourage an exchange of views by the couple
- If the woman dislikes her genitalia or discloses a distress linked to her genitalia, schedule a new follow-up appointment; reassure her by explaining that adjusting to such a change can require time; and investigate the cause of the dislike and distress to allow it to be addressed

Johnson C, Nour NM. Surgical techniques: defibulation of Type III female genital cutting. J Sex Med. 2007 Nov;4(6):1544-7.

Jacoby S, D., & Smith A. Increasing Certified Nurse-Midwives' confidence in managing the obstetric care of women with female genital mutilation/cutting. 2013. Journal of Midwifery and Women's Health, 58(4), 451-456.

Marras S, Catania L, Abdulcadir O, Petignat P, Abdulcadir J. Defibulation: a visual reference and learning tool. 2017. J Sex Med. Submitted

Drawings reprinted with permission from World Health Organization. WHO guidelines on the management of health complications from female genital mutilation. Geneva, Switzerland: World Health Organization; 2016. Copyright 2016

Counseling guidelines reprinted with permission from Abdulcadir J, McLaren S, Boulvain M, Irion J. Health Education and clinical care of immigrant women with female genital mutilation/cutting who request postpartum reinfibulation. Int J Gynaecol Obstet. 2016 Oct;135(1):69-72.

Photos, illustrations and Q-score reprinted with permission from: Abdulcar J, Cantania L, Hindin MJ, Say L, Petignat P, Abdulcadir O. Female Genital Mutilation: A Visual Reference and Learning Tool for Health Care Professionals. Obstet Gynecol. 2016 Nov;128(5):958-963



Scan this image to view Video on your smartphone