

TROPHY

7th
EDITION

CONTEST



THEA INTERNATIONAL CONTEST OF CLINICAL
CASES IN PATHOLOGIES OF THE EYE



2018 - 2019 EDITION

MANAGING OCULAR SURFACE INFLAMMATION

THE BEST CLINICAL CASES
FROM 22 COUNTRIES



WWW.THEA-TROPHY.COM

 **Thea**
let's open our eyes



PREFACE

M^r. JEAN-FRÉDÉRIC
CHIBRET





M. Jean-Frédéric CHIBRET
President of Laboratoires Théa

Théa has focused its activities on research, development and commercialization of eye-care products, but at the same time has invested in education and knowledge promotion in line with the strong Chibret family tradition. In this way, Théa supports many projects and educational activities such as the European Meeting of Young Ophthalmologists (EMYO) or its partnership with the European Board of Ophthalmology (EBO).

In 2012, Théa launched its first annual contest: "TROPHY" (the Théa international Contest of clinical cases in Pathologies of the eye). The main objective of this contest is to encourage fellows and residents to participate actively in their speciality through the sharing of the results of their clinical cases and experience.

Every year has its own specific subjects: after "Glaucoma", "Glaucoma and ocular surface", "Persistent or recurrent corneal ulcers", "Management of corneal disorders", "Non-surgical treatment of corneal disorders", "Novel management of ocular surface disease", 2018's topic was "Managing ocular surface inflammation".

Anonymously chosen by a special board of experts, the top three winners are invited by Théa to present their clinical cases during the Théa symposium organized alongside the ARVO congress.

A constantly growing number of participants wish to submit their latest researches at this international symposium. In 2018, more than 200 ophthalmologists competed to be one of the three TROPHY contest winners.

We would like to thank all the judges, both national and international, who have helped to review the many cases submitted each year.

Finally, we would like to thank all the participants in past TROPHY competitions and warmly invite any young residents and fellows in ophthalmology to take part in the coming years.



PREFACE

PROFESSOR MAURIZIO
ROLANDO





Professor Maurizio ROLANDO
Professor of Ophthalmology, University
of Genoa, Italy

Laboratoires Théa's involvement in education in ophthalmology is outstanding and long-lasting. The annual Trophy contest is just one example. The first "Trophy" for clinical cases in Ophthalmology took place in 2012. Since then many interesting case reports have been submitted and discussed during the Trophy events by dedicated young ophthalmologists encouraged by Théa to share their knowledge and experience.

I was honored to be chair of the 7th edition of the Trophy which covered the topic "Managing ocular surface inflammation"

Altogether more than 200 fascinating cases discussing ocular surface inflammation were received from 23 countries this year. Interestingly, many complex clinical cases were submitted, and indeed all three winners presented intriguing, new treatment approaches to overcome severe ocular surface inflammation. This underlines the importance of treating inflammation in our care of patients with ocular surface disease.

The three winners from Italy (3rd place), Germany (2nd) and UK (1st), were chosen by an independent international jury. They presented cases of bilateral cyclical conjunctivitis in chronic myelomonocytic leukaemia, dry eye disease and severe ocular graft versus-host disease.

I hope you will enjoy reading this brochure as much as I did. Please share this brochure with your colleagues and encourage young ophthalmologists to apply for the next Trophy. You may even consider using some of the recommended novel medical and/or surgical options in the care of your patients with ocular surface disease.

.....

TROPHY WINNERS AT AWARDS CEREMONY

.....

The 3 winners of the 7th edition were:

1/ Dr Caroline WILDE

2/ Dr Yevgeniia ATISKOVA

3/ Pr Giuseppe GIANNACCARE

They won the opportunity to present their unpublished clinical cases to an international audience during the Théa symposium at the 2019 ARVO meeting chaired by professor Rolando.



Henri CHIBRET, Dr. Yevgeniia ATISKOVA, Pr. Giuseppe GIANNACCARE, Dr. Caroline WILDE,
.Prof. Maurizio ROLANDO, Jean-Frédéric CHIBRET.

TROPHY WINNERS AT THE THÉA ARVO SYMPOSIUM
IN VANCOUVER, MAY 2019



Prof. Maurizio ROLANDO, Henri CHIBRET, Dr. Caroline WILDE (1st Winner), Jean-Frédéric CHIBRET



Prof. Maurizio ROLANDO, Dr. Yevgeniya ATISKOVA (2nd Winner), Henri CHIBRET, Jean-Frédéric CHIBRET



Prof. Maurizio ROLANDO, Henri CHIBRET, Pr. Giuseppe GIANNACCARE (3rd Winner), Jean-Frédéric CHIBRET



3 WINNING CASES

2018 - 2019 EDITION



BILATERAL CYCLICAL CONJUNCTIVITIS IN CHRONIC MYELOMONOCYTIC LEUKAEMIA

13

Dr. Caroline WILDE
Moorfields Eye Hospital, London – UNITED KINGDOM



A CASE REPORT: DRY EYE DISEASE?

19

Dr. Yevgeniya ATISKOVA
Friedrich Schiller University, Jena – GERMANY



SEVERE OCULAR GRAFT VERSUS-HOST DISEASE: WHEN LIVING-RELATED DONORS CAN HELP TWICE

27

Pr. Giuseppe GIANNACCARE
S.Orsola-Malpighi Teaching Hospital, University of Bologna, Bologna - ITALY

★
25
BEST NATIONAL
CASES

2018 - 2019 EDITION



THE EFFECT OF SMOKING ON THE CORNEAL SURFACE 35

Dr. RhizLane ABDI
Hospital Mohammed VI, Oujda – MOROCCO

SUCCESSFUL MANAGEMENT OF SEVERE UNILATERAL INFLAMMATORY CORNEAL MELTING AS AN INITIAL PRESENTATION OF RHEUMATOID ARTHRITIS 41

Dr. Rosa ALVARADO
Universidad Peruana Cayetano Heredia – PERU

ACICLOVIR RESISTANT HERPETIC KERATITIS: AN EMERGING PROBLEM 49

Dr. Anne-Laurence BEST
Bicêtre Hospital, Le Kremlin-Bicêtre – FRANCE

A CHALLENGING GRAFT-VERSUS-HOST DISEASE CASE - A CONSERVATIVE TREATMENT 57

Dr. Oana-Maria BODEA
Emergency Clinical Hospital of Sibiu – ROMANIA

SERIOUS CORNEAL COMPLICATIONS FROM UNDIAGNOSED FLOPPY EYELID SYNDROME 67

Dr. Nizar DIN
Moorfields Eye Hospital, London – UNITED KINGDOM

NECROTIZING SCLERITIS AFTER “PTERYGIUM” EXCISION WITH MITOMYCIN C 73

Mrs. Anna FRIESACHER
Universitätsklinik für Augenheilkunde, Graz – SWITZERLAND

DEVELOPMENT OF INFLAMMATORY EYE DISEASES IN PATIENTS WITH ENDOCRINE OPHTHALMOPATHY AFTER THE ELIMINATION OF RESTRICTIVE STRABISMUS 79

Dr. Galina GLADYSHEVA
Bauman University, Moscow – RUSSIA

EVALUATION OF HYDROCORTISONE AS TREATMENT OF OCULAR GRAFT-VERSUS-HOST DISEASE: A CASE REPORT 87

Dr. Bárbara GONZALEZ
Hospital Universitario La Paz, Madrid – SPAIN

★
25
BEST NATIONAL
CASES

2018 - 2019 EDITION



A CASE OF REFRACTORY RECURRENT OCULAR GRAFT VERSUS HOST DISEASE	107
.....	
Mrs. Emilie GREENAN Trinity College Medical School, Dublin – IRELAND	
MASQUERADING CORNEAL GRAFT REJECTION-MANAGEMENT OF BILATERAL GRAFT HYDROPS FOLLOWING PENETRATING KERATOPLASTY IN A PATIENT WITH KERATOCONUS AND FLOPY EYELID SYNDROME	105
.....	
Dr. Ranko GVOZDENOVIC Institute of Ophthalmology, Clinical centre of Serbia, Faculty of Medicine, Belgrade - SERBIA	
CYCLOSPORINE - A REAL ALTERNATIVE	113
.....	
Dr. Tanja JURKUL Otto-von-Guericke University, Magdeburg – GERMANY	
TOTAL SCLERITIS PREDOMINANTLY POSTERIOR INDICATIVE OF HASHIMOTO THYROIDITIS	121
.....	
Dr. Malika KHEIDRI Hospital- universital center Issad Hassani, Beni Messous ,Algers – ALGERIA	
COMBINED USE OF TOPICAL CYCLOSPORINE 0.1% WITH A REGENERATIVE AGENT POLY (CARBOXYME THYLGLUCOSE SULFATE) FOR CORNEAL MELT SECONDARY TO GRAFT-VERSUS-HOST-DISEASE	131
.....	
Dr. Despoina-Georgia KOKOSIOULI National and Kapodistrian University of Athens, General Hospital of Athens – GREECE	
TOPICAL CYCLOSPORINE IN A SEVERE STEROID-DEPENDENT PHLYCTENULAR KERATOCONJUNCTIVITIS	137
.....	
Dr. Diogo LOPES Garcia de Orta Hospital, Almada – PORTUGAL	
REGENERATING AGENT PLUS SERUM EYE DROPS FOR THE TREATMENT OF PERSISTENT CORNEAL EPITHELIAL DEFECT: AUTOMATED QUANTITATIVE ASSESSMENT OF CORNEAL WOUND HEALING	143
.....	
Dr. Marco PELLEGRINI S.Orsola-Malpighi University Hospital, Bologna – ITALY	
ADVANCED STAGE MMP TREATED BY INTRAVENOUS CYCLOPHOSPHAMIDE	151
.....	
Dr. Maja POTRC University Medical centre Ljubljana, Ljubljana – SLOVENIA	

★
25
BEST NATIONAL
CASES

2018 - 2019 EDITION



CORNEAL MELTING AND PRESUMED HERPETIC KERATITIS: THE AMBIGUOUS ROLE OF CORTICOSTEROIDS AND ANTIVIRAL PROPHYLAXIS	159
.....	
Dr. Michèle TACK Ghent University, Ghent – BELGIUM	
COMBINED TREATMENT OF RECURRENT STROMAL HERPETIC KERATITIS WITH ULCERATION	167
.....	
Dr. Liudmyła TROICHENKO Odessa State Medical University, Odessa – UKRAINE	
VERNAL KERATOCONJUNCTIVITIS - WOLF IN SHEEP'S CLOTHING	175
.....	
Dr. Päivi VARONEN FINLAND	
TRANSPLANTATION OF AMNIOTIC MEMBRANE AND LIMBAL AUTOGRAFT FOR PATIENTS WITH RECURRENT PTERYGIUM	183
.....	
Dr. Maja VLADISAVLJEVIĆ LJUBAS General Hospital, Slavonski Brod – CROATIA	
MANAGEMENT OF ATYPICAL ACANTHAMOEBA KERATITIS IN A 48 YEAR-OLD WOMAN	189
.....	
Dr. Dominika WRÓBEL-DUDZIŃSKA Clinical Hospital No. 1, Department of Diagnostic and Glaucoma Microsurgery – POLAND	
LIMITED CONJUNCTIVAL FLEP FOR REPAIRING CORNEAL PERFORATION CLOSED TO VISUAL AXIS	197
.....	
Dr. Ugur YILMAZ Pamukkale University, Pamukkale – TURKEY	



Dr. Caroline WILDE
Moorfields Eye Hospital, London – UNITED KINGDOM

Caroline Wilde received her Bachelors of Medicine and Surgery with Honours, in 2012, from the University of Liverpool. She also won numerous prizes such as the “Trainee of the Year Award” in 2014 or the “Best research paper” delivered at HEYH School of ophthalmology Research Day in 2015. Dr Wilde is now working at the Moorfields Eye Hospital, London.



.....

BILATERAL CYCLICAL CONJUNCTIVITIS IN CHRONIC MYELOMONOCYTC LEUKAEMIA

.....

★ INTRODUCTION ★

Chronic myelomonocytic leukaemia (CMML) is a clonal haematopoietic stem cell disorder, characterised by overlapping features between myelodysplastic syndromes and myeloproliferative neoplasms, with an inherent tendency to transform to acute myeloid leukaemia.⁽¹⁾ Systemic inflammatory and autoimmune manifestations have been described in myeloid malignancies with a prevalence ranging from 10-20%. Presentations include systemic vasculitis, connective tissue disease, polyarthritis, polymyalgia rheumatica as well as skin manifestations including Sweet Syndrome.⁽²⁾ Allogeneic stem cell transplant currently remains the only curative option for younger and transplant-eligible patients but is limited by donor options and the inherent complications associated with allogeneic stem cell transplant.⁽¹⁾

We report a case of a 67 year old lady who presented to us with bilateral chronic conjunctivitis and was subsequently diagnosed with CMML. To our knowledge, conjunctivitis as the presenting feature of CMML has not been reported previously.

★ CASE PRESENTATION ★

A 67 year old lady presented to the eye casualty with 6 months history of red, inflamed eyes with epiphora and discharge. She has been treated with chloramphenicol with no improvement. There was no history of atopy or allergy. Past medical history included breast cancer treated with wide local excision and radiotherapy in 2009. She was treated with an aromatase inhibitor and breast cancer remains in remission.

Visual acuity was 6/9 in each eye with intraocular pressures of 12 and 14 mmHg in the right and left eyes. There was significant bilateral meibomian gland dysfunction and hyperaemia of the lid margin. The conjunctiva was injected with a papillary reaction and corneal punctate epithelial erosions were noted. She was treated with ocular lubricants.

A blood count demonstrated anaemia, monocytosis and thrombocytopenia (Hb 103 g/L, WBC $12.1 \times 10^9/L$, Monocyte $5.7 \times 10^9/L$, Neutrophil $4.5 \times 10^9/L$, Lymphocytes $1.5 \times 10^9/L$, platelet $34 \times 10^9/L$). Blood film showed monocytosis, dysplastic neutrophils. Bone marrow aspirate showed 95% cellularity with trilineage dysplasia and 11% blasts. Cytogenetics was normal. A diagnosis of CMML-2 was made.

She was then treated with six cycles of azacitidine. Azacitidine is given by subcutaneous injection on a daily basis from Monday to Friday and then Monday and Tuesday of the following week. The seven day course is repeated on a 28 day cycle.

She was reviewed in ophthalmology clinic after the fifth and sixth cycles of chemotherapy. The patient, a laboratory scientist, noted that each treatment with azacitidine improved her ocular symptoms. She reported that after the 7 days of treatment, her eyes would start to improve and by day 15, her eyes would return to normal. Then her symptoms would deteriorate towards the end of the cycle. At each of these visits the monocyte count was relatively low ($0 \times 10^9/L$ and $1.710 \times 10^9/L$ respectively) and the signs of conjunctivitis were relatively mild.

Following the sixth cycle, chemotherapy was stopped as she awaited haematopoietic stem cell transplant (HSCT). At review in ophthalmology clinic 6 weeks after her final cycle of chemotherapy, she reported increasing redness and soreness of the eyes. On examination, there was an increase in hyperaemia, papillae, chemosis and punctate epithelial erosions. Monocyte count had increased to $7.510^9/L$. She was treated with dexamethasone 0.1% preservative free drops hourly.

Two weeks later, she reported that her symptoms were extremely severe. Examination showed that despite intensive treatment with dexamethasone 0.1% drops, there was periocular dermatitis with marked conjunctival injection, papillae and corneal punctate epithelial erosions. Figure 2a and 2b

shows photographs of the right and left eyes at this time. Monocyte count at this visit was $11.910^9/L$. The dexamethasone 0.1% preservative free drops were reduced to twice daily in case her symptoms were due to toxicity and conjunctival biopsy was planned.

Right conjunctival biopsy a week later showed a chronic inflammatory cell population dominated by macrophage-like cells. Immunohistochemistry revealed that the macrophage-like cells are positive for CD14, CD68 and CD163. The proteins encoded by these genes are highly expressed in monocytes and macrophages. The cyclical change of patient's conjunctival symptoms is more in keeping with CMML induced inflammation that improves with each cycle of azacitidine rather than CMML infiltration.

One week later, after conditioning chemotherapy (Fludarabine, Mephalan and Campath), a matched unrelated donor allogeneic HSCT was performed. A bone marrow biopsy 100 days following HSCT showed complete remission. When reviewed in clinic a month following transplant, she reported that all her symptoms resolved after the transplant and examination showed mild conjunctival hyperaemia. Monocyte count had returned to normal levels. Figure 2c and 2d show photographs taken three months following HSCT. A reduction in conjunctival hyperaemia and oedema can be observed. At final review 6 months following HSCT, she was asymptomatic with a normal ocular surface examination and using no topical ocular medication.

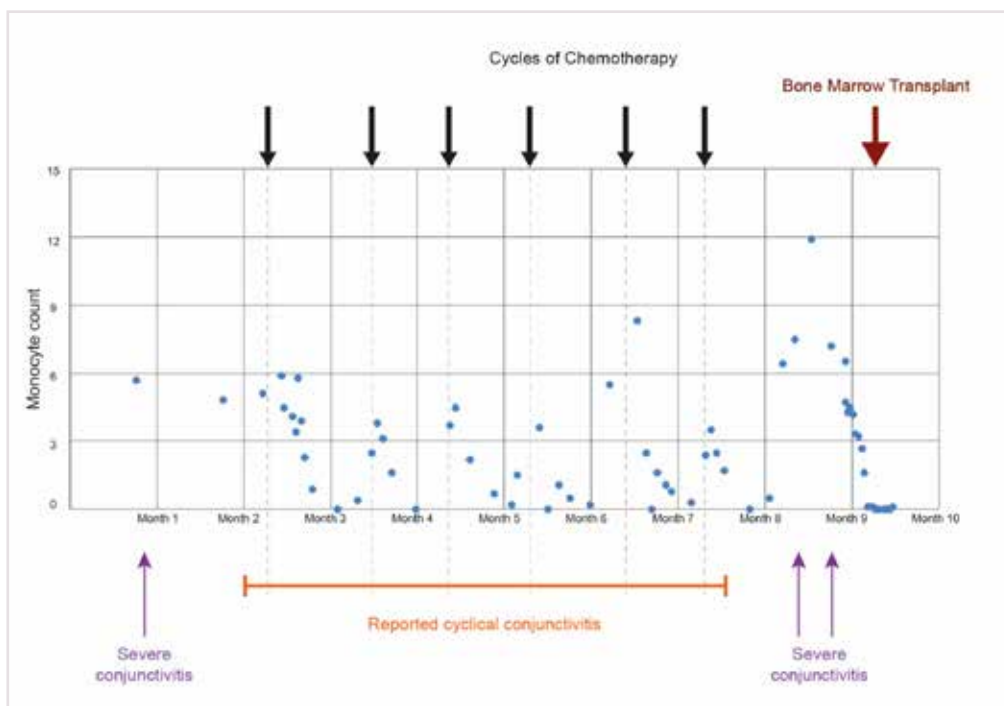


Figure 1 shows the monocyte count plotted against the date. The cycles of chemotherapy have been marked onto the graph. It can be seen clearly how the monocyte level increases and is reduced by the cycles of chemotherapy. After the final cycle of chemotherapy, the monocyte count continues to increase exponentially which was in keeping with the patient's severe symptoms. Following HSCT, the monocyte count returns to normal levels and the patient's disease went into remission.

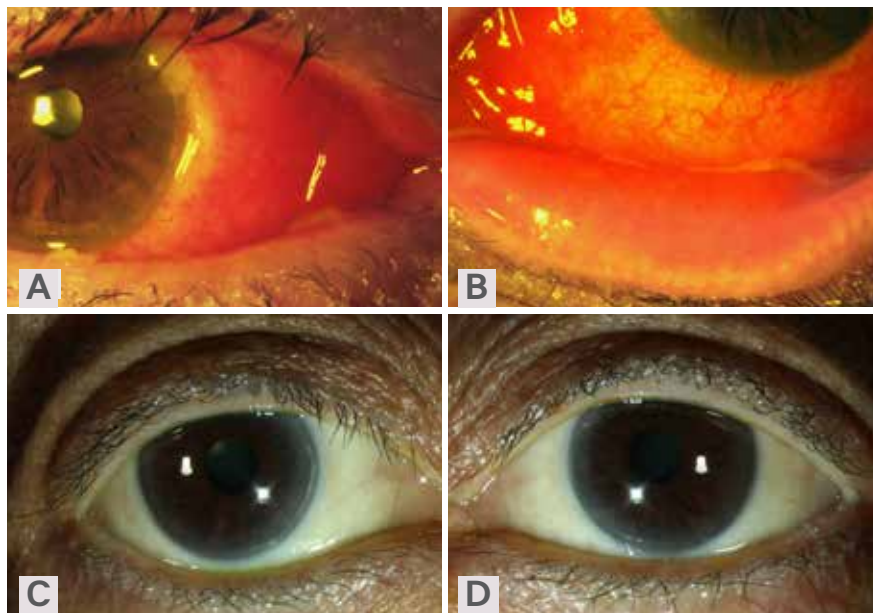


Figure 2: Photographs (a) and (b) show the right and left eye respectively whilst the patient has an elevated monocyte count before HSCT and is using hourly dexamethasone 0.1% preservative free drops. Marked conjunctival injection and oedema can be seen. Photographs (c) and (d) show the right and left eyes three months following HSCT and whilst the patient is not using any topical treatment. A reduction in conjunctival hyperaemia and oedema can be observed.

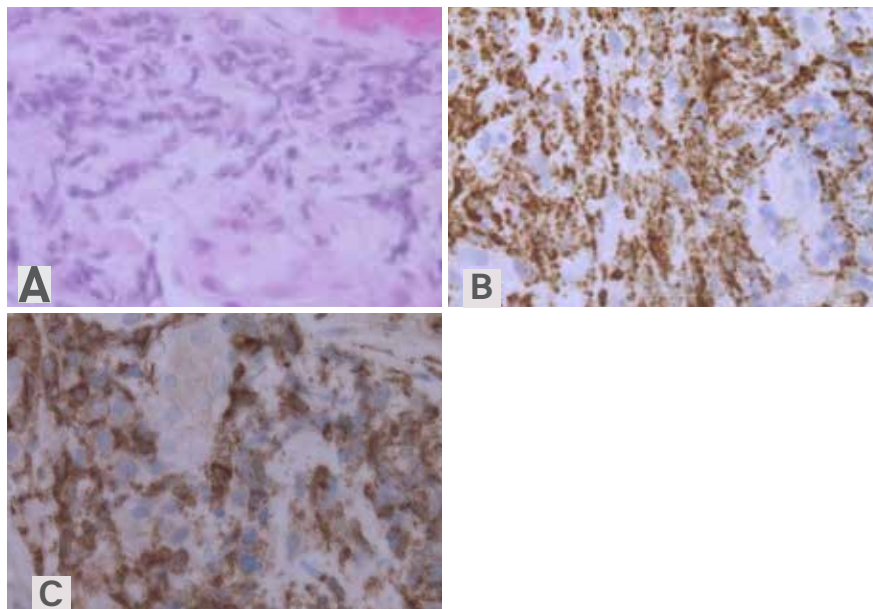


Figure 3: Haematoxylin and eosin staining (a) of a section of conjunctiva (60x) revealed dense inflammatory cell infiltration. Immunohistochemistry showed extensive staining for the macrophage marker CD68 (b). Immunohistochemistry staining with the marker CD14 (c) revealed a large population of these inflammatory cells to be monocytes.

★ DISCUSSION ★

Leukaemia may affect any tissue of the eye by direct invasion or secondary involvement. The posterior segment is more commonly affected with findings of increased retinal dilatation and tortuosity, haemorrhages, Roth spots and leukaemic infiltrates.⁽³⁾ In a retrospective study, Kezula et al, reported that 19 of 41 patients with myelodysplastic syndromes developed ocular complications including corneal ulcer, iridocyclitis, vitreous haemorrhage, retinal haemorrhage, cotton wool spots and optic neuritis.⁽⁴⁾ Conjunctival involvement is rare but occurs most often in patients with lymphocytic leukaemias⁽⁵⁾. Cases of chemosis, conjunctivitis, conjunctival mass and corkscrew vessels have been reported.⁽³⁾

In our case, the patient presented with conjunctivitis and was very symptomatic and resistant to treatment with topical steroids. Cycles of chemotherapy alleviated her symptoms and following a curative HSCT, her symptoms completely resolved. The conjunctivitis settled completely following HSCT. This is presumably due to normalization of the monocyte population and also to the immunomodulatory effect of HSCT. A biopsy was performed to examine for direct invasion of the conjunctiva but multidisciplinary review of immunohistochemistry by haematology and pathology concluded that this represented chronic inflammatory infiltrate. Secondary involvement with metastases was considered as ocular and leptomeningeal metastases can occur in leukaemias and lymphomas.⁽⁶⁾ It was also important to consider Sweet's syndrome which is characterised by fever, erythematous skin lesions and neutrophilic leucocytosis.⁽³⁾

Anterior uveitis and hypopyon have been described as a presenting feature of chronic myeloid leukaemia.⁽⁷⁾ Byrareddy et al describe two cases of anterior chamber hypopyon which were subsequently diagnosed as chronic myeloid leukaemia. Both cases resolved with induction of chemotherapy⁽⁸⁾

Patients with chronic conjunctivitis should be investigated to rule out masquerade syndromes. Referral to haemato-oncologist for further investigation and initiation of therapy may have potentially lifesaving implications.

★ REFERENCES ★

1. Patnaik MM, Parikh SA, Hanson CA, Tefferi A. Chronic myelomonocytic leukaemia: a concise clinical and pathophysiological review. *Br J Haematol.* 2014;165:273-86
2. Kipfer B, Daikeler T, Kuchen S, Hallal M, Andina N, Allam R et al. Increased Cardiovascular Comorbidities in Patients with Myelodysplastic Syndromes and Chronic Myelomonocytic Leukaemia Presenting with Systemic Inflammatory and Autoimmune Manifestations. *Seminars in Hematology* (2018), doi: 10.1053/j.seminhematol.2018.05.002
3. Sharma T, Grewal J, Gupta S, et al. Ophthalmic manifestations of acute leukaemias: the ophthalmologist's role. *Eye (Lond)* 2004;18:663-72
4. Kezuka T, Usui N, Suzuki E, Wakasugi K, Usui M. Ocular complications in myelodysplastic syndromes as preleukemic disorders. *Jpn J Ophthalmol.* 2005;49:377-383. doi: 10.1007/s10384-005-0228-6.
5. Duke-Elder S. *System of ophthalmology. Cornea and conjunctiva*, Vol V111. CV Mosby: St Louis, 1965; 1190-1195. 7 Allen RA, Straatsma BR. Ocular involvement in leukaemia and allied disorders. *Arch Ophthalmol* 1961; 66: 490-508. 8 Swartz M, Jampol LM. Comma-shaped venular segments of conjunctiva in chronic granulocytic leukaemia. *Can J Ophthalmol* 1975; 10: 458-461.
6. Decker EB, Burnstine RA. Leukemic relapse presenting as acute unilateral hypopyon in acute lymphocytic leukemia. *Ann Ophthalmol.* 1993;25:346-349.
7. Sudharshan S, Kumari A, Biswas J. Bilateral hypopyon as the presenting feature of chronic myeloid leukaemia.
8. Byrareddy R, Takkar B, Azad SV, Chawla R. Anterior chamber exudation in chronic myeloid leukaemia. *BMJ Case Rep.* 2016 Nov 28;2016. pii: bcr2016217173. doi: 10.1136/bcr-2016-217173.



Dr. Yevgeniya ATISKOVA
Friedrich Schiller University, Jena - GERMANY

Yevgeniya Atiskova obtained her Medical Degree in 2014, from the Friedrich Schiller University, Jena, in Germany. She is currently working in the Ophthalmology Clinic and Polyclinic at the University Hospital of Hamburg-Eppendorf, Germany.



A CASE REPORT: DRY EYE DISEASE?



★ INTRODUCTION ★

Ocular surface disease or dry eye syndrome are autoimmune disorders of the ocular surface. A recent study in Australia reported that more than 50% of people over 50 years of age suffer from dry eye symptoms, while women are more frequent affected.⁽¹⁾ Typical symptoms are epiphora, blurry vision, burning, redness and foreign body sensation.⁽²⁾ Meibomian gland dysfunction (MGD) is the most frequent reason for dry eye symptoms in adults causing chronic inflammation and hyperkeratinisation of the conjunctiva.⁽³⁾ Patients with mild symptoms are often diagnosed with dry eye disease and not followed up by ophthalmologists constantly, although eye involvement can be present in several systemic autoimmune disorders, particularly in Sjogren's syndrome, rheumatoid arthritis, lupus erythematosus, lichen planus, pemphigus, bullous pemphigoid, rosacea.⁽⁴⁻⁷⁾

★ CASE PRESENTATION ★

Here we describe the clinical course of a female patient, who was 58 years old at initial visit at our clinic. She presented with tearing and burning in her left eye for several weeks. The subjective visual acuity was unchanged. No symptoms were reported in the right eye. There were no operations or any ocular diseases in the past medical history. The patient had no internal diseases and did not take any drugs in the last months. The initial best corrected visual acuity was 20/25 on the right and 20/32 on the left eye. Intraocular pressure was normal. In the right eye a slight dysfunction of meibomian glands was remarkable, while conjunctiva, cornea and intraocular structures were not conspicuous. In the left eye also a meibomian gland dysfunction (MGD) was reported. Furthermore, a cicatricial conjunctival irritation was noticed subtarsal temporal and the conjunctiva was hyperemic. The first suggested diagnosis was MGD and cyclosporin 0.1% eye drops were prescribed. As a conjunctival scar was remarkable a conjunctival specimen was taken to exclude a chlamydia trachomatis infection. In addition vitamine A serum level and rheumatic parameters (ANA, ANCA, rheuma factor, Anti-Jo-1, Anti-Scl-70, Anti-Sm, Anti-SS-A (Ro), Anti-SS-B (La), Anti-U1-RNP) were analysed in serum for considering autoimmune disorders. All tests were negative and MGD remained as the primary diagnosis. As the patient observed an increased blurred vision after two weeks of application of the cyclosporin eye drops she stopped these and mostly used artificial tears. 2 months after initial presentation the patient reported an increased pain and redness of the left eye. Also itching occurred as an additional symptom. The visual acuity was reduced (20/50) on the left eye. Conjunctival hyperaemia was increased, the scarred retraction unchanged and an irregular corneal surface with keratitis superficialis punctata was noticed. The right eye was normal with no discomfort. Due to ongoing meibum stasis and inflammation, oral doxycycline 40mg once a day was prescribed for 6 weeks. In addition lubricating gel and oxytetracycline eye ointment was ordered. After further 6 weeks the patient had a visual decline (20/200) on her left eye. Slit lamp examination revealed serious keratitis superficialis punctata and a beginning formation of a tarsal symblepharon. Regarding the worsening of the symptoms and the general skin condition of the patient we supposed that a possible diagnosis could be blepharoconjunctivitis associated with rosacea. Due to acute deterioration we recommended local steroids, artificial tears as well as cyclosporin A eye drops.

About 6 months after initial presentation a conjunctival metaplasia was remarkable in the left eye.

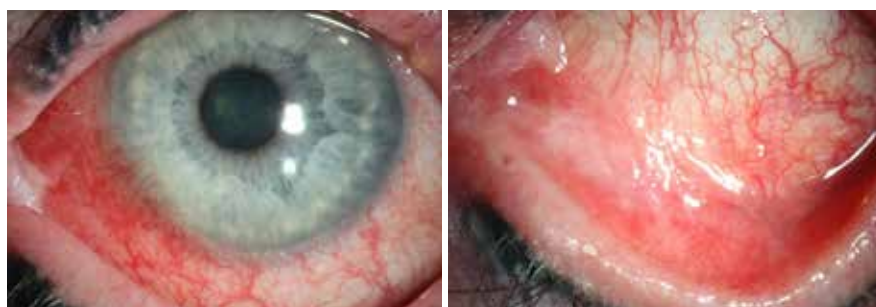

Figure 1. Clinical case presentation 6 months after initial visit. Progressive symblepharon formation, redness and conjunctival metaplasia in the left eye.

A CASE REPORT: DRY EYE DISEASE?

Due to this new finding a conjunctival biopsy was performed. The histological investigation revealed an acanthosis of conjunctival squamous epithelium and chronic inflammation with conjunctival scars. The pathological result explained no dysplasia or malignant signs. The oral therapy with doxycycline 100mg per os was continued for two more months. As a massive progression of symblepharon formation and beginning vascularisation of the cornea was remarkable, a second conjunctival biopsy was performed with special remark on signs for ocular pemphigoid and lichen planus.

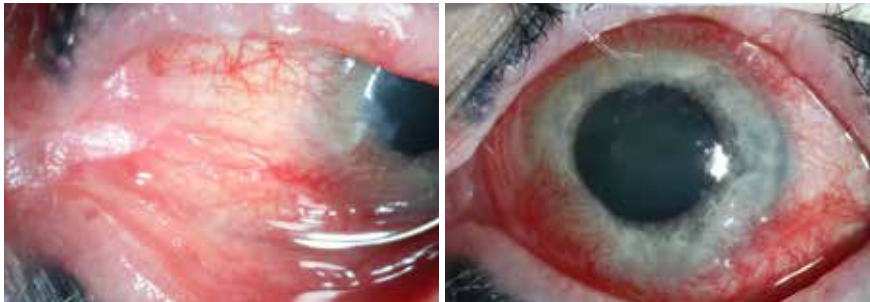

Figure 2. Massive deterioration at 8.5 months after initial presentation. Progressive symblepharon formation as well as corneal vascularisation in the left eye.

The histopathological result showed granular immunofluorescence of complement 3 (C3) at the basal membrane zone, what suggested lichen planus. Additional serum tests were performed with no detection of anti-basal antibodies. As an autoimmune disease was suspected, local immunosuppressive therapy (cyclosporin eye drops 1% and local corticosteroids) as well as systemic immune suppression (corticosteroids 1mg/kg body weight initial dose with slowly reduction, azathioprin 50mg) were administered. About 6 weeks of immunosuppressive therapy the patient showed a profound worsening of visual acuity (6/190), epiphora, pain and redness of the left eye. At the ophthalmological examination symblepharon formation was increased, scars and metaplastic conjunctival areas were not reduced. A progressive circular vascularization and subtotal corneal erosion were noticed. After a rapid progressive deterioration of corneal and conjunctival condition and a recently observed progressive strong swelling of the caruncula on immunosuppression over 2 months a third biopsy was performed.

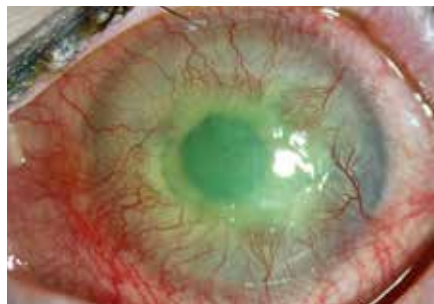

Figure 3. 2.5 months after local and systemic immunosuppressive therapy. Further deterioration of the conjunctival and corneal inflammation with massive vascularization and ongoing cicatricial conjunctivitis.

Within the operation a solid tumorous lesion was noticed next to the plica semilunaris. An encapsulated tumor, which expanded in the superior and inferior lacrimal canaliculus and posterior orbital region, was remarkable. The surgeon decided to excise a 10x10mm part of the lesion for histopathological analysis. A macroscopic full resection was not possible in primary surgery, due to the expanded manner of the lesion into the posterior orbit. The histopathological result was a high grade poorly differentiated neuroendocrine carcinoma of the left orbit (cN0 cM0). The systemic immunosuppressive therapy was stopped immediately. A cranial MRI investigation showed no signs of infiltration of the tumorous lesion in adjacent tissue or infiltration of the lamina papyracea. A local inflammatory reaction after excision of the tumor was conspicuous at the medial lid, conjunctiva and orbit. A full body F18-FDG-PET/CT showed also no signs of local enrichment of the radiopharmakon. Low enrichment was associated with the previous surgical excision. A conspicuous focus was visible in the right os ileum. Experts of different clinical departments (ophthalmology, oral and maxillofacial surgery, pathology, oncology, radiotherapy) discussed the case in a specialized tumor board. The common decision recommended a radical resection of the tumor and surrounding tissue. An orbital exenteration with following adjuvant radiochemotherapy was recommended as the prognosis of intraorbital poorly differentiated neuroendocrine cancer is poor⁸. Also a biopsy of the focus in the os ileum was discussed. The patient refused this extensive surgery and decided to receive only radiotherapy and chemotherapy after a detailed consultation about the reduced prognosis was held with her. Currently radiotherapy (cyberknife; 6 cycles with 6 gray) is ongoing and a chemotherapy is planned to start (4-6 cycles of 3 weeks therapy with carboplatin and etoposid). The conspicuous focus in the os ilium should be reassessed after passed chemotherapy.

A trophic corneal ulcer appeared under radiotherapy which is under treatment with serum eye drops, local antibiotics (ofloxacin) and preservative-free artificial tears. The corneal integrity is stable at the moment while the visual acuity unfortunately decreased (hand movement).

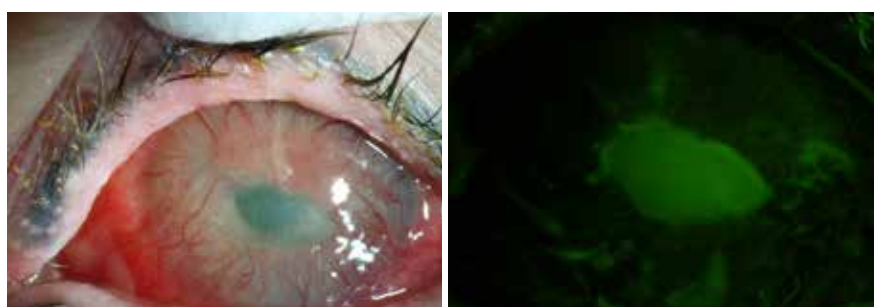


Figure 4. Trophic corneal ulcer with progressing vascularisation right after radiotherapy. Intense local therapy is necessary.

★ DISCUSSION ★

The previous report describes a case with challenging diagnose finding. As the patient reported mild symptoms at good visual acuity at the initial visits meibomian gland dysfunction was supposed to be the diagnosis. While the presented symptoms were getting worse further investigations as conjunctival biopsy were performed for diagnose finding and a therapy was assimilated. Dermatological diseases as rosacea, acne vulgaris or atopic dermatitis can be associated with ocular surface diseases. Rosacea is a chronic skin disease commonly affecting sebaceous glands in patients between 50 and 60 years of age. Typical ocular manifestations are chronic inflammation of eye lids and conjunctiva⁹. However also the formation of pyogenic granuloma, symblepharon and conjunctival adhesions as well as reduction of visual acuity were described in patients suffering from rosacea^{5, 10}. Due to clinical observations and histopathological results of the conjunctival biopsy a blepharoconjunctivitis associated with rosacea was assumed. As a therapeutic effect of systemic doxycycline was absent, a second biopsy with special investigations was performed to especially prove if there were evidence for ocular pemphigoid or lichen planus. These are very rare disorders, yet they initially present with similar symptoms^{6,11}. Progressive conjunctivitis, keratinization of conjunctiva and eye lids as well as symblepharon formation and keratopathy are well known findings in ocular pemphigoid^{12,13}. Ocular pemphigoid is a rare systemic chronic autoimmune disease which affects more women than men. In several cases diverse mucous tissues, e.g. oral, gastrointestinal or urogenital mucosa, are affected in addition to the conjunctiva^{12,13}. However, unilateral involvement of the eye may also occur at initial presentation¹². Today's diagnostic standard is immunohistopathology examination using the immunofluorescent or immunoperoxidase technique of conjunctival biopsy as we performed in the presented case¹⁴. Long term remission may be achieved by immunomodulatory therapy with corticosteroids, dapsone, methotrexate, azathioprine, mycophenolate mofetil, cyclophosphamide, rituximab or immunoglobuline in this disease^{14,16}. Furthermore, lichen planus, an inflammatory autoimmune disease, can present with uni- or bilateral ocular manifestation involving conjunctiva, cornea, and lacrimal drainage system. Typical findings are cicatricial conjunctivitis with subepithelial fibrosis, fornix shortening and symblepharon formation as described in the presented patient^{6, 17,18}. Also, systemic manifestation is possible with inflammatory affection of other mucosal tissue^{19,20}. Dense linear and shaggy fibrinogen deposits and deposition of IgM and C3 along the basement membrane zone are typical for immunofluorescence in biopsy of the conjunctiva in lichen planus²⁰. Topical therapy with corticosteroids and cyclosporine eye drops is recommended. In severe disease progression also a systemic immunosuppression should be administered⁶. Due to immunohistopathological analysis of the second biopsy the diagnosis lichen planus was considered in the present case and a topical and systemical immunomodulating therapy was applied as recommended.

As described before a massive deterioration was noticed after immunosuppressive therapy. Due to this observation a third biopsy was performed. During the operation a suspicious tumorous lesion was detected and partly removed for histopathological analysis. The histopathological result showed a neuroendocrine tumor. Single cases with paraneoplastic lichen planus associated with follicular, small-cleaved cell lymphoma and malignant thymoma were described previously²¹. A paraneoplastic lichen planus is a very rare possible cause of cicatrizing conjunctivitis. To our knowledge an ocular paraneoplastic lichen planus without any other manifestations was not described yet. It remains unclear, whether the observed lichen planus is a secondary paraneoplastic finding caused by the neuroendocrine cancer or the primary disease. An exacerbation of the cancer manifestation under immunosuppressive therapy of the lichen planus should also be considered.

Neuroendocrine intraorbital tumors are very rare malignancies. In most cases they are metastases with primary tumors in other organs. Systemic symptoms can occur due to possible endocrine activity of the tumor. A wide spectrum of different cell types exists, while a poor differentiated high-grade neuroendocrine tumor is associated with a poor prognosis.

★ CONCLUSION ★

Diagnose finding in ocular surface disease is very challenging as different diseases can present initial similar symptoms. Dry eye symptoms are typical for several autoimmune diseases but can be also shown in context with infections, traumata or cancer.

In complex clinical cases with slowly progressive clinical manifestations, as presented here, months or even years can pass by until right diagnose making. A detailed photographical documentation can be very helpful in evaluation of slowly changing findings. Even though dry eyes are a widespread disease, dry eye symptoms should always be taken seriously and followed up by ophthalmologists. Frequent controls and intensive examinations with blood withdrawals for investigation of autoimmune markers and blood count, biopsy and also neuroimaging (craniofacial MRI) are important in complex cases with atypical symptoms and progressive courses as cicatrizing conjunctivitis and ocular surface disease may be associated with paraneoplastic disease and malignancy.

★ REFERENCES ★

1. Chia EM, Mitchell P, Rochtchina E, Lee AJ, Maroun R, Wang JJ. Prevalence and associations of dry eye syndrome in an older population: the Blue Mountains Eye Study. *Clin Exp Ophthalmol* 2003;31:229-232.
2. Nebbioso M, Del Regno P, Gharbiya M, Sacchetti M, Plateroti R, Lambiase A. Analysis of the Pathogenic Factors and Management of Dry Eye in Ocular Surface Disorders. *Int J Mol Sci* 2017;18.
3. Knop E, Knop N, Millar T, Obata H, Sullivan DA. The international workshop on meibomian gland dysfunction: report of the subcommittee on anatomy, physiology, and pathophysiology of the meibomian gland. *Invest Ophthalmol Vis Sci* 2011;52:1938-1978.
4. Generali E, Cantarini L, Selmi C. Ocular Involvement in Systemic Autoimmune Diseases. *Clin Rev Allergy Immunol* 2015;49:263-270.
5. De Marchi SU, Cecchin E, De Marchi S. Ocular rosacea: an underdiagnosed cause of relapsing conjunctivitis-blepharitis in the elderly. *BMJ Case Rep* 2014;2014.
6. Mohebbi M, Mirghorbani M, Banafshe Afshan A, Towfighi M. Lichen Planus in Ocular Surface: Major Presentations and Treatments. *Ocul Immunol Inflamm* 2018;1-8.
7. Tan JC, Tat LT, Francis KB, Mendoza CG, Murrell DF, Coroneo MT. Prospective study of ocular manifestations of pemphigus and bullous pemphigoid identifies a high prevalence of dry eye syndrome. *Cornea* 2015;34:443-448.
8. Jorgensen M, Heegaard S. A review of nasal, paranasal, and skull base tumors invading the orbit. *Surv Ophthalmol* 2018;63:389-405.
9. Steinhoff M, Schaubert J, Leyden JJ. New insights into rosacea pathophysiology: a review of recent findings. *J Am Acad Dermatol* 2013;69:515-26.
10. Rahman MQ, Lim Y, Roberts F, Ramaesh K. Fibrosing blepharo-conjunctivitis following pyogenic granuloma in ocular acne rosacea. *Ocul Immunol Inflamm* 2010;18:346-348.
11. Williams GP, Nightingale P, Southworth S, et al. Conjunctival Neutrophils Predict Progressive Scarring in Ocular Mucous Membrane Pemphigoid. *Invest Ophthalmol Vis Sci* 2016;57:5457-5469.
12. Ahmed M, Zein G, Khawaja F, Foster CS. Ocular cicatricial pemphigoid: pathogenesis, diagnosis and treatment. *Prog Retin Eye Res* 2004;23:579-592.
13. Foster CS, Sainz De La Maza M. Ocular cicatricial pemphigoid review. *Curr Opin Allergy Clin Immunol* 2004;4:435-439.
14. Kirzhner M, Jakobiec FA. Ocular cicatricial pemphigoid: a review of clinical features, immunopathology, differential diagnosis, and current management. *Semin Ophthalmol* 2011;26:270-277.
15. Hingorani M, Lightman S. Ocular cicatricial pemphigoid. *Curr Opin Allergy Clin Immunol* 2006;6:373-378.
16. You C, Ma L, Anesi SD, Stephen Foster C. Long-term remission of ocular cicatricial pemphigoid off immunomodulatory therapy. *Eur J Ophthalmol* 2018;28:157-162.
17. Huang S, Channa P. Cicatricial keratoconjunctivitis associated with lichen planus. *GMS Ophthalmol Cases* 2015;5:Doc08.
18. Huerva V. Lichen planus on the ocular surface. *Cutan Ocul Toxicol* 2015;34:232-233.
19. Brewer JD, Ekdawi NS, Torgerson RR, et al. Lichen planus and cicatricial conjunctivitis: disease course and response to therapy of 11 patients. *J Eur Acad Dermatol Venereol* 2011;25:100-104.
20. Thorne JE, Jabs DA, Nikolskaia OV, Mimouni D, Anhalt GJ, Nousari HC. Lichen planus and cicatrizing conjunctivitis: characterization of five cases. *Am J Ophthalmol* 2003;136:239-243.
21. Hahn JM, Meisler DM, Lowder CY, Tung RC, Camisa C. Cicatrizing conjunctivitis associated with paraneoplastic lichen planus. *Am J Ophthalmol* 2000;129:98-99.



Pr. Giuseppe GIANNACCARE
S.Orsola-Malpighi Teaching Hospital, University of Bologna, Bologna - ITALY

Giuseppe was born in Italy. He has a position of Researcher, Ophthalmologist, S.Orsola-Malpighi University Hospital, University of Bologna, Italy.



.....

SEVERE OCULAR GRAFT VERSUS-HOST DISEASE: WHEN LIVING-RELATED DONORS CAN HELP TWICE

.....

★INTRODUCTION★

Although Intra Ocular Pressure (IOP) remains a significant factor in glaucoma disease, many cases of glaucoma occur in the absence of high pressure readings during exams. In some cases, vascular factors appear to be particularly important and there is building evidence that systemic vascular dysregulation plays a major role. Allogeneic hematopoietic stem cell transplantation (allo-HSCT) is presently the treatment of choice for a variety of malignant hematologic disorders¹. Stem cells can be donated by relatives (when available), or by healthy volunteers. The aim of HSCT is to obtain the continued remission of the malignancy through the allo-response (“graft versus-leukemia”). Unfortunately, this phenomenon is intimately associated with graft versus-host disease (GVHD), an autoimmune-like reaction directed against a broad spectrum of recipient tissues, including the eye.

The inflammation of the ocular surface is the hallmark of chronic ocular GVHD, and similarly to other autoimmune-mediated ocular surface diseases, the inflammatory damage determines fibrotic changes of the ocular surface and adnexa, which are obstacles for the effective treatment of this condition. The most common clinical features consist of dryness, conjunctival fibrosis, punctate and/or filamentous keratopathy, superior limbic keratoconjunctivitis (SLK), recurrent erosions, chronic blepharitis, atrophy and irregularity of the eyelid margin, which may eventually induce keratinization of the tarsal conjunctiva and symblephara. In most severe cases, on one side SLK-related inflammation can potentially result in permanent limbal stem cell deficiency (LSCD), characterized by conjunctivalization and keratinization of the cornea with superficial and deep vascularization, as well as persistent epithelial defects. On the other side, immune-mediated inflammation of the bulbar

conjunctiva can determine the destruction of goblet cells, leading to dry eye, sterile corneal ulcer, melting and perforation². At this stage, there is no chance of visual rehabilitation through conventional management with topical anti-inflammatory treatment, including corticosteroids and cyclosporine.

CONJUNCTIVAL-LIMBAL GRAFT: SURGICAL TECHNIQUE

Westcott scissors are used to dissect from the donor eye the trapezoidal-shaped superior conjunctival tissue (about 10 x 5 mm) attached to a lamellar kerato-limbal tissue containing the limbal stem cells (about 10 x 1 mm) (Figure 1).

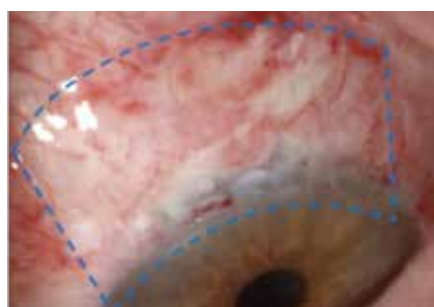


Figure 1. Clinical picture illustrating the harvest site of the donor eye outlined by the blue dotted line

Then, the dissection and removal of a superior kerato-limbal and conjunctival Lenticule of similar size is performed in the recipient eye. The harvested tissue is sutured into place using interrupted 8-0 vicryl stitches, which are reabsorbed within few weeks, taking care to maintain the orientation of the graft. Topical betamethasone/chloramphenicol/tolitetraacycline ointment is applied, and the eye is pressure patched for 48 hours. No systemic immunosuppression is required either pre- or postoperatively.

★ CASE PRESENTATION ★

PATIENT #1

A 59-year-old man was referred to our Institution for his recalcitrant severe ocular GVHD with intense photophobia and bilateral visual impairment. In 2005, he had been treated for acute myeloid leukemia with an allo-HSCT procedure, with his sister as donor. Few years later, he developed severe ocular GVHD that was treated with topical and systemic immunosuppressants. Superficial lamellar keratectomy followed by amniotic membrane transplantation had been performed in both eyes (OU), and uneventful cataract surgery in right eye (OD). Two episodes of corneal perforations occurred in left eye (OS):

SEVERE OCULAR GRAFT VERSUS-HOST DISEASE: WHEN LIVING-RELATED DONORS CAN HELP TWICE

the first one was treated with cyanoacrylate glue and staged penetrating keratoplasty (PK); the second one with conjunctival flap according to Gundersen technique and temporary complete tarsorrhaphy.

Upon presentation, slit-lamp examination revealed in OD severe meibomian gland dysfunction (MGD), intense conjunctival injection, superficial and deep corneal neovascularization involving the visual axis (Figure 2, part A). His OS presented severe MGD, intense conjunctival injection and conjunctival flap covering the corneal graft with an area of focal thinning (descemetocoele) in the supero-nasal quadrant (Figure 2, part B).

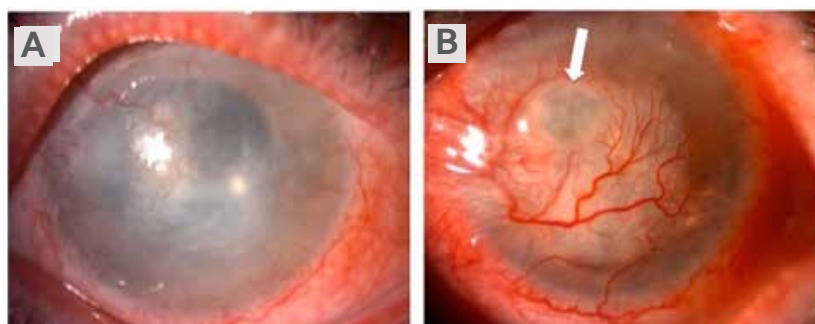


Figure 2. Clinical appearance of both eyes of Patient #1 at the time of presentation. Part A: Severe MGD, intense conjunctival injection, superficial and deep corneal neovascularization involving the visual axis in OD. Part B: Severe MGD, intense conjunctival injection, conjunctival flap covering the corneal graft. Note the area of focal thinning (descemetocoele) (white arrow) in the supero-nasal quadrant.

The Ocular Surface Disease Index (OSDI) score was 89, while Schirmer Test type I measured below 1 mm/5' in OU. Visual acuity was limited to 20/200 in OD and to light perception in OS. The patient's general health was good, with a normal blood cell count and no other organs involved by GVHD. The intense ocular surface inflammation was managed aggressively in OU with topical corticosteroid (0.3% hydrocortisone sodium phosphate) 4 times daily (qid), cyclosporine 1mg/mL twice daily (bid), trehalose/hyaluronate-based tear substitute every 2 hours, rolitetracycline/betamethasone/chloramphenicol ointment at bedtime, warm compresses and lid hygiene. However despite treatment, clinical picture remained approximately unchanged in OU, while anterior-segment Optical Coherence Tomography documented a progressive focal thinning of the cornea in OS. Therefore, we decided to proceed in this eye with transplantation a graft including conjunctiva and limbus obtained from the same living-related bone marrow donor (sister), according to the technique described above. Surgery was uneventful, and as early as one month postoperatively, patient's discomfort symptoms and signs of ocular surface inflammation began to improve. Six months postoperatively, the OSDI score decreased to 28, and Schirmer Test type I increased to 4 mm/5' in OS. Furthermore, conjunctival injection and peripheral corneal neovessels decreased significantly, with an increased thickness at the site of descemetocoele (Figure 3, part A). Conjunctival and corneal cells with donor chromosomes (XX, female) were identified in the recipient bed by fluorescence in situ hybridization 6 months after surgery (FISH) (Figure 3, part B).

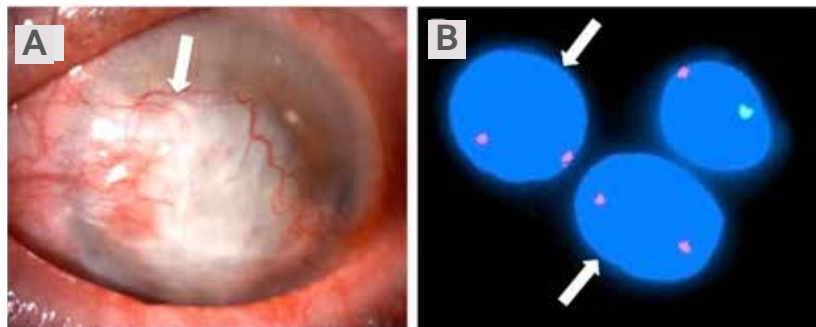


Figure 3. Part A: Clinical appearance of OS 6 months after conjunctival-limbal transplantation. Note the significant decrease of both conjunctival injection and peripheral corneal neovessels; in addition an increased thickness at the site of descemetocoele was observed (white arrow). Part B: FISH analysis with chromosome-specific painting DNA probes showed the presence of cells that expressed donor chromosomes (XX, sister; red circles) (white arrows) in the recipient bed 6 months after transplantation.

Currently, 8 months postoperatively, ocular surface condition is stable in OU, and patient is candidate for mushroom keratoplasty for optical indication in OS.

PATIENT #2

A 60-year-old man was referred to our Institution for ocular GVHD with severe bilateral visual impairment, and history of recurrent multiple corneal perforations in OS. In 2006, he had been treated for acute myeloid leukemia with an allo-HSCT obtained from a volunteer donor. Few months later, he developed ocular GVHD which worsened progressively over the subsequent years, particularly in OS where he experienced multiple corneal perforations (8 episodes), treated with different strategies including cyanoacrylate patch, tectonic PK, conjunctival flap and complete tarsorrhaphy.

Upon presentation, slit-lamp examination revealed severe MGD with diffuse punctate keratopathy (Oxford score 5 out of 5) in OD (Figure 4, part A). In OS, a retracted conjunctival flap with inferior paracentral corneal perforation and a mature white cataract were visible behind the tarsorrhaphy (Figure 4, part B).

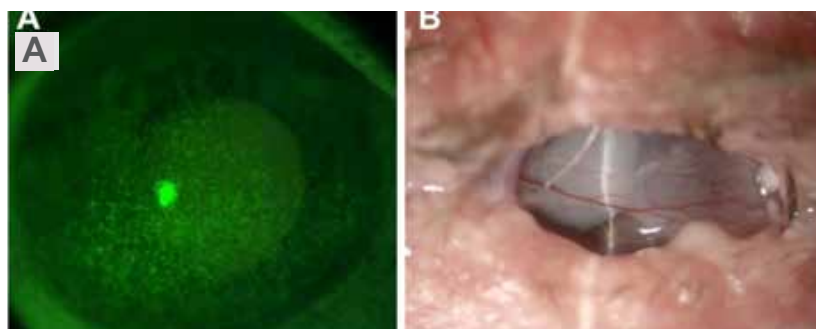


Figure 4. Part A: Slit lamp photography under cobalt blue illumination with the aid of a 7503 Boston Yellow Filter Kit showing the diffuse punctate keratopathy using 2% sodium fluorescein (Oxford score 5) in OD. Part B: Clinical appearance of OS showing retracted conjunctival flap with inferior paracentral corneal perforation and mature white cataract behind the tarsorrhaphy.

SEVERE OCULAR GRAFT VERSUS-HOST DISEASE:
WHEN LIVING-RELATED DONORS
CAN HELP TWICE

The OSDI score was 90, and Schirmer Test type I measured below 1 mm/5' in OU. Visual acuity was limited to 20/200 in OD due to the concomitant presence of central retinal vein occlusion, and to light perception in OS. The patient's general health was good with a normal blood cell count. The dry eye syndrome was managed only topically in OD with umbilical cord blood serum eye drops every 2 hours, corticosteroid (0.3% hydrocortisone sodium phosphate) qid, cyclosporine 1mg/mL bid, warm compresses, lid hygiene and rolitetracycline/betamethasone/chloramphenicol ointment at bedtime. This therapy allowed a good control of ocular surface inflammation in OD, thus the clinical picture remained stable over the 1-year follow-up. Furthermore, 6 intravitreal injections of anti-vascular endothelial growth factor (VEGF) combined with laser photocoagulation were performed to manage the immune-mediated retinal disease and avoid neovascular complications. Conversely, complex surgery including lensectomy, tectonic PK and conjunctival flap according to Gundersen technique was required in OS (Figure 5, part A). Although an uneventful surgery and a strong anti-inflammatory postoperative treatment (oral cyclosporine and dexamethasone bid, topical prednisolone acetate qid, cyclosporine bid, short-term levofloxacin qid, lubricants and ointments every 2 hours), sterile corneal perforation occurred again requiring a new tectonic PK. Early postoperative course was regular, but two months later a persistent epithelial defect appeared and progressed rapidly to stromal ulceration and descemetocoele formation (Figure 5, part B). Another PK was performed along with the injection of botulinum toxin A to induce ptosis. Currently, two months after the last surgery, corneal graft is quite clear but a large epithelial defect is still present (Figure 5, part C).

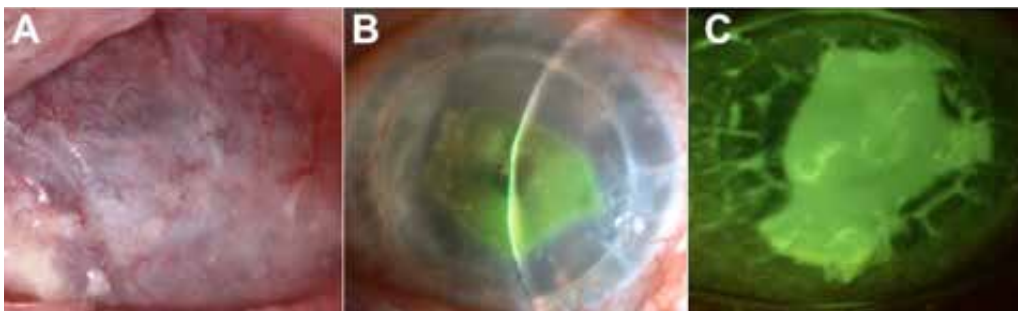


Figure 5. Clinical appearance of OS during the course of the disease. Part A: Normally-vascularized conjunctival Gundersen flap few days after surgery. Part B: Persistent epithelial defect of the PK graft progressed to stromal melting and central descemetocoele. Part C: Persistent epithelial defect of the last PK graft 2 months after surgery.

Theoretically, this case would benefit from conjunctival-limbal graft (like Patient #1), but since HSCT was obtained by an anonymous volunteer donor, this technique is not feasible. However, we sent an official request to the Bone Marrow Donor Registry of our Country, and we are still waiting the authorization for asking the same donor to donate again. If conjunctival-limbal donation from the same bone marrow donor will be not practicable for legislative issues, we will evaluate other possible options for the challenging management of this patient, including Boston Keratoprosthesis, oral mucosa graft or conjunctival flap plus complete tarsorrhaphy.

★ DISCUSSION ★

Ocular GVHD is a major complication following allo-HSCT occurring in a significant percentage of transplanted patients. The intense inflammation of the ocular surface determines LSCD with corneal conjunctivalization and neovascularization; in addition, the extreme dryness causes the onset of persistent epithelial defect that often progresses to corneal ulceration, melting and perforation.

Recently, our Group proposed for the first time the transplantation of a conjunctival-limbal graft obtained from the same living-related bone marrow donor in the setting of ocular GVHD. On one side, the conjunctival graft provides to the recipient bed the goblet cells that are essential for the production of the mucus layer of the tear film. On the other side, the limbal graft provides the amount of stem cells fundamental for the regeneration of the corneal surface, the recovery of corneal transparency and the healing of corneal ulcer. This approach is based on the hypothesis formulated by Starzl (pioneering transplant surgeon and Nobel prize recipient) that the bone-marrow transplantation induces chimerism and consequent tolerance to tissue transplanted from the same donor at the same or later time (Figure 6, parts A-B).^{4,5}

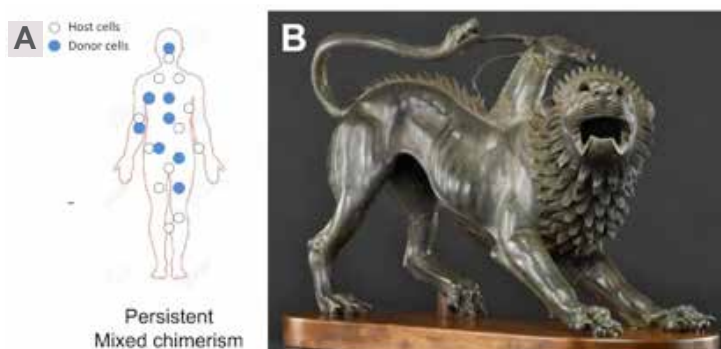


Figure 6: Part A: Persistent mixed chimerism induced after HSCT (from Oura T et al. Clin Exp Immunol. 2017); Part B: The "Chimera of Arezzo" is an Etruscan bronze of 400 BC that was found in 1553 in Arezzo, and brought to Florence to join the collections of the Grand Duke Cosimo I de' Medici and set up in the hall of Leo X in Palazzo Vecchio. In 1871 it was transferred to the Archaeological Museum of Florence.

Based on this hypothesis, Kawai and co-Authors were also able to discontinue all immunosuppressive therapy in four of five patients receiving a combined transplantation of HLA-mismatched bone marrow and kidney.⁶

The initial results of our technique are extremely encouraging. The procedure improved tear secretion, decreasing ocular surface inflammation and causing a marked regression of corneal neovessels. Transplanted cells survived in the recipient environment for at least 6 months, as demonstrated by FISH analysis performed in the case with donor-recipient sex mismatch (Patient #1). It must be highlighted that our surgical approach succeeded without any sign of rejection in the absence of any systemic immunosuppression. Conversely, in the past HLA matched (identical or haplo-identical) allograft conjunctival transplantation obtained from relatives has been used for treating severe bilateral dry eye conditions including Stevens-Johnson and Lyell syndrome as well as chemical burns. However, episodes of rejection were noticed within

the first year after surgery in a significant percentage of cases.⁷ Furthermore, combined conjunctival limbal allografts and keratolimbal allografts have been proposed for the treatment of severe ocular surface failure secondary to Steven-Johnson syndrome, ocular cicatricial pemphigoid, chemical/thermal injuries, and severe atopic keratoconjunctivitis. However, systemic and/or topical long-term immunosuppressive medications were required throughout the entire follow-up period.⁸

Our procedure can eventually be repeated safely even more times in case of "exhaustion" of the transplanted tissue, since the recovery of normal anatomy and function has been demonstrated to occur within 1 year from harvesting in the donor eye.

Unfortunately, only half of all GVHD patients received HSCT from a sibling, and thus can benefit from this technique. On the contrary, patients who received stem cell from volunteer donor are not eligible (at least in our Country) since the Bone Marrow Donor Registry does not allow any direct contact between donors and recipients throughout the entire course of care.

★ CONCLUSION ★

Transplantation from the living-related bone marrow donor of both conjunctiva and limbal epithelial stem cells is effective for the treatment of patients with severe ocular GVHD. In these cases, the intense ocular surface inflammation determines LSCD with corneal neovascularization, while the extreme dryness causes the onset of persistent epithelial defect that often progresses to corneal ulceration, melting and perforation. At this stage, topical anti-inflammatory therapy alone cannot restore ocular surface condition, while conjunctival-limbal graft is able to address both LSCD and extreme dryness, without the need for systemic immunosuppressants thanks to the induced-chimerism.

★ REFERENCES ★

1. Hessen M, Akpek EK. Ocular graft-versus-host disease. *Curr Opin Allergy Clin Immunol*. 2012;12:540-547.
2. Tabbara KF, Al-Ghamdi A, Al-Mohareb F, Awas M, Chaudhri N, Al-Sharif F et al. Ocular findings after allogeneic hematopoietic stem cell transplantation. *Ophthalmology*. 2009;116: 1624-1629.
3. Busin M, Giannaccare G, Sapigni L, et al. Conjunctival and limbal transplantation from the same living-related bone marrow donor to patients with severe ocular graft-vs-host disease. *JAMA Ophthalmol*. 2017;135:1123-1125.
4. Starzl TE, Demetris AJ. Transplantation tolerance, microchimerism, and the two-way paradigm. *Theor Med Bioeth*. 1998;19:441-455.
5. Oura T, Cosimi AB, Kawai T. Chimerism-based tolerance in organ transplantation: preclinical and clinical studies. *Clin Exp Immunol*. 2017;189:190-196.
6. Kawai T, Cosimi AB, Spitzer TR, et al. HLA-mismatched renal transplantation without maintenance immunosuppression. *N Engl J Med*. 2008;358:353-361.
7. Kwitko S, Marinho D, Barcaro S, et al. Allograft conjunctival transplantation for bilateral ocular surface disorders. *Ophthalmology*. 1995;102:1020-1025.
8. Biber JM, Skeens HM, Neff KD, et al. The Cincinnati procedure: technique and outcomes of combined living-related conjunctival and limbal allograft and keratolimbal allograft in severe ocular surface failure. *Cornea*. 2011;30:765-771.



Dr. Rhizlane ABDI
Hospital Mohammed VI, Oujda – MOROCCO

.....

THE EFFECT OF SMOKING ON THE CORNEAL SURFACE

.....

★INTRODUCTION★

Smoking is currently considered a serious public health problem in the world. Cigarette smoke contains more than 4,000 compounds, which are toxic during acute or chronic exposure and possibly toxic to ocular tissues affecting the eye by an ischemic or oxidative mechanism. Smoking also affects the eyes, toxins associated with smoking decrease blood flow or help to form clots in the ocular capillaries, Free radicals produced by smoking affect the normal function of cells and have been reported to cause ocular damage^[1].

Ophthalmologic disorders associated with smoking include cataract, age-related macular degeneration, retinal ischemia, anterior optic ischemic neuropathy,. The conjunctival mucosa is very sensitive to chemicals, fumes and irritations. the gases that come from tobacco smoke, causing conjunctival redness, excessive tearing and discomfort due to stimulation of nerve endings without conjunctivitis. Smoking cigarettes also increases the risk of dry eye syndrome and exacerbates existing conditions^[2]. Thus, the purpose of this study was to investigate the effects of chronic smoking on the ocular surface and tear characteristics in smokers and non-smokers.

★ CASE PRESENTATION ★

MATERIAL AND METHOD:

This is a prospective study conducted in CHU MOHAMMED VI OUJDA MOROCCO on a period of 8 months from January 2018 to August 2018 .

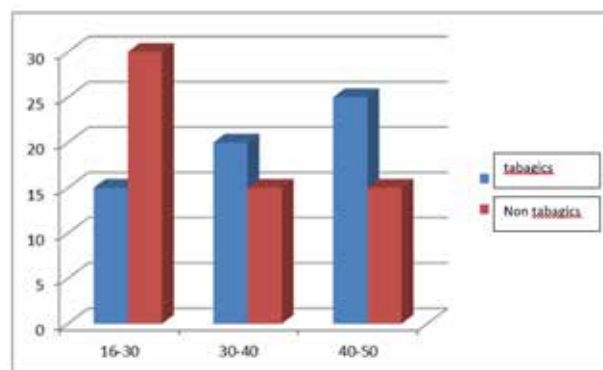
A total of 60 (120 eyes) smokers and 60 (120) non-smokers, matched by age and sex were included in this study. The ocular surface was evaluated by the fluoesceine test with tear film rupture time measurement, corneal sensitivity, and completing the Schirmer II test. The data were analyzed using statistical software for the social sciences (SPSS). A p-value less than 0.05 was considered statistically significant. The data was collected using exploitation sheet and a questionnaire that included details on smoking, such as the duration and number of cigarettes per day, and participants' eye complaints as well as their antecedents. Patients with any of the following conditions were excluded from the study: any systemic or ophthalmological disease (dysfonction of meibomian glands, dryness, ocular allergy)wearing contact lenses, history of use of any medication or refractive errors.

RESULT :

At the end of the study, 120 patients were included in our study: 60 smokers and 60 non-smokers.

THE AGE:

The age of patients in the smoking groups ranged from 20 to 50 years with an average age of 35. While in the non-smoking group the age ranged from 16 to 50 years with an average age of 41 years The figure below illustrates the breakdown by age group:



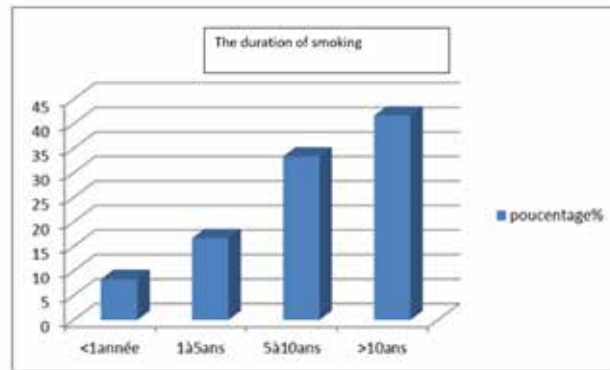
SEX:

In our study, all of our smoking group patients were men while in non-smoking groups 75% of patients were men and 25% were women.

THE EFFECT OF SMOKING ON THE CORNEAL SURFACE

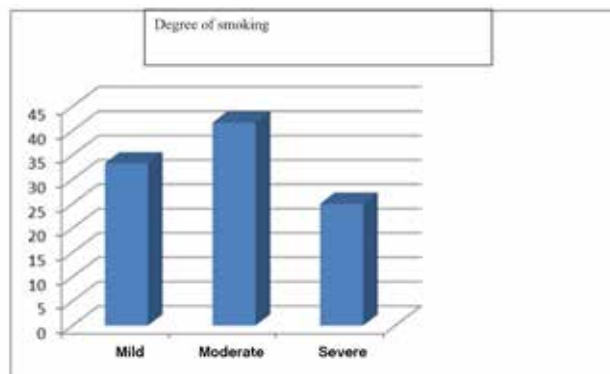
THE DURATION OF SMOKING :

The duration of smoking was <1 year in 8.33% of smokers ,between 1 year and 5 years in 16.66% of patients, between 5 and 10 years in 20 patients or 33.33%, more than 10 years in 25 patients or 41.66% of patients



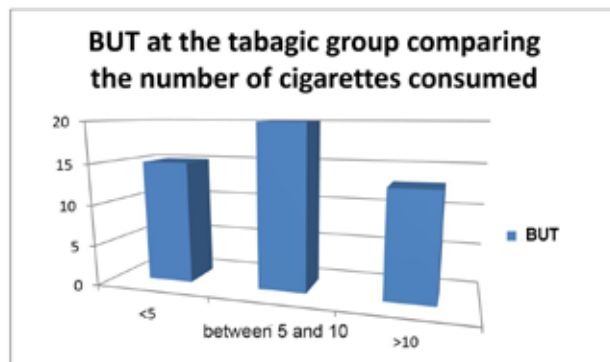
DEGREE OF SMOKING:

32% of patients were light smokers 40% were moderate smokers and 28% were severe smokers.



BREAK UP TIME :

In the smoking group, 80% of patients had an abnormal BUT while 100% of the non-smoked groups had a normal BUT.



FLUOESCEINE TEST:

20% of smoker groups had superficial punctate keratitis.

SCHIRMER TEST:

There was no clinically significant difference between smoking and non-smoking groups with an average of 11 mm / 5s for smokers and 13mm / 5 minutes for non-smokers

★ DISCUSSION ★

Dry eye is one of the most common ophthalmic diseases found in older individuals, and it may be exacerbated by several environmental factors.

Cigarette smoking has been reported to have a harmful effect on tear film stability and ocular surface^[3].

Cigarette smoking has been reported in a multitude of clinical conditions that cause a dysfunctional tear film resulting in dry eye.^[3] In this study, we have shown that smoking has statistically significant detrimental effects on the precorneal tear film and ocular surface.

Smoking cigarette can directly cause excessive tearing and the unstable tear film may trigger reflex tearing. Altinörs et al. tears film lipid layer by lipid peroxidation process and causes dry eye symptoms^[4].

There are many theories about the mechanisms by which smoking causes the breakdown of the precorneal tear film. Of those, the effect of lipid peroxidation is the most likely cause of tear film breakdown. Altinörs and al^[4] assessed the lipid layer of the tear film in smokers and reported damage in the lipid layer which prevents the spreading of tear film corneal surface, rendering it unwettable^[5].

Cigarette smokers also have higher levels of lipid peroxidation than non-smokers^[6]. The chemical composition of cigarette smoke is complex, with many free radical species, aldehydes, peroxides, epoxides, nitrogen oxides, peroxy radicals, and other pro-oxidants being present^[6]. There is growing evidence that these oxidant species may contribute to the disease process associated with smoking. Smoking can also cause ocular surface epithelial damage because the smoke comes into direct contact with the ocular surface. This could be caused by increased inflammation due to the toxic irritants present in cigarette smoke, which results in the absence of growth factors required for epithelial differentiation.

THE EFFECT OF SMOKING ON THE CORNEAL SURFACE

The presence of toxins and irritants in smoke causes a conjunctival reaction that leads to eye redness.

Cigarette smoking also causes a change in the tear protein patterns of smokers compared with non smokers.

By performing electrophoretic analysis of tear proteins, Grus et al^[7] observed that changes in tear proteins were greater and more severe in smokers than in controls. They noted significantly more protein peaks in severe smokers than in non smokers.

They correlated the changes with the increase in dry eye related subjective symptoms in smokers.

★ CONCLUSION ★

In conclusion, smoking cigarettes undermined the tear film and ocular surface by decreasing both the quantity and quality of tear secretion, reducing corneal sensitivity and inducing squamous metaplasia. It is therefore recommended that patients with dry eye syndrome and ocular surface disorders avoid smoking, even if they do not have severe dry eye presentation.

★ REFERENCES ★

1. Seddon J, Fong D. Introducing "Public health and the eye." *Surv Ophthalmol* 1994;38:325.
2. Satici A, Bitiren M, Ozardali I, et al. The effects of chronic smoking on the ocular surface and tear characteristics: a clinical, histological and biochemical study. *Acta Ophthalmol Scand* 2003;81:583-7.
3. Sat+al, histological and biochemical study. *Acta Ophthalmol Scand* 2003; 81:583-587
4. Altinors DD, Akca S, Akova YA, et al. Smoking associated with damage to the lipid layer
5. Altinors DD, Akca S, Akova YA, Bilezicki B, Goto E, Dogru M, Tsubota K. Smoking associated with damage to the lipid layer of the ocular surface. *Am J Ophthalmol.* 2006;141:1016
6. Pryor WA. Cigarette smoke and the role of free radicals in chemical carcinogenicity. *Environ Health Perspect.* 1997;105:875-82.
7. Grus FH, Sabuncuo P, Augustin A, Pfeiffer N. Effect of smoking on tear proteins. *Graefes Arch Clin Exp Ophthalmol.* 2002; 240:889-92.



Dr. Rosa ALVARADO
Universidad Peruana Cayetano Heredia – PERU

.....

SUCCESSFUL MANAGEMENT OF SEVERE UNILATERAL INFLAMMATORY CORNEAL MELTING AS AN INITIAL PRESENTATION OF RHEUMATOID ARTHRITIS

.....

★ INTRODUCTION ★

Corneal perforations can be derived from a variety of disorders and may lead to devastating ocular sequelae. They can result from infectious, traumatic or inflammatory conditions and they presented in the context of systemic autoimmune diseases as rheumatoid arthritis, systemic lupus erythematosus or with granulomatosis polyangiitis among others. Corneal perforations require immediate attention and it is essential to identify and treat the underlying cause and referral to a specialist unit¹.

Rheumatoid arthritis (RA) is an autoimmune disease that classically presents with symmetrical inflammatory polyarthritis, joint stiffness, fever, weight loss, and malaise. There may also be periarticular bony erosions, joint deformities, and nodules, with classic sparing of the distal interphalangeal joints. Females are more commonly affected, and there is an association with human leukocyte antigen (HLA)-DR4 and increased cytokine Th17. The

extra-articular complications of RA include ophthalmological manifestations, which can, in some cases, be the first signs of the disease. The pathogenesis of RA-associated corneal ulcer is attributed to a local imbalance between levels of a specific collagenase (MMP-1) and its tissue inhibitor (TIMP-1), causing the rapid keratolysis. Furthermore, it has been suggested that corneal ulceration heralds the presence of active vasculitis locally and systemically requiring aggressive immunosuppression. Ocular inflammatory diseases can be sight-threatening and warrant prompt management and proper collaboration between ophthalmologists and rheumatologists or internal medicine experts to provide the best care for patients^{2,3}.

We report a case of a rare extra-articular presentation of RA only with a severe unilateral inflammatory corneal melting in the absence of clinically active flares of joint inflammation.

★ CASE PRESENTATION ★

64-year-old woman evaluated at the emergency room of our hospital describing burning sensation and pain in the right eye (RE) of ten days. The best corrected visual acuity (BCVA) was hand motion. At the slit lamp evaluation, we objectify a moderate ciliary hyperemia with an inferior corneal perforation of 5mm wide by 3mm high, uveal prolapse, flat anterior chamber with mild inflammatory reaction and nuclear sclerosis were observed (Figure 1).

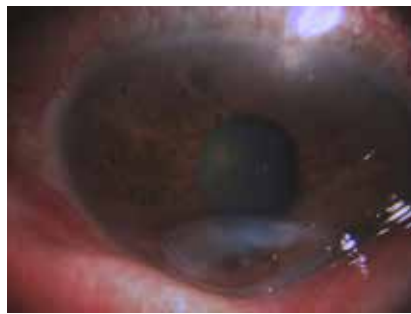

Figure 1: Inferior corneal ulcer with perforation and uveal prolapse. No signs of infection were observed.

Contralateral eye examination was normal. In the emergency room, the eye was occluded with topical antibiotic. No history of trauma, ophthalmic diseases or previous eye surgeries. Among the pathological systematic history included a diagnosis of diabetes, arterial hypertension, and chronic obstructive pulmonary disease. No rheumatologic symptoms or signs were reported. We thought in a neurotrophic keratopathy due to the history of uncontrolled glycemia. The possibility of treating corneal perforation with

SUCCESSFUL MANAGEMENT OF SEVERE UNILATERAL INFLAMMATORY CORNEAL MELTING AS AN INITIAL PRESENTATION OF RHEUMATOID ARTHRITIS

cyanoacrylate or amniotic membrane arises, but given the defect size and corneal tissue availability, we decided surgical treatment with a tectonic patch graft in order to restore the integrity of the eye as soon as possible. In preoperative biochemistry no alteration was found, so we performed the surgery without any complications (Figures 2, 3).

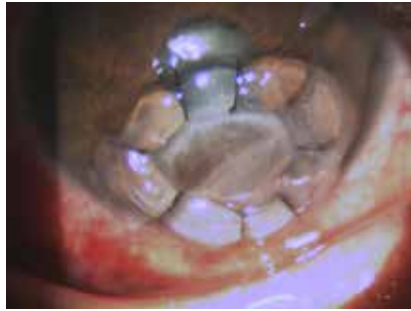


Figure 2: 1-day postop, showing a patch graft in situ.

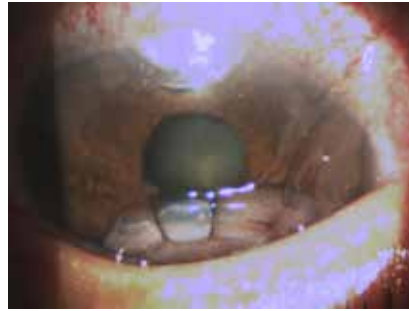

Figure 3: 1-day postop, showing the presence of an air bubble in a formed anterior chamber.

Medical treatment included platelet-rich plasma, one drop every 4 hours, and topical antibiomatic coverage as well as ciprofloxacin orally. The patient came back after eleven days with foreign body sensation, and no graft remaining was found (Figure 4). An evaluation by a rheumatologist was made, but any diagnosis was found, while corneal tissue melting continued (Figure 5).

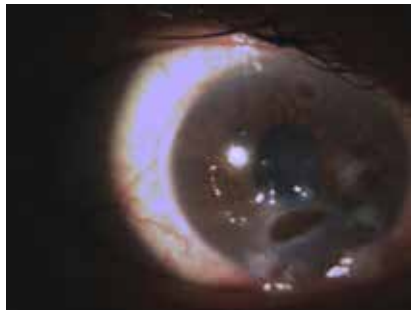

Figure 4: 11-day postop with severe patch graft melting.

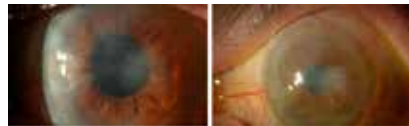

Figure 5: 15-day postop only sutures were kept in situ.

Oral doxycycline 100mg twice a day was added and a second surgical intervention was performed using a sclerocorneal patch graft and a conjunctival flap (Figure 6)



Figure 6: second patch with a conjunctival flap.

Three days after the second surgery, the patient developed melting of the conjunctival flap (Figure 7). The patient was referred to an internal medicine specialist for a second evaluation.

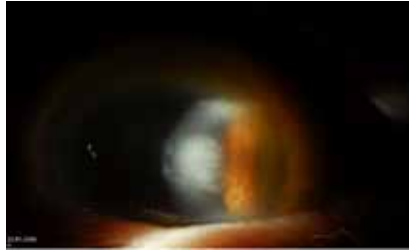

Figure 7: 3-days postop with conjunctival flap melting.

She denied systemic symptoms, arthralgias or arthritis, but the profile autoimmune antibodies were positive for Rheumatoid Factor (RF) four-fold higher than normal values, low positive for Anti-Ro/SSA and negative for Anti-La/SSB antibodies, Antinuclear Antibodies (ANA), Cytoplasmic Antineutrophil Cytoplasmic Antibodies (c-ANCA), Perinuclear Anti-neutrophil Cytoplasmic Antibodies (p-ANCA). In biochemistry stands elevated Erythrocyte Sedimentation Rate (ESR) and C-Reactive Protein (CRP). We decided added topical cyclosporine a, oral azathioprine (500mg per day) and intramuscular dexamethasone.

One week after, new perforations were observed in conjunctival suture places (Figure 8.1, 8.2)

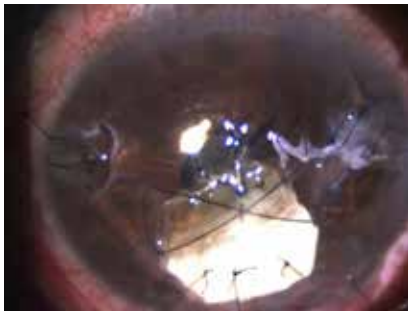

Figure 8-1: No conjunctival flap remained.

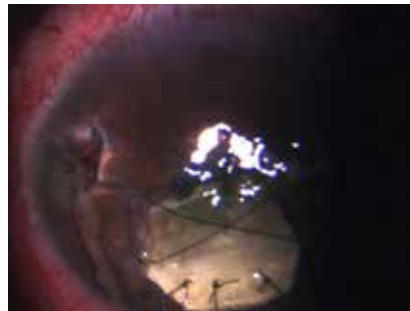

Figure 8-2: New corneal perforation with uveal prolapse were found after remove sutures.

A therapeutic contact lens (TCL) was placed and medical treatment was continued. Progressively decreases both epithelial defect and the size of the perforation. On the fourth day of treatment, in the absence of TCL, not Seidel was observed. One month later, peripheral corneal neovascularization began to invade suture places and graft melting continued in a slow way (Figure 9), while the corneal defect began a progressive closure during the first three months after immunotherapy was added (Figure 10).

SUCCESSFUL MANAGEMENT OF SEVERE
UNILATERAL INFLAMMATORY CORNEAL MELTING
AS AN INITIAL PRESENTATION
OF RHEUMATOID ARTHRITIS

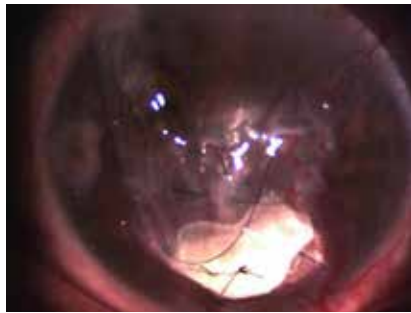


Figure 9: Corneal neovascularization and patch graft melting.

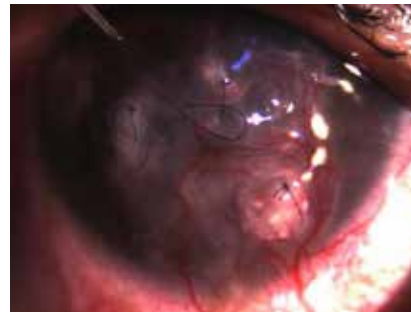


Figure 10: Progressive corneal defect closure.

At this time a foreign body sensation and blurry vision in the contralateral eye were present, we objectify a punctate keratitis and corneal filaments (Figure 11). She referred arthralgias of recent onset, warm, tender and swollen joints, and also joint stiffness that was usually worse in the mornings and after inactivity. An intense treatment with topical lubricants and loteprednol 0.5% was initiated in the left eye.

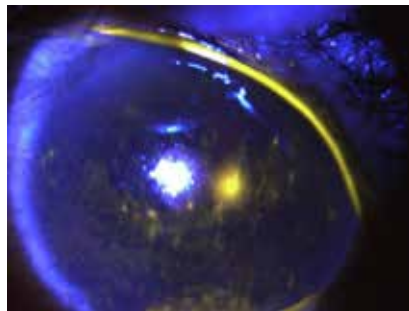


Figure 11: Fluorescein staining in contralateral eye.

At present, seven months later, BCVA is 20/80 with nuclear cataract, complete epithelization of the lesion with secondary corneal scarring (Figure 12). Continued monitoring for RA and treatment is maintained with artificial tears and autologous serum awaiting penetrating keratoplasty and cataract surgery.

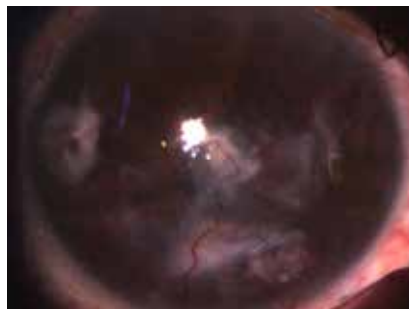


Figure 12: Last follow-up with complete epithelization.

★ DISCUSSION ★

The normal tear film has antimicrobial properties and contains immunomodulatory factors such as collagenase inhibitors (e.g., alpha-2 macroglobulin). Patients with an inflammatory ocular disease are deficient in these protective mechanisms and have increased proteolytic enzymes such as plasminogen activator in the tear film. Consequentially, can lead to superficial punctate keratitis, filamentary keratitis, corneal ulcer, and ultimately, corneal melt. Inflammatory corneal melting leading to perforation may be due to infectious and non-infectious destructive conditions².

Rheumatoid arthritis (RA) principally affects the joints but is sometimes complicated by extra-articular conditions, which can be life-threatening. Episcleritis, scleritis and peripheral ulcerative keratitis (PUK) can also occur during the course of RA, or more rarely be the initial signs of the disease. Development of PUK associated with systemic diseases may represent worsening of a potentially life-threatening disease. These ocular conditions are not specific to RA, but RA is their leading cause, ahead of systemic vasculitis. Ocular inflammatory diseases can be sight-threatening and warrant prompt management and close collaboration between the ophthalmologist and rheumatologist or internal medicine expert is required for the diagnosis and therapeutic management of these patients^{3,4}.

PUK is an inflammatory condition of the peripheral cornea in which thinning and ulceration develops in a juxtalimbal characteristic location. Corneal perforation represents its most severe complication. This condition is bilateral in 40% of cases and its incidence has been estimated at three cases per 1 million inhabitants in one study from England. RA is observed in 34–42% of PUK cases. The prevalence of PUK in patients with RA is less than 3% but is now becoming uncommon possibly because of improved treatment of RA³.

As in scleritis, rheumatoid PUK frequently occurs in patients with destructive, often nodular, RA of long duration, often after 20 years of disease progression, and in patients with high titers of RF and anti-CCP antibodies. In a historic retrospective series, Foster et al. reported a mortality of patients with RA complicated with PUK and/or necrotizing scleritis of about 50% at 10 years in the absence of immunosuppressive treatment; the mortality was mostly due to the subsequent occurrence of rheumatoid vasculitis. The occurrence of PUK, therefore, marks a turning point in the course of RA, requiring urgent, multidisciplinary management^{1,3}.

In our patient, the onset of corneal perforation was acute without a trauma antecedent, autoimmune disease, or previous eye diseases, nor contralateral eye disorders to suspect a clear etiology. When corneal dehiscence occurred again, we decided to start intramuscular dexamethasone and oral azathioprine after the autoimmune antibodies profile were obtained. Despite the surgical treatment, a delay in the proper management of the inflammatory underlying disease could result in a worse visual prognosis and life-threatening.

In these cases, the first-line treatment with systemic corticosteroids is indicated for acute phases, in our patient we were aware of the arterial tension and glucose levels during corticosteroids treatment because of the presence of underlying diseases. Immunosuppressive therapy is also required, we used oral azathioprine because of concerns over its safety it is generally used only in severe RA⁵⁻⁷.

SUCCESSFUL MANAGEMENT OF SEVERE UNILATERAL INFLAMMATORY CORNEAL MELTING AS AN INITIAL PRESENTATION OF RHEUMATOID ARTHRITIS

Graft survival is highly influenced by adequate control of immune-mediated corneal melting and prevention of superimposed corneal surface infection. A retrospective review on rheumatoid arthritis-associated corneal perforations by Bernauer et al. reported that 80% of early (within the first 6 months) graft failures were attributed to recurrent corneal melting following penetrating keratoplasty. This suggests the need for an aggressive immunosuppressive regimen in the postoperative state⁶.

Immunosuppressive therapy of RA with the thiopurine azathioprine has been reported since 1965 but may take 8-12 weeks to see an effect. Side effects include nausea and alopecia. Blood tests to monitor blood counts and liver function tests are necessary for patients on azathioprine. Our patient showed normal values in blood cell counts and liver functions test, and the single dose of 500 mg was well tolerated⁸.

In our case, application of patch corneal graft and intensive topical treatment including lubricants, platelet-rich plasma, autologous serum eye drops, and anti-inflammatory treatment were insufficient to prevent ongoing corneal melting. The second surgery including a conjunctival flap did not stabilize the ocular surface until immunosuppressive therapy was initiated. Our main goal was to first stabilize the ocular integrity, enabling further surgical procedures to restore visual acuity in the future when eventually RA is less active.

The known association of this disease with RA should make us think of this possibility and should perform appropriate tests. Together with aggressive medical therapy and close follow-up may achieve good visual outcomes.

★ CONCLUSION ★

This case highlights the potential for Rheumatoid Arthritis to present with a serious ocular complication despite the lack of a priori systemic symptoms and signs, as well as the importance of immunosuppressive therapy in the treatment of this complication.

★ REFERENCES ★

1. Loza-Garcia D, Serna-Ojeda JC, Pedro-Aguilar L, Jimenez-Corona A, Olivo-Payne A, Graue-Hernandez E. Non-traumatic corneal perforations: etiology, treatment and outcomes. *Br J Ophthalmol* 2017;101:634–639.
2. Artifoni M, Rothschild PR, Brézin A, Guillemin L, Puéchal X. Ocular inflammatory diseases. *Rev. Rheumatol* 2014; 10: 108–116.
3. Yagci A. Update on peripheral ulcerative keratitis. *Clinical Ophthalmology* 2012;6 747–754.
4. Suresh E. Diagnosis of early rheumatoid arthritis: what the non-specialist needs to know. *J R Soc Med* 2004;97:421–424.
5. Singh G, Salvador V, Bagchi A, Tushabe R, Abrudescu A. Rheumatoid Arthritis-Associated Corneal Ulceration with Superimposed Infection by Methicillin-Resistant *Staphylococcus aureus*: A Complicated Type of Corneal Melt. *Am J Case Rep*, 2014; 15: 523-525.
6. Medsinghe A, Gajdosova E, Moore W, Nischa K. Management of inflammatory corneal melt leading to central perforation in children: a retrospective study and review of literature. *Eye* (2016) 30, 593–601.
7. Vivino FB, Minerva P, Huang CH, Orlin SE. Corneal melt as the initial presentation of primary Sjögren's syndrome. *J Rheumatol*. 2001 Feb;28(2):379-82.
8. Suarez-Almazor ME, Spooner C, Belseck E. Azathioprine for treating rheumatoid arthritis. *Cochrane Database of Systematic Reviews* 2000, Issue 4. Art. No.: CD001461.





Dr. Anne-Laurence BEST
Bicêtre Hospital, Le Kremlin-Bicêtre – FRANCE

.....

ACICLOVIR RESISTANT HERPETIC KERATITIS: AN EMERGING PROBLEM

.....

★INTRODUCTION★

The most frequent ocular involvement due to herpes simplex virus 1 (HSV-1) is keratitis with an incidence ranging from 18.2 to 25.8/100 000 inhabitants per year⁽¹⁾. Because of its recurring nature after the first episode, keratitis can lead to visual loss, due to corneal opacification and neovascularization. Therefore, herpes simplex keratitis (HSK) is among the leading causes of infectious blindness in industrialized countries⁽²⁾. The efficiency of antiviral prophylaxis treatment with acyclovir (ACV) to avoid recurrences has been proven as early as 1998 by the Herpetic Eye Disease Study (HEDS^(3,4)) and allowed ACV to be recommended in prevention of HSK recurrence. Thereafter, a prodrug of ACV, valacyclovir (VACV) was developed for its greater oral bioavailability. Both ACV and VACV may be prescribed during at least 12 months in case of recurrent episodes of HSK^(5,7). However, possible recurrences of HSK despite VACV or ACV treatment may drive ophthalmologists to extend the duration of treatments and therefore, many patients receive antiviral prophylaxis for several years. These practices may have contributed to the emergence of aciclovir resistant (ACVR) HSK⁽⁸⁾. Indeed, it has been shown that long duration of prophylaxis is one of the major risk factor for ACVR resistant strains in corneal samples of patients with HSK⁽⁹⁾. If first cases of ACVR HSK were reported in immunocompromised patients⁽¹⁰⁾, ACVR HSK has been more recently reported in immunocompetent patients^(9,11) and seems to become an emerging problem. The aim of this study was to report three cases of ACVR HSK, to discuss the clinical context in which this diagnosis may be suspected and the

available techniques to prove it, and finally explore the possible therapeutic strategies to address this challenging condition.

★ CASE PRESENTATION ★

We here report a series of three patients with ACVR HSK, seen in our department (a reference center for herpes and zoster keratitis) from January 2010 to December 2016. Systemic medical history, including immune status of the patients and ocular herpes history (duration of disease, prophylaxis and number of recurrences) were collected for all patients. Comprehensive ophthalmological examination and virological analysis are also reported.

CASE 1

A 53 years old immunocompetent woman was referred in February 2010 for recurrent left HSK despite well conducted antiviral prophylaxis. The patient had no significant medical history. She had experienced her first episode of HSK in the childhood (at the approximate age of 10) and since had more than 20 clinical recurrences of ocular herpes disease, including epithelial and stromal HSK and anterior uveitis. At the time of presentation, the patient received a prophylactic treatment for recurrent HSK with oral VACV (500mg/day) and claimed to be assiduously compliant. The patient had been continuously taking this prophylaxis for the last 18 months, although she had previously received several courses of antiviral prophylaxis. At this first evaluation, she complained of decreased vision with painful ocular redness. Her best-corrected visual acuity (BCVA) was 20/50 in the left eye and 20/20 in the right eye. Intraocular pressure (IOP) was normal. Slit lamp examination revealed typical dendritic keratitis in the left eye (Figure 1, A) associated with several stromal opacities and corneal anaesthesia. There was no anterior chamber reaction. Tear sample was collected from the lower conjunctival fornix using Schirmer strips and HSV-1 DNA was detected by real-time PCR using the Artus® HSV-1/2 RG kit (Qiagen). The patient was treated by debridement of the epithelial lesion associated with topical lubricant and oral valaciclovir 500 t.i.d. At control, five days later, the dendritic lesion persisted. Because this recurrence occurred despite a well conducted prophylaxis, and resisted to conventional treatments, a genotypic HSV-1 resistance assay was asked to the virology department. While awaiting the results, the VACV dosage was increased to 3g daily and topical ganciclovir 0,15%, 5 times a day, was added. At re-evaluation five days later, the dendritic lesion had healed. The genotypic analysis of HSV-1 revealed a substitution mutation in the viral thymidine kinase gene (R222H) reported to be linked to a poor ACV phosphorylation activity⁽¹²⁾. After the diagnosis of ACVR HSK, the prophylactic treatment was switched to famciclovir 500mg t.i.d, another TK dependent nucleoside analogue, marketed for HSV-2 and varicella zoster virus, with a slightly different conformation compared to aciclovir. Despite this switch, the patient had 8 recurrences during the 7.5 years follow-up, including epithelial keratitis, keratouveitis, endothelitis, and necrotizing stromal keratitis. At the end of follow-up, BCVA of the left eye during quiescent phase was 20/200. The visual loss was mainly caused by corneal opacities and dense cataract (Figure 1, B). Endothelial count was reduced to 850 cells/mm² and cataract surgery +/- associated with lamellar posterior keratoplasty was declined by the patient.

ACICLOVIR RESISTANT HERPETIC KERATITIS: AN EMERGING PROBLEM

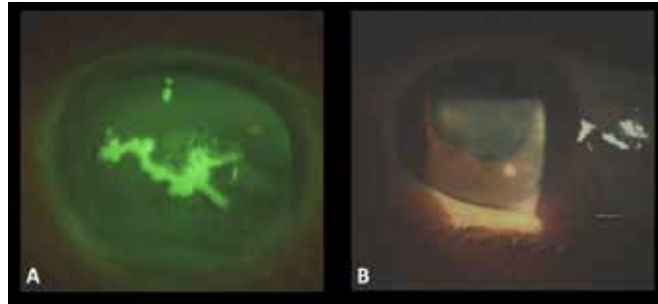


Figure 1: (A) dendritic lesion associated with stromal edema without endothelium affect in the left eye. (B) recent picture, with sequellae of multiple recurrences (keratitis and keratouveitis), including stromal opacities and posterior synechiae.

CASE 2

A 73-year-old immunocompetent woman with history of recurrent right eye HSK, presented with painful red eye associated with blurred vision. The patient had her first episode of HSK at the age of 56 and had 10 documented recurrences. Her medical history was positive for systemic hypertension. She was receiving antiviral prophylaxis with VACV 500mg t.i.d, with good patient-reported compliance. Ophthalmological examination revealed BCVA of 20/100 in the right eye and 20/20 in the left eye. The conjunctiva of the right eye was injected with markedly decreased corneal sensation. Slit lamp exam with fluorescein staining disclosed a geographic ulcer associated with stromal opacities and circumferential superficial and deep corneal neovascularization (Figure 2 A, B). Fundus examination was unremarkable in both eyes. Tear samples and corneal swab (performed both for virological diagnosis and debridement) were positive for HSV-1 genome and genotypic resistance assay was performed to investigate this HSK occurring despite high dosage antiviral prophylaxis. VACV dosage was increased to 3 g daily, associated with topical ganciclovir 0,15%, 5 times a day. Resistance assay revealed a stop codon in the viral thymidine kinase gene (UL23) causing a complete deficiency of this enzyme (Table 1). The lesion healed in seven days, and the prophylaxis was switched to oral famciclovir (500mg t.i.d). Further evolution was marked by 3 recurrences of the disease during the 10 months follow-up. At last visit, right eye BCVA was 20/200 with markedly increased central corneal opacities and more diffuse corneal neovascularization (Figure 2 C, D).

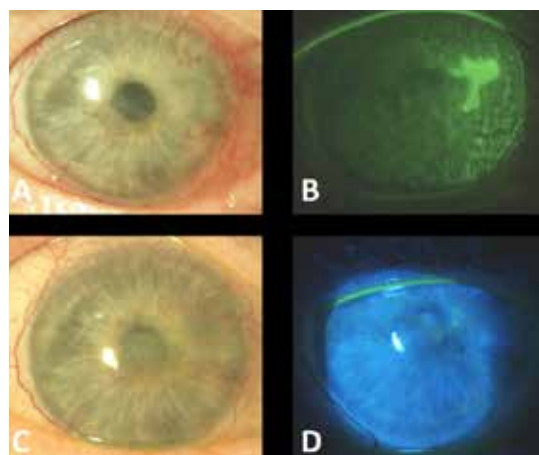


Figure 2: (A) geographic ulcer with circumferential neovascularization. (B) fluorescein staining. (C) and (D): slit lamp examination findings at last visit: increased central corneal opacity and neovascularization associated with visual loss.

CASE 3

A 64-year-old immunocompetent man, with history of recurrent left eye HSK, presented with painful red eye associated with blurred vision. He had no significant past medical history except statin-treated hypercholesterolemia. The patient had his first episode of HSK at the age of 34 and had approximately 15 recurrences. He was receiving antiviral prophylaxis with VACV 500 mg t.i.d with good self-reported compliance. Ophthalmological examination revealed BCVA of 20/20 in both eyes. The conjunctiva of the left eye was injected with markedly decreased corneal sensation. Slit lamp exam with fluorescein staining showed a vast dendritic epithelial lesion in the peripheral nasal cornea (Figure 3 A) with no anterior chamber reaction and normal IOP. Tear sample and corneal swab was performed for virological diagnosis and debridement. The samplings were positive for HSV-1 genome and genotypic resistance assay was performed to investigate this HSK occurring despite antiviral prophylaxis. The treatment associated debridement of the lesion with topical ganciclovir 0.15% 5 times a day, topical lubricant and oral famciclovir 500mg t.i.d. The genotypic analysis of HSV-1 revealed a substitution mutation in the viral thymidine kinase gene (M128L) associated with poor ACV phosphorylation activity (Table 1)⁽¹³⁾. One week later, the dendritic lesion had healed (Figure 3 B). After the diagnosis of HK resistance to ACV, the prophylactic treatment was replaced by famciclovir 500mg b.i.d, which did not succeed in preventing further recurrences. Evolution was marked by 3 recurrences during the 16 months follow-up period. Fortunately, the left eye BCVA at the last visit, was still 20/20.

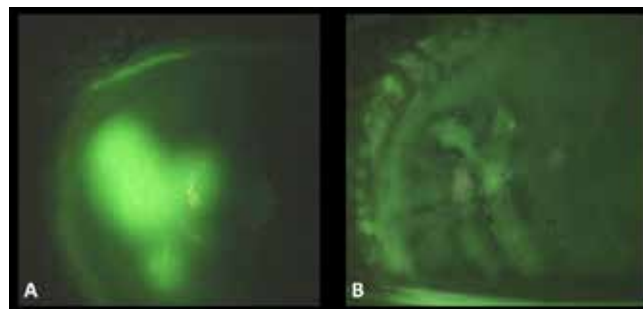


Figure 3: (A) fluorescein staining of a vast dendritic epithelial lesion in the peripheral nasal cornea. (B) One week later, the dendritic lesion had healed.

Case N°	CT	HSV-1 UL 23 (thymidine kinase) genetic analysis	HSV-1 UL 30 (DNA polymerase) genetic analysis
1	35.9	ACV resistance: R222H Natural polymorphisms: C6G N23S K36E A192V G251C A265T V267L P268T D286E N376H	Natural polymorphisms: S33G A330R V905M P1124H T1208A
2	37.09	ACV resistance: D228Stop Natural polymorphisms: N23S K36E R89Q	No amplification
3	30.05	ACV resistance: M128L Natural polymorphisms: N23S K36E R89Q G240E A265T N376	Natural polymorphisms: S33G A330R V905M A12003T T1208A

Table 1: Virological findings of patients (CT: cycle threshold of PCR, HSV-1: Herpes simplex virus 1, ACV: Acyclovir).

★ DISCUSSION ★

In this series of 3 ACVR HSK, resistance assay was motivated in 2 patients by HSK recurrence despite a well conducted prophylactic treatment and in one case by resistance to curative treatment. All 3 patients were immunocompetent.

Initially reported in immunocompromised patients⁽¹⁰⁾, ACVR HSK were subsequently reported in immunocompetent patients^(14,15). Besides, the proportion of ACVR strains in corneal isolates has increased in recent years^(9,11). We recently reported that 83% of HSV-1 PCR-positive ocular samples (100% of the samples that could be analyzed) from patients with relapsing HSK despite antiviral prophylaxis contained viruses with genotypic resistance to ACV⁽¹⁶⁾.

The gold standard for the diagnosis of HSV-1 resistance is based on plaque assay, performed using cell culture seeded with infectious viral particles exposed to serial dilution of antiviral drugs (i.e. antivirogram). However, this technique requires viral strain isolation and culture, which may be difficult to achieve in the setting of ocular samples⁽¹⁵⁾. Genotypic HSV-1 resistance assay is based on the amplification and sequencing of viral thymidine kinase gene (UL23) and DNA polymerase (UL30) genes. This assay is performed using viral DNA, which is more easily isolated from ocular samples (corneal swabs, tears or aqueous) than infectious viral particles. UL23 and UL30 sequences are screened for mutations conferring resistance (comparison with available published literature for genotype-phenotype correlations). Genotypic resistance assay is now accepted as a reliable method for detecting clinically relevant HSV-1 drug resistance⁽¹⁷⁾. In our 3 patients, resistance to ACV was caused by mutations in the viral TK gene (2 substitutions and one stop codon). This viral enzyme is responsible for the first phosphorylation of ACV, which is followed by 2 further phosphorylations by cellular kinases in HSV-1 infected cells. Once ACV is transformed into ACV triphosphate, it is incorporated by viral DNA polymerase and cause viral DNA synthesis termination. Resistance to ACV is most commonly associated with alterations of the viral thymidine kinase activity (up to 95% of cases) and more rarely with alterations of the viral DNA polymerase (5% of cases)⁽¹⁸⁾. Only one case of ACVR HSK due to DNA polymerase mutation has been reported in the literature⁽¹⁵⁾.

Management of patients who present recurrences associated with viral replication despite antiviral prophylaxis is challenging, as these recurrences may be caused by viral resistance, poor drug absorption (up to 14% of patients), or poor compliance to antiviral prophylaxis⁽¹⁶⁾. In case of antiviral resistance, knowing the underlying resistance mechanism can be very useful to adapt the treatment. In case of TK-deficient virus, it may be appropriate to switch to an antiviral drugs whose action is independent of TK, such as topical trifluridine in case of epithelial keratitis or intravenous foscavir for patients with associated severe stromal / endothelial keratitis or keratouveitis⁽¹⁹⁾. These drugs may be good alternative for curative treatment. Topical ganciclovir may also be

considered as an option for epithelial keratitis. Despite its viral TK-dependence to phosphorylation, GCV allows higher intracellular penetration and may overcome resistance through very high local concentrations⁽²⁰⁾. Nevertheless, there are currently no available options for antiviral prophylaxis in these patients. Similarly, there are no antiviral drugs available for ACVR HSV-1 keratitis caused by DNA polymerase mutant strains. New anti-HSV-1 molecules, such as helicase primase inhibitors, could be beneficial but still need to be tested in the context of ocular disease⁽²¹⁾. In parallel, other strategies involving heparan sulfate mimetics could be considered in the management of these patients. Indeed, envelop HSV-1 glycoproteins use extracellular heparan sulfate to bind and entry epithelial cells. Heparan sulfate biomimetics used in eyedrops for corneal regeneration (poly-carboxymethylglucose sulfate solution), a topical heparan sulfate mimetic labelled for chronic ulcers, could compete for adsorption of viruses into susceptible cells. In a recently published in vitro study, Deback et al. showed that heparan sulfate biomimetics used in eyedrops for corneal regeneration was able to inhibit viral replication by 98.4% of an HSV-1 strain highly resistant to both acyclovir and foscavir. Further studies are warranted to define its potential role as an adjuvant or prophylaxis therapy in ACVR keratitis⁽²²⁾.

★ CONCLUSION ★

To summarize, ACVR HSK may be suspected in patients with recurrences including an epithelial (replicative) component, despite well conducted antiviral prophylaxis and/or clinical resistance to well conducted curative treatment. Genotypic resistance assay provides reliable results and provide information on viral resistance mechanism. Curative management of patients harboring TK deficient virus can be achieved using TK independent drugs, such as trifluridine or foscavir or molecules allowing higher intracellular concentrations, such as topical ganciclovir. There are no currently available options for preventive treatment in these situations. New strategies including virus entry or helicase primase inhibition are needed to address this emerging problem.

★ REFERENCES ★

1. Labetoulle M, Auquier P, Conrad H, Crochard A, Daniloski M, Bouée S, et al. Incidence of herpes simplex virus keratitis in France. *Ophthalmology*. mai 2005;112(5):888-95.
2. Farooq AV, Shukla D. Herpes simplex epithelial and stromal keratitis: an epidemiologic update. *Surv Ophthalmol*. sept 2012;57(5):448-62.
3. Acyclovir for the prevention of recurrent herpes simplex virus eye disease. Herpetic Eye Disease Study Group. *N Engl J Med*. 30 juill 1998;339(5):300-6.
4. Oral acyclovir for herpes simplex virus eye disease: effect on prevention of epithelial keratitis and stromal keratitis. Herpetic Eye Disease Study Group. *Arch Ophthalmol Chic Ill* 1960. août 2000;118(8):1030-6.
5. MacDougall C, Guglielmo BJ. Pharmacokinetics of valaciclovir. *J Antimicrob Chemother*. juin 2004;53(6):899-901.
6. Miserocchi E, Modorati G, Galli L, Rama P. Efficacy of valacyclovir vs acyclovir for the prevention of recurrent herpes simplex virus eye disease: a pilot study. *Am J Ophthalmol*. oct 2007;144(4):547-51.
7. Weller S, Blum MR, Doucette M, Burnette T, Cederberg DM, de Miranda P, et al. Pharmacokinetics of the acyclovir pro-drug valaciclovir after escalating single- and multiple-dose administration to normal volunteers. *Clin Pharmacol Ther*. déc 1993;54(6):595-605.
8. Labetoulle M, Colin J. [Current concepts in the treatment of herpetic keratitis]. *J Fr Ophtalmol*. avr 2012;35(4):292-307.
9. Van Velzen M, van de Vijver DAMC, van Loenen FB, Osterhaus ADME, Remeijer L, Verjans GMGM. Acyclovir prophylaxis predisposes to antiviral-resistant recurrent herpetic keratitis. *J Infect Dis*. 1 nov 2013;208(9):1359-65.
10. Bodaghi B, Mougín C, Michelson S, Agut H, Dighiero P, Offret H, et al. Acyclovir-resistant bilateral keratitis associated with mutations in the HSV-1 thymidine kinase gene. *Exp Eye Res*. oct 2000;71(4):353-9.
11. Duan R, de Vries RD, Osterhaus ADME, Remeijer L, Verjans GMGM. Acyclovir-resistant corneal HSV-1 isolates from patients with herpetic keratitis. *J Infect Dis*. 1 sept 2008;198(5):659-63.
12. Hussin A, Md Nor NS, Ibrahim N. Phenotypic and genotypic characterization of induced acyclovir-resistant clinical isolates of herpes simplex virus type 1. *Antiviral Res*. nov 2013;100(2):306-13.
13. Duan R, de Vries RD, van Dun JM, van Loenen FB, Osterhaus ADME, Remeijer L, et al. Acyclovir susceptibility and genetic characteristics of sequential herpes simplex virus type 1 corneal isolates from patients with recurrent herpetic keratitis. *J Infect Dis*. 1 nov 2009;200(9):1402-14.
14. Burrel S, Boutolleau D, Azar G, Doan S, Deback C, Cochereau I, et al. Phenotypic and genotypic characterization of acyclovir-resistant corneal HSV-1 isolates from immunocompetent patients with recurrent herpetic keratitis. *J Clin Virol Off Publ Pan Am Soc Clin Virol*. sept 2013;58(1):321-4.
15. Gueudry J, Boutolleau D, Gueudin M, Burrel S, Miri A, Bodaghi B, et al. Acyclovir-resistant varicella-zoster virus keratitis in an immunocompetent patient. *J Clin Virol Off Publ Pan Am Soc Clin Virol*. sept 2013;58(1):318-20.
16. Rousseau A, Boutolleau D, Titier K, Bourcier T, Chiquet C, Weber M, et al. Recurrent herpetic keratitis despite antiviral prophylaxis: A virological and pharmacological study. *Antiviral Res*. oct 2017;146:205-12.
17. Piret J, Boivin G. Antiviral resistance in herpes simplex virus and varicella-zoster virus infections: diagnosis and management. *Curr Opin Infect Dis*. 2016;29(6):654-62.
18. Burrel S, Deback C, Agut H, Boutolleau D. Genotypic characterization of UL23 thymidine kinase and UL30 DNA polymerase of clinical isolates of herpes simplex virus: natural polymorphism and mutations associated with resistance to antivirals. *Antimicrob Agents Chemother*. nov 2010;54(11):4833-42.
19. Zhang W, Suzuki T, Shiraishi A, Shimamura I, Inoue Y, Ohashi Y. Dendritic keratitis caused by an acyclovir-resistant herpes simplex virus with frameshift mutation. *Cornea*. janv 2007;26(1):105-6.
20. Colin J, Hoh HB, Easty DL, Herbert CP, Resnikoff S, Rigal D, et al. Ganciclovir ophthalmic gel (Virgan; 0.15%) in the treatment of herpes simplex keratitis. *Cornea*. juill 1997;16(4):393-9.
21. Shiraki K. Antiviral Drugs Against Alphaherpesvirus. *Adv Exp Med Biol*. 2018;1045:103-22.
22. Deback C, Rousseau A, Breckler M, Molet L, Boutolleau D, Burrel S, et al. Antiviral effects of Cacicol[®], an heparan sulfate biomimetic for corneal regeneration therapy, for herpes simplex virus type 1 and varicella zoster virus infection. *Antivir Ther*. 20 juill 2018;



Dr. Oana-Maria BODEA
Emergency Clinical Hospital of Sibiu – ROMANIA

.....

A CHALLENGING GRAFT-VERSUS-HOST DISEASE CASE - A CONSERVATIVE TREATMENT

.....

★INTRODUCTION★

Graft-versus-host disease (GVHD) remains an important, frequent long-term complication of allogeneic hematopoietic cell transplantation – allo-HCT (occurs in 25-70% of patients), performed as a potentially curative treatment for a variety of hematologic malignancies, in which donor lymphocytes recognize host histocompatibility antigens as foreign. GVHD is a condition that is responsible for non-relapse mortality and morbidity in patients undergoing allo-HCT^[2].

The temporal relationship to transplantation is not considered decisive anymore in determining whether there is an acute or a chronic clinical syndrome of GVHD, but the clinical features do. Acute patterns of GVHD include skin bullae desquamation, severe bile duct injury, and extensive gastrointestinal crypt drop-out. On the other hand, chronic GVHD (cGVHD) features are more complex and may be limited to one organ or may be widespread. The cGVHD has the potential to affect all mucosal surfaces, including ocular, oral, vaginal, and gastrointestinal areas. Moreover, it can affect the skin, the liver and the lungs. Ocular surface mucosa is a representative target organ of cGVHD. Although rare, posterior

segment involvement includes ischemic microvascular retinopathy, posterior scleritis, choroidal thickening and serous detachment, which may significantly impair vision^[6,15,16].

The hallmarks of ocular GVHD include severe Keratoconjunctivitis Sicca (from major and accessory lacrimal glands infiltration by GVHD-effecting T lymphocytes), occurring in 40-76% of patients, and conjunctival inflammation, as a primary manifestation of cGVHD or secondary to severe dry eye^[1,2,4,5].

Ocular symptoms of mild cGVHD can be minimized by a stepwise approach involving local treatment only. Current ocular therapies include lubricant artificial tears, steroids, cyclosporine, tacrolimus, autologous serum tears, lacrimal punctal occlusion, and scleral contact lenses in order to support the tear film, control inflammation, and to maintain mucosal integrity. In patients with moderate-to-severe cGVHD systemic immunosuppressive therapy should be considered. Chronic GVHD itself and systemic immunosuppressive therapy both impair immune defenses, therefore infection-prevention measures are indicated. To date, there have been no controlled trials for ocular GVHD treatment options. Good medical practice and judgement dictate flexibility^[2,6].

The complexity of this disease and the serious impact on quality of life, impairing organ function and restricting daily activities emphasize the importance of the long-term management of the condition since with timely diagnosis, proper-tailored treatment, irreversible damage can be avoided^[2,6].

Successful management of cGVHD can control the disease until systemic treatment is no longer needed to prevent recurrent or progressive disease activity or even an exacerbation of any residual affliction^[10].

★ CASE PRESENTATION ★

We present the sinuous evolution and results of a conservative treatment (with topical lubricants associated with systemic and topical immunosuppressive treatments) in a case of a 29-year old female patient, with no ophthalmological antecedents, who developed a severe dry eye disease due to a chronic graft-versus-host disease.

In June 2016, the patient was diagnosed with acute lymphoblastic leukemia and one year later, in October 2017, she underwent an allogeneic stem cell transplantation with peripheral blood stem cells. Six months after transplantation, the immunosuppressive therapy was interrupted, and shortly after, she developed epiphora, followed by blurred vision OU, dry eyes, foreign

A CHALLENGING GRAFT-VERSUS-HOST DISEASE CASE - A CONSERVATIVE TREATMENT

body sensation, and redness along with photophobia.

At the initial presentation, we measured the best corrected visual acuity (BCVA) for the right eye (OD) 0.3 and for the left eye (OS) 0.7, with normal intraocular pressure. Abnormalities of tear dynamics were shown by Schirmer's test values (without anesthesia, at 5 minutes) of 0 mm in both eyes and initial tear break-up time (TBUT) of less than 5 seconds (BUT OD = 2 sec, BUT OS = 3 sec). The Ocular Surface Disease Index (OSDI) correlated significantly the patient perception of symptoms, revealing a total of 47 points, graded as severe (≥ 33).

On slit-lamp examination we determined: confluent areas of diffuse superficial keratitis (Fig.1), filaments stained with fluorescein dye, presence of conjunctival pseudomembranes (the early debridement was performed), subtarsal fibrosis of the upper eyelid of both eyes- an indicative of severe systemic involvement (Fig.2), obstruction of Meibomian gland and Zeis gland orifices and marked inflammation of the ocular surface. The Oxford ocular staining score showed a grade 2 score for cornea (between 6 and 30 corneal spots were evaluated on each eye).

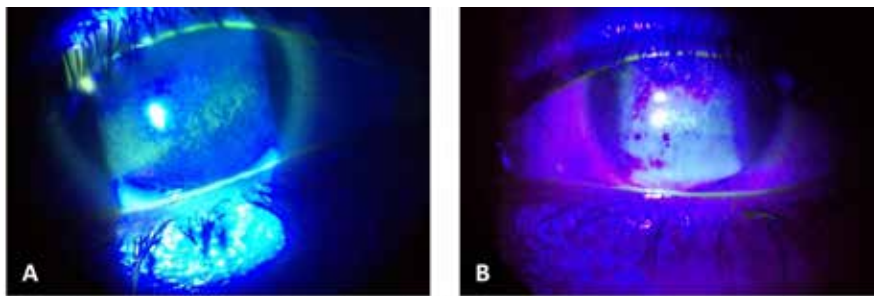


Figure 1: Right (A) and Left (B) eye (according to NIH Consensus, Grade 3 severe staining). Initial slit-lamp images showing diffuse superficial keratitis, with irregular distribution of fluorescein.

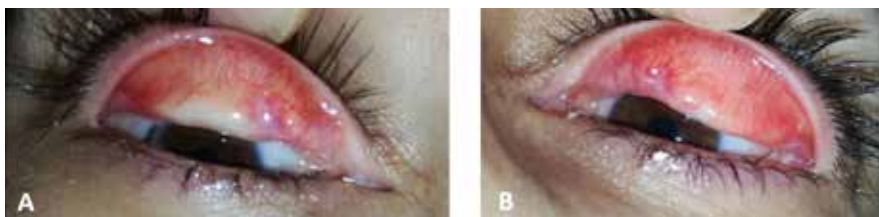


Figure 2: Right and Left eye. Initial slit-lamp images showing marked subtarsal fibrosis and conjunctival inflammation.

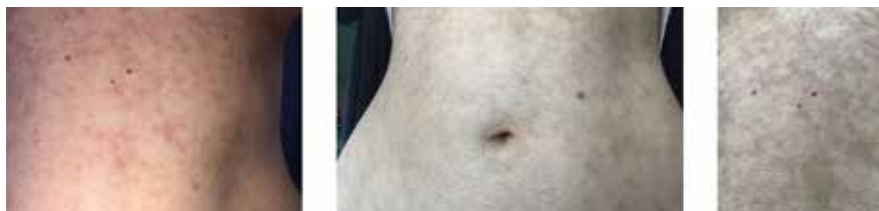

Figure 3: Poikiloderma - reticulated pattern of the abdomen. Epidermal atrophy and three colours: red, brown and white.

The routine blood tests showed abnormalities as follows: cholestasis (total bilirubin > 3 mg/dL), hepatic cytolysis with elevated alanine aminotransferase (ALT) levels (ALT > 5 x normal upper limit), eosinophilia. The clinical data revealed also a weight loss more than 5% without gastrointestinal symptoms.

According to the National Institutes of Health Consensus from 2014, a new ocular sicca documented by low Schirmer's test with a mean value of ≤ 5 mm at 5 minutes (score 3) is sufficient for the diagnosis of ocular chronic GVHD, but an additional distinctive clinical feature is necessary to establish eligibility for general chronic GVHD. Therefore, the liver disorders (score 3), the skin and mouth involvement (features scored 2, respectively 1) corroborate our patient's diagnosis of general severe chronic GVHD.

The ocular involvement was graded as severe (according to NIH consensus criteria 2014), based on the aggregation of specific parameters (OSDI, Schirmer test, corneal fluorescein staining and conjunctival inflammation), the severe dry eye symptoms and the loss of vision significantly affecting activities of daily living (our patient being unable to work).

The early diagnosis of chronic GVHD enabled adequate therapeutic intervention for ocular and systemic signs and symptoms. The treatment required multiple strategies including systemic and organ specific therapy, which focuses on increasing ocular surface moisture and on decreasing ocular surface inflammation.

The systemic therapy was promptly started by the hematologist with high-dose corticosteroid, considered as a first-line therapy (methylprednisolone, 1 mg/kg body weight/day) in combination with calcineurin inhibitor (CNIs) - cyclosporine, along with ursodeoxycholic acid, antiviral and antibiotic therapy, vitamins.

Considering the severe form of ocular GVHD, our algorithm starts the topical treatment with cyclosporine 0,1% once daily and 4 drops per day of corticosteroid (fluorometholone). Intensive topical application including preservative-free artificial tears (containing trehalose and hyaluronic acid - best tolerated by the patient), one drop every 30 minutes, and 2 times per day for the gel form were also recommended. Furthermore, we added autologous serum eye drops (prepared by spinning down the patient's whole blood, then collecting the serum into dropper bottle without dilution), 4 drops per day and Vitamin A (retinyl palmitate) - consisting ointment, at bedtime. In the first level of therapy we included also patient education and counseling. Usage of humidifiers, lower room temperatures and avoidance of sun exposure was recommended.

The patient was seen regularly in our Department of Ophthalmology as well as in the Department of Hematology/Oncology. During the following controls, gradual reduction of superficial punctual keratitis was observed. Vision of her both eyes had ameliorated progressively. A gradual tapering of the corticosteroids was performed. The hematologist recommended a reduction of 4 mg/week depending on the patient's clinical response.

At one month after the initiation of the systemic and topical treatment, the OSDI score decreased significantly from 47 (severe) to 16 points (mild), improving the quality of daily activities. The BCVA of the right eye was 0.7, and of the left eye was 0.6, with normal intraocular pressure. The Schirmer's test values remained 0 mm for both eyes, with the quality of tears affected, TBUT of 3 seconds in the right eye and 4 seconds in the left eye. The progressive discontinuation of general and topical corticosteroid continued. The current ocular therapy included: cyclosporine 0,1% once daily, fluorometholone, 2 drops per day, autologous serum eye drops, 4 drops per day, Vitamin A - consisting ointment, once, at bedtime, intensive topical application including preservative-free artificial tears (containing trehalose and hyaluronic acid), one drop every hour, and 2 times per day for the gel form.

Two months later, BCVA was measured OD 0.6 and OS 1. A subtle improvement was measured for the Schirmer test (OS = 2 mm), although a rise of the systemic corticosteroid dose was made due to the subjective complaints (severe dry eye, blurred vision OU).

Following controls in our outpatient clinic revealed a partial organ response, because of the recurrences of severe dry eye, the stable ocular surface alternating with a moderate inflammation. Topical cyclosporine 0,1% one instillation per day, fluorometholone (with progressive discontinuation), autologous serum eye drops and topical lubrication 5 times per day remained as local treatment.

The six-months follow-up showed:

- very good improvement of the vision for both eyes, BCVA OD = 1, BCVA OS = 1,
- a normal intraocular pressure (OU),
- schirmer test of 0 mm (OU),
- TBUT OU values less than 5 seconds (3 seconds, respectively 4 seconds),
- OSDI measured a total of 15 points (mild, symptom-free patient),
- superficial punctuate keratitis.

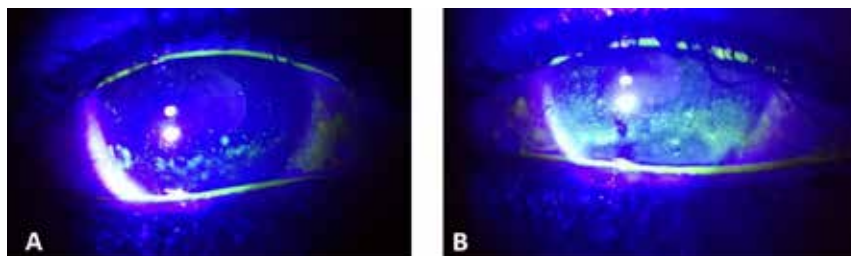


Figure 4: Right (A) and Left (B) eye. Follow-up at 6 months: the slit-lamp images showing diffuse superficial keratitis.

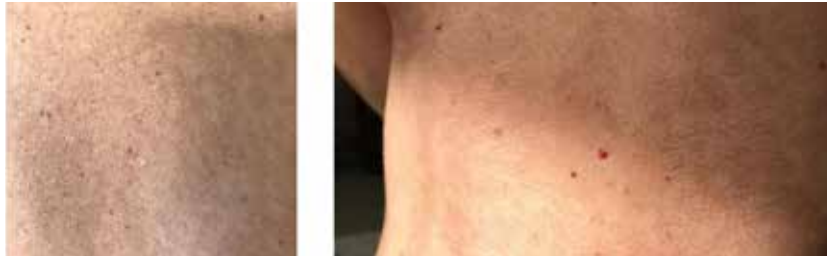

Figure 5: Skin appearance at 6 months follow-up.

Long-term topical cyclosporine and the low-absorption corticosteroid application was continued, with a frequency of one instillation at 2 days. 6 months after the initial presentation, the ocular surface presents no corneal filaments, but corneal spots. The Schirmer test and TBUT values did not change relevantly. Though, this discrepancy between the low values of Schirmer test and the subjective perception was expected, the correlation to the dry eye disease severity has not been confirmed in other studies either. On the other hand, assessment of patient symptoms with OSDI score added further information to the overall ocular evaluation. OSDI score is considered a valid and reliable tool for evaluation of dry eye disease severity and the impact on activities of daily life.

This association of systemic and organ specific therapy provided a stable ocular surface, without any complications, showing good results of the multidisciplinary team approach. For further organ specific therapies, we take into consideration the gas-permeable scleral lens for management of severe keratoconjunctivitis sicca. Temporary or permanent occlusion of the tear-duct punct may add significant improvements.

★ DISCUSSION ★

The systemic immune suppression remains the gold-standard in the management of the general cGVHD, having an effect also on improving dry eye symptoms. Furthermore, the association with the topical therapy offers functional benefits. The treatment regimens may vary, but it usually starts with 0.5 to 1 mg/kg body weight per day of methylprednisolone, with or without cyclosporine, tacrolimus or sirolimus. The immunosuppressive therapy extends on a median period of 2-3 years. The long-term steroid treatment at high-doses causes serious toxicity, 25% of treated patients presenting bone density loss, diabetes mellitus and infectious diseases. This requires a good strategy for tapering the dose, as soon as GVHD improves^[15].

On the other hand, the topical steroids run the risk of atrophy of the cornea and silent infectious keratitis. They are also associated with an increased risk of infection, high intraocular pressure, and cataract formation. For these reasons, topical steroids are recommended for pulse therapy better than for prolonged treatment. Topical cyclosporine has a higher long-term efficacy than steroids, though it can produce a local burning and stinging sensation^[12]. Treatment efficacy of a low-dose topical steroid in dry eye patients with chronic GVHD is reduced, compared with those without GVHD, even when controlling for clinical disease severity. This warrants the exploration of more effective therapies in managing ocular GVHD^[4].

First-line therapy in severe ocular cGVHD is represented by topical steroids, which exert non-specific inhibitory effects on the inflammatory response, decreasing the ocular surface inflammation, minimizing the need for systemic immunosuppression and maximizing the graft-versus-leukemia effect. In our case, the association of the promptly first line-therapy (systemic and topical steroids) with systemic and topical CNIs (with minimal side-effects), autologous serum, which controls also the ocular surface inflammation, and intensive topical lubrication were sufficient to prevent further complications and progression to higher stages. It is important to observe that even if recurrences were present in the evolution of our patient, the treatment response was favorable and that so far there have been no complications.

The goal of chronic GVHD treatment is to produce a sustainable benefit by reducing symptom burden, controlling objective manifestations of disease activity, preventing damage and impairment, and improving overall survival without causing disproportionate harms related to the treatment itself. Appropriate management of cGVHD requires continuous modulation of immunosuppressive treatment. The intensity of treatment required to control the disease decreases across time. Successful management of chronic GVHD can control the disease until systemic treatment is no longer needed to prevent recurrent or progressive disease activity or exacerbation of any residual damage.

We consider the ocular cGVHD a lifetime condition due to the marked tendency to recurrence or progression, despite intensive treatment. Long-term management and close monitoring are necessary, to prevent serious ocular complications like corneal ulceration, melting, and perforation, endophthalmitis, even after the need for intensive intervention has passed.

While ocular GVHD usually occurs in the setting of other systemic GVHD, it was the initial presentation of our patient's systemic GVHD. This leads us to suggest that dry eye is an important sign for diagnosis and early aggressive treatment of systemic chronic GVHD, a careful examination by the ophthalmologist perceptive to the diagnosis of ocular GVHD serves a crucial role^[5]. The severe ocular cGVHD presented as severe dry eye and ocular surface disease, which had a profound impact on the quality of life of our patient. The fact that she is a young, active individual offered us a very good compliance and adherence to the therapy.

Early detection, precise diagnosis of chronic ocular GVHD enabled adequate therapeutic intervention for ocular and systemic signs and symptoms, improved the ability to perform regular activities of daily living and enhanced the quality of our patient's life. An optimal outcome required a collaborative dialogue between our team of ophthalmologists, the hematologist and the bone-marrow transplant specialists.

★ CONCLUSION ★

We present a case of a severe Keratoconjunctivitis Sicca, as an initial manifestation of a general chronic graft-versus-host disease. The association of the systemic immune suppression therapy with topical steroid therapy, autologous serum, and intensive topical lubrication were sufficient to prevent further complications and progression to higher stages, even if recurrences were present in the evolution of our patient. A prompt diagnosis followed by a patient-tailored conservative treatment was essential in obtaining an optimal outcome.

Chronic GVHD remains a potentially life-threatening multi-organ systemic disease associated with significant mortality and morbidity and decreased quality of life. Helping these patients involves both raising awareness of the condition at large, educating and tailoring immunosuppression treatment approach to each affected person. Evaluation by an ophthalmologist and frequent follow-up exams should be included in the management of these patients, to prevent potential complications.

★ REFERENCES ★

1. Sundaram, V., Barsam, A., Barker, L., Khaw P.T., (2016). Training in Ophthalmology, the essential clinical curriculum (2nd Edition, pp. 62-63).
2. Nassiri N., Eslani M., Panahi N., Mehravaran S., Ziaei A., Djalilian A.R., Ocular Graft Versus Host Disease Following Allogeneic Stem Cell Transplantation: A Review of Current Knowledge and Recommendations. Retrieved October 2018 from *J Ophthalmic Vis Res* 2013; 8 (4): 351-358.
3. Reza D., Jager M.J., Kim S.K., Ocular Graft-vs.-Host Disease: The Downside of Success , *EyeNet Magazine* , December 2013.
4. Yin J., Kheirkhah A., Dohlman T., Saboo U., Reza D., Reduced Efficacy of Low-dose Topical Steroids in Dry Eye Disease Associated with Graft-versus-Host Disease. *Am J Ophthalmol* 2018; 190:17–23. 2018.
5. Ogawa, Y. et al. International Chronic Ocular Graft-vs-Host-Disease (GVHD) Consensus Group: Proposed Diagnostic Criteria for Chronic GVHD (Part I). *Sci. Rep.* 3, 3419; DOI:10.1038/srep03419 (2013).
6. Jagasia M.H., Greinix H.T., Aroca M., Williams K.M., Wolff D., Cowen E.W., Palmer J., Weisdorf D., Treister N.S., Cheng G.-S., Kerr H., Stratton P., Duarte R.F., McDonald G.B., Inamoto Y., Vigorito A., Arai S., Manuel B. Datiles, Jacobsohn D., Heller T., Kitko C.L., Mitchell S.A., Martin P.J., Shulman H., Wu R.S., Cutler C.S., Vogelsang G.B., Lee S.J., Pavletic S.Z., Flowers M.E.D., National Institutes of Health Consensus Development Project on Criteria for Clinical Trials in Chronic Graft-versus-Host Disease: I. The 2014 Diagnosis and Staging Working Group Report. *Biol Blood Marrow Transplant.* 2015 March; 21(3): 389–401.e1. doi:10.1016/j.bbmt.2014.12.001.
7. Shulman H.M., Cardona D.M., Greenson J.K., Hingorani S., Horn T., Huber E., Krefl A., Longrich T., Morton T., Myerson D., Prieto V.G., Rosenberg A., Treister N., Washington K., Ziemer M., Pavletic S.Z., Lee S.J., Flowers M.E.D., Schultz K.R., Jagasia M., Martin P.J., Vogelsang G.B., Kleiner D.E., Histopathologic Diagnosis Of Chronic Graft Versus Host Disease: NIH Consensus Development Project on Criteria for Clinical Trials in Chronic Graft-Versus-Host Disease: II. The 2014 Pathology Working Group Report. *Biol Blood Marrow Transplant.* 2015 April; 21(4): 589–603. doi:10.1016/j.bbmt.2014.12.031.
8. Lee S.J., Wolff D., Kitko C., Koreth J., Inamoto Y., Jagasia M., Pidala J., Olivieri A., Martin P.J., Przepiorka D., Pusic I., Dignan F., Mitchell S.A., Lawitschka A., Jacobsohn D., Hall A.M., Flowers M.E.D., Schultz K.R., Vogelsang G., and Pavletic S., Measuring Therapeutic Response In Chronic Graft-Versus-Host Disease: National Institutes of Health Consensus Development Project on Criteria for Clinical Trials in Chronic Graft-Versus-Host Disease: IV. The 2014 Response Criteria Working Group Report. *Biol Blood Marrow Transplant.* 2015 June; 21(6): 984–999. doi:10.1016/j.bbmt.2015.02.025.
9. Carpenter P.A., Kitko C.L., Elad S., Flowers M.E.D., Gea-Banacloche J.C., Halter J.P., Hoodin F., Johnston L., Lawitschka A., McDonald G.B., Opiari A.W., Savani B.N., Schultz K.R., Smith S.R., Surtala K.L., Treister N., Vogelsang G.B., Williams K.M., Pavletic S.Z., Martin P.J., Lee S.J., Couriel D.R., National Institutes of Health Consensus Development Project on Criteria for Clinical Trials in Chronic Graft-versus-Host Disease: V. The 2014 Ancillary Therapy and Supportive Care Working Group Report. *Biol Blood Marrow Transplant.* 2015 July; 21(7): 1167–1187. doi:10.1016/j.bbmt.2015.03.024.
10. Martin P.J., Lee S.J., Przepiorka D., Horowitz M.M., Koreth J., Vogelsang G.B., Walker I., Carpenter P.A., Griffith L.M., Akpek G., Mohty M., Wolff D., Pavletic S.Z., Cutler C.S., National Institutes of Health Consensus Development Project on Criteria for Clinical Trials in Chronic Graft-versus-Host Disease: VI. The 2014 Clinical Trial Design Working Group Report. *Biol Blood Marrow Transplant.* 2015 August; 21(8): 1343–1359. doi:10.1016/j.bbmt.2015.05.004.
11. Wolff D., Bertz H., Greinix H., Lawitschka A., Halter J., Holler E.: The treatment of chronic graft-versus-host disease: consensus recommendations of experts from Germany, Austria, and Switzerland. *Dtsch Arztebl Int* 2011; 108(43): 732–40. DOI: 10.3238/arztebl.2011.0732
12. Lin X., Cavanagh H.D., Ocular manifestations of graft-versus-host disease: 10 years' experience, *Clin Ophthalmol.* 2015; 9: 1209–1213. Published online 2015 Jul 3. doi: 10.2147/OPHT.S84704
13. Curtis L.M., Datiles M.B., Steinberg S.M., Mitchell S.A., Bishop R.J., Cowen E.W., Mays J., Cartu J.M., Kuzmina Z., Pirsal F., Fowler D.H., Gress R.E., Pavletic S.Z., Predictive models for ocular chronic graft-versus-host disease diagnosis and disease activity in transplant clinical practice, *haematologica* | 2015; 100(9)
14. Nassar A., Tabbara K.F., Aljurf M., Ocular manifestations of graft-versus-host disease, *Saudi Journal of Ophthalmology* (2013) 27, 215–222.
15. Ogawa Y, Kuwana M, Dry eye as a major complication associated with chronic graft-versus-host disease after hematopoietic stem cell transplantation. *Cornea.* 2003; 22:S19–S27.
16. Pathak M., Diep P.P., Lai X., Brinch L., Ruud E., Drolsum L., Ocular findings and ocular graft-versus-host disease after allogeneic stem cell transplantation without total body irradiation, *Bone Marrow Transplantation volume* 53, pages 863–872 (2018)



Dr. Nizar DIN
Moorfields Eye Hospital, London – UNITED KINGDOM

.....

SERIOUS CORNEAL COMPLICATIONS FROM UNDIAGNOSED FLOPPY EYELID SYNDROME

.....

★INTRODUCTION★

Floppy eyelid syndrome (FES) is a disorder of unknown aetiology characterised by extremely lax lids that can be everted by external skin traction¹. In affected individuals sleeping face down into a pillow can result in upper lid eversion and abrasion of the conjunctiva or cornea, with signs of chronic ocular surface irritation and a diffuse papillary conjunctivitis. Symptoms of chronic redness, stickiness and irritation are the usual reason for ophthalmic referral. Sight threatening corneal disease is rare, but associations include keratoconus²⁻⁴, corneal vascularisation, infectious keratitis, and corneal perforation⁴⁻⁷. Affected individuals are typically overweight males who may also experience chronic fatigue from obstructive sleep apnoea (OSA)⁸.

The lid laxity of FES may not be evident unless it is directly elicited, and individuals may not be aware they have (OSA). Failure to consider FES as a cause for chronic conjunctivitis or keratitis can lead to an unnecessary delay in starting appropriate management. The purpose of this paper is to describe three individuals who had severe progressive keratitis for a substantial period before the presence of FES was suspected. All three also had symptoms of OSA. To estimate the prevalence of severe corneal complications in individuals with FES we reviewed the clinical records of all individuals with a diagnosis of FES seen at this hospital over the ten-year interval from 2008.

★ CASE PRESENTATION ★

MATERIAL AND METHODS

The local research ethics committee approved this study, and it adhered to the tenets of the Declaration of Helsinki. We describe the clinical features of three individuals who had severe keratitis who were subsequently identified to have FES. For each individual we recorded the body mass index (BMI >25 = obese), the duration of symptoms, the features of their ocular disease, and the subsequent management. The Moorfields Eye Hospital electronic patient record was used to identify individuals potentially affected with FES seen in the 10-year interval from January 2008. We reviewed these records to confirm the diagnosis of FES and documented any corneal signs that had been recorded the clinical notes, recalling the paper records if there was diagnostic uncertainty. Serious corneal disease was defined as corneal ulceration, vascularisation or scar that affected vision. Individuals were not specifically examined for keratoconus or endothelial disease⁴.

RESULTS

CASE 1

A 37 year old man with a BMI of 41.2 who had a 6 month history of bilateral conjunctivitis, worse in the left eye, treated with multiple courses of topical antibiotic. He then developed an acute secondary bacterial keratitis, from which coagulase-negative staphylococcus isolated, and this was treated topical vancomycin and ceftazidime. Despite one month of this treatment the ulceration progressed, and the cornea perforated. Following transfer, he was diagnosed with FES with additional symptoms of sleep apnoea. An 8.50mm penetrating keratoplasty was performed combined with a temporary lateral tarsorrhaphy. Despite a subsequent lateral canthoplasty, and a further tarsorrhaphy, there was continued corneal exposure and severe ocular surface inflammation and the graft failed (Table 1, Fig 1 A-C).

CASE 2

A 43 year old male with a BMI of 39.5 who presented with an 8 week history of superior corneal ulceration (Fig 1D). The initial diagnosis was peripheral ulcerative keratitis and he received treatment with oral prednisolone 80mg daily and a botulinum toxin tarsorrhaphy. Investigations for autoimmune disease was negative (ACE, RhF, anti-CCP, ANCA, ANA, Hepatitis C) The cornea perforated and Enterococcus faecalis and a Staphylococcus sp were isolated. Following transfer, he was diagnosed with FES and a right tectonic lamellar keratoplasty was performed combined with a temporary lateral tarsorrhaphy. He was referred for symptoms of OSA and further lid surgery is planned.

CASE 3

A 44 year old man with a body mass index (BMI) of 38.9 was managed over four years for idiopathic bilateral inferonasal corneal scars, worse on the left side (Fig 1E-F). The scar on the left cornea was partly vascularised and it rapidly recurred despite 5 attempts at surgical removal, combined on occasion with fine needle vessel diathermy, subconjunctival injection of bevacizumab 2.5mg, and topical MMC 0.02% applied to the base of the lesion after excision. Histology of the primary excision specimen reported a hypertrophic vascularised scar. FES was identified four years after the onset of symptoms. He usually slept on his left side and his partner confirmed he had symptoms of sleep apnoea. He declined lid surgery and sleep studies but opted to attempt weight reduction instead and to use ointment and a protective shield over the left eye at night. The signs have remained stable over the subsequent 8 months.

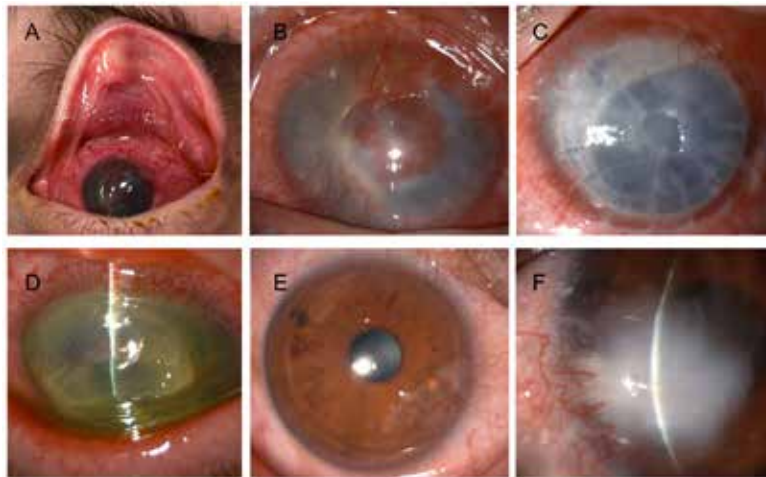


Figure 1 - Case 1 demonstrates extreme laxity of the upper lid, conjunctival hyperaemia, and a perforated central corneal ulcer (A). The cornea is densely vascularised and there is a large epithelial defect with a central perforation (B). Despite a tarsorrhaphy and lid-shortening, at four weeks after penetrating keratoplasty there is continuing ocular surface inflammation with a persistent epithelial defect, loose suture, and an opaque graft (C). Case 2 showing hyperaemia with a large superior corneal melt that had perforated (D). Case 3 with a nasal hypertrophic scar on the right cornea (E) and dense and vascularised scar on the left cornea (F). This individual usually slept with the left side of his face on the pillow.

Our retrospective review from the EPR identified 104 cases of FES who attended over a ten-year period (Table 2). This did not include the three individuals described above. Only a minority had been referred for review by a corneal specialist. From these 104 individuals there were only 4 (3.8%) cases who had severe keratitis; four patients had developed severe corneal vascularisation and corneal opacity and two of these had corneal ulceration that required a tectonic keratoplasty.

Case	Gender/age	BMI	Diagnosis Delay (months)*	Corneal features	Corneal management	Lid management	Final BCVA
1	M/37	41.2	7	Central corneal ulcer with perforation	Tectonic keratoplasty	Lateral tarsorrhaphy and secondary tarsorrhaphy	HM
2	M/43	39.5	2	Peripheral corneal ulcer with perforation	Lamellar keratoplasty	BTX tarsorrhaphy, temporary surgical tarsorrhaphy	HM
3	M/44	38.9	48	Vascularised hypertrophic scars	Superficial keratectomy x 3 Diathermy MMC 0.02%	Temporary tarsorrhaphy	6/36

Table 1 - Clinical details of three individuals with severe keratitis associated with floppy eyelid syndrome

BMI body mass index, HM hand movement, BTX botulinum toxin, BCVA best corrected visual acuity at last follow up

* From onset of symptoms to diagnosis of floppy eye syndrome

Corneal disease	Number (%)
Punctate epithelial keratitis	24 (23.1%)
Corneal vascularisation	4 (3.8%)
Filamentary keratitis	2 (1.9%)
Microbial keratitis	2 (1.9%)
Corneal perforation	2 (1.9%)
Persistent epithelial defect	1 (1.0%)

Table 2 - Corneal signs reported in 104 individuals diagnosed with floppy eyelid syndrome seen in the 10-year interval from 2008

★ DISCUSSION ★

Floppy eyelid syndrome (FES) is most frequently observed in obese males in their third or fifth decade, although it can also affect women and children.^{1,4,7} Affected individuals often experience chronic redness, ocular irritation and discharge. Clinical signs include a combination of easy eversion of the eyelids, a lax tarsal plate, and a secondary micropapillary conjunctival reaction.^{1,7} Secondary ocular surface disease can be very asymmetric or unilateral,^{4,7} which may reflect the preferred side on which patients sleeps, often face down on their pillow. Affected individuals may also have OSA.^{7,8} The aetiology of FES is unknown, but a degradation of elastin fibres may predispose to a loss of rigidity of the tarsal plates.^{7,9-11} Management is targeted at prevention of lid eversion and protection of the ocular surface⁷.

The three cases in this series each had chronic ocular surface disease associated with FES. In each there was a substantial delay between the onset of severe keratitis and identification of FES as the probable causative factor. In each individual there had been a failure to improve as well as potentially unnecessary investigations and treatments prior to the diagnosis of FES. Even after the diagnosis of FES was confirmed, the difficulty in surgically preventing lid eversion meant that the ocular surface disease was not rapidly controlled (Cases #1 and #2).

The prevalence of FES is also unknown, as it is an under-diagnosed cause for chronic conjunctivitis or keratitis.^{4,7} Not all patients have significant secondary ocular surface inflammation. In a case series of 60 patients 29% did not have signs of corneal disease.⁴ The most common corneal change suggestive of chronic ocular surface disease is punctate epithelial keratopathy (45%), but filamentary keratitis, recurrent corneal erosion, microbial infection, vascularisation, and scarring and stromal melting also occur.⁴ Corneal perforation has been reported as a complication of FES, either secondary to microbial infection or as a result of exposure.⁴⁻⁶ However, in these reports the infection and perforation either occurred after the diagnosis of FES had been made or lid surgery performed,^{4,5} or there was associated rheumatoid arthritis

that could have predisposed the eye to a corneal melt.⁶ In our retrospective review of 104 individuals 23% were recorded to have signs of corneal disease. This prevalence of corneal disease is lower than in a previous reports on 60 individuals with FES,⁴ which may reflect the shorter period of follow up or our preferred primary management pathway to the oculoplastic service rather than to the corneal service.

★ CONCLUSION ★

In conclusion, severe corneal disease can be the presenting feature of FES, but in some individuals the diagnosis of FES can still be delayed or missed. Therefore, signs of FES should be actively sought in individuals who have chronic conjunctivitis or keratitis, particularly if they are obese. Affected individuals may not volunteer that they have symptoms of a disturbed sleep pattern until asked directly, and individuals who have associated symptoms of OSA should be referred for sleep studies and potential continuous positive airways pressure (CPAP) therapy. This study highlights that although the proportion of individuals with FES who have sight loss from corneal complications is low, the consequences of a missed diagnosis can be a protracted delay in providing appropriate treatment and thus clinical deterioration, as well as unnecessary investigation and treatment.

★ REFERENCES ★

1. Culbertson WW, Ostler HB. The floppy eyelid syndrome. *Am J Ophthalmol.* 1981;92(4):568-575.
2. Donnenfeld ED, Perry HD, Gibraltar RP, Ingraham HJ, Udell IJ. Keratoconus associated with floppy eyelid syndrome. *Ophthalmology.* 1991;98(11):1674-1678.
3. Pihlblad MS, Schaefer DP. Eyelid laxity, obesity, and obstructive sleep apnea in keratoconus. *Cornea.* 2013;32(9):1232-1236.
4. Culbertson WW, Tseng SC. Corneal disorders in floppy eyelid syndrome. *Cornea.* 1994;13(1):33-42.
5. Pujari A, Bajaj MS, Padhy SK, Agarwal D. Floppy eyelid syndrome: delayed diagnosis is not desired. *BMJ Case Rep.* 2017;2017.
6. Rossiter JD, Ellingham R, Hakin KN, Twomey JM. Corneal melt and perforation secondary to floppy eyelid syndrome in the presence of rheumatoid arthritis. *Br J Ophthalmol.* 2002;86(4):483.
7. Ezra DG, Beaconsfield M, Collin R. Floppy eyelid syndrome: stretching the limits. *Surv Ophthalmol.* 2010;55(1):35-46.
8. Leibovitch I, Selva D. Floppy eyelid syndrome: clinical features and the association with obstructive sleep apnea. *Sleep Med.* 2006;7(2):117-122.
9. Segev F, Heon E, Cole WG, et al. Structural abnormalities of the cornea and lid resulting from collagen V mutations. *Invest Ophthalmol Vis Sci.* 2006;47(2):565-573.
10. Netland PA, Sugrue SP, Albert DM, Shore JW. Histopathologic features of the floppy eyelid syndrome. Involvement of tarsal elastin. *Ophthalmology.* 1994;101(1):174-181.
11. Schlotzer-Schrehardt U, Stojkovic M, Hofmann-Rummelt C, Cursiefen C, Kruse FE, Holbach LM. The Pathogenesis of floppy eyelid syndrome: involvement of matrix metalloproteinases in elastic fiber degradation. *Ophthalmology.* 2005;112(4):694-704.++



Mrs. Anna FRIESACHER

Universitätsklinik für Augenheilkunde, Graz – SWITZERLAND

.....

NECROTIZING SCLERITIS AFTER “PTERYGIUM” EXCISION WITH MITOMYCIN C

.....

★INTRODUCTION★

The first reported use of mitomycin C in pterygium surgery is documented in Japan in 1963¹ and later on in the USA in 1988². Mitomycin C is as an alkylating agent and an anti-tumour antibiotic isolated from *Streptomyces caespitosus*. It inhibits the DNA synthesis, leading thus a long-term inhibition of tenon’s fibroblast proliferation³. Combined pterygium excision with intraoperative application of mitomycin C is discussed to reduce the recurrence rate. Nevertheless, we should be aware of potential adverse effects and complications of mitomycin C application. Review of the literature to date describes some mild complications as punctate keratitis, chemosis and delayed wound healing of the conjunctiva⁴, but also severe, vision-threatening complications as persisting corneal oedema, corneal perforation, scleral thinning and calcification, iritis, sudden onset of mature cataract, as well as secondary glaucoma, photophobia and pain^{5,11}. Application of mitomycin C was associated with significant corneal endothelial cell loss¹¹. Here, the non-healing conjunctival epithelial defect it thought to proceed to the dreaded scleral or corneal melting⁶. Treatment options include a variety of surgical and non-surgical procedures to prevail perforation of the eye.

We report on minimal invasive procedures applied in a patient with scleral necrosis and severe bullous keratopathy following pterygium excision combined with intraoperative application of mitomycin C. The treatment applied here supported the healing process confirmed by subjective improvement of patient’s symptoms.

★ CASE PRESENTATION ★

A 87-year-old man presented in our clinic for a second opinion having suffered a persisted severe ocular pain on the left eye for the last three weeks, started on the second day after surgery.

At presentation, three weeks after surgery a gradual thinning of the sclera spreading to the adjoining cornea was observed, probably as due to scleral and perilimbal ischemia surrounded by secondary inflammation. Scleral necrosis and marginal corneal ulceration are easy to recognise in Figure 1. In addition, the clinical examination revealed signs of chronic blepharitis with a dysfunction of the marginal eyelid glands on both eyes, as well as, a negative Bell's sign were observed on both eyes. No leaking could be detected with Fluorescein test. The best-corrected visual acuity was 0.3 on the left eye and 0.9 on the right eye. The intraocular pressure was within the normal range and symmetric on both eyes. Fundoscopy showed no relevant pathology. The diagnosis of postoperative mitomycin C induced scleral necrosis and keratopathy on the pre-existing trophic anterior segment disease, were postulated.

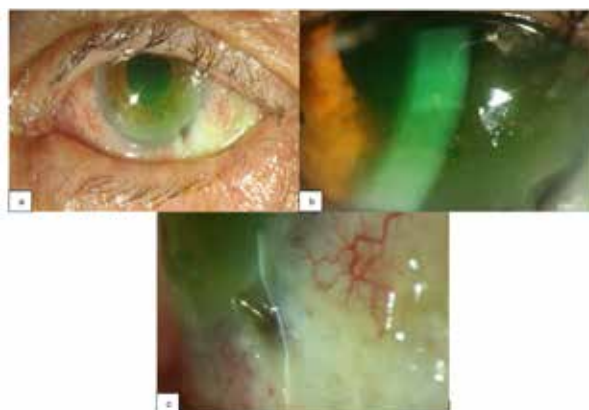

Figure 1: (a) Ischemic perilimbal area at 5 o'clock position with scleral thinning spreading to the adjoining cornea, surrounded by inflammation. Bullous keratopathy and marginal corneal ulceration, merging inferior-temporal sclera (b) with a conjunctival substance defect and avascular necrotic sclera (c) are to be detected.

According to the surgery report, a 0.02% mitomycin C was applied for 3 minutes following surgical excision of the "pterygium". Afterwards, the bare sclera was covered with amniotic membrane graft, sutured with Vicryl 7.0.

Histological results revealed conjunctival tissue with focal metaplasia of the squamous epithelium, stromal fibrosis, elastosis, as well as a small amount of conjunctival calcification, findings compatible with pinguecula on atypical location (Figure 2).

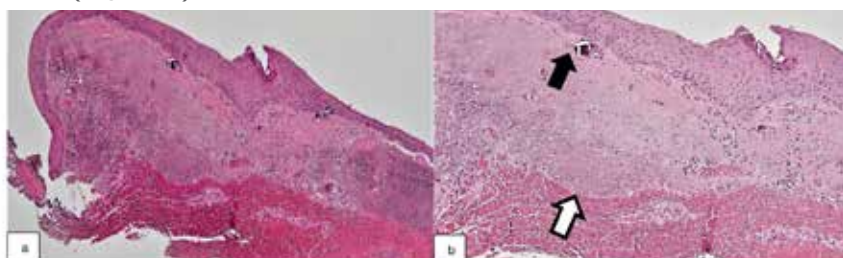


Figure 2: Hematoxylin-eosin staining of the excised tissue. Magnification 50x (a), shows a squamous epithelium mucosa with elastosis, a finding typical for pinguecula (white arrow). Magnification 100x (b) reveals in addition, subepithelial fibrotic connective tissue with a small amount dystrophic calcification (black arrow).

NECROTIZING SCLERITIS AFTER “PTERYGIUM” EXCISION WITH MITOMYCIN C

We proceeded with conservative local lubrication, supported by broad-spectrum local and systemic antibiotic therapy. Instead of local steroids, we reduced the already initiated systemic prednisone treatment from 40 to 20 mg once a day.

Due to accompanying blepharitis, we started doxycycline 100 mg once a day to strengthen the corneal stroma, thus preventing perforation. In order to reduce the intense pain and to support a sufficient closure of the eye in the presence of negative Bell's phenomenon, we injected a total of 20 units Botox in the lower eyelid.

At presentation, before receiving any preliminary histology, due to the patient's age and in order to cover a possible simultaneous herpes superinfection, we added to systemic therapy a 500 mg valaciclovir twice a day.

Following patient's general history, neither systemic autoimmune, nor rheumatoid diseases were reported, as might be expected in association with scleromalacia.

Within the following days a gradual remission under applied treatment, was achieved. A significant reduction of the necrotic area supporting the symptomatic pain release could be monitored. The corneal thickness resolved slowly (Figure 3).

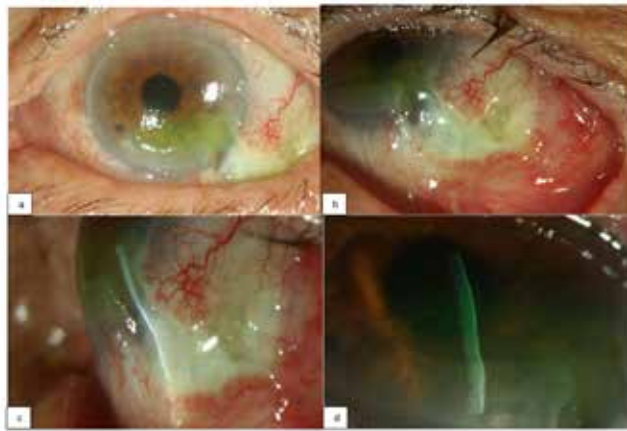

Figure 3: (a, b) Reduction of the necrotic area and the surrounded inflammation, (c) even if the thinning of the sclera and (d) the cornea still persists.

Within the following two weeks a mild vascularization on the margin of the lesion could be observed. The extension of the corneal erosion showed a significant regression (Figure 4). However, further improvement is still to be expected.

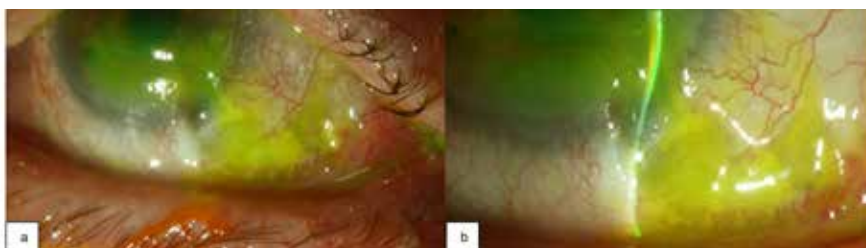

Figure 4: (a) Further regression of the scleral and corneal defect within the following two weeks.

★ DISCUSSION ★

The presented herein case illustrates an example of severe complications, in terms of scleral necrosis and deep corneal ulceration, due to mitomycin C application during pinguecula excision.

Our case provides a picture of trophic anterior segment disorder as part of chronic eyelid margin dysfunction, with consecutive moisturize malfunctioning, by underlying negative Bell's phenomenon. All of the listed entities seem to be the reason for the atypical fibroblastic conjunctival proliferation presented as an atypical pinguecula, unfortunately recognised as a pterygium.

The combination of excision of the ("supportive trophic") fibrotic conjunctival tissue to the bare sclera with the application of mitomycin C, which inhibits DNA synthesis, have led to a progressive necrosis of the adjoining sclera and cornea, in our case.

According to the literature, the recurrence rate after simple pterygium excision using bare sclera technique without adjuvant treatment is between 24% and 89%⁴. The application of mitomycin C reduces the rate from 2.7% to 44%^{5,13}. Many studies to day discuss the effectiveness and the safety of mitomycin C with consideration. For instance, an application time of three minutes and a concentration of 0.02% are suggested to be the best balance between the shortest exposure time and the lowest concentration⁶, which has been taken into consideration here, as well. However, the age and the predisposing trophic pathology by underlying negative Bell's phenomenon should have preliminary been evaluated with care.

In the literature, the most reported complications after mitomycin C application are necrotising scleritis, scleral calcification and ulceration, corneal oedema, iritis, glaucoma, cataract and corneal damage⁷. Nowadays, in order to prevent early complications it is advisable to use a conjunctival-limbal autograft or amniotic membrane transplantation simultaneously (avoiding a bare sclera)⁷ and to try to preserve as much as possible normal scleral and conjunctival tissue applying little or no cauterisation⁸.

Conservative treatment of scleral complications includes corticosteroids, cyclooxygenase inhibitors, local and systemic antibiotics, immunosuppressive agents as: cyclosporine, methotrexate, infliximab and anti-TNF blockers⁹.

The goal of any late surgical interventions is reconstruction of necrotic areas to support the healing process, e.g. excision of granulation tissue, conjunctival-tenon grafts, amniotic membranes or the use of scleral patch⁹.

In our case, apart from the conservative therapy and minimal invasive procedure, we supported the trophic problem and the negative Bell's phenomenon in this elderly man, by application of Botox. Nevertheless, the follow up is remaining. Further operative treatments to achieve a satisfying result might still be necessary.

★ CONCLUSION ★

This case describes the importance of the strict selection of patients and the controlled use of mitomycin C in pterygium surgery with a careful follow up of the avascular conjunctival and per-iliacal scleral area⁸. Among the patient's age, other risk factors to be included are: systemic autoimmune diseases, as well as other systemic diseases predisposing to immunodeficiency or wound-healing impairment, as for instance diabetes mellitus, thyroid disorders, ophthalmic zoster and hypercalciuria¹⁴. Moreover, before applying mitomycin C, any local surface disorders like keratoconjunctivitis sicca, acne rosacea, atopic keratitis or Sjögren's syndrome should be ruled out¹⁰.

There is a direct correlation between increased concentration and extend of exposure. Further studies are needed to find the optimal route of administration, dose and duration of treatment with mitomycin C, which provide the greatest combination of safety and efficacy¹³.

With this illustration, we hope to call attention to the intraoperative use of mitomycin C in order to prevent severe ocular complications in the future. Application of mitomycin C is an effective adjuvant to reduce recurrence rate of pterygium, but should be used with consideration in patients featuring predisposing factors for scleral necrosis.

★ REFERENCES ★

1. Kunitomo N, Mori S. Studies on the pterygium. Part 4: a treatment of the pterygium by mitomycin-C installation (in Japanese). *Nippon Ganka Gakkai Zasshi* 1963;67:601-607
2. Singh G, Wilson MR, Foster CS. Mitomycin eye drops as treatment for pterygium. *Ophthalmology* 1988;96:813-821
3. Solomon A, Kaiserman I, Raiskup FD, et al. Long-term effects of mitomycin C in pterygium surgery on scleral thickness and the conjunctival epithelium. *Ophthalmology* 2004;111:1522-1527
4. Perez-Rico C, Benitez-Herreros J, Montes-Mollon MA, et al. Intraoperative mitomycin C and corneal endothelium after pterygium surgery. *Cornea* 2009;28:1135-1138
5. Anduze AL, Burnett JM. Indications for and complications of mitomycin-C in pterygium surgery. *Ophthalmic Surg Lasers* 1996;27:667-673
6. Raiskuo F, Solomon A, Landau D, et al. Mitomycin C for pterygium: long-term evaluation. *Ophthalmology* 2004;88:1525-1428
7. Rubinfeld RS, Pfister RR, Stein RM, et al. Serious complications of topical mitomycin-C after pterygium surgery. *Ophthalmology* 1992;99:1647-1654
8. Lam D, Wong A, Fan D, et al. Intraoperative mitomycin C to prevent recurrence of Pterygium after excision. *Ophthalmology* 1998;105:901-905
9. Gupta A, Thakur A. Surgically induced necrotizing scleritis. *The Uveitis Atlas*. Springer (India). 2016;1-6
10. Safianik B, Ben-Zion I, Garzozzi HJ. Serious corneoscleral complications after pterygium excision with mitomycin C. <http://www.ncbi.nlm.nih.gov/pmc/articles/PMC1771048>. (0810.2018,21.45)
11. Hardten DR, Samuelson TW. Ocular toxicity of mitomycin-C. *Int Ophthalmol Clin* 1999;39(2):79-90
12. Kheirkahsh A, Izadi A, Kajari MY, et al. Effects of mitomycin C on corneal endothelial cell count in pterygium surgery: role of application location. *Am J Ophthalmol* 2011;151:488-493
13. Kaufman SC, Jacobs DS, Lee WB, et al. Options and Adjuvants in surgery for Pterygium. A report by the American Academy of Ophthalmology. *Ophthalmology* 2013;120:201-208
14. Watson PG, Hazleman BL. *The sclera and systemic disorders*. Sussex: Saunders, 1976



Dr. Galina GLADYSHEVA
Bauman University, Moscow – RUSSIA

.....

DEVELOPMENT OF INFLAMMATORY EYE DISEASES IN PATIENTS WITH ENDOCRINE OPHTHALMOPATHY AFTER THE ELIMINATION OF RESTRICTIVE STRABISMUS

.....

★INTRODUCTION★

In this report, I would like to touch upon one of the global problems, which, in my opinion, has not so far been given due attention to, that is the development of inflammatory eye diseases in patients with endocrine ophthalmopathy after the elimination of restrictive strabismus. Another goal is to show, with a clinical example, ways toward the solution of this problem.

The incidence of autoimmune diseases of the thyroid gland with its hyperfunction (Basedow's, or Graves' disease) varies in various regions from 0.5 to 2%, and endocrine ophthalmopathy (EOP) evolves in 40-60% of patients. In recent years, the incidence of such diseases tends to increase.

The average age of patients varies from 35 to 58 years. The peak incidence falls on the 5th and 7th decade of life. Women get sick 2.7-5.25 times more frequently than men. Nevertheless, the number of severe forms of the disease decreases, which regularity is associated with the improvement in the diagnosis, made by endocrinologists, of early forms of thyrotoxicosis and, accordingly, their earlier treatment. Also, not the least role is played by the interest that ophthalmologists have shown in treatment of this pathology in recent years, taking upon themselves the burden of treating such patients.

Today, one can say with certainty that EOP is not an independent disease, but it arises as a result of complex immunopathogenetic mechanisms against the background of obvious or hidden dysfunction of the thyroid gland. There are three practically equivalent factors participating in the development of exophthalmos: the increase in the volume of extraocular muscles (EOM) as a result of cellular infiltration, the increase in the volume of orbital fat against the background of disturbed adipogenesis, and the edema of the soft tissues of the orbit (EOM and orbital fiber) resulting from the excessive accumulation of glycosaminoglycans.

In addition, we cannot exclude the violation of the venous current in the orbit, which occurs when the volume of its soft tissues increases, especially at the apex of the orbit. An increase in the soft tissues of the orbit at an unchanged volume of the orbital cavity itself leads to the ejection of the soft tarsoorbital fascia of the orbit to the front and the emergence of characteristic symptoms of rare blinking and gazing (Stellwag symptom), the exposure of a wide scleral band when looking up (Kocher's symptom) or down (Gref's symptom) and other symptoms.

Pronounced exophthalmos can lead to keratopathy. In addition to the severity of exophthalmos, risk factors include incomplete eyelid closing, dry eye syndrome, corneal sensitivity disorders, absence of Bell phenomenon, and the retraction of the lower eyelid. Histological studies point to a nonspecific character of the lesion, represented by epithelium keratinization, ulceration and vascularization of the cornea, which can be caused by infiltrates and extensive erosions, up to purulent xerotic keratitis.

Thus, the wide prevalence of inflammatory diseases of the eye surface in patients with endocrine ophthalmopathy inflicts the danger of development of severe consequences. The incapacitation of patients determines the appropriateness and relevance of our research as well as the application of pathogenetically substantiated methods and approaches to treatment.

★ CASE PRESENTATION ★

A 52-year-old patient complained of a decrease in left-eye visual acuity, yellowing of the left eye, pain in the left eye, photophobia, and the swelling of the upper eyelid.

From the anamnesis of the disease: 10 days ago, the patient was operated on: Hyposuprotropia with a restrictive component. Endocrine ophthalmopathy of the both eyes. The patient underwent a full diagnostic examination. A diagnosis was made.

Keratouveitis is sharp, severe course. Purulent corneal ulcer of the left eye. Endocrine ophthalmopathy of the both eyes.

The objective picture of the patient included lacrimation, purulent discharge, and the mixed injection of the eyeball.

The biomicroscopic examination of the left eye with the staining of fluorescein solution (Figure 3.) has revealed the presence of a round infiltrate dense in the optical zone of cornea with a diameter of 5.5 x 4.5 mm along the circumference of which there was deposit of yellow pus. The defect is colored bright green. An active purulent infiltration of deep-lying stromal strata of the cornea was observed. There was no involvement of the iris in the process, the pupil reacted to the light. There were post-operative sutures on the conjunctiva.

B-scan has not revealed any vitriate signs.

VISUAL ACUITY:

- Vis of the right eye 0.3 sph-0.75D cyl-4.0D ax10°=0.5 incommensurable
- Vis of the left eye 0.03 sph-1.0D cyl-4.0D ax160°=0.08 incommensurable

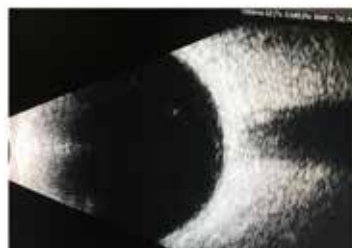

Figure 1: B-scan: the vitreous body has multiple hypoechogenic inclusions, without fixation to the membranes, a slight thickening of the choroid.

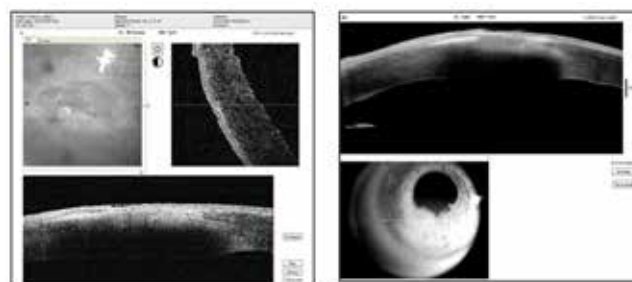


Figure 2: OCT of the anterior segment: the cornea is thickened; an inhomogeneous hyperreflective focus being present in the surface strata and obscuring deeper-lying areas.choroid.

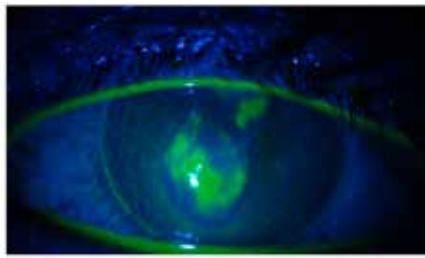


Figure 3: Staining of the cornea with fluorescein solution, choroid.

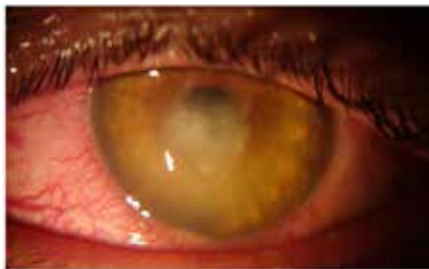


Figure 4: Central corneal ulcer.

The patient was prescribed anti-inflammatory, antibacterial, and keratoprotective treatment (general and local):

Of the left eye: Dalargin 1 mg No. 7, Lidocaine 2% 2.0 ml No. 7.

Intramuscularly: Cefotaxime 500 mg No. 7, Prourokinasa 5000 ME No. 7, Meldonium 10% 1 ml No. 7, Choline alfoscerat No. 7, Diclofenac 3.0 No. 3, Valaciclovir No. 10.

In under the conjunctivitis: Gentamicin 0.5 No. 10, Mezaton No. 10

General intravenously Dexamethasone 2.0 No. 5, Furosemide 2.0 No. 5.

During treatment, she received magnetophoresis with Levofloxacin No. 7, drop irrigation with Dextrani No. 5

Locally, Picloxidin drops 4 times a day, Tropicamide + phenylephrine 2 times a day during 2 weeks, Bromfenac once a day during 1 month, Dexpanthenol 3 times a day during 1 months, and application of the Vita-Pt ointment for the night were prescribed locally. Also prescribed were Meloxicam 1 tablet 15 mg once a day during 10 days and Valaciclovir 1 tablet once a day during 1 month. Immediately, a cornea swab was taken and the seeding for microflora and for the sensitivity to antibiotics was made.

Bacteriological study of the left eye conjunctiva: no growth of microflora and Candida fungi was found, and an abundant growth of gram-positive Staphylococcus aureus cocci was observed.

**DEVELOPMENT OF INFLAMMATORY EYE
DISEASES IN PATIENTS WITH ENDOCRINE
OPHTHALMOPATHY AFTER
THE ELIMINATION OF RESTRICTIVE STRABISMUS**

The next day a positive dynamics was observed: the discharge was minimal, the center of the ulcer has cleared of pus, the purulent plaque remained present only around the periphery of the ulcer. Then, for another one day, the pus had cleared completely, the eye became calmer, and the epithelization of the ulcer began.

Of physiotherapy procedures, the following was prescribed:

Electrophoresis with calcium chloride 2% No. 7, Laser stimulation No. 7.

Reseeding done on the tenth day gave no growth. The course of treatment lasted up to ten days. On the tenth day by the OCT of the anterior segment it was revealed that the cornea thickness had decreased and the hyperreflective focus in the surface strata exhibited more distinct boundaries. The patient was discharged with a calm eye and with persistent cornea opacity as an out-come.

VISUAL ACUITY ON DISCHARGE:

- Vis of the right eye 0.3 sph-0.75D cyl-4.0D ax10°=0.55 in corrigible
- Vis of the left eye 0.1 sph-0.75D cyl-4.0D ax160°=0.45 in corrigible

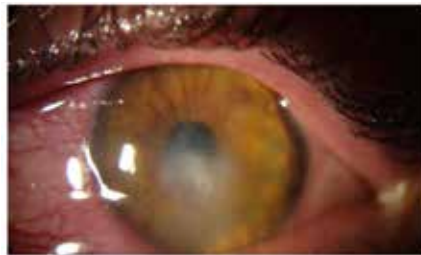

Figure 5: Persistent cornea opacity in the outcome of purulent corneal ulcer.

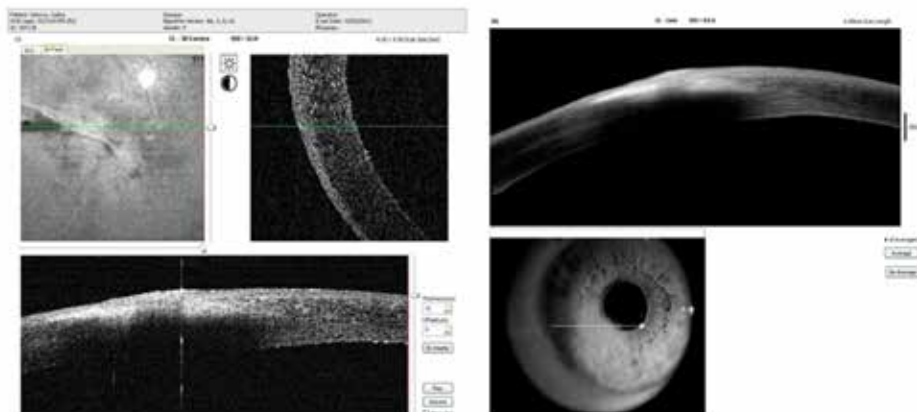


Figure 6: OCT of the anterior segment: the cornea thickness has decreased, the hyperreflective focus in the surface strata exhibits more distinct boundaries.

★ DISCUSSION ★

This clinical example is very meaningful in terms of complications of surgical treatment of patients with restrictive strabismus against the background of endocrine ophthalmopathy. Therefore, an important aspect of the intra-operative management of patients with EOP was the prevention of complications from the side of cornea. This point is related with the duration of surgery, and with the danger of damages inflicted to the corneal epithelium when it contacts the eyelid speculum as a result of considerable vertical eye rotations during the operation.

We use the more frequent irrigation of cornea with saline or the instillation of viscoelastics as keratoprotectors.

The nearest post-operative complications can be revealed in connection with the fact that the akinesia created for the operation leads to the fact that within 2-3 hours after the operation, the patient has no ability to completely close his/her eyelids.

This also increases the risk of keratopathy. The cause may be the contact of the cornea with an applied sterile gauze dressing and with no moistening of cornea due to the lack of adequate eye blinking. In addition, the pre-operative hypotrophy state produced the protection of cornea by the contact with the conjunctiva of the lower eyelid. The level position of the eye after the operation deprives the patient of this "protection". That is why a perforated convex plastic occluder was applied onto the patient instead of gauze dressing (Figure 7). Until reaching the ability to completely close the eyelids (Figure 9), the patient's cornea is to be irrigated with keratoprotectors (Figure 8).

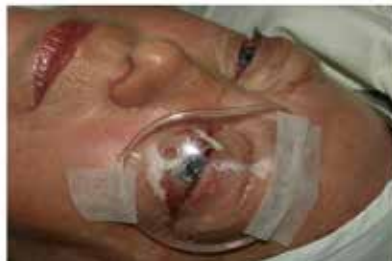

Figure 7: Transparent perforated occluder.

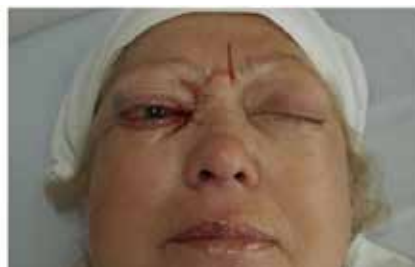

Figure 8: Cornea irrigation with VitA-pos until the termination of akinesia.

DEVELOPMENT OF INFLAMMATORY EYE
DISEASES IN PATIENTS WITH ENDOCRINE
OPHTHALMOPATHY AFTER
THE ELIMINATION OF RESTRICTIVE STRABISMUS

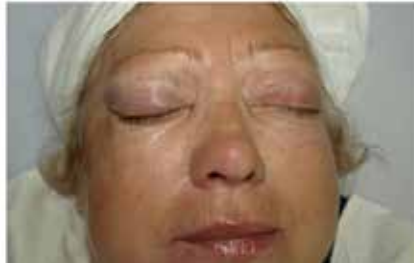

Figure 9: Complete closure of eyelids.

★ CONCLUSION ★

The proposed intraoperative and postoperative surveillance of patients with endocrine ophthalmopathy is the most justified one since it helps to minimize all possible sequelae from the side of the cornea.

Patients with endocrine ophthalmopathy in the post-operative period need a dynamic observation of an ophthalmologist for a period of at least a month, with a 14-day prescription of broad-spectrum antibiotics, and with the permanent administration of keratoprotectors and moisturizers for cornea and conjunctiva.

★ REFERENCES ★

1. Dedov I.I., Mel'nichenko G.A. Endokrinologiya. Natsional'noye rukovodstvo. Dedov I.I., Mel'nichenko G.A., Endocrinology. National guide. Moscow, 2008.
2. Panteleeva O.G. Sovremennaya kontseptsiya mekhanizma narusheniy zritel'nykh funktsiy pri endokrinnoy oftal'mopatii: Avtoref. dissertatsii doktora med. nauk. Panteleeva O.G. The modern concept of the mechanism of visual function disorders in endocrine ophthalmopathy: Theses of a Dissertation for the Degree of a Doctor of Medical Sciences, Moscow, 2007.
3. Mourits M.P., Koornneef L., Wiersinga W.M., Prummel M.F., Berghout A., Gaag R. van der. Clinical Criteria for the Assessment of Disease Activity in Graves Ophthalmopathy: Novel Approach // Br. J. Ophthalmol. 1989. Vol. 73. P. 639–644.
4. Plisov I.L. Sposob lecheniya restriktivnogo kosoglaziya, assotsirovannogo s endokrinnoy oftal'mopatiyei // Patent Rossiyskoy Federatsii No. 2313319. 2006. Byul. No. 17. Plisov I.L. A method of treatment of restrictive strabismus associated with endocrine ophthalmopathy // RF Patent No. 2313319. 2006. Bull. No. 17.



Mrs. Bárbara GONZALEZ
Hospital Universitario La Paz, Madrid – SPAIN

.....
**EVALUATION OF HYDROCORTISONE
AS TREATMENT OF OCULAR
GRAFT-VERSUS-HOST DISEASE:
A CASE REPORT**
.....

★INTRODUCTION★

Graft-versus-host disease (GVHD) is one of the main complications in bone marrow transplantation, an immune response derived from T donor cells infiltration directed against the host tissues, mainly attacking the skin, liver, gastrointestinal system and glands. The incidence oscillate from 10% to 90% depending on different factors like the donor or the induction protocol^(1,2).

Typically GVHD has been divided into acute and chronic forms, depending on when did the symptoms started before or after 100 days of the transplantation, although currently many authors divide it according to clinical criteria⁽¹⁾.

Ocular manifestations ranges from 60% to 90% and it may affect anterior or posterior segments, being more oftently affected the anterior ocular surface. Dry eye is the most common disorder and it is observed in almost 90% of the cases⁽³⁾.

The treatment of chronic GVHD is based on hydration with artificial

tears and on the control of inflammation with topical corticosteroids and immunosuppressants. However it is often not enough to control the ocular manifestations. Topical medications including serum autologous eyedrop for lubrication and also corticosteroids, cyclosporine and tacrolimus are the main treatment of the ocular GVHD. In spite of these, a satisfactory control of the inflammation and ocular discomfort often remains a challenge^(1,4).

The aim of this case report is to study the effect of a new topical corticosteroids whose active principle is hydrocortisone on ocular surface inflammation in the context of ocular GVHD.

★ CASE PRESENTATION ★

A male patient, forty-nine years old, was diagnosed of high-risk acute myeloblastic leukaemia type M2. He was referred to our center for performing allogeneic transplantation from an unrelated donor in July 2017, after two cycles of induction with Idarubicin and Ara-c according to the PETHEMA LMA 2010 protocol.

The patient is evaluated twelve months after the transplant due to suspicion of chronic GVHD, with symptoms such as ocular foreign body sensation, fluctuating vision and photophobia that did not improve with artificial tear drops.

Slit lamp examination in both eyes revealed telangiectasias in the free edge of the eyelid, staining of the external half of the Marx line as well as thin pseudomembranes in the lower tarsus of the right eye.

In addition, we observed mild-moderate conjunctival hyperemia (Image 1), as well as mucin filaments attached to the cornea of both eyes (Image 2).

Fluorescein and green lysine stain (Image 2 and 3) showed grade III superficial punctate keratitis (SPK) bilateral affecting cornea and conjunctiva (according to Oxford Scheme).

The basal Schirmer test was 0 mm and 3 mm in the right and left eye respectively, and the intraocular pressure was 10 millimeters of mercury (mmHg) in both eyes.

Therefore, treatment with topical hydrocortisone in monodose was started 3 times a day for 2 weeks.

Two weeks after the treatment the patient reported a subjective decrease in symptoms and an objective reduction in the degree of conjunctival hyperemia (Image 1) and SPK (Image 2), especially at the conjunctival level in the left eye (Image 3), as well as a lower amount of mucin filaments less adherent to the cornea (Image 2). Although it refers to a burning sensation of 10 minutes duration after the administration of the treatment, this didn't prevent the patient from complying with the therapeutic guidelines.

EVALUATION OF HYDROCORTISONE
AS TREATMENT OF OCULAR
GRAFT-VERSUS-HOST DISEASE:
A CASE REPORT

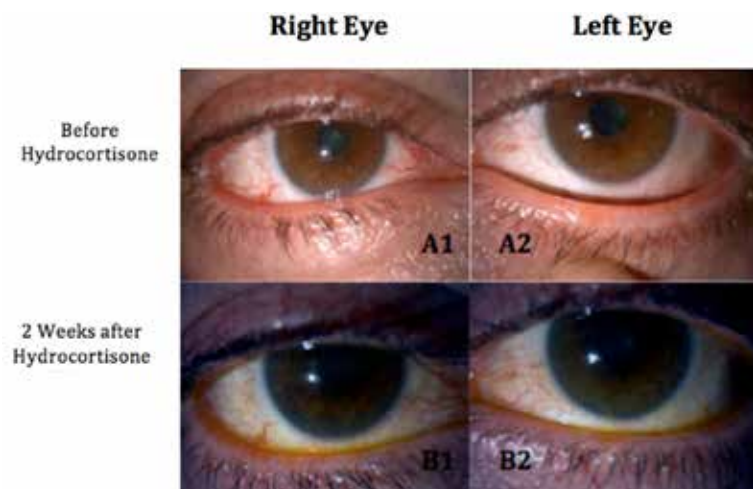

Figure 1: Degree of conjunctival hyperemia before and after treatment with hydrocortisone (A1-2) - Conjunctival hyperemia in basal stage; (B1-2) Conjunctival hyperemia had decreased 2 weeks after treatment with hydrocortisone

In the evaluation after four weeks of the start of the treatment, the patient reported photophobia, but the fluctuating vision symptoms had disappeared and the foreign body sensation had decreased.

Examination of the slit lamp showed telangiectasias of the free edge of the eyelid, a more irregular staining of the Marx line than was observed in the basal stage, as well as a disappearance of the pseudomembranes of the lower tarsus.

The conjunctival hyperemia decreased objectively, as well as the degree of staining with fluorescein and green lysine, reaching a grade II-III and I of the Oxford Scheme in the right and left eye respectively (Image 2 and 3). Disappearing all signs of filamentous keratitis.

On the other hand, no changes were observed in the Schirmer test or in the intraocular pressure with respect to the basal stage.

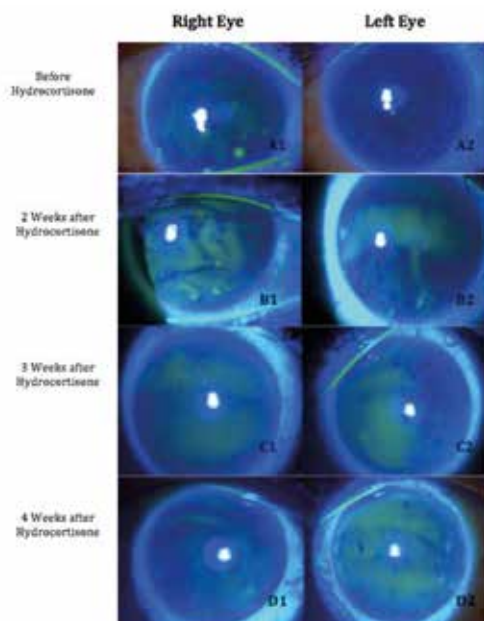


Figure 2: Fluorescein staining before and after treatment with hydrocortisone (A1-2) Fluorescein staining in basal stage, SPK grade III, filamentary keratitis ; (B1-2) Two weeks after the treatment there was a decrease in the number of filaments and their adhesion to the cornea, as well as the degree of fluorescein staining; (C1-2) Three weeks after the treatment we observed a SPK grade II-III and I in the right and left eye, and the filaments had disappeared; (D1-2) Four weeks later the SPK had been reduced to grade II-I in both eyes. after treatment with hydrocortisone

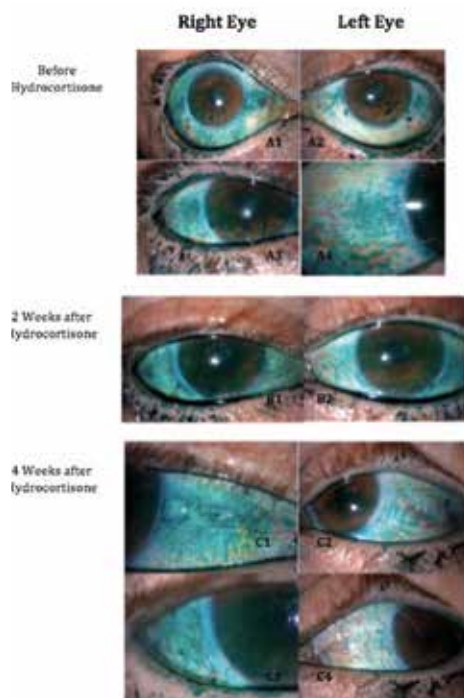


Figure 3: Green Lysine staining before and after treatment with hydrocortisone (A1-4) Green Lysine staining in basal stage, SPK grade III; (B1-2) Two weeks after the treatment there was a decrease in the degree of the staining, grade III in right eye, grade II in left eye; (C1-4) Four weeks later the SPK had been reduced to grade II-III and I in right and left eye respectively.

★ DISCUSSION ★

This clinical case of a male with a mild-moderate form of chronic GVHD demonstrates what many studies had previously corroborated, the efficacy of topical corticosteroids in the inflammatory control of the ocular surface in cases of ocular GVHD. Being therefore the drug of first choice in this pathology used in different concentrations and formats.

In our study it is appreciated that at the beginning of the treatment with corticoids the patient showed a significant reduction of the symptoms of dry eye, such as the sensation of foreign body and fluctuating vision, as well as a discreet decrease of the photophobia. But with the passage of the weeks the progression of the symptomatology stabilized maintaining its effect until the end of the study, without achieving an absolute control of the symptoms⁽⁴⁾.

On the other hand, it generated a significant improvement in the degree of staining of the SPK compared with the basal stage, both at the corneal and conjunctival levels. In addition to reducing filamentary keratitis and with all this the risk of major complications of the ocular surface, controlling the pathology before causing irreversible affliction⁽⁵⁾.

In this way, hydrocortisone is shown to reduce the symptoms associated with keratoconjunctivitis sicca of GVHD, as other corticosteroids such as methylprednisolone and immunosuppressants such as cyclosporine and tacrolimus previously demonstrated. All of them manage to improve the degree of fluorescein staining without producing significant changes in the

EVALUATION OF HYDROCORTISONE AS TREATMENT OF OCULAR GRAFT-VERSUS-HOST DISEASE: A CASE REPORT

Schirmer test during the follow-up as shown by the study by Qiu Y et al. Although other studies seem to show some increase in tear excretion^(4,5,6).

At the conclusion of the follow-up with hydrocortisone there were no significant changes in patient's intraocular pressure or other serious side effects.

Contrarily, methylprednisolone is a topical corticosteroid with a high degree of penetration into the anterior chamber, generating a significant increase in intraocular pressure at the end of many follow-up studies including the one by Abud TB et al. Unlike prednisolone, hydrocortisone has a low degree of systemic and ocular penetration and a biological half-life of less than 12 hours, presenting itself as an effective alternative with a low profile of adverse effects in comparison with other topical corticosteroids^(4,7).

Although if a certain burning sensation was shown to the topical use of hydrocortisone, this did not prevent compliance with the therapeutic guidelines, not showing differences with the tolerability of other drugs like cyclosporine or tacrolimus used for the same purpose, proving to be a safe and useful drug in the treatment of chronic ocular GVHD^(4,5,6).

Another advantage offered by this new topical medication is its monodose format, allowing to eliminate the preservatives present in the rest of topical corticosteroids of the market, and with it the associated risk of dry eye. In this way hydrocortisone can be considered as a drug with a low side effect profile and effective in the treatment of different inflammatory pathologies of the anterior surface of the eye⁽⁷⁾.

★ CONCLUSION ★

In conclusion, topical hydrocortisone in monodose proved to be an effective and safe drug in the treatment of chronic ocular GVHD symptoms, reducing the signs of dry eye and ocular inflammation. Offering the advantage of being the first topical corticosteroid to eliminate the preservatives and with it the associated risk of dry eye.

★ REFERENCES ★

1. Krachmer, J.A.Y.H. Cornea. (Third ed.).: Elsevier INC; 2011.
2. Sun YC, Chai X, Inamoto Y et al. Impact of Ocular Chronic Graft-versus-Host Disease on Quality of Life. *Biol Blood Marrow Transplant* 21 (2015) 1687-1691
3. Qiu Y, Hong J, Peng R. Manifestation of Clinical Categories of Ocular Graft-versus-Host Disease. *Journal of Ophthalmology*. 2018. 1-7.
4. Abud TB, Amparo F, Saboo US et al. A Clinical Trial comparing the Safety and Efficacy of Topical Tacrolimus versus Methylprednisolone in Ocular Graft-Versus-Host Disease. *Ophthalmology*. 2016;123(7): 1449-1457.
5. Pathak M, Diep PP, Lai X et al. Ocular findings and ocular graft-versus-host disease after allogeneic stem cell transplantation without total body irradiation. *Bone Marrow Transplantation*. 2018; 53: 863-872.
6. Wang Y, Ogawa Y, Dogru M et al. Ocular surface and tear functions after topical cyclosporine treatment in dry eye patients with chronic graft-versus-host disease. *Bone Marrow Transplantation* (2008) 41, 293-302.
7. Softacort technical sheet [Internet]. Agencia Española de Medicamentos y Productos Sanitarios (AEMPS) 2018. Recovered from: https://www.aemps.gob.es/cima/dohtml/ft/82398/FichaTecnica_82398.html



Mrs. Emilie GREENAN
Trinity College Medical School, Dublin – IRELAND

.....

A CASE OF REFRACTORY RECURRENT OCULAR GRAFT VERSUS HOST DISEASE

.....

★INTRODUCTION★

Allogenic haematological stem cell transplantation (HSCT) from related or unrelated HLA-matched donors is a well-established and potentially curative form of treatment for a wide range of benign and malignant haematological malignancies, as well as aplastic anaemia, severe immunosuppression, and some metabolic diseases such as mucopolysaccharidosis and lysosomal storage disorders⁽¹⁾. Since its introduction in 1957⁽²⁾, the number of HSCTs has continued to rise year on year with an estimated 25,000 undertaken annually worldwide. If current trends continue the number of unrelated HLA matched transplants is expected to double in the coming 5 years⁽³⁾. Improvements in infection prophylaxis, immunosuppression, myeloablative conditioning regimens, DNA based tissue typing and supportive care has expanded the indications for HSCT, increasing the treatment options available to older patients and overall enhancing patient outcomes^(4, 5). However despite such progress, the most common and serious complication of HSCT, graft versus host disease (GVHD) still affects between 25-70% of recipients and remains a major cause of non-relapse related patient morbidity and mortality^(6, 7).

Previously GVHD had been classified as either acute GVHD (aGVHD) or chronic GVHD (cGVHD) dependant on the time of presentation since HSCT, that being 100 days. This simple distinction failed to

appreciate the differences in the pathophysiology and clinical manifestations of the disease subtypes. As such the National Institute of Health (NIH) introduced a new benchmark for diagnosis, with reliance placed instead on clinical signs and symptoms⁽⁸⁾; acute disease is classified as⁽¹⁾ classical aGVHD with skin (maculopapular rash, bullous lesions and desquamation), GI (nausea, vomiting, anorexia, diarrhoea and ileus) and hepatic (cholestasis) involvement occurring within the first 100 days post transplantation or⁽²⁾ persistent, recurrent or late aGVHD which presents with the above symptoms 100 days post transplantation. The latter is often associated with a tapering or discontinuation of the immunosuppressive regimen⁽⁹⁾. cGVHD is often preceded by a history of aGVHD and can be restricted to a single organ or can affect several organs throughout the body⁽¹⁰⁾. Subtypes include⁽¹⁾ classical cGVHD, without features of aGVHD, and⁽²⁾ overlap syndrome, in which the patient develops symptoms of both acute and chronic GVHD concurrently.

The pathophysiology of GVHD is multifactorial and complex in nature. aGVHD is an exaggerated 'cytokine storm'⁽¹¹⁾. It involves an acute inflammatory response when the donor T lymphocytes responding appropriately to the foreign recipient's environment after the HSCT. However, the inflammatory network is excessively stimulated by the recipient's conditioning regime resulting in the over production of activating signals. This leads to the generation, proliferation, differentiation and migration of donor immune cells⁽³⁾. Clinically it manifests in a similar fashion to Steven Johnson Syndrome. In contrast, the underlying pathogenesis of cGVHD is less well understood limited partly because it is poorly reproduced in animal models. It has been suggested that it is caused by the dysregulated recovery of the recipient's immune system leading to inadequate thymus function and thus failed deletion of autoreactive T cell clones. Clinical features are akin to that of chronic immune mediated inflammatory disorders such as Sjogrens Syndrome⁽¹²⁾.

Ocular manifestations of GVHD develop in 40-60% of patients after allogeneic-SCT and can lead to severe ocular surface complications^(9,13). Studies have shown that patients rarely regain a normal tear film in the years following HSCT^(14, 15). The disease can affect all parts of the eye and its associated adnexa, although keratoconjunctivitis sicca is the most common finding and is present in 90% of cases. Other ocular signs and symptoms include conjunctival hyperaemia, pseudomembranous conjunctivitis dysfunction of the lacrimal and meibomian glands, corneal ulceration, scarring and perforation^(16,17). The posterior segment is rarely affected although mention of retinal and choroidal lesions have been previously made in the literature⁽¹⁸⁾. Treatment options for ocular GVHD include topical agents to provide lubrication directly to the ocular surface, as well as both systemic and topical agents to suppress T cell over activation and to target the dysregulated inflammatory response.

Despite recent progress in the understanding of the pathogenesis of GVHD and expanding treatment options, either a targeted treatment regime or an effective preventative treatment option has yet to be established. Herein, this is illustrated with the following case of refractory overlap ocular graft versus host disease, and its associated complications as treated over a ten-month period.

★ CASE PRESENTATION ★

A 24-year-old woman was referred to our service with a 2-month history of decreased visual acuity and symptoms of keratoconjunctivitis sicca. She had a history of diffuse large B cell lymphoma, stage IVb having spread to both her bone marrow and central nervous system. Seven months previously this had been treated with an allogeneic HSCT from a sibling donor after chemotherapeutic conditioning. She had developed aGVHD with skin, gastric and mild ocular involvement (grade III) and this had been effectively treated with a tapered regime of systemic steroids. She then developed ocular cGVHD which was of moderate intensity but well managed with topical corticosteroids and lubricants until she developed a urinary tract infection. This rapidly triggered acute left hip pain with associated swelling and reduced function (presumed to be reactive arthritis) along with severe oral and ocular inflammation. Treatment with systemic steroids resolved her joint and oral symptoms. However, her ocular inflammation continued relentlessly and she was referred to the ocular immunology and anterior segment service for further management.

By this time, her visual acuity had reduced to 6/30 in the RE and 6/12 in the left best corrected. This was attributed to bilateral corneal epithelial defects measuring 6 mm x 2.5mm in the right and 2.5 mm x 2.5 mm in the left, along with severe bilateral pseudomembranous conjunctivitis, and early symblepharon formation (Fig 1). Her treatment to this point had consisted of a combination of intravenous methylprednisolone, followed by high dose oral and topical steroids, chloramphenicol eye drops and an intensive regime of lubrication. This had provided little to no relief. MRI brain and orbits were normal, and conjunctival swabs produced no growth. A prokera ring was inserted into the right eye to assist with healing of the persistent epithelial defect. The patient was prescribed g-maxidex 2 hourly, g-ofloxacin 2 hourly, g-timolol OD and hourly lubrication with preservative free eye drops and gels nocte for both eyes. Systemically she was commenced on prednisolone 40mg, cyclosporine A (CsA) 50mg BD for continued immunological and inflammatory suppression, along with prophylactic anti-viral and anti-fungal cover with posaconazole, valacyclovir and doxycycline 100mg OD to aid re-epithelisation and reduce ocular surface inflammation.

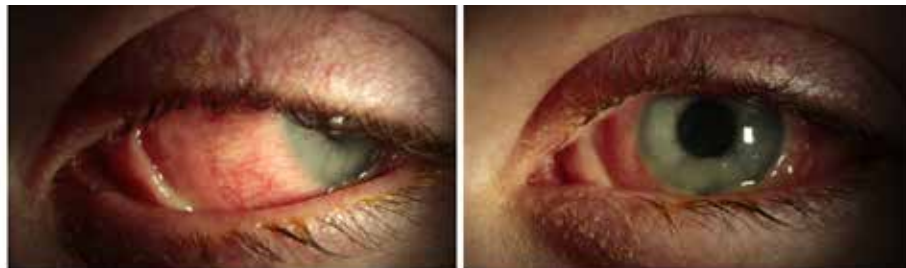

Figure 1: Anterior segment photographs demonstrating periocular erythema, diffuse hyperaemia and oedema of the bulbar conjunctival, with pseudomembranous conjunctivitis visible nasally. Bilateral epithelial defects with mucous secretions, and early symblepharon formation.

The prokera ring was poorly tolerated and was removed a week after insertion. Her condition continued to deteriorate and a month later she still showed a bilateral mucopurulent discharge with marked conjunctival chemosis and a total corneal epithelial defect in the right eye (Fig 2). Conjunctival swabs were taken for HSV, VZV, CMV, PCR, culture and sensitivity, gram staining as well as a scraping of the right cornea. All results were negative. A conjunctival biopsy was taken and was noted to contain CD3 cells, T lymphocytes, non-specific inflammation, and was negative for B lymphocytes and malignancy.

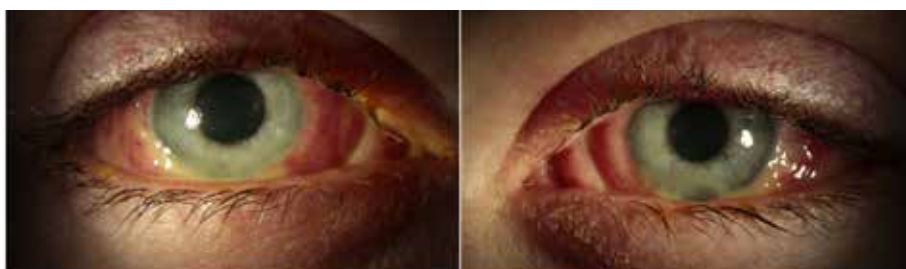

Figure 2: Right eye shown above with a total epithelial defect. Marked conjunctival chemosis and early cicatricial changes can be seen in both eyes.

Treatment was altered as follows: Topically, g-ofloxacin was changed to chloramphenicol minims QDS, autologous serum drops 2 hourly and oc-tacrolimus 0.03% BD were added, dexamethason 0,1% was switched to dexamethasone preservative-free 0,1% QDS, preservative-free nocte along with continued use of g-timolol and an intensive lubrication regime as before. Systemically mycopholate mofetil (MMF) 1g BD was commenced, along with extracorporeal photophoresis (ECP), whilst continuing CsA, doxycycline 100mg OD, and 30mg oral prednisolone daily. Surgically, the patient underwent bilateral amniotic transplants, and right eye lower lid everting sutures to correct an early cicatricial entropion.

Over the following 4 weeks the patient's conjunctiva became less inflamed. However treatment failed to improve the corneal epithelial defects and a mucopurulent discharge persisted. Inflammatory changes continued with symblepharon formation, trichiasis and haze of the right cornea (Fig 3). Systemically, her serum C reactive protein (CRP) was raised and it was felt that the autologous serum eye drops might be exacerbating her condition so they were replaced with allogeneic serum drops. In an attempt to resolve the epithelial defects, a repeat bilateral amniotic membrane transplant was performed and combined with a lateral tarsorrhaphy in the right eye. G-cyclosporine (Ikervis) nocte was added into the regime along with g-acetylcysteine 5% QDS, and g-chloramphenicol was changed to g-moxifloxacin QDS. Hourly preservative free lubricating eye drops and gels at night, along with g-timolol and g-dexafree were all continued as before. Systemically the patient was commenced on immunosuppressive infliximab infusions, and continued with ECP, CsA, MMF and oral prednisolone 20mg OD.

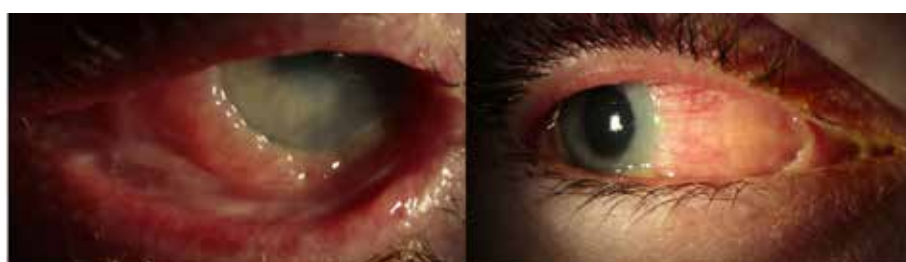

Figure 3: Marked chemosis, in the right more so than the left, and corneal haziness. Symblepharon formation with trichiasis is also noted, mainly affecting the right eye.

A CASE OF REFRACTORY RECURRENT OCULAR GRAFT VERSUS HOST DISEASE

The amniotic transplants remained in place over the following two months. But despite this the inflammatory changes continued. Adverse side effects from prolonged usage of high dose steroids began to develop and the patient started to show signs and symptoms of Cushing's syndrome. Systemically, empiric erythromycin was commenced to help reduce the conjunctival inflammation and discharge, but was not tolerated and stopped soon after. After a poor response to infliximab infusions over an 8-week period, she was commenced on monthly cyclophosphamide IV infusions.

Six months since initially presentation, the patient's ocular condition was deteriorating and inflammatory changes continued in an unyielding fashion (Fig 4). CT orbits and sinuses were negative. Further ocular samples were sent; conjunctival biopsy for 16s and 18s RNA were negative, as was conjunctival culture and sensitivity. CMV PCR from the conjunctiva was positive and corneal scrapings floridly grew *Corynebacterium*, which was shown to be sensitive to vancomycin. Treatment was altered accordingly. A three-week course of valganciclovir was commenced along with oral augmentin. Topically g-vancomycin was prescribed hourly. G-cyclosporine, and dexamethason 0,1% preservative-free were stopped on a trial basis. Allogenic serum drops, g-timolol and lubrication was continued as before. Subsequently, she received a once off dose of intravenous methylprednisolone 1g followed by a high dose oral prednisolone taper.

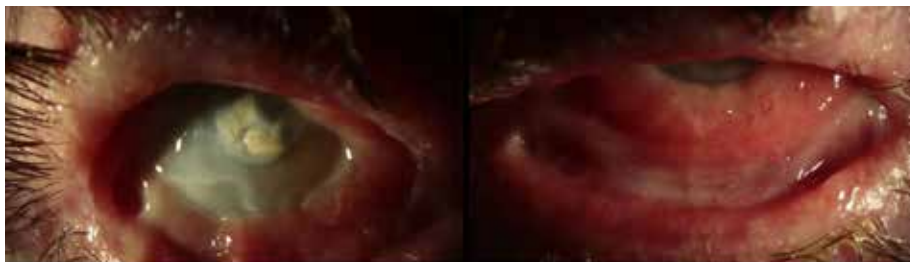


Figure 4: There is conjunctival chemosis and fibrosis with bilateral symblepharon formation due to subtarsal fibrosis. Cicatricial occlusion of the lower punctae has led to outflow obstruction. Right eye shows rapid deterioration, with significant corneal hazing and sloughing, preventing visualisation of the anterior chamber and its structure.

A moderate benefit from this regime of systemic steroid therapy combined with cyclophosphamide and topical vancomycin was achieved over the following month. The trial without dexamethason 0,1%, CsA and serum drops had led to worsening of inflammation indicating the benefits of topical corticosteroids in particular. Chemosis worsened, and visual acuity dropped to hand movements in the right and 3/60 best corrected in the left. Bilateral conjunctival discharge returned and conjunctival cicatrization continued to develop with ankyloblepharon formation. The right corneal surface began to thin with a central epithelial defect (Fig 5). Repeat corneal scrapings this time yielded a rich growth of mycoplasma sensitive to moxifloxacin, which was commenced on an hourly basis for 2 days initially following which it was tapered. The discharge resolved following topical moxifloxacin treatment, although other signs of conjunctival inflammation persisted. G-azithromycin was added BD for 3 days along with a 2-week course of oral clindamycin. Systemic immunosuppression was changed to the anti-B cell monoclonal antibody rituximab, the JAK 1/2 inhibitor ruxolitinib and oral prednisolone which was tapered to 5mg daily along with continued use of CsA.

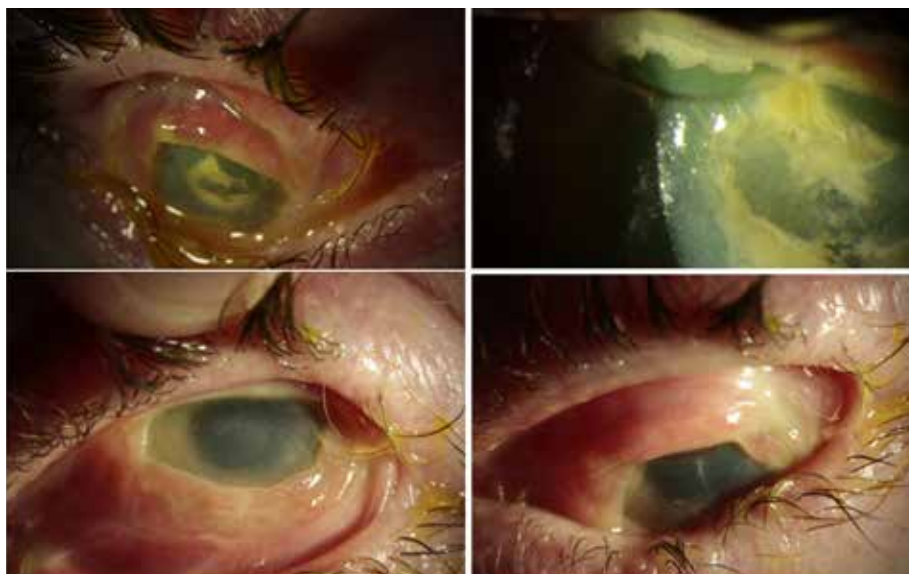


Figure 5: Right eye shows a central epithelial defect and severe corneal thinning with risk of perforation. Below are two pictures of the left eye showing chronic fibrotic changes of the anterior surface as well as corneal surface haze beginning to develop.

The combination of intensive topical corticosteroids, topical antibiotics and systemic rituximab and ruxitinib yielded a significant improvement in the conjunctival inflammation and an improvement in her visual acuity to 6/24 left eye. However, 8 weeks later the right eye developed a persistent corneal ulcer measuring 1.5 x 3mm, stromal thinning and a descemetocoele. Conjunctival chemosis returned in both eyes along with significant pain. Her visual acuity was reduced to HM right eye and CF left eye. A multi-layered amniotic membrane graft along with a central tarsorrhaphy to give 80% lid closure was performed in the right eye under general anaesthesia. In an effort to combat conjunctival chemosis, sub conjunctival dexamethasone was given at the same time under anaesthesia. Rituximab was re-commenced with weekly infusions for 4 weeks.

After ten months of unremitting ocular GVHD-related inflammation the patient's right ocular surface is improving with healing of the corneal ulcer and stabilisation of the descemetocoele and the conjunctival inflammation has finally resolved. However, the visual acuity has reduced to hand movements in the right eye and 2/60 in the left eye due to corneal opacification (Fig 6). Marked restriction of eye movement due to conjunctival cicatrisation is present and signs of severe aqueous deficient dry eye disease persist. She remains on g-moxifloxacin QDS, g-pred minims QDS, allogenic serum drops QDS, and intensive lubrication, all to both eyes. Systemic immunosuppressive therapy consists of hydrocortisone 30mg OD, tacrolimus 1.5mg BD and ruxolitinib 10mg BD.

A CASE OF REFRACTORY RECURRENT
OCULAR GRAFT VERSUS HOST DISEASE

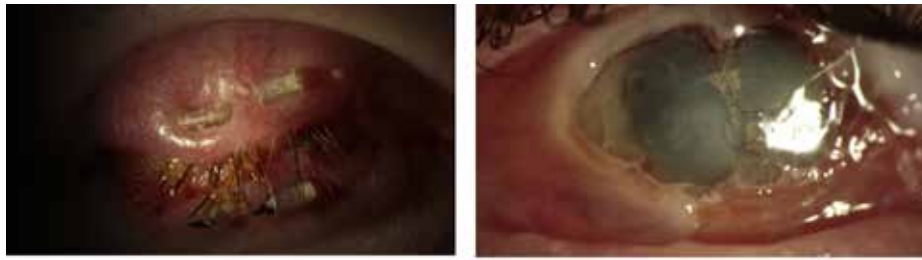


Figure 6: The right eye has undergone a layered amniotic membrane transplant in conjunction with a generous lateral tarsorrhaphy in an effort to prevent perforation. The left corneal surface is hazy, due to surface fibrosis and calcification.

See table 1 for a summary of treatment.

Topical treatment	Systemic treatment	Surgical treatment
Lubrication: <ul style="list-style-type: none"> ❖ Preservative free drops ❖ Preservative free ointments ❖ (Punctae occlusion-scarred over) 	Steroids: <ul style="list-style-type: none"> ❖ IV methylprednisolone ❖ High dose, pulsed oral prednisolone 	Amniotic membrane transplants OU (multiple)
Antibiotics: <ul style="list-style-type: none"> ❖ Chloramphenicol ❖ Ofloxacin ❖ Moxifloxacin ❖ Vancomycin ❖ Azithromycin 	Antibiotics: <ul style="list-style-type: none"> ❖ Doxycycline ❖ Erythromycin ❖ Co-amoxiclav 	Right lower lid everting sutures
Serum drops: <ul style="list-style-type: none"> ❖ Autologous ❖ Allogenic 	Anti-viral: <ul style="list-style-type: none"> ❖ Valacyclovir 	Lateral tarsorrhaphy OU, with repeat central tarsorrhaphy on the right eye
Anti-inflammatory <ul style="list-style-type: none"> ❖ Pred minims ❖ Dexafree ❖ Cyclosporine A ❖ Tacrolimus 	Immunosuppression: <ul style="list-style-type: none"> ❖ Cyclosporine A ❖ Tacrolimus ❖ Infliximab ❖ Rituximab ❖ Ruxolitinib 	
Intraocular pressure control: <ul style="list-style-type: none"> ❖ Timolol 	Extracorporeal photophoresis	
Subconjunctival dexamethasone		
Prokera ring		

Table 1: Summary of treatment

★ DISCUSSION ★

Ocular GVHD is a complex condition that can be extremely difficult to treat and manage, as demonstrated by the case report described above.

Topical therapy is the mainstay of treatment aimed at both the symptoms of dry eye disease and the underlying inflammatory component. It should revolve around four main principles, as suggested by the NIH consensus guidelines in 2006⁽¹⁹⁾; (1) lubrication, (2) tear preservation and evaporation prevention⁽³⁾ decreased ocular surface inflammation and⁽⁴⁾ ocular surface epithelial support. Preservative free medication is course preferred as phosphate containing eye drops can damage the ocular surface epithelia as well as promote corneal calcification in the presence of corneal erosions and ulcers⁽²⁰⁾. Surgical and systemic treatment should be initiated only when topical therapy alone cannot control ocular symptoms and ideally management should be multidisciplinary with active input from both ophthalmology and haematology teams.

Lubrication can be achieved with the frequent use of artificial tears, minimising epithelial defects⁽²¹⁾, decreasing discomfort and improving visual function^(22, 23) as well as diluting inflammatory mediators. Viscous ointments are also useful especially when used at bedtime. In previous studies, no difference in efficacy was observed between specific lubrication products or brands⁽²⁴⁾. Although our patient was unable to tolerate a bandage contact lens, they may also be used to stabilise tear film and to restore normal cellular turnover⁽²⁵⁾. Acetylcysteine eye drops have mucolytic and anti-collagenase properties, but as of yet, their efficacy has not been proven in clinical trials. The use of oral muscarinic agonists, such as pilocarpine have been shown to have some benefit in patients with dry eye disease associated with Sjogrens Syndrome⁽²⁶⁾, however their use is associated with undesirable side effects and contraindications, and as such were not used.

Tear drainage can be reduced temporarily with the use of punctal plugs or permanently with surgical cauterisation. Our patient's puncta fibrosed over due to the extensive inflammatory component of her ocular disease. Control of tear evaporation can also be aided with treatment to improve meibomian gland dysfunction. Topical eye drops, such as g-azithromycin, as well as oral doxycycline were used to challenge eyelid inflammation, treat possible bacterial infection and to improve glandular secretion and the tear lipid layer⁽²⁷⁾.

Intreating ocular GVHD is vital to address not only ocular dryness, but also the related inflammatory component underpinning the disease. Topical steroids promote lymphocyte apoptosis and suppress cell mediated inflammation⁽²⁸⁾. However, their long-term use is associated with unwanted side effects such as ocular hypertension, glaucoma, cataract formation, corneal thinning and increased susceptibility to infection. Topical cyclosporine is can be used alone or in conjunction with corticosteroids, and acts as a steroid sparing agent. CsA suppresses T cells, reducing inflammation, apoptosis and increases the

number of conjunctival goblet cells and its use has been shown to be effective in various forms of dry eye disease, including cGVHD^(29,30). Topical tacrolimus has a similar mechanism of action to that of CsA, although evidence for its use in the treatment of ocular GVHD is limited to a single reported case⁽²¹⁾. Unfortunately, our patient's inflammation was never controlled sufficiently to allow here to be independent of topical steroids.

Epithelial cell support can be achieved through the use autologous or allogeneic serum eye drops. They are rich in vitamin A, growth factors and fibronectin, are valuable in the treatment of epithelial defects⁽³¹⁾ and support the integrity of the cornea and conjunctival surfaces⁽³²⁾. Amniotic membrane transplants were used on multiple occasions to treat the patient's refractory epithelial defects and corneal ulceration, and in order to prevent further thinning and perforation^(33,34), along with surgical closure of her eyelids.

Corticosteroids, with their potent anti-lymphocyte and anti-inflammatory effect are the gold standard for the treatment for both aGVHD and cGVH, and results in the complete remission in nearly half of all affected patients⁽³⁵⁾. Cyclosporine or tacrolimus can be used in conjunction with corticosteroids, and similar to topical treatment allows for the reduction of steroid dosage and thus reducing unwanted side effect profiles with their long-term use⁽³⁶⁾. ECP has been shown to be useful as a second line agent in steroid resistant cGVHD or in patients with steroid intolerance⁽³⁷⁾. It has been shown to be of particular use in patients with mucous membranous disease and ocular GVHD⁽³⁸⁾. ECP induces T cell apoptosis, monocyte differentiation and T cell regulation. Our patient received further immunosuppression with the use of TNF blocking medications, suppressing APC production as well as inhibition of tyrosine kinase with JAK 1/2 inhibitors. The combination of rituximab, ruxolitinib, low dose oral prednisolone and intensive topical corticosteroids, preservative-free lubrication and antibiotic therapy was eventually successful at achieving remission from the inflammation. Long term topical therapy will be required to manage the severe aqueous tear deficiency that persists.

★ CONCLUSION ★

Ocular GVHD is a common complication following HSCT, and the condition has long lasting implications for those patients affected. The above case report has exasperated all known treatment options, and is a demonstration of the catastrophic results of uncontrolled ocular inflammation when this condition is at its worst. It highlights the need for further research into the pathogenesis of ocular GVHD, in the hope of identifying diagnostic and therapeutic biomarkers and more effective and targeted treatments.

★ REFERENCES ★

1. Malatack JJ, Consolini DM, Bayever E. The status of hematopoietic stem cell transplantation in lysosomal storage disease. *Pediatric neurology*. 2003;29(5):391-403.
2. Henig I, Zuckerman T. Hematopoietic Stem Cell Transplantation—50 Years of Evolution and Future Perspectives. *Rambam Maimonides Medical Journal*. 2014;5(4):e0028.
3. Ferrara JL, Levine JE, Reddy P, Holler E. Graft-versus-host disease. *Lancet (London, England)*. 2009;373(9674):1550-61.
4. Welniak LA, Blazar BR, Murphy WJ. Immunobiology of allogeneic hematopoietic stem cell transplantation. *Annual review of immunology*. 2007;25:139-70.
5. Appelbaum FR. Haematopoietic cell transplantation as immunotherapy. *Nature*. 2001;411(6835):385-9.
6. Dean RM, Bishop MR. Graft-versus-host disease: emerging concepts in prevention and therapy. *Current hematology reports*. 2003;2(4):287-94.
7. Lee SJ, Klein JP, Barrett AJ, Ringden O, Antin JH, Cahn J-Y, et al. Severity of chronic graft-versus-host disease: association with treatment-related mortality and relapse. *Blood*. 2002;100(2):406-14.
8. Filipovich AH, Weisdorf D, Pavletic S, Socie G, Wingard JR, Lee SJ, et al. National Institutes of Health consensus development project on criteria for clinical trials in chronic graft-versus-host disease: I. Diagnosis and staging working group report. *Biology of blood and marrow transplantation : journal of the American Society for Blood and Marrow Transplantation*. 2005;11(12):945-56.
9. Shikari H, Antin JH, Dana R. Ocular graft-versus-host disease: a review. *Survey of ophthalmology*. 2013;58(3):233-51.
10. Riemens A, te Boome L, Imhof S, Kuball J, Rothova A. Current insights into ocular graft-versus-host disease. *Current opinion in ophthalmology*. 2010;21(6):485-94.
11. Antin JH, Ferrara JL. Cytokine dysregulation and acute graft-versus-host disease. *Blood*. 1992;80(12):2964-8.
12. Gratwohl AA, Moutsopoulos HM, Chused TM, Akizuki M, Wolf RO, Sweet JB, et al. Sjogren-type syndrome after allogeneic bone-marrow transplantation. *Annals of internal medicine*. 1977;87(6):703-6.
13. Uchino M, Ogawa Y, Uchino Y, Mori T, Okamoto S, Tsubota K. Comparison of stem cell sources in the severity of dry eye after allogeneic haematopoietic stem cell transplantation. *Br J Ophthalmol*. 2012;96(1):34-7.
14. Anderson NG, Regillo C. Ocular manifestations of graft versus host disease. *Current opinion in ophthalmology*. 2004;15(6):503-7.
15. Hirst LW, Jabs DA, Tutschka PJ, Green WR, Santos GW. The eye in bone marrow transplantation. I. Clinical study. *Archives of ophthalmology (Chicago, Ill : 1960)*. 1983;101(4):580-4.
16. Abud TB, Amparo F, Saboo US, Di Zazzo A, Dohlman TH, Ciolino JB, et al. A Clinical Trial Comparing the Safety and Efficacy of Topical Tacrolimus versus Methylprednisolone in Ocular Graft-versus-Host Disease. *Ophthalmology*. 2016;123(7):1449-57.
17. Nassar A, Tabbara KF, Aljurf M. Ocular manifestations of graft-versus-host disease. *Saudi Journal of Ophthalmology*. 2013;27(3):215-22.
18. Hessen M, Akpek EK. Ocular graft-versus-host disease. *Current Opinion in Allergy and Clinical Immunology*. 2012;12(5):540-7.
19. Wolff D, Bertz H, Greinix H, Lawitschka A, Halter J, Holler E. The Treatment of Chronic Graft-Versus-Host Disease: Consensus Recommendations of Experts From Germany, Austria, and Switzerland. *Deutsches Arzteblatt International*. 2011;108(43):732-40.
20. Bernauer W, Thiel MA, Kurrer M, Heiligenhaus A, Rentsch KM, Schmitt A, et al. Corneal calcification following intensified treatment with sodium hyaluronate artificial tears. *The British journal of ophthalmology*. 2006;90(3):285-8.
21. Tam PM, Young AL, Cheng LL, Lam PT. Topical 0.03% tacrolimus ointment in the management of ocular surface inflammation in chronic GVHD. *Bone marrow transplantation*. 2010;45(5):957-8.
22. American Academy of Ophthalmology Cornea/External Disease Panel, Preferred Practice Patterns Committee. Dry eye syndrome. San Francisco, CA. American Academy of Ophthalmology (AAO). 2003.
23. Javadi M-A, Feizi S. Dry Eye Syndrome. *Journal of Ophthalmic & Vision Research*. 2011;6(3):192-8.
24. Doughty MJ, Glavin S. Efficacy of different dry eye treatments with artificial tears or ocular lubricants: a systematic review. *Ophthalmic & physiological optics : the journal of the British College of Ophthalmic Opticians (Optometrists)*. 2009;29(6):573-83.
25. Inamoto Y, Sun Y-C, Flowers MED, Carpenter PA, Martin PJ, Li P, et al. Bandage soft contact lenses for ocular graft-versus-host disease. *Biology of blood and marrow transplantation : journal of the American Society for Blood and Marrow Transplantation*. 2015;21(11):2002-7.
26. Pappas AS, Sherrer YS, Charney M, Golden HE, Medsger TA, Jr., Walsh BT, et al. Successful Treatment of Dry Mouth and Dry Eye Symptoms in Sjogren's Syndrome Patients With Oral Pilocarpine: A Randomized, Placebo-Controlled, Dose-Adjustment Study. *Journal of clinical rheumatology : practical reports on rheumatic & musculoskeletal diseases*. 2004;10(4):169-77.
27. Frucht-Pery J, Sagi E, Hemo I, Ever-Hadani P. Efficacy of doxycycline and tetracycline in ocular rosacea. *American journal of ophthalmology*. 1993;116(1):88-92.
28. Pflugfelder SC. Antiinflammatory therapy for dry eye. *American journal of ophthalmology*. 2004;137(2):337-42.
29. SaLL K, Stevenson OD, Mundorf TK, Reis BL. Two multicenter, randomized studies of the efficacy and safety of cyclosporine ophthalmic emulsion in moderate to severe dry eye disease. *CsA Phase 3 Study Group. Ophthalmology*. 2000;107(4):631-9.

30. Lelli GJ, Jr., Musch DC, Gupta A, Farjo QA, Nairus TM, Mian SI. Ophthalmic cyclosporine use in ocular GVHD. *Cornea*. 2006;25(6):635-8.
31. Matsumoto Y, Dogru M, Goto E, Ohashi Y, Kojima T, Ishida R, et al. Autologous serum application in the treatment of neurotrophic keratopathy. *Ophthalmology*. 2004;111(6):1115-20.
32. Chiang CC, Lin JM, Chen WL, Tsai YY. Allogeneic serum eye drops for the treatment of severe dry eye in patients with chronic graft-versus-host disease. *Cornea*. 2007;26(7):861-3.
33. Peris-Martinez C, Menezo JL, Diaz-Llopis M, Avino-Martinez JA, Navea-Tejerina A, Risueno-Reguillo P. Multilayer amniotic membrane transplantation in severe ocular graft versus host disease. *European journal of ophthalmology*. 2001;11(2):183-6.
34. Dua HS, Gomes JA, King AJ, Maharajan VS. The amniotic membrane in ophthalmology. *Survey of ophthalmology*. 2004;49(1):51-77.
35. MacMillan ML, Weisdorf DJ, Wagner JE, DeFor TE, Burns LJ, Ramsay NK, et al. Response of 443 patients to steroids as primary therapy for acute graft-versus-host disease: comparison of grading systems. *Biol Blood Marrow Transplant*. 2002;8(7):387-94.
36. Koc S, Leisenring W, Flowers ME, Anasetti C, Deeg HJ, Nash RA, et al. Therapy for chronic graft-versus-host disease: a randomized trial comparing cyclosporine plus prednisone versus prednisone alone. *Blood*. 2002;100(1):48-51.
37. Greinix HT, Knobler RM, Worel N, Schneider B, Schneeberger A, Hoecker P, et al. The effect of intensified extracorporeal photochemotherapy on long-term survival in patients with severe acute graft-versus-host disease. *Haematologica*. 2006;91(3):405-8.
38. Couriel D, Hosing C, Saliba R, Shpall EJ, Andelini P, Popat U, et al. Extracorporeal photopheresis for acute and chronic graft-versus-host disease: Does it work? *Biology of Blood and Marrow Transplantation*. 2006;12(SUPPL. 2):37-40.



Dr. Ranko GVOZDENOVIC

Institute of Ophthalmology, Clinical centre of Serbia, Faculty of Medicine, Belgrade - SERBIA

.....

MASQUERADING CORNEAL GRAFT REJECTION: MANAGEMENT HYDROPS IN BILATERAL CORNEAL GRAFT FOLLOWING

.....

★ INTRODUCTION ★

Keratoconus is a degenerative disease of the cornea, with onset generally at puberty. Approximately 20% of cases are complicated by the formation of a corneal scar and can be treated by lamellar or penetrating keratoplasty (PK). Its incidence is reported to be about 1/2000 in general population¹. Changes in organization of corneal collagen structure and intercellular matrix, and apoptosis of keratocytes of central or paracentral anterior stroma and the Bowman layer, are documented in the literature. These changes make the corneal tissue weak and represent the cause of ectasia and complications in keratoconus^{2,3}. One of the complications of advanced keratoconus is acute hydrops. Patients with hydrops suffer from acute visual loss with pain and photophobia. Conjunctival hyperemia and diffuse corneal edema with intrastromal cystic spaces are visible as clinical presentation. Rupture of the endothelial layer and abruption of Descemet's membrane allow aqueous to enter the stroma and produce marked stromal edema. Corneal edema may last weeks to months and

gradual improvement is usually associated with reduction in pain and redness. Corneal scar is a late complication of acute hydrops⁴.

Floppy eyelid syndrome (FES) is characterized by the easy eversion of the upper eyelid which occurs spontaneously during sleep, causing the exposure of the eye surface and chronic papillary conjunctivitis. Pathogenesis of FES has not been totally defined yet: it is more frequent in male patients and it is associated with disorders such as obesity, obstructive sleep apnea, keratoconus, high blood pressure and diabetes⁵.

Acute hydrops, especially bilateral, after corneal transplantation is rare, because corneal graft is usually taken from a normal eye and extension of hydrops from recipient tissue to donor cornea is restricted by host-donor interface. We present a case of bilateral acute hydrops after PK in a keratoconic patient, who also suffers from obesity and FES.

★ CASE PRESENTATION ★

A 70-year-old man, diagnosed with bilateral keratoconus at 15 years old, presented to us with acute visual loss, pain, redness, extreme photophobia and blepharospasm of both eyes. He had undergone PK for the right eye 35 years ago, and of the left eye 34 years ago. During these years, he had no problem with his operated eyes, no history of graft rejection and he did not use any topical or systemic medications. In the last few years his visual acuity has been minimally reduced with the onset of the initial nuclear cataract. One month before coming to our clinic, his problem had suddenly started, first on left than on the right eye, involving both eyes in a period of 7 days. At presentation, best corrected visual acuity (BCVA) of the both eyes was counting finger at 1 m. On slitlamp examination both eyes showed diffuse conjunctival congestion with severe corneal epithelial and stromal edema that involved inferior part of the recipient cornea and a large part of the donor cornea. Also, there was superficial graft vascularization on the right eye on 12h. There were no keratic precipitates. Because of severe and diffuse corneal stromal edema (central corneal thickness was 725 μ m right and 710 μ m left eye), it was not possible to evaluate anterior chamber in details (Figure 1 and Figure 2).

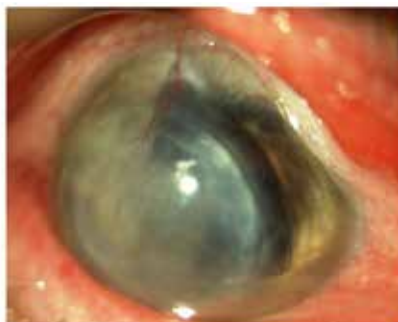

Figure 1: right eye-first visit

**MASQUERADING CORNEAL GRAFT REJECTION :
MANAGEMENT HYDROPS IN BILATERAL
CORNEAL GRAFT FOLLOWING**

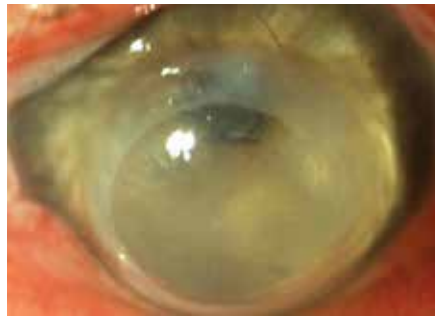

Figure 2: left eye-first visit

Intraocular pressure was 14 mmHg in the right eye and 15 mmHg in the left eye. The patient also had FES(Figure 3), and obesity.

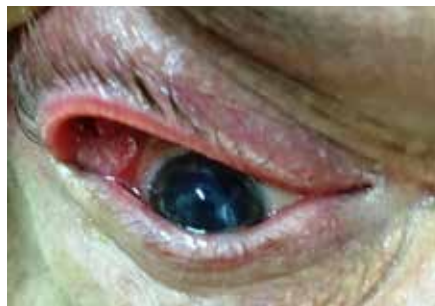

Figure 3: sign of Floppy eyelid syndrome

The patient is treating arterial hypertension for the past twenty years, and has a coronary bypass operation. Patient was prescribed Prednisolone acetate 1% ophthalmic suspension eye drops 8 times a day, and every 5 minutes during the first hour after waking up. 6 months later after detailed monitoring and maintenance and gradual reduction of corticosteroid therapy, no significant improvement in the clinical picture and visual acuity was achieved. A small part of the peripheral corneal graft of the both eye was cleared, but central part remain the same, so we decided to analyze grafts by using the module for anterior segment of optical coherent tomography (ASOCT). ASOCT showed a diffuse separation of the Descemet's membrane on almost the whole graft surface, with a mean central pachymetry that corresponded to the results 6 months ago, upon admission to our clinic. (Figure 4 and Figure 5).

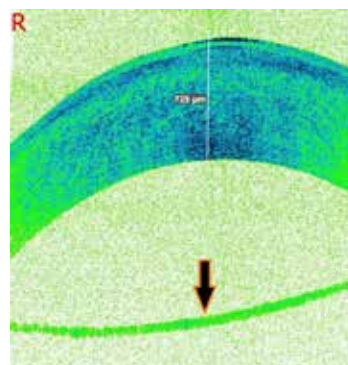


Figure 4: ASOCT- right eye-central graft thickness black arrow showing detachment of Descemet's membrane




Figure 5: ASOCT- left eye-black arrow showing detachment of Descemet's membrane almost to the border of graft-host junction

The patient showed symptoms of photophobia and blepharospasm all the time, which even increased partly over time. Based on the length of follow-up and clinical findings, it was decided that the patient should be re-treated with KPP at the left eye first and then 3 months later on the right eye. One month after re-grafting the left eye, visual acuity on that eye was 20/30 with correction, photophobia and blepharospasm were minimal, and patient was much better (Figure 6 and Figure 7).

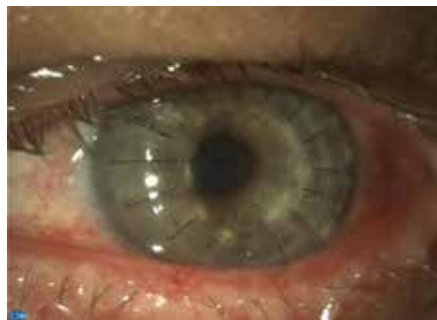

Figure 6: left eye one month after re-grafting

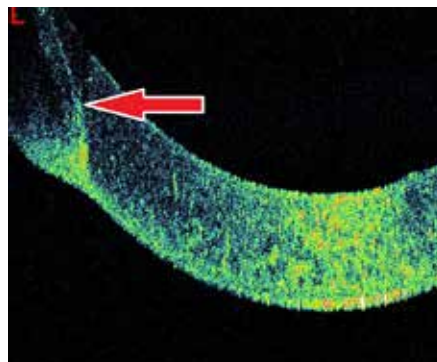


Figure 7: ASOCT- left eye- one month after re-grafting Red arrow showing host-donor junction

★ DISCUSSION ★

Keratoconus is the most common corneal disorder that is characterized by ectasia. Due to scar formation after corneal acute hydrops and poor contact lens tolerance, about 10% to 20% of patients need corneal transplantation.¹ In spite of 5 year survival rate of 93% to 97% for corneal graft in these patients,^{6,7} there is a risk of graft rejection especially endothelial one. Topical steroids and hypertonic sodium chloride eye drop or ointment can be effective for corneal hydrops. Most of them last several months and finally leave significant and then eventually need corneal transplantation. Sometimes, corneal scar is out of the visual axis and by flattening the corneal surface makes contact lens wearing more convenient.^{8,9} In this paper we introduced a keratoconic patient that had undergone corneal transplantation about 35 years ago and suffered from acute VA reduction secondary to acute hydrops on corneal graft. ASOCT confirmed the detachment of Descemet's membrane from the deep stroma on both eyes six months after the initial severe acute hydrops. Since the patient was referred to us after a while, some chronic changes including vascularization of the cornea, areas of stromal fibrosis and scar also developed. Wickremasinghe et al¹⁰ present two patients which had acute hydrops, 25 years after corneal transplantation. They had acute visual loss and photophobia. On slit-lamp, stromal edema of the graft and adjacent recipient cornea was observed. Descemet's membrane tear and detachment at the donor-host interface was responsible for this edema. Also, hydrostatic pressure might lead to fluid penetration into the recipient stromal cornea adjacent to the donor corneal stroma. Thota et al¹¹ were doing histopathologic examination of graft hydrops, and interlamellar accumulation of fluid was more than intralamellar edema. Cornea responded to this fluid accumulation through formation of a cellular layer around these cystic spaces. This reaction is actually the response of avascular cornea to limit fluid dissemination and finally elimination of it. Using ultrasound biomicroscopy (UBM), Nakagawa et al¹² concluded although the presence of tear in Descemet's membrane is a main factor for acute hydrops in keratoconic patients, it is not the single cause and other factors including intrastromal cleft formation are important. Intrastromal clefts are confirmed in all patients with acute hydrops. They concluded that UBM is helpful for detection of Descemet's membrane tear and intrastromal clefts. These clefts may happen simultaneously or immediately after tear in Descemet's membrane. In terms of resolving edema, the presence of cleft between Descemet's membrane and corneal stroma postpones membrane reattachment and expose large stromal surface to the anterior chamber and water accumulation in stroma. One interesting finding in our patient was corneal vascularization that apparently developed after acute hydrops. Feder et al¹³ pointed out the presence of the corneal vascularization as a rare complication of acute hydrops and considered hydrops adjacent to the limbal area with intrastromal cleft as a risk factor for development of corneal vascularization. Our patient had a superficial vascularization of graft on one eye, but we do not know if he developed it before or after hydrops due to the time when he was sent to us. Several studies¹⁴⁻¹⁶ reported recurrence of keratoconus in transplanted cornea, even 22 years after surgery. In one case of recurrent keratoconus, acute hydrops occurred 20 years after

surgery.¹⁷ In our patient there was no history of recurrence of keratoconus and he had had good vision, no graft rejections before this graft hydrops. 35 years after KPP our patient had on both grafts large area of detachment of Descemet's membrane almost to the border of graft-host junction, but no rupture of Descemet's membrane and no stromal clefts on ASOCT. At the first examination, due to the significant stromal edema and the impossibility of insight into the deeper structure of the cornea and anterior chamber, we treated the patient as if he had a graft rejection.

★ CONCLUSION ★

There are small number of reports of acute hydrops in corneal grafts patient with keratoconus, especially bilateral and associated with floppy eyelid syndrome, but differentiation between acute hydrops and graft rejection is very important because management to these problem is different. In acute hydrops of corneal graft, especially if there is a diffuse large separation of Descemet's membrane, there is no place for high dose of steroids and re-grafting is probably the only solution. UBM and ASOCT are very important tools in distinguishing these two entities.

★ REFERENCES ★

1. Rabinowitz YS. Keratoconus. *Surv Ophthalmol* 1998;42:297-319.
2. Tuori AJ, Virtanen I, Aine E, et al. The immunohistochemical composition of corneal basement membrane in keratoconus. *Curr Eye Res* 1997;16:792-801.
3. Cheng EL, Maruyama I, SundarRaj N, et al. Expression of type XII collagen and hemidesmosome-associated proteins in keratoconus corneas. *Curr Eye Res* 2001;22:333-340.
4. Aldave AJ, Mabon M, Hollander DA, et al. Spontaneous corneal hydrops and perforation in keratoconus and pellucid marginal degeneration. *Cornea* 2003;22:169-174.
5. Pihlblad MS, Schaefer DP. Eyelid laxity, obesity, and obstructive sleep apnea in keratoconus. *Cornea*. 2013 Sep;32(9):1232-6.
6. Sharif KW, Casey TA. Penetrating keratoplasty for keratoconus: complications and long-term success. *Br J Ophthalmol* 1991;75:142-146.
7. Williams KA, Muehlberg SM, Lewis RF, et al. How successful is corneal transplantation? A report from the Australian corneal graft register. *Eye* 1995;9:219-227.
8. Tuft SJ, Gregory WM, Buckley RJ. Acute corneal hydrops in keratoconus. *Ophthalmology* 1994;101:1738-1744.
9. Grewal S, Laibson PR, Cohen EJ, et al. Acute hydrops in the corneal ectasias: associated factors and outcomes. *Trans Am Ophthalmol Soc* 1999;97:187-198.
10. Wickremasinghe SS, Smith GT, Pullum KW, et al. Acute Hydrops in keratoconus masquerading as acute corneal transplant rejection. *Cornea* 2006;25:739-741.
11. Thota S, Miller WL, Bergmanson JP. Acute corneal hydrops: A case report including confocal and histopathological considerations. *Contact Lens Anterior Eye* 2006;29:69-73.
12. Nakagawa T, Maeda N, Okazaki N, et al. Ultrasound biomicroscopic examination of acute hydrops in patients with keratoconus. *Am J Ophthalmol* 2006;141:1134-1136.
13. Feder RS, Wilhelmus KR, Vold SD, et al. Intrastromal clefts in keratoconus patients with hydrops. *Am J Ophthalmol* 1998;126:9-16.
14. Nirankari VS, Karesh J, Bastion F, et al. Recurrence of keratoconus in donor cornea 22 years after successful keratoplasty. *Br J Ophthalmol* 1983;67:23-28.
15. Rubinfeld RS, Traboulsi EI, Arentsen JJ, et al. Keratoconus after penetrating keratoplasty. *Ophthalmic Surg* 1990;21:420-422.
16. Bechrakis N, Blom ML, Stark WJ, et al. Recurrent keratoconus. *Cornea* 1994;13:73-77.
17. Dursun D, Fernandez V, Dubovy S, et al. Hydrops in a corneal graft. *Cornea* 2002;21:535.



Dr. Tanja JURKUL
Otto-von-Guericke University, Magdeburg – GERMANY

.....

CYCLOSPORINE - A REAL ALTERNATIVE

.....

★INTRODUCTION★

Different dermatological diseases like rosacea, psoriasis, atopy may cause chronic ocular manifestation and develop chronic keratitis. Due to this, impairment or loss of vision are the risk. There are different therapeutic strategies with the tear substitute, topic corticoid or cyclosporine.

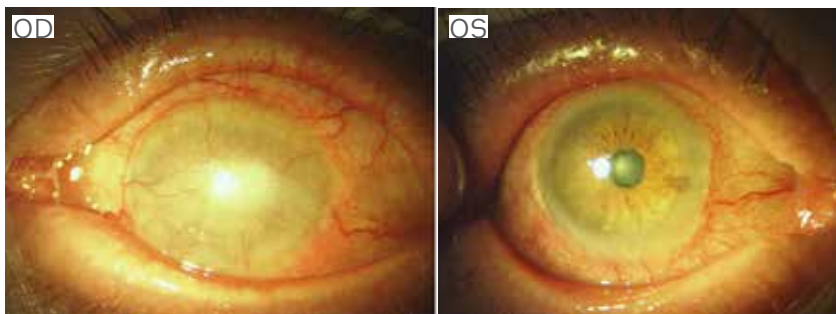
Cyclosporine A eye drops were developed in 1995. Today it is used for treatment of various immune or inflammatory diseases of the cornea, conjunctiva and uvea.

The goal of this review is to support the healing of dry eye and chronic keratitis. It documents the effect of a ten year treatment with cyclosporine on a rosacea keratitis case.

★ CASE PRESENTATION ★

05/2006

In this report, the male patient F., 79 years old described strong complaints since five years like dry eye, burn, foreign body sensation. Please notice the left eye- the entire cornea is tarnished, a range of vaskularisation, no iris or pupil details. There were no effects of a tear substitute or therapeutic contact lens. In December 2006, impairment of vision was noticed. Hygiene of marginal structures, antibiotic therapy with ofloxacin eye drops, aciclovir ointment and carbomer 980 gel were the first therapeutical option. In the following weeks the corneal sensitivity on both eyes was cleared. The diagnosis this time was keratitis neuroparalytica. Ofloxacin and aciclovir were not necessary anymore. In January 2007 the patient still had the marginal blepharitis. So he was prescribed doxycyclin 100 mg once a day

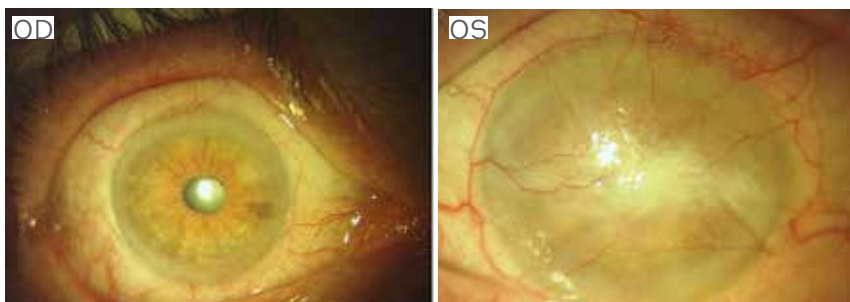


c.c. 0,6

s.c. finger count, glasses don't help

02/2007

We decided to begin the therapy with cyclosporine eye drops 2 % three times a day on both sides and cyclosporine ointment 0,05 % before bed.

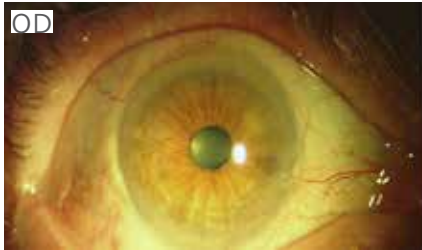

s.c. 0,6, glasses don't help

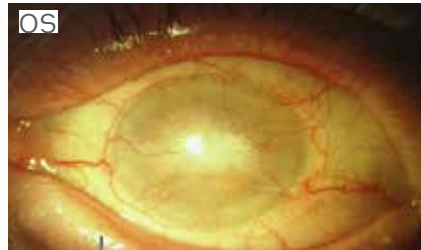s.c. finger count, glasses don't help

05/2007

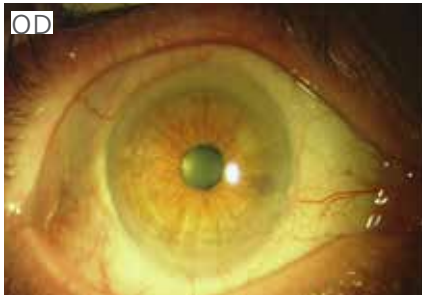Now we had the recommendation to show the patient to the dermatologist to rule out psoriasis, rosacea and atopy.



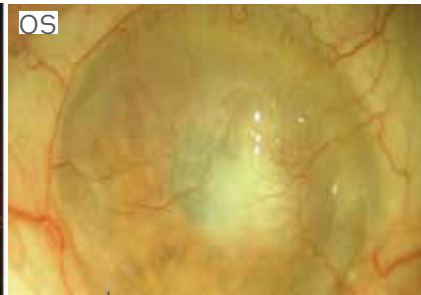s.c. 1,0 p



s.c. 1/30



s.c. 1,0 pp



s.c. 1/20

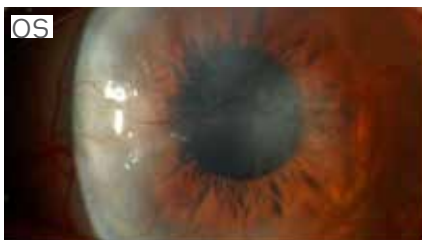In July and August 2007 the dermatologists diagnosed rosacea for this case. The patient was prescribed doxycycline and body emulsion. During the next weeks exanthema broke out on the patient's trunk and legs. An allergy test followed.

Rosacea is a multifactorial chronic inflammatory disease with various clinical manifestations. Primarily it is seen as a dermatological condition, however, it's not uncommon for it to develop ophthalmological implications affecting eyelids, cornea and conjunctiva.

On the right eye, the frequency of the cyclosporine eye drops was reduced to twice a day and on the left eye we continued with three times a day. Every half an hour the patient administered artificial tears.

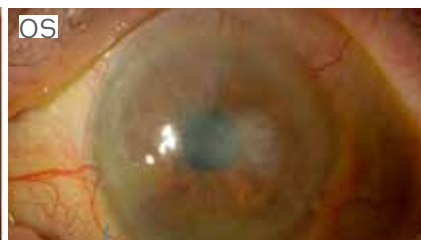The vision increased from year to year.

10/2007



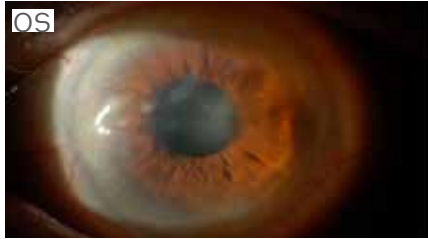s.c. 1/15

05/2008



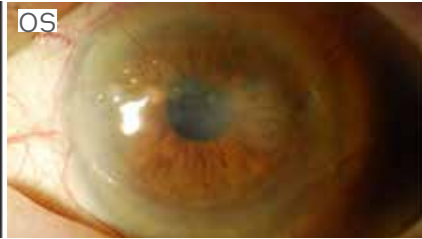s.c. 0,1

02/2011



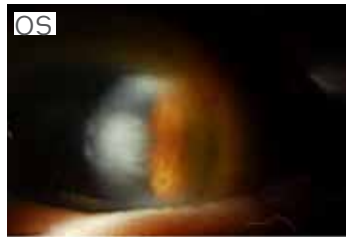s.c. 0,25

10/2014



s.c. 0,2 pp

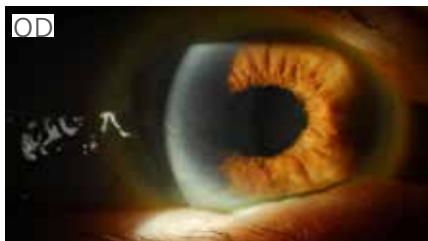07/2016



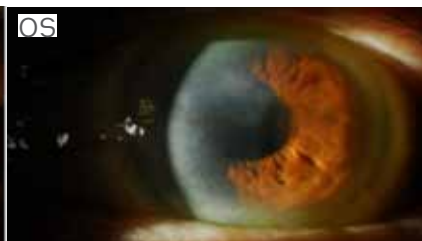c.c. 0,4 p

01/2017

The cyclosporine administration lasted from February 2007 till January 2017. The vision in this period increased from finger count to c.c. 0,4. The patient showed tolerance to cyclosporine well. The cornea on the left eye is partly clear, the corneal scar is much smaller than in 2007, no vascularisation and now it was possible to evaluate the iris and pupil.



c.c. 1,0

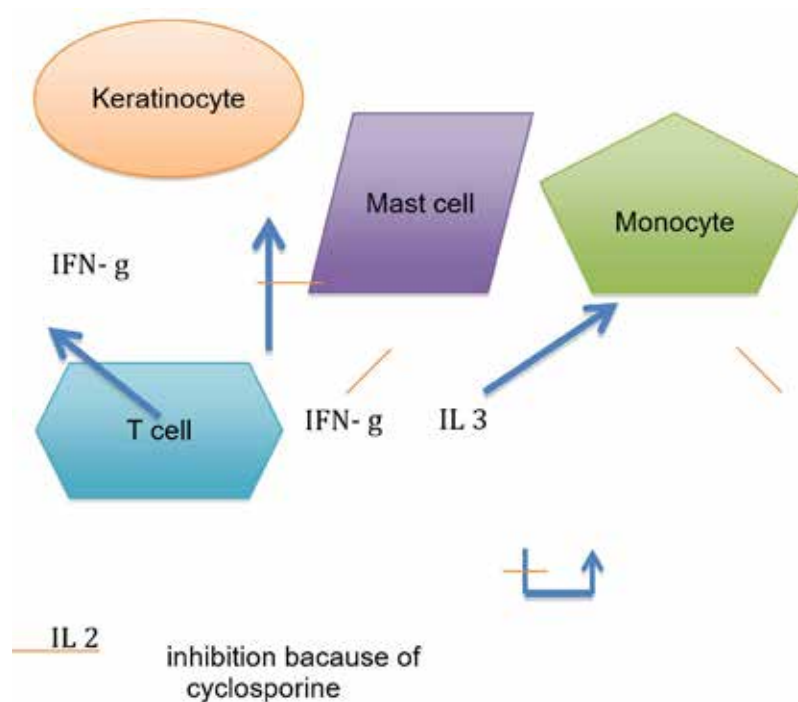


c.c. 0,4

★ DISCUSSION ★

WHAT IS THE MODE OF ACTION OF CYCLOSPORINE?

In 1975 the chemical structure was found. Cyclosporine is obtained by the spores of the fungus *Tolypodadium inflatum*. It intervenes in the early phase of T-cell-activation because of inhibition nuclear transcription factors. The transcription is suppressed by IL 2. The T-cell-activation is inhibited. Therefore, the activated T-cells can't multiply. The immune system is reversible inhibited. Special IL 2 is suppressed but also IL 3,4,5,8, and IFN- g is suppressed.



In the following chart are the side effects of cyclosporine separated in topic and systemic therapy of cyclosporine.

<u>topic therapy</u>	<u>systemic therapy</u>
<p>often: eyelid erythema eyelid edema ocular hyperemia increased production of tear fluid blurred vision ocular pain</p> <p>occasionally: conjunctival edema tear production disorder eye secretion pruritus conjunctivitis blepharitis foreign body sensation</p>	<p>heightened risk for: infection (virus, bacteria, fungi, parasites) lymphoma, malignant tumor especially of the skin</p> <p>very often: hyperlipidaemia, tremor 10-20 %, headache 15 %, hypertonia 15-40 %, nausea, vomiting, diarrhoea, gingivahyperplasia, hypertrichosis, kidney function disorder</p> <p>often: leukopenia, anorexia, hyperuricaemia, hyperkalemia, hypomagnesemia, paresthesias, gastric ulcer, liver injury, acne, myalgia, tiredness, fever</p>

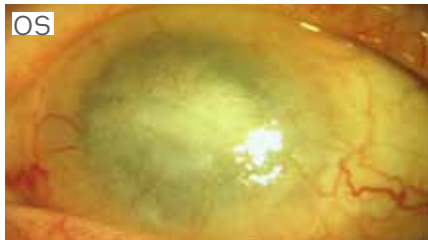
There is no evidence of an increased risk of ocular surface neoplasia with the use of topical ocular cyclosporine⁽¹⁾. To reduce the side effects we recommend the application of the tear substitute before using cyclosporine. Using cool cyclosporine eye drops may relieve the side effects as well. Nasolacrimal occlusion after application of the cyclosporine also helps. Dose variation for older patients is not necessary. There is no special treatment for patients with liver or renal failure. The only disadvantage: cyclosporine eye drops have to be prepared in pharmacy and have less durability.

★ CONCLUSION ★

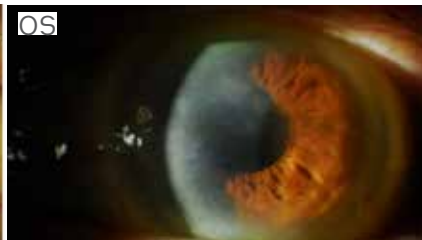Topic cyclosporine is a good therapeutic option to treat difficult keratitis with dry eye, corneal scars and vascularisation when tear substitute or corticoid eye drops doesn't help. The key advantage of cyclosporine is no increase in tension and no development of cataract in contrast to corticoids. There is a good tolerance of cyclosporine and less reason not to use it for a longer time. Collaboration between ophthalmology and dermatology specialists is necessary in order to choose the appropriate strategy for rosacea treatment.

Here is the effect of cyclosporine after a treatment period of ten years on the left eye. The vision has increased from finger count to c.c. 0,4.

02/2007



01/2017



★ REFERENCES ★

- Rouimi F et al, Topical cyclosporine A and risk of ocular surface neoplasia, *J Fr Ophtalmol.* 2018 Feb;41(2):122-128
- Peyman A et al, Topical cyclosporine-A versus prednisolone for herpetic stromal keratitis: a randomized controlled trial, *Acta Ophthalmol.* 2018 Oct 3
- Pflugfelder SC, de Paiva CS, The Pathophysiology of Dry Eye Disease: What We Know and Future Directions for Research, *Ophthalmol.*, 2017 Nov; 124(11S):S4-S13
- Boujnah Yet al, Prospective, monocentric, uncontrolled study of efficacy, tolerance and adherence of cyclosporin 0.1 % for severe dry eye syndrome, *J Fr Ophtalmol.* 2018 Feb;41(2):129-135
- Saldanha IJ et al, Gaps in Current Knowledge and Priorities for Future Research in Dry Eye, *Cornea.* 2017 Dec;36(12):1584-1591
- Safonova TN et al, New approaches to the treatment of keratoconjunctivitis sicca, *Vestn Oftalmol.* 2017;133(2):75-81
- Trufanov SV, Shakhbazyan NP, Ophthalmic Rosacea: etiopathogenesis and modern treatment methods, *Vestn Oftalmol.* 2018;134(3):121-128
- <https://compendium.ch/mpromnr/27569/html/de>, 13.10.2018, 17:29
- <https://compendium.ch/mpromnr/26412/html/de>, 13.10.2018, 17:29
- <https://www.rheuma-online.de/medikamente/ciclosporin-immunosporin/jim-detail/wirkmechanismus/>, 12.10.2018, 11:13

PICTURES

Title page: <http://www.3dchem.com/CyclosporinA.asp>, 10.10.2018, 10:02
Patient pictures: The patient agreed for the presentation of the pictures.



Dr. Malika KHEIDRI

Hospital- universital center Issad Hassani, Beni Messous ,Algers – ALGERIA

.....

TOTAL SCLERITIS PREDOMINANTLY POSTERIOR INDICATIVE OF HASHIMOTO THYROIDITIS

.....

★INTRODUCTION★

- Posterior scleritis: inflammation of the sclera behind the equator, accounts for 3 to 20% of all scleritis.
- It is associated in 60% of cases with anterior scleritis.
- It is a rare cause of ocular inflammation, whose symptomatology is nonspecific, which makes the clinical diagnosis difficult.
- Idiopathic in 50 to 60% of cases as it may be secondary to an infectious disease or systemic disease.
- We report the case of a total scleritis predominantly posterior in a 12-year-old girl.

★ CASE PRESENTATION ★

- Child of 12 years, Weight: 85 kg, height:160 cm
- BMI of 33.2nd grade of obesity
- Family history of HASHIMOTO thyroiditis : mother and brother treated by Levothyroxine
- Presented in the ER for red Eye with pain triggered by eye movements , without loss of visual acuity



Figure 1: girl of 12 yo, BMI of 33.2

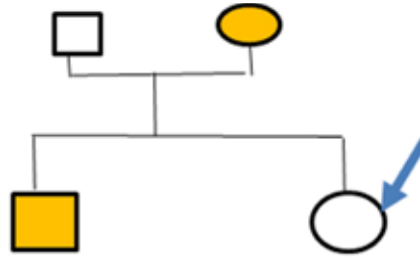
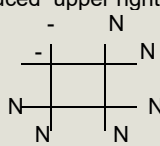
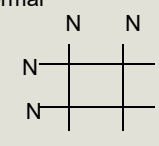


Figure 2: family tree

**TOTAL SCLERITIS PREDOMINANTLY POSTERIOR
INDICATIVE
OF HASHIMOTO THYROIDITIS**

OPHTHALMOLOGICAL EXAMINATION

Right eye		Left eye
<ul style="list-style-type: none"> - Ptosis associated with palpebral edema <ul style="list-style-type: none"> o No variability of ptosis during the day and excessive fatigue o Palpebral fissure height at 03 mm o Margin–reflex distance 03 mm - Proptosis : reducible , axile, non-painful, non-pulsatile - No diplopia - No eyelid malformations - No disorders of the eyelashes 	INSPECTION	good static and dynamic of the eyelids
10/10	VA (CC)	10/10
reduced upper right gaze 	Ocular motility	Normal 
<ul style="list-style-type: none"> - Diffuse conjunctival hyperemia with a red inflamed sclera more pronounced in the temporal side - Neosynephrine 1% Test : Negative - Cornea: clear - Anterior chamber deep and optically empty - Rest of the anterior segment without anomaly - Schirmer test without anomaly - Exploration of lachrymal lanes without abnormality 	Slit lamp exam	anterior segment without anomaly
Posterior pole without anomaly <ul style="list-style-type: none"> • No retinal folds • No DSR • No papillary edema 	fundus examination	Posterior pole without anomaly

RIGHT EYE

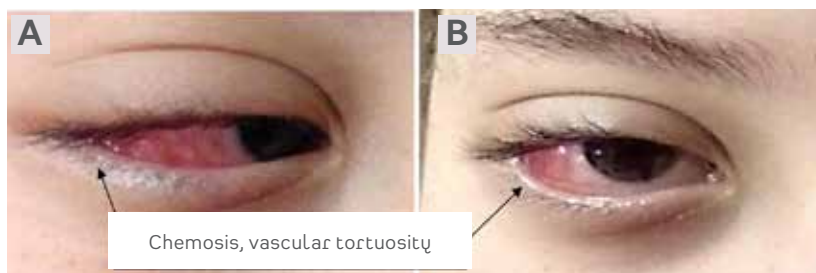


Figure 3: (A,B): arrow showing conjunctival and scleral hyperemia more pronounced the temporal side

FUNDUS EXAMINATION: RIGHT EYE

- No retinal folds
- No DSR
- No papilla edema

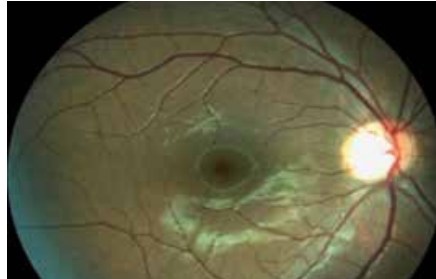


Figure 4: fundus photograph of the right eye

ADDITIONAL TESTS:

1-OPHTHALMOLOGICAL

Ultrasound mode B: right eye : findings in favor of diffuse scleritis of the right eye: thickening of the sclera “T” shaped

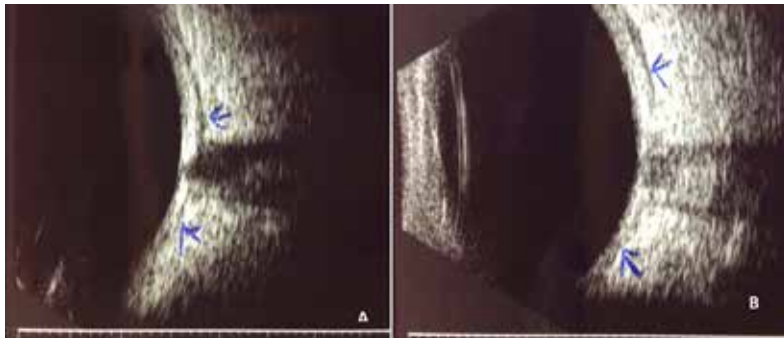


Figure 5: (A, B) Imaging Of B-scan ultrasonography of the right eye showing a T shaped thickening of the sclera

Visual field: within the limits of normal

- Normal retinal sensitivity
- Fovea threshold: 32 db
- Global index: normal



Figure 6: (A, B) imaging of the visual field of the right eye

**TOTAL SCLERITIS PREDOMINANTLY POSTERIOR
INDICATIVE
OF HASHIMOTO THYROIDITIS**

2- BIOLOGICAL EXAMINATIONS:

- Blood count: Hyperleukocytosis
- Sedimentation rate: elevated at the first hour count
- Lipidic: Triglycerides \nearrow
- Renal: normal
- Tuberculin skin test : negative
- Serologies:
 - » ASLO <200 IU / L
 - » Lyme, borreliosis, leprosy: negative
 - » Viral:
 - » HSV1, 2: negative
 - » VZV: negative
 - » Syphilis: negative
- Thyroid:
 - » TSHu: 7.71 μ IU / ml: \nearrow
 - » FT4: 17.28 pmol / l: normal

3- IMMUNOLOGICAL EXPLORATION

- Thyroid:
 - » Ac anti-TPO: normal
 - » Anti-TG: normal
- Systemic disease:
 - » FR: negative
 - » AAN:
 - » Native DNA: negative
 - » Anti SSA, SSB, RNP: negative
 - » AC anti-phospholipid: negative
 - » ANCA: Negativ
- HLA typing:
 - » HLA B27
 - » HLA B5 } NEGATIVE

4-RADIOLOGICAL EXAMINATIONS

- Chest X-ray: normal
- Orbito-cerebral CT: **CHANDLER grade 2**: orbital cellulitis

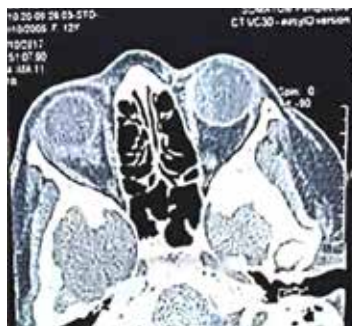

Figure 7: imaging of CT scan (axial view) showing orbital cellulitis of the right eye

5-OPINIONS OF OTHER SPECIALISTS:

- Pediatrics: presence of hepatic steatosis
- Endocrinology: Cervical ultrasound: normal volume thyroid gland, well vascularized with color Doppler, presence of micro colloid follicles in right and left thyroid lobes

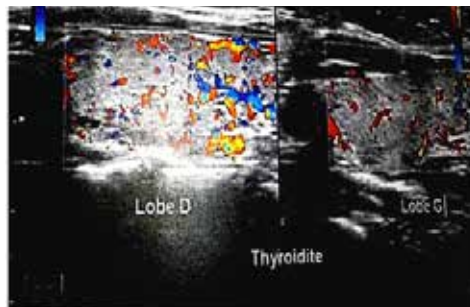


Figure 8: imaging of cervical ultrasound of the thyroid

POSITIVE DIAGNOSIS

- After a collegiate decision (pediatric + ophthalmological + endocrinological) the diagnosis is: total secondary scleritis of the right eye predominantly posterior in a 12 yo child

DIAGNOSTIC ETIOLOGIQUE

THYROIDITIS OF HASHIMOTO is retained according to the following arguments

- Family history of thyroiditis
- BMI 30.33
- High TSH
- FT4 normal
- Normal AC TPO
- Cervical ultrasound: colloidal follicle

TRETEMENT

- The child was put after collegiate discision on a bolus of Methylprednisolone at a dose of 1g / m2 /day
- Strict monitoring of the Bp, HR
- Relay to oral Predinsone 2mg / kg during 01 months then progressive reduction of the dosis
- The follow-up showed a clear improvement:
 - » Disappearance of functional signs
 - » Calm anterior segment
 - » Echo B: regression of scleral thickening at day 10

**TOTAL SCLERITIS PREDOMINANTLY POSTERIOR
INDICATIVE
OF HASHIMOTO THYROIDITIS**

Image of the evolution after 03 days of bolus:

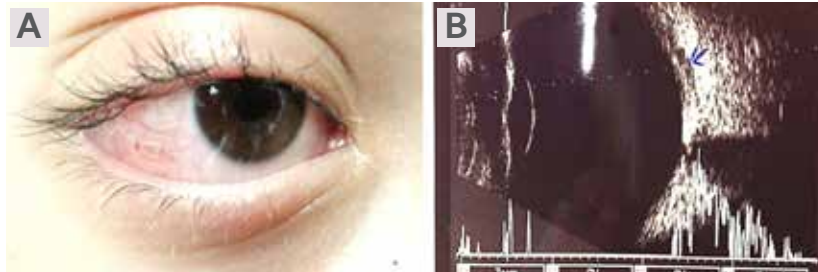


Figure 9: (A) regression of the conjunctival hyperemia after 03 days of treatment (B) Imaging Of B-scan ultrasonography of the right eye showing a regression of scleral thickening

Evolution at day 10:

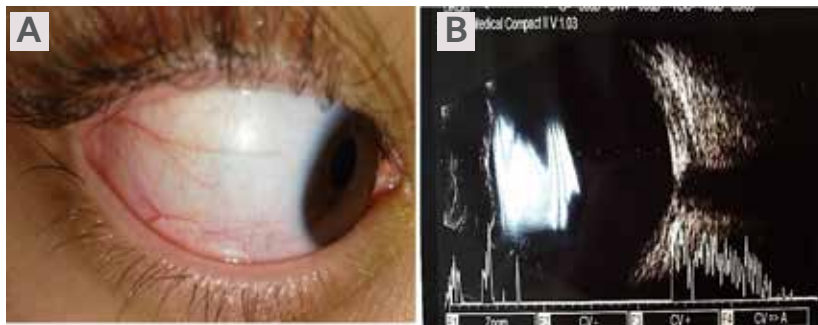


Figure 10: (A) sclera and conjunctiva clear from any inflammation (B) Imaging Of B-scan ultrasonography of the right eye showing a total regression of scleral thickening

★ DISCUSSION ★

- Posterior scleritis is a rare form of scleritis that manifest with eye pain often associated with a decrease in visual acuity, it is associated in 60% of cases with anterior scleritis.
- In children the causes are mainly : systemic diseases (juvenile chronic arthritis, connective tissue disease, vasculitis, sarcoidosis, RA)
- HASHIMOTO thyroiditis is an autoimmune disease characterized by lymphoplasmacytic infiltration of the thyroid gland and a very rare cause of scleritis especially in children, which remains poorly documented until this day.
- In our case, it is an infra-clinical HASHIMOTO thyroiditis that has been diagnosed which is marked by an elevation of the TSH and a normal T4

- The prevalence is high and increase with age or familial context of thyroiditis at the rate of 3 to 15%
- The child is still under close ophthalmic monitoring and endocrine control quarterly given the risk of progression to complete form in 5 to 10% of cases by the presence of anti-TPO Anti-corp with mainly cardiovascular damage.

★ CONCLUSION ★

Scleritis is a serious ocular pathology that requires rigorous and rapid multidisciplinary management.

Despite a predominant idiopathic cause, a thorough and thorough etiological research should be initiated to avoid complications or recurrences.

•

★ REFERENCES ★

- Posterior scleritis about 06 cases Journal Français d'Ophtalmologie Vol 26, N° 8 - octobre 2003
- Scleritis: When might a systemic disease be involved? Journal Français d'Ophtalmologie Volume 33, n° 8 pages 593-598 (octobre 2010)
- Intraocular inflammation and uveitis ,Basic and Clinical Science Course 2017
- Kanski Clinical Ophthalmology 8th_edition



Dr. Despoina-Georgia KOKOSIOULI

National and Kapodistrian University of Athens, General Hospital of Athens – GREECE

.....

COMBINED USE OF TOPICAL CYCLOSPORINE 0.1% WITH A REGENERATIVE AGENT POLY (CARBOXYME THYLGLUCOSE SULFATE) FOR CORNEAL MELT SECONDARY TO GRAFT-VERSUS-HOST-DISEASE

.....

★INTRODUCTION★

Graft Versus Host Disease (GVHD) is one of the main complications in Allogeneic Hematopoietic Stem Cell Transplantation (allo-HSCT), a treatment option indicated for blood malignancies and other blood disorders. According to clinical features and pathogenic processes, two principal versions of GVHD have been described. The acute form where liver, skin and gastrointestinal system is involved and the chronic form with cutaneous, gastrointestinal, pulmonary, musculoskeletal and ocular manifestations. While acute GVHD is attributed to host tissue damage by activated T-cells and cytokines of the donor tissue, the chronic type of the disease is related to thymic damage and impaired negative selection of autoreactive T-cells¹.

Ocular involvement is present in about 40-60% of cases with allo-HSCT. GVHD can affect all parts of the eye but the ocular surface is most commonly involved and complications are attributed to inflammatory fibrotic deterioration of conjunctival and lacrimal glands leading to reduced density of mucin secreting cells and impaired tear production. A great variety of manifestations has been

reported, including blepharitis, episcleritis, pseudomembranes, conjunctival chemosis and hyperaemia, cicatricial conjunctivitis, keratoconjunctivitis sicca, filamentary keratitis, diffuse punctate epitheliopathy, corneal epithelial defects and corneal ulcers. Eye dryness, increased fibrous secretion, photophobia and alacrimia are the most common symptoms². Management of this condition involves topical treatment aiming to the substitution of tear deficiency and the restoration of corneal integrity. In severe cases systemic immunosuppression may be indicated.

★ CASE PRESENTATION ★

A 67-year-old man presented complaining about progressively worsening pain and gradual visual loss in his left eye over the last 20 days. His medical history included acute myeloid leukemia treated with bone marrow transplantation 11 months ago, psoriatic arthritis and coronary disease. Best-corrected visual acuity (BCVA) was 7/10 in his right eye (OD) and finger counting at 30cm in his left eye (OS).

On slit-lamp biomicroscopy, blepharitis and pseudophakia were evident in both eyes. Diffuse coarse punctate epithelial keratopathy, a deep quiet anterior chamber were present OD. In the left eye, a central corneal melt with perforation of 1mm diameter and surrounding stromal edema and hypohyalma without flare or cells in the anterior chamber were noted. The cornea was covered by a therapeutic contact lens (Figure 1).

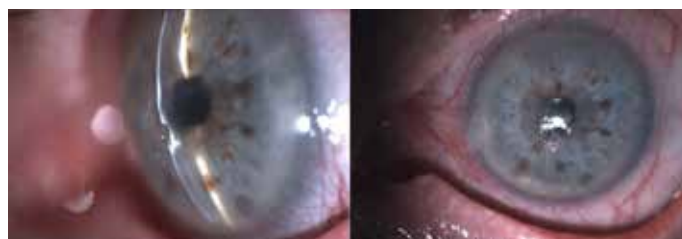

Figure 1: Slit-Lamp images depicting sterile focal melt and perforation of the cornea. Please note the shallow anterior chamber in the presence of only mild conjunctival hyperemia.

In order to restore the tectonic integrity of the left eye, cyanoacrylate glue was applied at the perforation with concurrent bandage contact lens placement. Topical treatment was prescribed and included in both eyes, sodium hyaluronate 2% gel every two hours, cyclosporine 0.1% eye drops twice a day. In addition, non-preserved ofloxacin 0.3% eye drops were given in the left eye four times a day for ten days.

On the first post-operative day, slit lamp examination showed the glue in place, a watertight sealing of the perforation and deep anterior chamber (Figure 2). Topical therapy was administered as mentioned above for the following weeks and bandage contact lens was replaced every one month.

COMBINED USE OF TOPICAL CYCLOSPORINE
0.1% WITH A REGENERATIVE AGENT POLY
(CARBOXYMETHYLGLUCOSE SULFATE) FOR
CORNEAL MELT SECONDARY TO
GRAFT-VERSUS-HOST-DISEASE

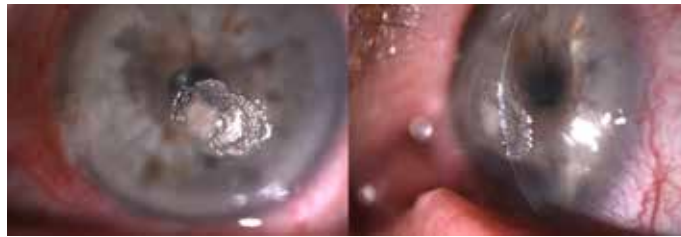

Figure 2: Slit-lamp images depicting the cyanoacrylate glue plug tamponading the melt area that is visible under the glue. The anterior chamber is deep and mild conjunctival hyperemia is present

Two months following surgery, the glue fell off revealing an epithelial defect overlying a hypotrophic stromal scar without any signs of perforation (Figure 3A). Despite intensive treatment with lubricants and cyclosporine during the next two weeks, no healing tendency could be detected. In order to promote epithelialization, autologous serum and onlay amniotic membrane transplantation were considered. However, autologous serum was not considered as safe to administer due to the systemic immunosuppressive treatment the patient was receiving and potentially toxic components of the drug metabolites in the serum³. Amniotic membrane was not available in our hospital at that time. Hence, in order to promote epithelialization, a commercially available regenerative agent poly (carboxymethylglucose sulfate) was prescribed once every three days.

The epithelial defect healed completely after 4 weeks, leaving a hypotrophic stromal scar behind (Figure 3B). The use of the regenerating agent was discontinued at that point.

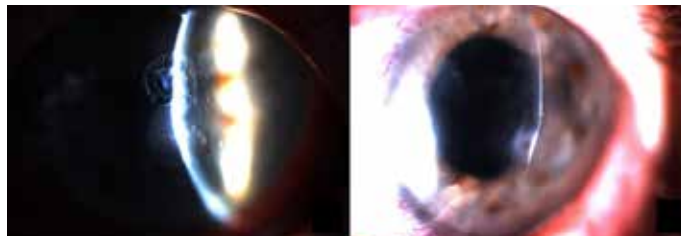

Figure 3: Slit-lamp images before (a) and after (b) the use of the matrix-therapy agent. Please note the visible epithelial margins of the epithelial defect in the left hand-side image and the thin stromal scar in the right hand-side image.

Nine months later, the patient is still under topical treatment with hydrating agents and cyclosporine 0,1% twice a day in both eyes. BCVA was 7/10 OD and 6/10 OS and the corneal epithelium was intact in OD, while in OS fine central punctate epitheliopathy was present (Figure 4).

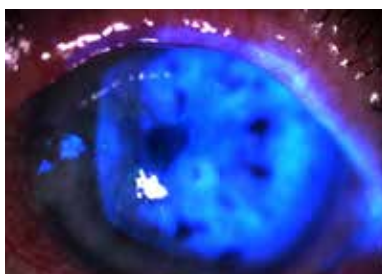


Figure 4: Slit-lamp images depicting only mild punctate epitheliopathy in the central cornea 9 months following successful closure of the persisting epithelial defect OS.

★ DISCUSSION ★

Sterile corneal melt is the inflammatory dissolution of the corneal stroma in the absence of ocular infection and a common prelude to the development of corneal perforation. Differential diagnosis includes keratoconjunctivitis sicca, exposure keratopathy, neurotrophic keratopathy, keratopathy related to certain autoimmune diseases (rheumatoid arthritis, polyarteritis nodosa, systemic lupus erythematosus, Wegener's granulomatosis) and GVHD, while cataract surgery is recognised as a triggering factor for corneal melt in eyes with pre-existing probable causative factors^{4,5,6,7,8}. Given the medical history and the clinical findings of the ocular examination, it was concluded that ocular GVHD is the most probable culprit in our case.

As for every case with corneal melt leading to perforation, independently of the causative mechanism, restoration of the corneal integrity is crucial and the treatment options include use of cyanoacrylate glue, pedicle conjunctival flap, amniotic membrane, pericardium or tectonic corneal transplant. In cases of central small perforations (less than 2-3mm in diameter) without surrounding large area of tissue loss, gluing is the most preferable approach⁹. Further management of patients with corneal melt aims at prevention of infections, minimization of corneal destruction and scarring and restoration of the epithelium. Preservative-free antibiotics may be used to reduce epithelial toxicity and preservative-free tear substitutes are essential for corneal lubrication. Cyclosporine eye drops decrease local inflammation, while autologous serum eye drops may be used as an alternative as they contain a large number of epitheliotropic factors that are present in tears¹⁰.

Carboxymethyl dextran sulfate polymer is bioengineered to replace heparan sulfate, which is an important factor both for matrix proteins and for growth factors. It is characterized as a regenerating agent (RGTA) which acts as a scaffold for matrix therapy in cellular level facilitating regeneration of damaged tissues¹¹. It has CE marking for chronic epithelial corneal defects, neurotrophic keratitis and persistent anterior corneal dystrophies with associated pain^{12,13,14} while there are several reports of faster corneal epithelial healing when used after corneal cross-linking (CXL)^{15,16,17}. In our case, two months after the initial corneal perforation a small 1mm in diameter epithelial and anterior stromal defect was still present. After the use of the matrix-therapy agent as adjunctive treatment to cyclosporine and lubricating factors, the size of the defect reduced significantly over the following weeks and the epithelium was fully restored in one month.

COMBINED USE OF TOPICAL CYCLOSPORINE
0.1% WITH A REGENERATIVE AGENT POLY
(CARBOXYMETHYLGLUCOSE SULFATE) FOR
CORNEAL MELT SECONDARY TO
GRAFT-VERSUS-HOST-DISEASE

★ **CONCLUSION** ★

Ocular GVHD is a serious complication of allo-HSCT with potentially devastating effects on the ocular surface and the vision. Restoration of the corneal integrity when corneal melt is observed is of paramount importance. To our knowledge, this is the first report on the successful use of both cyclosporine eye drops and carboxymethyl dextran sulfate polymer for treating a persisting corneal defect due to GVHD. Further studies may elucidate the efficacy of combined cyclosporine-RGTA treatment in the treatment of persisting epithelial defects.

★ **REFERENCES** ★

1. Ferrara JL, Levine JE, Reddy P, Holler E. Graft-versus-host disease. *The Lancet*. 2009;373(9674):1550–1561.
2. Qiu Y, Hong J, Peng R. Manifestation of Clinical Categories of Ocular Graft-versus-Host Disease. *J Ophthalmol*. 2018; 2018: 6430953.
3. Ali TK, Gibbons A, Cartes C, Zarei-Ghanavati S, Gomaa M, Gonzalez I, Gonzalez AE, Ozturk HE, Betancurt C, Perez VL. Use of Autologous Serum Tears for the Treatment of Ocular Surface Disease From Patients With Systemic Autoimmune Diseases. *Am J Ophthalmol*. 2018 May;189:65-70
4. Hossain P. The corneal melting point. *Eye (Lond)*. 2012 Aug; 26(8): 1029–1030.
5. Inagaki E, Ogawa Y, Matsumoto Y, Kawakita T, Shimmura S, Tsubota K. Four cases of corneal perforation in patients with chronic graft-versus-host disease. *Mol Vis*. 2011; 17: 598–606.
6. Adrean SD, Puklin JE. Perforated corneal ulcer with subsequent endophthalmitis in a patient with graft-versus-host disease. *Cornea*. 2007;26:107–8.
7. Suzuki M, Usui T, Kinoshita N, Yamagami S, Amano S. A case of sterile corneal perforation after bone marrow transplantation. *Eye*. 2007;21:114–6.
8. Yeh PT, Hou YC, Lin WC, Wang IJ, Hu FR. Recurrent corneal perforation and acute calcareous corneal degeneration in chronic graft-versus-host disease. *J Formos Med Assoc*. 2006;105:334–9.
9. Portnoy SL, Insler MS, Kaufman HE. Surgical management of corneal ulceration and perforation. *Surv Ophthalmol*. 1989; 34: 47–58.
10. Zhang X M V. J, Qu Y, et al. Dry eye management: targeting the ocular surface microenvironment. *Int J Mol Sci*. 2017;18:1398
11. Han SB, Liu Y, Mohamed-Noriega K, Mehta JS. Application of novel drugs for corneal cell regeneration. *J Ophthalmol*. 2018; 2018: 1215868.
12. Chebbi CK, Kichenin K, Amar N, et al. Pilot study of a new matrix therapy agent (RGTA OTR4120) in treatment-resistant corneal ulcers and corneal dystrophy. *J Fr Ophtalmol*. 2008;31(5):465–471.
13. Guerra M, Marques S, Gil JQ, et al. Neurotrophic keratopathy: therapeutic approach using a novel matrix regenerating agent. *J Ocul Pharmacol Ther*. 2017;33(9):662–669.
14. Arvola R. P. J., Robciuc A., Holopainen J. M. Matrix regeneration therapy: a case series of corneal neurotrophic ulcers. *Cornea*. 2016;35(4):451–455.
15. Gumus K., Guerra M. G., de Melo Marques S. H., Karaküçük S., Barritault D. A new matrix therapy agent for faster corneal healing and less ocular discomfort following epi-off accelerated corneal cross-linking in progressive keratoconus. *J Refract Surg*. 2017;33(3):163–170.
16. Kymionis G. D., Liakopoulos D. A., Grentzelos M. A., et al. Effect of the regenerative agent poly(carboxymethyl glucose sulfate) on corneal wound healing after corneal cross-linking for keratoconus. *Cornea*. 2015;34(8):928–931.
17. Bata A. M., Witkowska K. J., Wozniak P. A., et al. Effect of a matrix therapy agent on corneal epithelial healing after standard collagen cross-linking in patients with keratoconus: a randomized clinical trial. *JAMA Ophthalmol*. 2016;134(10):1169–1176.



Dr. Diogo LOPES
Garcia de Orta Hospital, Almada – PORTUGAL

.....

TOPICAL CYCLOSPORINE IN A SEVERE STEROID-DEPENDENT PHLYCTENULAR KERATOCONJUNCTIVITIS

.....

★ INTRODUCTION ★

Phlyctenular keratoconjunctivitis is a rare ocular immunological disorder resulting from a hypersensitivity reaction to an inciting agent, most frequently staphylococcal antigens and mycobacterium tuberculosis.¹ This disorder is frequently associated with chronic meibomitis and chalazia that are common signs of ocular rosacea, as result of meibomian gland dysfunction.² It occurs primarily in children and adolescents under 18 years old with higher prevalence in females.³ Corneal and conjunctival phlyctenules, inferior superficial punctate keratopathy are the most common manifestations but in severe cases it can progress to corneal ulcer, infiltrates, neovascularization and even perforation. The corneal phlyctenules can be distinguished from conjunctival phlyctenules, mainly by the location and severity of the symptoms. Although both can be located at the limbus, corneal phlyctenules frequently migrate to cornea and progress to corneal ulceration and posterior neovascularization.⁴

★ CASE PRESENTATION ★

Approximately 2 years ago, a healthy 12-year-old black female without a history of prior ocular or medical disease presented in our urgent care service with photophobia associated to a hyperemic and painful left eye with 6 weeks of evolution. Ophthalmic examination revealed conjunctival hyperemia and a paracentral corneal ulcer in the left eye with a visual acuity of 20/20 OD and 20/30 OS. Gram stain and culture of a conjunctival swab did not reveal any organisms. The patient was treated with topical moxifloxacin, ciprofloxacin ointment and artificial tears that restored the corneal integrity. Four weeks later, she came to our consult with new symptoms and the biomicroscopy revealed a new stromal ulcer and centripetal corneal neovascularization in the left eye, conjunctival hyperemia and phlyctenules in both eyes. (Figure 1) At this phase, the patient was treated with topical moxifloxacin, oral doxycycline and artificial tears. As soon as the corneal ulcer was completely healed, the patient started topical and corticosteroid treatment with dexamethasone eye drops and low dose of oral prednisolone. Testing for chlamydia trachomatis and mycobacterium tuberculosis was negative as was immune disease investigation. During the follow-up, the patient presented episodes of chalazia and facial pustules and we added eyelid hygiene with warm compresses to the therapy (Figure 2). Therefore, the diagnosis of bilateral phlyctenular keratoconjunctivitis secondary to recurrent ocular rosacea was presumed. After 2 months of treatment, conjunctival and corneal phlyctenules improved with regression of the neovessels but a left paracentral corneal opacity remained (Figure 4), leading to an impaired vision (20/20 OD and 20/40 OS). After several failed attempts of tapering the corticosteroids (Figure 3), the addition of topical cyclosporine 0.05% to the therapy enabled corticosteroid discontinuation.

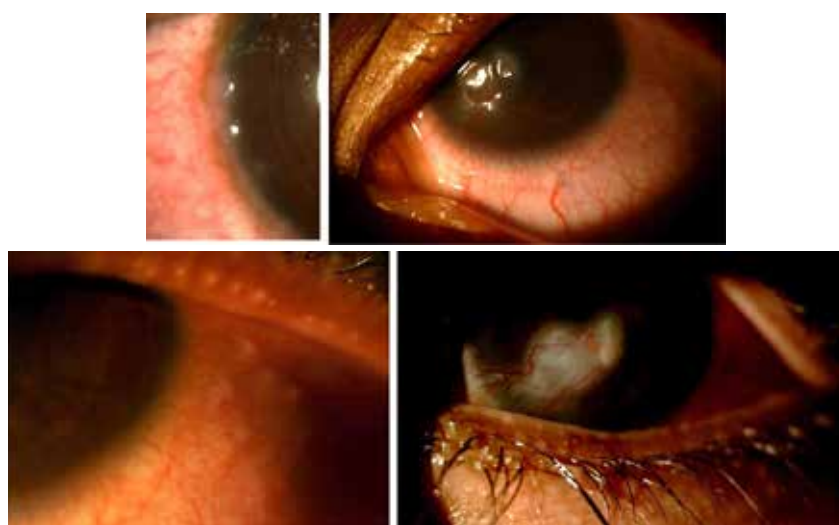

Figure 1: Corneal ulcer in the left eye and corneal neovascularization.

TOPICAL CYCLOSPORINE IN A SEVERE STEROID-DEPENDENT PHLYCTENULAR KERATOCONJUNCTIVITIS

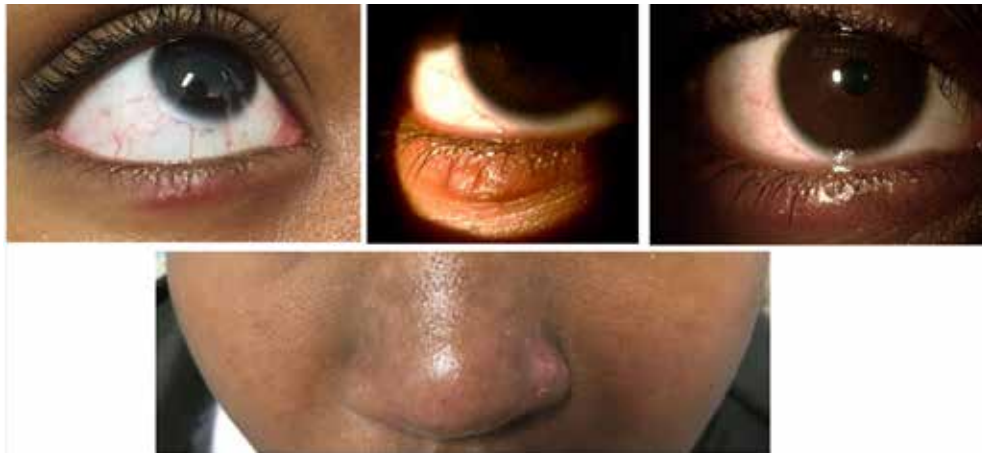

Figure 2: Chalazion in right eye and facial pustules.

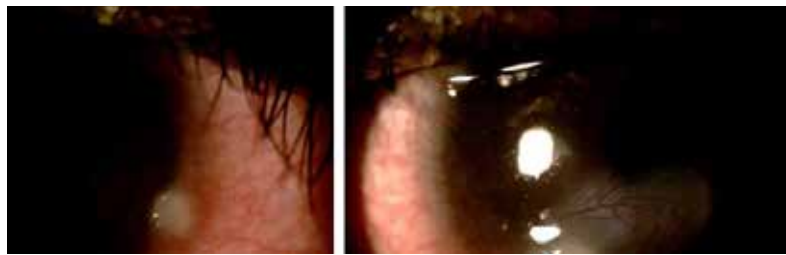

Figure 3: Relapsing episodes with corneal phlyctenules

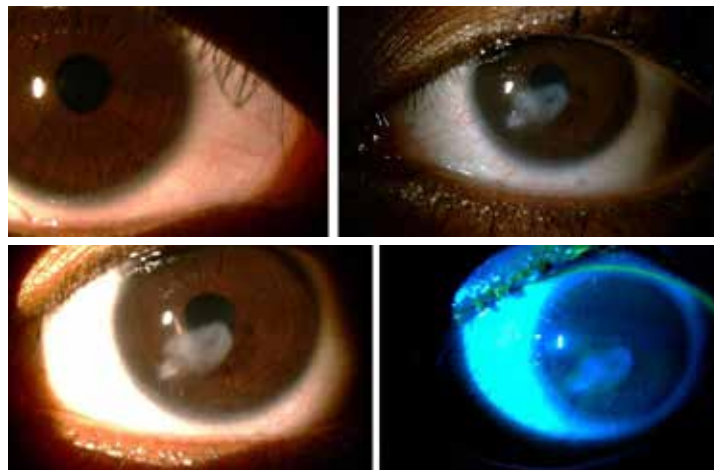


Figure 4: Clinical regression and stabilization with a paracentral opacity in the left eye

Phlyctenular keratoconjunctivitis is a local corneal and conjunctival inflammation, presumed to be a type IV cell-mediated hypersensitivity to microbial antigens with bilateral presentation in approximately 40% of the patients.¹ Some studies report an association with ocular rosacea that has a possible causative role in phlyctenulosis.^{4,5} Although in mild to moderate cases and especially in the presence of staphylococcal or rosacea related

blepharitis, the treatment with eyelid hygiene and oral antibiotics drugs like doxycycline or erythromycin can be enough to control the inflammation, topical corticosteroid is considered the mainstay treatment in cases of severe disease with corneal ulcers and neovascularization.² Complications of the severe form of PK include corneal scarring/opacities, thinning and even perforation. Unfortunately, in few patients, this disorder can be steroid-dependent or refractory to steroid therapy. In these cases to prevent potential adverse effects of steroid long-term use, topical or even systemic immunosuppressive drugs, as cyclosporine and tacrolimus, have been used with success.^{1,2,6,7} The literature reports a good control of ocular inflammation with topical cyclosporine 2%, as showed by our case report, and tacrolimus 0.03% (30 times more potent), being excellent options of treatment, with minimal side effects, in patients with steroid-dependent or refractory phlyctenular keratoconjunctivitis.^{1,2}

★ CONCLUSION ★

Although staphylococcus aureus and mycobacterium tuberculosis are the most common causes of phlyctenular keratoconjunctivitis, it is important to keep in mind that the literature reports some cases of phlyctenular keratoconjunctivitis secondary to childhood ocular rosacea and blepharitis. As our case reports, the phlyctenules, a typical sign of phlyctenular keratoconjunctivitis may not be present as an initial manifestation of this condition. This case also empathizes, as other studies and case reports, that topical cyclosporine 0.05% can be an effective and safe treatment in children with phlyctenular keratoconjunctivitis with severe steroid-dependent corneal inflammation.

★ REFERENCES ★

1. Kymionis, G. D., Kankariya, V. P., & Kontadakis, G. A. (2012). Tacrolimus Ointment 0.03% for Treatment of Refractory Childhood Phlyctenular Keratoconjunctivitis. *Cornea*, 31(8), 950–952.
2. Doan, S., Gabison, E., Gatinel, D., Duong, M.-H., Abitbol, O., & Hoang-Xuan, T. (2006). Topical Cyclosporine A in Severe Steroid-Dependent Childhood Phlyctenular Keratoconjunctivitis. *American Journal of Ophthalmology*, 141(1), 62–66.e2.
3. Culbertson, W. W., et al. (1993). "Effective Treatment of Phlyctenular Keratoconjunctivitis with Oral Tetracycline." *Ophthalmology* 100(9): 1358-1366.
4. Neiberg, M. N., & Sowka, J. (2008). Phlyctenular keratoconjunctivitis in a patient with Staphylococcal blepharitis and ocular rosacea. *Optometry - Journal of the American Optometric Association*, 79(3), 133–137.
5. Blaustein BH, Gurwood AS. Recurrent phlyctenular keratoconjunctivitis: a forme fruste manifestation of rosacea. *Optometry* 2001;72(3): 179-84.
6. Valério Sequeira Valadares, J., Bastos-Carvalho, A., Pedrosa Franco, J. M., Mourão, A. F., & Monteiro-Grillo, M. (2014). Phlyctenular keratoconjunctivitis – an atypically severe case treated with systemic biologic immunosuppressive therapy. *GMS Ophthalmology Cases*, 4, Doc02. <http://doi.org/10.3205/oc000015>
7. Oworu, O., Alagband, P., & Hutchinson, C. (2013). Successful treatment of phlyctenular keratoconjunctivitis with topical cyclosporin A. *Contact Lens and Anterior Eye*, 36(5), 265–266.



Dr. Marco PELLEGRINI
S.Orsola-Malpighi University Hospital, Bologna – ITALY

.....

REGENERATING AGENT PLUS SERUM EYE DROPS FOR THE TREATMENT OF PERSISTENT CORNEAL EPITHELIAL DEFECT: AUTOMATED QUANTITATIVE ASSESSMENT OF CORNEAL WOUND HEALING

.....

★INTRODUCTION★

Corneal persistent epithelial defects (PED) are defined as “epithelial defects persisting more than 2 weeks without improvement despite conventional treatment such as artificial tears or extended wear soft contact lenses.”¹ Several etiologies for PED include severe dry eye disease, chemical burns, Stevens-Johnson syndrome, limbal stem cell deficiency, corneal surgery, neurotrophic keratitis and exposure keratopathy.¹⁻³ The treatment of PED may be challenging, and in the absence of healing, the cellular degradation resulting from chronic inflammation may lead to corneal scarring, neovascularization, non-infectious stromal melting, and even corneal perforation.⁴

Recently, novel treatments such as regenerating agents (RGTA) and serum-derived eye drops have provided encouraging results in treatment of PED and chronic corneal ulcers that are resistant to conventional treatments.⁴⁻⁷ Regenerating agents are large biopolymers engineered as heparan sulfate analogues. They replace and mimic the degraded glycosaminoglycans of the

extracellular matrix, thereby creating a microenvironment favorable for tissue healing. Blood derived eye drops represent a group of biological therapies obtained either from patients' own blood or from donors. They contain a mixture of growth factor essential in corneal homeostasis and wound healing.⁸ The combined therapy of RGTA and blood derived eye drops has been recently proposed, thanks to the hypothesized synergistic effect discussed below in details.⁹

We report a case of PED resistant to conventional therapy that was successfully treated with a combination of RGTA and umbilical cord blood serum (CBS) derived eye drops. The response to the treatment was objectively evaluated by measuring the area of the corneal staining with a new automated digital imaging analysis technique.

★ CASE PRESENTATION ★

A 67-year-old Caucasian man was referred to the Cornea Service of our Institution because of a chronic corneal epithelial defect in his left eye. The patient had a history of severe alkali chemical burn in the same eye 5 years before. Three months after the injury, he developed limbal stem cell deficiency, and underwent limbal stem cell transplantation (autologous cultured limbal stem cell autograft) followed by penetrating keratoplasty 1 year later. Upon presentation, slit lamp examination revealed intense conjunctival hyperemia, peripheral corneal vascularization and a corneal epithelial defect covering the entire graft (Figure 1, part A and B).

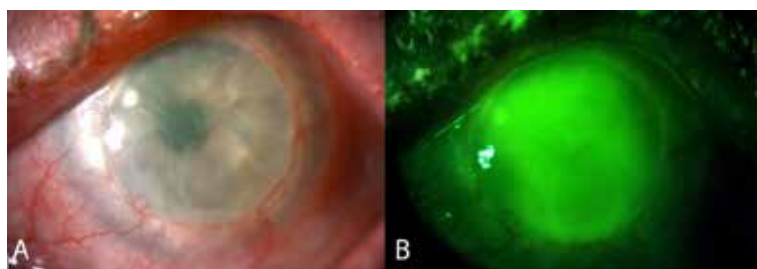


Figure 1: Slit-lamp photographs of the patient on presentation. A: intense conjunctival hyperemia with peripheral corneal neovascularization and opacification of the corneal graft. B: corneal fluorescein staining showing a corneal epithelial defect covering the entire graft.

Best-corrected visual acuity was limited to hand motion at 1 foot. The patient was instructed to instill tear substitutes containing trehalose and hyaluronic acid every 2 hours, steroids eye drops (hydrocortisone sodium phosphate) 4 times daily, cyclosporine eye drops twice daily, tetracycline/sulfamethylthiazole ointment at bedtime. This therapy allowed a better control of ocular surface inflammation, with significant reduction of conjunctival hyperemia and improvement of tear production. However, despite therapy, the epithelial defect remained stable in the subsequent 8 weeks. Based on

REGENERATING AGENT PLUS SERUM EYE DROPS FOR THE TREATMENT OF PERSISTENT CORNEAL EPITHELIAL DEFECT: AUTOMATED QUANTITATIVE ASSESSMENT OF CORNEAL WOUND HEALING

the diagnosis of PED resistant to conventional treatment, we opted for an experimental combined therapy of RGTA plus CBS eye drops. The patient was instructed to instill RGTA eye drops in the morning once every 2 days in combination with daily CBS eye drops (six times/day).

PATIENT EXAMINATION AND DIGITAL IMAGE ANALYSIS

During the course of study treatment, the patient was examined weekly. Slit-lamp photography was taken after administration of 2 mL of 2% fluorescein dye with a slit lamp equipped with a digital camera using the blue cobalt filter and a 7503 Boston yellow filter kit to enhance staining details. The anterior segment images were analyzed using the public domain software ImageJ 1.51s (National Institutes of Health, Bethesda, MD, USA) with a new technique that we developed. Briefly, the original image was opened in ImageJ (Figure 2, parts A and B), and the oval tool was used to trace and measure the total corneal area. The contrast-limited adaptive histogram equalization was applied to highlight the pixel intensity of areas corresponding to staining, and median filtering was applied to reduce noise. Next, the green channel image was split from the original image (Figure 2, parts C and D). The Huang threshold was used to obtain a binarized image (Figure 2, parts E and F), and the color threshold tool was used to select the white pixels. The area of white pixels within the total corneal area, representing the corneal staining, was measured. Finally, the corneal staining index, defined as the ratio between the staining area and the total corneal area, was calculated.

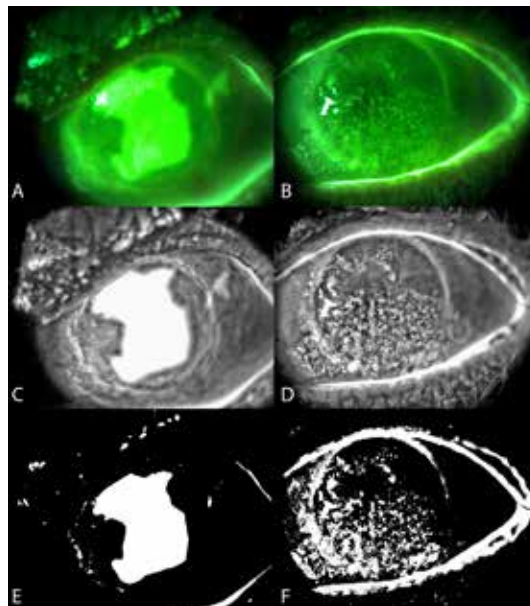


Figure 2: SCorneal fluorescein staining assessment with digital image analysis in the presence of single epithelial defect (parts A, C, E) and punctate superficial keratopathy (parts B, D, F). A, B: original slit-lamp photographs. C, D: contrast-limited adaptive histogram equalization was applied to highlight the pixel intensity areas, median filtering was applied to reduce noise and the green channel image was split from the original image. E, F. Huang threshold was used to binarize the image. The corneal staining index was measured dividing the area of white pixels within the corneal area for the total corneal area..

PATIENT FOLLOW-UP

Following the beginning of the combined therapy with RGTA and CBS, the corneal epithelial defect healed gradually, and ocular surface inflammation reduced rapidly. The corneal staining index measured 50.0% at week 1 (Figure 3, part A), and reduced to 48.7% at week 2 (Figure 3, part B), to 25.2% at week 3 (Figure 3, part C), and to 13.3% at week 4 (Figure 3, part D). At week 5, although the epithelial defect was completely healed, superficial punctate keratopathy was still present, with a corneal staining index of 26.2% (Figure 3, part E). Therefore, the combined RGTA and CBS treatment was discontinued, while tear substitutes were continued every 2 hours. At week 8, the superficial punctate keratopathy was improved; corneal staining index was 4.8% (Figure 3, part F) and the patient reported the resolution of ocular surface symptoms (OSDI score 8). Treatment global tolerance assessed by both examiners and patient was very satisfactory. No adverse events occurred.

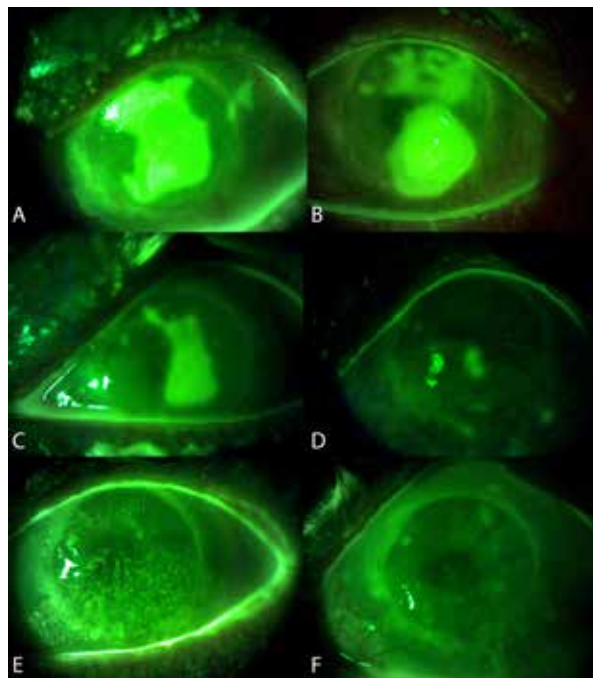


Figure 3: Progressive healing of the epithelial defect after the combined therapy with regenerating agent and cord blood serum eye drops at respectively 1 week, 2 weeks, 3 weeks, 4 weeks, 5 weeks and 8 weeks (parts A-F).

★ DISCUSSION ★

Corneal wound healing consists of a complex sequence of events involving cell migration, proliferation, differentiation, and extracellular matrix remodeling. This process is modulated by several cytokines, growth factors and extracellular matrix proteins, and may be impaired by different pathological conditions including ocular surface inflammation.¹⁰ In our patient, the complex puzzle of ocular surface alterations (i.e. sequelae of alkali burn, limbal stem cell deficiency, penetrating keratoplasty and severe dry eye disease) determined a corneal PED resistant to conventional treatment. Therefore, we decided to treat firstly and aggressively the underlying ocular surface inflammation, which is known to impair epithelial healing and cause excessive fibrotic response with corneal opacification and neovascularization.¹¹ Subsequently, the combined therapy with RGTA and CBS addressed the healing of the epithelial defect by supplying the proper amount of growth factors as well as the substrate required for cellular proliferation and migration.

Regenerating agents are structural analogues of heparan sulfates designed to imitate the actions of the extra-cellular matrix components.¹² These polymers replace the damaged heparan sulfate at the site of injury, restore the matrix architecture, protect growth factors and matrix proteins from proteolysis, and attenuate ocular surface inflammation by reducing oxidative, proteolytic, and nitrosative damage.¹³ Cord blood serum contains high levels of growth factors including epidermal growth factor (EGF), fibroblast growth factor (FGF), transforming growth factor (TGF), nerve growth factor (NGF) and platelet-derived growth factor (PDGF).⁸ These factors promote the proliferation, vitality and migration of corneal cells, playing a key role in ocular surface wound healing. In addition, TGF- β has anti-inflammatory properties, inducing the activity of regulatory T cells and exerting a limiting effect on innate and adaptive immune responses.¹⁴

In recent years, various studies showed that both RGTA and serum eye drops are effective therapeutic alternatives for PED and chronic ulcers resistant conventional treatments.^{1-2,4-5} However, to date no reports of the combination of these two therapies for the treatment of PED are available in literature. This work describes for the first time the successful combined use of RGTA and CBS eye drops for the treatment of PED resistant to conventional treatment. Despite the challenging nature of the case due to a complex combination of ocular surface diseases, the epithelial defect healed completely in five weeks. We hypothesize a synergistic effect of the combined therapy: RGTA eye drops could protect the bioavailability of growth factors and provide a matrix over which epithelial cells can migrate during the wound healing process, whereas growth factors supplied by CBS eye drops could strengthen the repair process by promoting cell growth over the regenerated matrix.

We applied a novel image analysis algorithm to assess corneal fluorescein staining and monitor the response to the therapy. Traditionally, fluorescein staining is graded with subjective clinical scales which suffer from several disadvantages, such as high inter- and intraobserver variability, unequal steps and biased reference description for severity.¹⁵ Recently, objective methods to assess corneal fluorescein staining based on digital image analysis have been proposed.¹⁵⁻¹⁶ These techniques have a high level of intraobserver consistency, and provide more sensitive and reliable assessment than subjective grading.¹⁵⁻¹⁶ However, these methods were previously employed only in eyes with punctate corneal erosions and not in epithelial defects. The image analysis algorithm that we developed used contrast-limited adaptive histogram equalization, a median filter and Huang thresholding to highlight corneal fluorescence. The technique provided reliable results in case of both single corneal epithelial defect and punctate keratopathy. This approach appears a valuable tool for evaluating objectively corneal staining in clinical trials.

★ CONCLUSION ★

Persistent epithelial defect represents a real therapeutic challenge for Ophthalmologists. This work describes for the first time the successful combined use of RGTA and CBS eye drops for the treatment of this condition. The rationale of this therapeutic strategy is based on the hypothesized synergistic effect of the two components, with RGTA protecting growth factors from proteolysis and providing an optimal migration substrate, and CBS supplying growth factors that promote cell growth over the regenerated matrix. The new digital image analysis technique used in this study was shown to be a useful objective method for evaluating quantitatively corneal fluorescein staining, and monitor the response to the therapy over the entire follow-up.

REGENERATING AGENT PLUS SERUM EYE DROPS
FOR THE TREATMENT OF PERSISTENT CORNEAL
EPITHELIAL DEFECT: AUTOMATED QUANTITATIVE
ASSESSMENT OF CORNEAL WOUND HEALING

★ REFERENCES ★

1. Tsubota K, Goto E, Shimmura S, Shimazaki J. Treatment of persistent corneal epithelial defect by autologous serum application. *Ophthalmology* 1999; 106(10):1984-1989.
2. Yoon KC, Heo H, Jeong IY, Park YG. Therapeutic effect of umbilical cord serum eyedrops for persistent corneal epithelial defect. 2005;19(3):174-178.
3. Lee SH, Tseng SCG. Amniotic membrane transplantation for persistent epithelial defects with ulceration. *Am J Ophthalmol*. 1997;123:303-312.
4. Aifa A, Gueudry J, Portmann A, Delcampe A, Muraine M. Topical treatment with a new matrix therapy agent (RGTA) for the treatment of corneal neurotrophic ulcers. *Invest Ophthalmol Vis Sci*. 2012;53(13):8181-8185.
5. Kymionis GD, Liakopoulos DA, Grentzelos MA, et al. Combined topical application of a regenerative agent with a bandage contact lens for the treatment of persistent epithelial defects. *Cornea*. 2014;33(8):868-872.
6. Young AL, Cheng ACO, Ng HK, et al. The use of autologous serum in persistent corneal epithelial defects. *Eye*. 2004;18:609-614.
7. Schrader S, Wedel T, Moll, et al. Combination of serum eye drops with hydrogel bandage contact lenses in the treatment of persistent epithelial defects. *Arch Clin Exp Ophthalmol*. 2006;244:1345-1349
8. Giannaccare G, Versura P, Buzzi M, Primavera L, Pellegrini M, Campos EC. Blood derived eye drops for the treatment of cornea and ocular surface diseases. 2017;56(4):595-604.
9. Giannaccare G, Fresina M, Vagge A, Versura P. Synergistic effect of regenerating agent plus cord blood serum eye drops for the treatment of resistant neurotrophic keratitis: a case report and a hypothesis for pathophysiologic mechanism. *Int Med Case Rep J*. 2015;8:277-281.
10. Katzman, L.R., and Jeng, B.H. Management strategies for persistent epithelial defects of the cornea. *Saudi J. Ophthalmol*. 28:168-172, 2014.
11. Bukowiecki A, Hos D, Cursiefen C, Eming SA. Wound-Healing Studies in Cornea and Skin: Parallels, Differences and Opportunities. *Int J Mol Sci*. 2017 Jun 12;18(b). pii: E1257.
12. Chebbi, C.K., Kichenin, K., Amar, N., et al. Pilot study of a new matrix therapy agent (RGTA OTR4120) in treatment resistant corneal ulcers and corneal dystrophy. *J. Fr. Ophtalmol*. 31:465-471, 2008.
13. Cejkova J, Olmiere C, Cejka C, Trosan P, Holan V. The healing of alkali-injured cornea is stimulated by a novel matrix regenerating agent (RGTA, CACICOL20): a biopolymer mimicking heparan sulfates reducing proteolytic, oxidative and nitrosative damage. 2014;29(4):457-478.
14. Stenwall PA, Bergstrom M, Seiron P, Sellberg F, Olsson T, Knutson F, et al. Improving the anti-inflammatory effect of serum eye drops using allogeneic serum permissive for regulatory T cell induction. *Acta Ophthalmol*. 2015;93(7):654-7.
15. Chun YS, Yoon WB, Kim KG, Park IK. Objective assessment of corneal staining using digital image analysis. *Invest Ophthalmol Vis Sci*. 2014; 55: 7896-7903.
16. Amparo F, Wang H, Yin J, Marmalidou A, Dana R. Evaluating Corneal Fluorescein Staining Using a Novel Automated Method. *Invest Ophthalmol Vis Sci*. 2017 May 1;58(6):BIO168-BIO173.



Dr. Maja POTRC
University Medical centre Ljubljana, Ljubljana – SLOVENIA

.....

ADVANCED STAGE MMP TREATED BY INTRAVENOUS CYCLOPHOSPHAMIDE

.....

★INTRODUCTION★

Mucous membrane pemphigoid (MMP) is an autoimmune disease that is characterized by recurrent sub-epithelial blisters. It predominantly involves various mucous membranes, skin can be occasionally affected as well^(1,2).

The lesions typically heal with excessive scar tissue formation⁽³⁾. Although ocular and oral mucosa are most common sites affected, it may manifest as varying constellation of urogenital, nasopharyngeal, oesophageal, and laryngeal mucosa lesions. The disease can occur at any age, but the onset is most common in the 7th decade⁽⁴⁾, the average age of onset being 65 years⁽³⁾. There are no racial or geographic predispositions, however women are estimated to be affected 1.5 to 5 times more frequently⁽⁵⁾. Although MMP is a rare disorder, with an incidence of 1,16 per million population per year⁽⁶⁾, it is the leading cause of chronic cicatrizing conjunctivitis in developed world⁽⁷⁾. When ocular manifestations are present, the term ocular MMP (OMMP), previously known as ocular cicatricial pemphigoid (OCP), is used. Eyes are affected in 70% of the patients, where severe loss of sight occurs in 30 % and bilateral blindness in up to 20%^(7,8). Ocular involvement, without any other signs of the disease, occurs in 50% of all cases treated by an ophthalmologists⁽³⁾.

OMMP typically presents with bilateral, but often asymmetric⁽⁴⁾, progressive conjunctival inflammation. When left untreated, fibrosis and retraction of sub-epithelial tissue lead to shortening of the fornices, flattening of the plica semilunaris and caruncle, formation of symblepharon, entropion, trichiasis, lagophthalmos, and ankyloblepharon. Patients complain of dry eye symptoms early on, as scarring destroys conjunctival goblet cells and obstructs lacrimal gland ductules and meibomian gland orifices⁽⁹⁾. Chronic limbitis develops, causing limbal stem cell depletion. Corneal neovascularization and conjunctivalization follow, developing vision-threatening keratopathy.

The diagnosis is based on clinical picture, histopathological and immunological examination⁽⁷⁾. In all patients with chronic and progressive cicatrizing conjunctivitis in the absence of other causes of conjunctival scarring, a perilesional mucosal or skin biopsy for histopathological and immunological examination has to be undertaken. The diagnosis is confirmed by a positive direct (DIF) or indirect immunofluorescence (IIF). Typical finding in DIF is linear deposition of immunoglobulin G, A, or complement (C3) along the basement membrane zone (Figure 1). IIF identifies specific circulating autoantibodies in serum and can be helpful if positive, however the sensitivity of this technique is poor and positive in only 41% of patients with OMMP⁽¹⁰⁾. Patients with a typical phenotype of progressive conjunctival scarring and negative immunohistopathology are diagnosed with MMP, if all other causes of this phenotype have been excluded^(7,11).

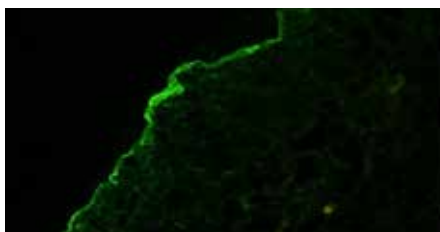


Figure 1: Direct immunofluorescence in MMP: characteristic staining of linear deposits of immunoglobulins IgG, A or C3 complement along BMZ.

Management and therapy are often challenging in MMP. A multidisciplinary approach consisting of dermatologists, ear, nose and throat specialists, and ophthalmologists is essential⁽¹²⁾. Topical treatment of ocular surface disorders is necessary, but is by itself not adequately effective in stopping MMP progression. Patients with OMMP are always regarded as high risk patients⁽¹⁾, in which the recommended treatment is a combination of immunomodulatory drugs.

★ CASE PRESENTATION ★

A 79-year-old male was referred to our clinic in December 2017 due to severe bilateral chronic blepharoconjunctivitis and recurrent entropion with trichiasis. His past medical history revealed complaints of chronic red eye, foreign body sensation, sharp eye pain bilaterally, epistaxis several times weekly, and gingival hypertrophy with occasional bleeding lasting for nearly 3 years. Aside from Diabetes Mellitus type 2, treated with oral antidiabetic drug Novonorm and diet, he had no other known systemic diseases.

Since the manifestation of aforementioned ocular difficulties, he had regular check-ups every 2-3 months, for follow-up and epilation of eyelashes due to trichiasis on his right eye at his secondary-level ophthalmologist's. In February 2017, he underwent entropion correction surgery on his right eye, which reappeared months later.

On initial presentation at our clinic, his best-corrected visual acuity was 0,3 for his right and 0,9 for his left eye. Both eyes showed thickened, red eyelid margins, more pronounced on the right eye, and conjunctivitis with glutinous discharge. On his right eye, there was also an entropion with trichiasis, symblepharon, and sectorial neovascularization with mild conjunctivalization of the cornea (Figure 2). Both fundi showed glaucomatous changes of optic nerves.

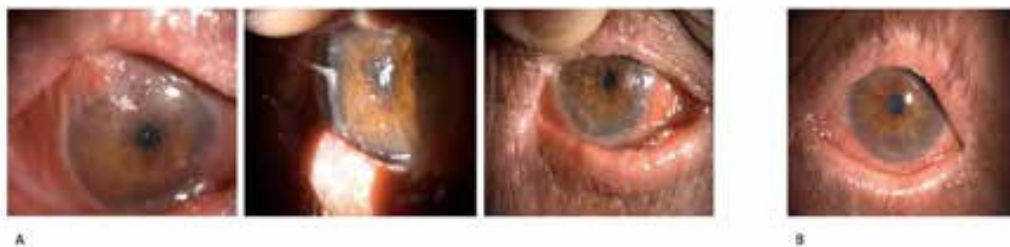


Figure 2: 2A right eye before treatment, 2B left eye before treatment

There were no signs of allergic aetiology. Infectious causes were excluded by repeated conjunctival smears tested for bacteria and fungi. Bilateral chronic cicatrizing conjunctivitis (CC) and concomitant presence of nasal and oral mucous membrane impairment have suggested that this patient has a systemic disease of possible autoimmune aetiology.

The patient was referred to an ear, nose, and throat specialist for investigation of oral and nasal changes.

Biopsy of perilesional tissue of nasal mucous membrane was examined by a pathologist for histopathological and immunohistochemical analysis. Direct Immunohistochemistry revealed the presence of linear immunoglobulin deposits along basal membrane zone, which corresponds to a subtype of autoimmune bullous dermatosis - mucous membrane pemphigoid. Serological

tests, indirect immunohistochemistry and ELISA, also revealed the presence of autoantibodies. However, the autoantibodies were of unknown identity.

Ocular MMP remains one of the most difficult eye surface conditions to diagnose and manage. Appropriate treatment, when started early, can prevent devastating, irreversible blindness⁽³⁾.

In our case, we primarily optimized topical therapy for ocular surface disorders with 0,1% cyclosporine 2 times daily, 1% dexamethasone once daily, artificial tears several times a day, and 5% acetylcysteine twice daily. Following positive immunohistochemistry, we decided for systemic immunomodulatory treatment in a step ladder manner. We initiated systemic corticosteroids in combination with mycophenolate mofetil. The patient received methylprednisolone in tapering dosage, 1mg/kg. The maintaining dose of 12 mg was reached in 3 weeks. Methylprednisolone was combined with mycophenolate mofetil 1000 mg twice daily.

3 months later he showed significant improvement in nasal and oral symptoms, but there was deterioration in his ocular status - shortening of the fornices and progression of symblepharon on his right eye. His visual acuity remained unchanged.

In view of persistent inflammation, the treatment was stepped up with an intravenous cyclophosphamide 500 mg in combination with intravenous methylprednisolone 500mg.

The first two administrations of intravenous drug combination were applied in one-month interval, but management of inflammation was not sufficient. We have shortened drug administration intervals to 2 weeks and the disease slowly stabilised, with no progression in inflammation or additional scarring (Figure 3). Up to now the patient has received 11 pulses of cyclophosphamide and is still due for the last, 12th application. Afterwards, we are planning to step down with immunosuppression to a medication with less side-effects, like mycophenolate mofetil, azathioprine, methotrexate, or dapsone.

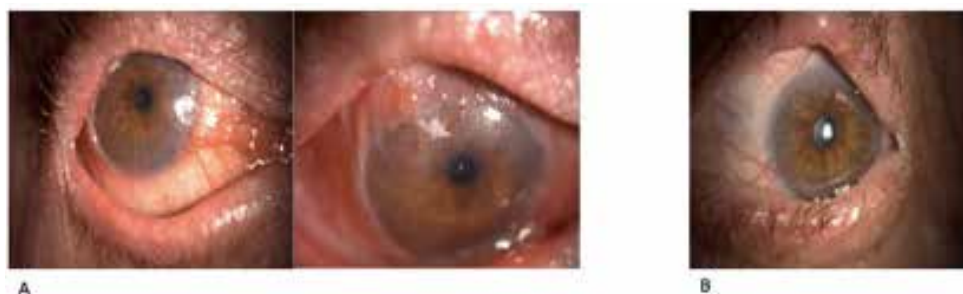

Figure 3: 3A Right eye after 11th dose of cyclophosphamide , 3B Left eye after 11th dose of cyclophosphamide

★ DISCUSSION ★

In patients with chronic, progressive, bilateral CC, it is of paramount importance to be aware of a wide differential diagnosis. Typical clinical presentation, ineffectiveness of topical treatment and exclusion of non-autoimmune causes of CC always suggest a possible systemic autoimmune disease.

On initial examination, it is firstly important to establish whether the disease is uni- or bilateral. Since unilateral progressive scarring is uncommon in MMP⁽¹³⁾, OSN and other conjunctival tumours masquerading as MMP need to be ruled out.

Sjogren syndrome and non-Sjogren dry eye are excluded by low Schirmer's 1 test⁽¹⁴⁾, which is rare in early ocular MMP⁽⁷⁾. In ocular rosacea, scarring is associated with meibomitis and papillary/follicular conjunctivitis, which is usually not present in patients with MMP⁽¹⁵⁾. Patient's history of an associated ocular condition or systemic disease suggests other common causes of CC, like pseudophthalmoid (most commonly caused by toxicity of antiglaucoma eye drops), Steven-Johnson's syndrome, and atopic keratoconjunctivitis. The differential diagnosis of MMP includes also other AIBDs, the most important being PV. They are distinguished immunohistochemically by the difference in location and pattern of DIF staining.

Patients are usually treated for more common eye diseases for years. A year before the diagnosis, our patient underwent entropion correction surgery. His problems were supposedly due to irritation of ocular surface with entropion related trichiasis. If that were the case, at least some of his problems would have been alleviated after surgery. However, on his post-operation check-up presentation the inflammation of ocular tissue was worse. Conjunctival incision surgery can cause reactivation or exacerbation of inflammation in patients with MMP⁽⁹⁾. Before any reconstructive surgery in patients with chronic bilateral CC, autoimmune diseases like MMP, have to be ruled out.

Unless all other options are unsuccessful, surgery is best avoided. When deemed vital, surgery should be carried out only when sufficient control of the disease is gained by preoperative immunosuppression.

Our patient presented with typical clinical picture and the diagnosis was confirmed with positive DIF examination. Although DIF is usually positive in patients with MMP, a considerable proportion of clinically diagnosed patients have a negative DIF result, ranging from 3-80%⁽¹¹⁾. In these, serological tests, IIF and ELISA, are used to identify the presence of serum autoantibodies. There are several identified proteins that have been shown to be target antigens in MMP, including BP180, laminin 332, BP230, α 5 β 1-integrin, laminin 311, type VII collagen and Laminin gamma1. However, certain antibodies in MMP patients cannot be identified from IIF examination⁽⁷⁾. In addition, from many different types of autoantibodies present in MMP, only 10 have been identified and entitled to specific epithelial basement membrane zone components⁽¹⁾. In our patient, IIF revealed the presence of circulating anti-basement membrane

zone autoantibodies, but we were not able to specify them with ELISAs. Although often negative in MMP, positive IIF may occasionally be diagnostic when DIF is negative⁽¹⁶⁾. Furthermore, IIF can detect the autoantibodies in patients with subclinical disease that are at risk of developing ocular manifestations in the future⁽⁷⁾.

Treatment of patients with MMP is often challenging and when diagnosed late in the course of the disease, prognosis is poor as systemic treatment has little or no effect. As topical treatment is ineffective in controlling MMP, we started immediately with systemic immunomodulatory therapy.

Usually the treatment is commenced with dapsone or sulphapyridine, and stepped-up to a more potent immunosuppressant, if ineffective⁽⁷⁾. Since our patient presented late in the course of the disease with moderate to severe form of MMP, we decided to start the treatment with more potent immunosuppressive drug mycophenolate mofetil (MMF). MMF is also one of the best tolerated, safest immunosuppressive drugs available⁽⁷⁾ and usually offers good control of inflammation. It takes up to 3 months after starting the treatment before majority of patients show some improvement⁽¹⁷⁾. However, MMF can be ineffective in controlling ocular inflammation in 9,7%, as was the case in our patient⁽¹⁸⁾.

Following no clinical improvement after 3 months of therapy, we switched MMF for a combination of intravenous immunomodulatory drugs, cyclophosphamide and corticosteroid. Cyclophosphamide is recommended as the drug of choice for severe inflammation in OMMP by all authors⁽⁷⁾. It can be administered orally or intravenously (IV). The main advantage of IV over oral administration is rapid induction in patients with severe ocular inflammatory involvement. It is also safer, as it avoids prolonged bladder exposure, thus allowing larger doses, and it induces only transient neutropenia, making intercurrent infections less likely^(7,19).

Until today the patient has received 11 doses of cyclophosphamide. At the last follow-up presentation, inflammation of ocular surface was considerably diminished, although ocular manifestations were not eradicated entirely. Complete elimination of ocular symptoms is impossible in our patient due to already developed scarring at the time of the referral to our clinic. Since systemic immunomodulatory medication can only prevent, but not reverse scarring, setting the right diagnosis early is crucial for the outcome possibilities of the patient. The patient is still due for the last, 12th application. By then, the safe cumulative dose of cyclophosphamide (6g) will be reached⁽²⁰⁾, as well as the remission of the disease. In patients with the most severe and persistent form of OMMP, CD20 monoclonal Rituximab⁽⁷⁾ or intravenous immunoglobulin therapy is the final, yet usually effective treatment option⁽²¹⁾.

It has been previously confirmed that in OMMP fibroblasts maintain profibrotic phenotype leading to progressive fibrosis, which may precipitate inflammation associated with MMP⁽²²⁾. Aldehyde dehydrogenase (ALDH) regulates this profibrotic activity and is overexpressed in OMMP. These findings provide evidence for possible use of Disulfiram by ALDH inhibition as a therapy for fibrosis in the future⁽⁷⁾.

★ CONCLUSION ★

MMP is a rare, yet debilitating disease. It is crucial to think of the diagnosis and recognize the clinical picture early on, since when left untreated it results in sight-threatening ocular surface scarring and/or blindness. Early clinical suspicion and referral for histopathological and immunological examination, are essential for prevention of irreversible ocular surface changes. Differential diagnosis and treatment protocols could lower the incidence of missed or late diagnosis and therefore enhance the disease prognosis.

★ REFERENCES ★

1. Chan LS, Ahmed AR, Anhalt GJ, Bernauer W, Cooper KD, Elder MJ et al. The first international consensus on mucous membrane pemphigoid: definition, diagnostic criteria, pathogenic factors, medical treatment, and prognostic indicators. *Arch Dermatol* 2002; 138: 370–379.
2. Hong-Hui Xu, Victoria P. Werth, Ernesta Parisi, Thomas P. Sollecito. Mucous Membrane Pemphigoid. *Dent Clin North Am.* 2013 Oct; 57(4): 611–630.
3. Dart JK, Saw VP. Immune modulation in ocular mucous membrane pemphigoid. In: Pleyer U, Alió J, Barisani-Asenbauer T, Le Hoang P, Rao NA (eds). *Immune Modulation and Anti-Inflammatory Therapy in Ocular Disorders IOIS Guidelines.* Springer: Berlin, Heidelberg, 2014, pp 19–37.
4. Williams GP, Radford C, Nightingale P, Dart JK, Rauz S. Evaluation of early and late presentation of patients with ocular mucous membrane pemphigoid to two major tertiary referral hospitals in the United Kingdom. *Eye (Lond)* 2011; 25: 1207–1218.
5. Casiglia J, Woo SB, Ahmed AR. Oral involvement in autoimmune blistering diseases. *Clin Dermatol* 2001;19(6):737–41.
6. Bernard P, Vaillant L, Labeille B, et al. Incidence and distribution of subepidermal autoimmune bullous skin diseases in three French regions. *Bullous Diseases French Study Group. Arch Dermatol* 1995; 131:48–52.
7. Dart JK. The 2016 Bowman Lecture Conjunctival curses: scarring conjunctivitis 30 years on. *Eye* (2017) 31, 301–332.
8. Hardy KM, Perry HO, Pingree GC, Kirby TJ Jr. Benign mucous membrane pemphigoid. *Arch Dermatol* 1971; 104: 467–475.
9. Elchahal S., Kavosh ER, Chu DS. Ocular Manifestations of Blistering Diseases. *Immunol Allergy Clin North Am.* 2008 Feb;28(1):119–36, vii.
10. Saw VP, Dart JK. Ocular mucous membrane pemphigoid: diagnosis and management strategies. *Ocul Surf* 2008; 6: 128–142.
11. Mary T. Labowsky, Sandra S. Stinnett, Jason Liss, Melissa Daluvou, Russell P. Hall, III, Christine Shieh. Clinical Implications of Direct Immunofluorescence (DIF) Findings in Patients with Ocular Mucous Membrane Pemphigoid. *Am J Ophthalmol.* 2017 Nov;183:48–55.
12. Neff AG, Turner M, Mutasim DF. Treatment strategies in mucous membrane pemphigoid. *Ther Clin Risk Manag.* 2008 Jun;4(3):617–26.
13. Saw VP, Dart JK, Rauz S, Ramsay A, Bunce C, Xing W et al. Immunosuppressive therapy for ocular mucous membrane pemphigoid strategies and outcomes. *Ophthalmology* 2008; 115: 253–261.
14. Sullivan BD, Crews LA, Sonmez B, de La Paz MF, Comert E, Charoenrook V et al. Clinical utility of objective tests for dry eye disease: variability over time and implications for clinical trials and disease management. *Cornea* 2012; 31: 1000–1008.
15. Alvarenga LS, Mannis MJ. Ocular Rosacea. *Ocul Surf* 2005; 3: 41–58.
16. Thorne JE, Anhalt GJ, Jabs DA. Mucous membrane pemphigoid and pseudopemphigoid. *Ophthalmology* 2004; 111: 45–52.
17. Nottage JM, Hammersmith KM, Murchison AP, Felipe AF, Penne R, Raber I. Treatment of mucous membrane pemphigoid with mycophenolate mofetil. *Cornea.* 2013 Jun;32(6):810–5
18. Ebenezer D. Et al. Mycophenolate Mofetil for Ocular Inflammation. *AM J Ophthalmol.* 2010 Mar; 149(3):423–432.e2.
19. Durrani K, Papaliodis GN, Foster CS. Pulse IV cyclophosphamide in ocular inflammatory disease: efficacy and short-term safety. *Ophthalmology* 2004; 111: 960–965.
20. Fischer-Betz R, Schneider M, Bombardieri S. Systemic Lupus Erythematosus: Treatment. In: Bijlsma JWJ ed. *Textbook on Rheumatic Diseases.* London: BMJ; 2012. p. 506–521.
21. Sacher C, Hunzelmann N. Cicatricial pemphigoid (mucous membrane pemphigoid): current and emerging therapeutic approaches. *Am J Clin Dermatol.* 2005;6 (2): 93–103.
22. Saw VP, Schmidt E, Offiah I, Galatowicz G, Zillickens D, Dart JK et al. Profibrotic phenotype of conjunctival fibroblasts from mucous membrane pemphigoid. *Am J Pathol* 2011; 178: 187–197.



Dr. Michèle TACK
Ghent University, Ghent – BELGIUM

.....

CORNEAL MELTING AND PRESUMED HERPETIC KERATITIS: THE AMBIGUOUS ROLE OF CORTICOSTEROIDS AND ANTIVIRAL PROPHYLAXIS

.....

★ INTRODUCTION ★

Herpes simplex virus (HSV) is a leading cause of infectious corneal disease. It is a frequent cause of corneal blindness in developed countries. 90% of adults are seropositive for HSV. Only 20-30% of seropositive individuals develop clinical manifestations, majority of which are herpes labialis. It is present as a latent infection in the trigeminal nerve and other sensory ganglia and causes periodic reactivation in the cornea. Relapsing and recurring episodes causes a cumulative effect and causes great morbidity through corneal scarring and neovascularization^{1,2}. Herpes simplex eye disease may manifest in different clinical forms, such as blepharitis, conjunctivitis, dendritic epithelial keratitis, neurotrophic keratopathy, immune stromal keratitis, necrotizing stromal keratitis and endothelitis, corneal ulceration, trabeculitis, episcleritis, scleritis, iridocyclitis and the acute retinal necrosis syndrome^{3,4}. Young et al estimated the incidence of HSV eye disease to 12 per 100 000 population, with increasing incidence with aging¹. Clinical evaluation, viral culture and especially PCR for Herpes viruses are important features in the diagnosis. In vivo confocal microscopy has gained popularity for diagnostic purposes in recent years due to its non-invasive

character and insight into the corneal microstructure. Epithelial findings include hyperreflective deposits and distorted and elongated epithelial cells. At the level of the deep epithelium Langerhans cells are characteristically observed. Honeycomb-shaped hyperreflective keratocytes are seen in the stroma and inflammatory cells may be seen at the level of the endothelium. Decreases in the subbasal nerve density are reported⁴.

★ CASE PRESENTATION ★

A 61-year old man was referred to our clinic and presented with a painful red eye, epiphora and blurred vision in the left eye.

The complaints started two weeks prior to presentation with bilateral injection and epithelial edema, after the prolonged wearing of soft contact lenses. The patient was treated by his own ophthalmologist with topical dexamethasone and chloramphenicol, with resolution of the clinical signs at the right eye. The left eye showed no improvement and therapy was switched to topical ofloxacin and cyclopentolate. In the medical history of this patient we withhold HIV positivity with minimal viral load (HIV-1 viral load <1/20 copies/mL), treated with highly active antiretroviral therapy (HAART) (combination of dolutegravir, abacavir and lamivudine).

BCVA was 0.9 at the right eye and counting fingers at 1 meter at the left eye. Slit lamp biomicroscopy showed a calm anterior segment in the right eye. The left eye showed a pronounced ciliary injection, inferior corneal epithelial defect, endothelial precipitates, Tyndall, anterior chamber cells 2+ and posterior synechiae (Fig. 1).

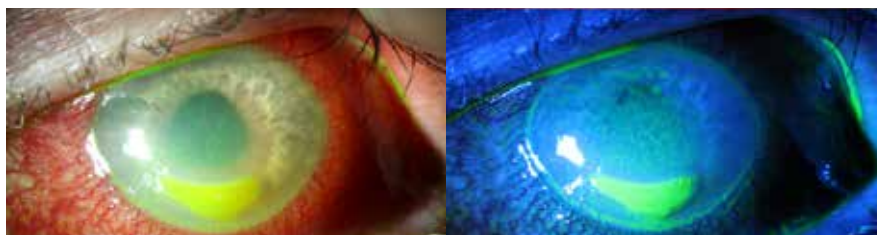


Figure 1: Slit Lamp examination of the left eye at presentation. Notice conjunctival and ciliary injection, corneal edema and oval shaped epithelial defect inferior (1mmx4mm).

A corneal swab was taken for culture and PCR. Topical moxifloxacin every hour was combined with ofloxacin gel at night and cyclopentolate twice daily. Culture remained negative and PCR came back negative for HSV1/2 and VZV two days later.

Additionally, in vivo confocal microscopy (HRT3, Heidelberg Engineering Inc., Germany) was performed and showed hyperreflective nuclei at the level of

CORNEAL MELTING AND PRESUMED HERPETIC KERATITIS: THE AMBIGUOUS ROLE OF CORTICOSTEROIDS AND ANTIVIRAL PROPHYLAXIS

the superficial epithelium and dendritic cells, suggestive for Herpes Simplex infection. There were no Acanthamoeba cysts nor fungal hyphae detected. (Fig. 2)

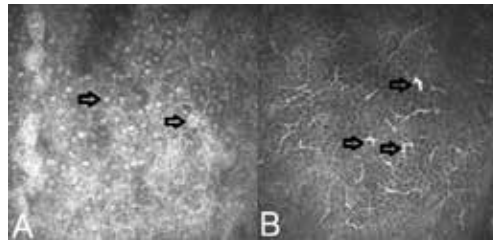


Figure 2: In vivo confocal microscopy of the left eye. A. Hyperreflective cells and nuclei at the level of the superficial epithelium. B. Increased density of Langerhans antigen presenting dendritic cells surrounding the subbasal nerve plexus. (indicated by arrows)

Therapy was switched to ganciclovir gel 5 times daily in association with topical dexamethasone and tropicamide. Evaluation one week later showed moderate clinical improvement. Signs and symptoms remained suggestive for herpetic keratitis with persistent stromal edema and stromal melting. One week later a further decrease in ciliary injection was seen, with pain reduction, less anterior chamber reaction and stromal edema. Ganciclovir gel was reduced to once daily. One week later however, our patient presented with a relapse of clinical signs. Ganciclovir gel was restarted 5 times daily in combination with topical moxifloxacin, dexamethasone and this time oral valaciclovir 500mg 3dd was added. A second corneal swab for viral PCR was performed but again came back negative. At week 4 the patient showed obvious clinical improvement and another attempt to taper therapy was initiated. Six weeks after presentation the clinical image progressed to a neurotrophic corneal ulcer with central stromal melting (Fig. 3). Therapy was switched to autologous serum 20% drops every hour, topical conservative-free ofloxacin 3 times daily, topical dexamethasone 2 times daily, atropine 1% once daily, ganciclovir gel at night and oral valaciclovir 500mg 3dd.

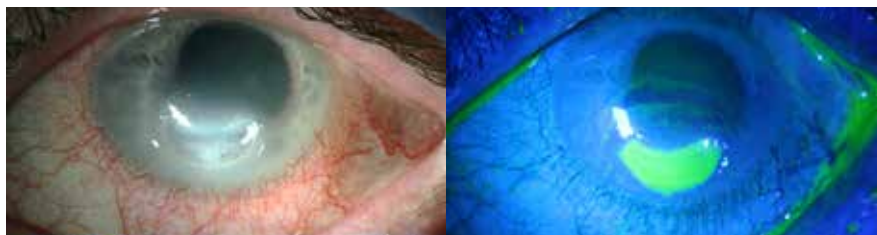


Figure 3: Slit lamp photography of the left eye 6 weeks after presentation. Notice neurotrophic ulcer with central stromal thinning.

Eight weeks after presentation inflammation declined and with further reduction of the corneal edema, an underlying descemetocoele became visible. Topical dexamethasone was stopped and oral doxycycline 100mg 2dd was associated to prevent further stromal melting (Fig 4).




Figure 4: Slit Lamp photography of the left eye. Notice Descemetocoele, visible on A. slit Lamp examination and B. anterior segment OCT.

To promote further regeneration of the extracellular matrix, Cacicol (Carboxymethylglucose sulfaat, Thea Pharma) was initiated (5 drops, 1 every other day). On consecutive anterior segment OCT (OCT SPECTRALIS, Heidelberg Engineering Inc., Germany) evaluations, a regeneration of the stromal bed could be noticed (Fig. 5).

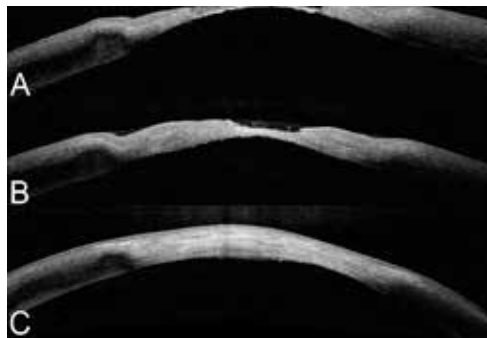


Figure 5: Anterior segment OCT images of the left eye. A. Notice descemetocoele before initiation of Cacicol. B and C. Notice regeneration of the stromal bed as a result of administration of doxycycline and Cacicol.

Eleven weeks after presentation corneal epithelium was intact, mild residual stromal thinning was present and the anterior chamber was perfectly calm (Fig. 6). Therapy could be switched to topical lubrication and fluorometholon was associated as maintenance therapy to inhibit corneal neovascularization.

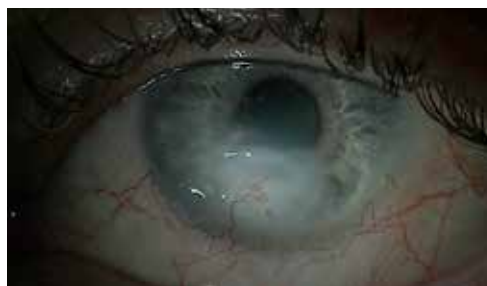

Figure 6: Slit lamp photography of the left eye 11 weeks after presentation. Notice intact corneal epithelium, regenerated stromal bed and superficial neovessel ingrowth

CORNEAL MELTING AND PRESUMED HERPETIC KERATITIS: THE AMBIGUOUS ROLE OF CORTICOSTEROIDS AND ANTIVIRAL PROPHYLAXIS

Eight months after initial presentation the BCVA in the affected eye was 0.7. Slit lamp biomicroscopy showed a calm anterior segment, intact epithelium, minimal residual stromal thinning and regression of the superficial neovascularization. Anterior segment OCT showed a restoration of the stromal bed. (Fig.7) All therapy was stopped.

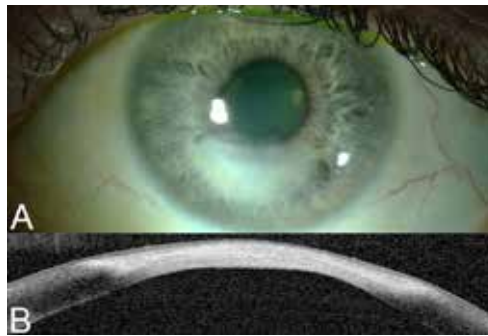


Figure 7: A. Slit Lamp photograph of the left eye 8 months after presentation. Notice the regression of the superficial neovascularization. B. Anterior segment OCT of the left eye 8 months after presentation. Notice the regenerated stromal bed with minimal residual stromal thinning.

★ DISCUSSION ★

Diagnosing and treating herpetic keratitis can be frustrating for both patient and clinician. Our case illustrates a prolonged course with slow clinical improvement and multiple relapses. Therapy had to be continuously evaluated based on the clinical image and treatment response.

Our patient was HIV positive. Although he had a minimal viral load, it is possible that this diagnosis prolonged the course of disease and made the healing process more difficult. As showed by Burcea et al., coinfection of HIV and HSV is common and these patients have a higher rate of incidence and recurrence of Herpetic keratitis.⁵

In our case, viral PCR was negative twice for HSV and VZV. Nevertheless, the clinical signs were suggestive and in addition the results of in vivo confocal microscopy pointed in the same direction, with hyperreflective nuclei at the level of the superficial epithelium and dendritic cells characteristic for HSV keratitis.⁴ Because of this, the lesion was treated as such with clinical improvement as a result.

Ganciclovir ocular gel was started 5 times daily. The effect of ganciclovir is irreversible with the HSV-infected cells. They become rapidly apoptotic and result in cell death. It also strongly inhibits viral replication in infected cells, but does not have an effect on the DNA of healthy cells, resulting in less toxicity.² In addition to topical antiviral treatment, dexamethasone was started. As shown in the Herpetic Eye Disease Study (HEDS) I, administration of topical corticosteroids results in reducing persistence or progression of stromal inflammation and shortening of the duration of HSV keratitis.⁶ At the time of the first relapse in our patient, three weeks after presentation, oral

antivirals were started. The HEDS II study found no additional benefit of oral Aciclovir in preventing HSV stromal keratitis or iritis in cases with epithelial keratitis. It did however find that prophylaxis at a low dose (400mg 2 times daily) significantly reduced recurrence rates in patients with HSV stromal keratitis.²

After reducing the inflammation, a descemetocoele became visible. Doxycycline was used in this case to prevent further stromal thinning. This antibiotic is known for its broad-spectrum approach but has additional anti-inflammatory functions due to its ability to inhibit matrix metalloproteinase (MMP) activity and both MMP and IL-1 synthesis. In ocular inflammatory surface disorders, it is administered to inhibit MMPs that have been pathologically activated and kill migratory keratocytes or fibroblasts responsible for the formation of scar tissue. It promotes complete coverage of the ocular surface with epithelial basal cells and consequentially the development of a stable, stratified epithelium.⁷

In an attempt to enhance stromal regeneration, topical Cacicol was administered. Cacicol is a tissue regenerating agent (RGTA) that mimics the action of destroyed heparin-sulfate and creates a matrix microenvironment where cells can migrate and multiply. These agents break down the negative repair-destruction cycle occurring in chronic lesions, have an antifibrotic effect through decrease in collagen III synthesis and improvement in collagen reorganization, and inhibit proteolytic enzymes *in vitro*.⁸

In the end, low dose topical steroids, fluorometholon, were used as a maintenance therapy to reduce remaining ocular surface inflammation and prevent excessive corneal neovascularization.

★ CONCLUSION ★

Herpes Simplex ocular infections are a major cause of visual morbidity. Patients infected with Herpes keratitis should have a close follow-up to avoid complications and recurrences.

Our patient, a 61-year old HIV+ soft contact lens wearer, showed a clinical picture very suggestive for herpetic keratitis but viral PCR was negative twice. The lesion was nevertheless treated as herpetic keratitis, since *in vivo* confocal microscopy was also suggestive. Since the patient was also HIV positive, it is possible that this was the main triggering factor for the development of the lesion and the flare-up, although the viral load was well controlled (<1/20 copies/mL) with HAART therapy. In our opinion, the keratitis was not associated with soft contact lens wear.

CORNEAL MELTING AND PRESUMED HERPETIC KERATITIS: THE AMBIGUOUS ROLE OF CORTICOSTEROIDS AND ANTIVIRAL PROPHYLAXIS

Multiple pitfalls were encountered during the treatment of this patient. While tapering medication, a relapse was seen and the clinicians in this case had to contend with a difficult balance between viral activity and therapeutic toxicity, as a descemetocele became visible after reducing the stromal inflammation.

Treatment of Herpetic keratitis should be combined with ocular surface regeneration. Administration of doxycycline orally and topical autologous serum and Cicicol led to a fast recovery of the stromal bed in our patient. Serial anterior segment imaging allowed the clinicians to evaluate the response to therapy. Low dose steroids were finally administered as maintenance therapy, by which the patient became in remission.

★ REFERENCES ★

1. Young RC, Hodge DO, Liesegang TJ, et al. The incidence, recurrence and outcomes of Herpes Simplex Eye Disease in Olmsted County, Minnesota, 1976 through 2007: The impact of oral antiviral prophylaxis. *Arch Ophthalmol.* 2010 Sept; 128(9): 1178–1183.
2. Tsatsos M, MacGregor Ch, Athanasiadis I, et al. Herpes Simplex virus keratitis: an update of the pathogenesis and current treatment with oral and topical antiviral agents. *Clinical and experimental Ophthalmology.* 2016; 44: 824-837.
3. Avinish Mishra LC, Luthra S, Baranwal CV. Corneal ulcer? Think beyond only a bacterial etiology. *Medical Journal Armed Forces India.* 2016; 71:85-87.
4. Yokogawa H, Kobayashi A, Mori N, Sugiyama K. Mapping of dendritic lesions in patients with herpes simplex keratitis using in vivo confocal microscopy. *Journal of clinical ophthalmology.* 2015 Sept. 2015(9):1771-1777.
5. Burcea M, Gheorghe A, Pop M. Incidence of Herpes Simplex Virus Keratitis in HIV/AIDS patients compared with the general population. *Journal of Medicine and Life.* 2015 Jan-Mar; 1(8):62-63.
6. Wilhelmus KR, Gee L, Hauck WW, et al. Herpetic Eye Disease Study. A controlled trial of topical corticosteroids for herpes simplex stromal keratitis. *Ophthalmology.* 1994 Dec; 101(12): 1883-95; discussion 1895-6.
7. Smith VA, Cook SD. Doxycycline – a role in ocular surface repair. *Br J Ophthalmol.* 2001; 88:619-625.
8. Alfa A, Gueudry J, Portmann A, et al. Topical treatment with a new matrix therapy agent (RGTA) for the treatment of corneal neurotrophic ulcers. *Invest Ophthalmol Vis Sci.* 2012 Dec 13;53(13):8181-5.



Dr. Liudmyła TROICHENKO
Odessa State Medical University, Odessa – UKRAINE

.....

COMBINED TREATMENT OF RECURRENT STROMAL HERPETIC KERATITIS WITH ULCERATION

.....

★ INTRODUCTION ★

Herpetic keratitis (HK) is a serious ophthalmological pathology and makes from 20 to 50% among inflammatory diseases of the cornea^[1].

Most often the eye is affected by the herpes simplex virus type 1. Primary lesions are more superficial, recurrences of herpetic keratitis are more often stromal. Frequently, HK occurs after acute respiratory viral infections of the body (45.5%), traumatic corneal lesions (26.8%), stressful situations (22.5%), and contact correction (3.4%)^[2].

The study of the problem of ophthalmoherpes with the development of new methods of treatment is an urgent problem in ophthalmology, since the clinical course of keratitis is marked by duration, severity and tendency to recurrence.

★ CASE PRESENTATION ★

From 2015 to the present the patient D.54 was followed up with the diagnosis: a syndrome of the dry eye of moderate severity, presbyopia in both eyes. The vascularized opacity of the cornea, stromal herpetic recurrent keratitis was in the left eye.

Prior to admission to our clinic, the patient has been experiencing recurrence of viral keratitis for 10 years. The treatment was carried out at the place of residence without using etiotropic and anti-inflammatory drugs on a full scale. In 2015 recurrences of keratitis increased (up to 3 recurrences per year) and the patient referred to our department for medical aid.

On admission a deep vascularized opacification of the cornea was observed in the optic and paraoptic part of the cornea on the affected eye. When staining with fluorescein, erosion of the cornea of 2/3 mm was found. On admission uncorrected visual acuity was 0.2. The Schirmer test was 6.0 mm. The Norn test was 7 seconds (Fig. 1)

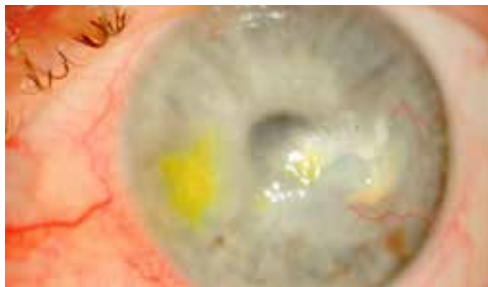


Figure 1: Vascularized opacity of the cornea. Erosion of the cornea.

On microbiological examination pathological flora was not detected in the conjunctival cavity. The patient, in addition to general ophthalmological studies, was also performed rheophthalmography (ROG) and rheoencephalography (REG), an immunogram with the detection of sensitization to herpes antigens. It was found that the volume pulse blood filling by the RQ index was by 37,2% lower compared to the paired eye, the tonic properties of the small vessels increased by 23,4 % and the velocity of the volumetric blood flow was reduced by 40,1%. The immunograms showed an increase in the lymphocyte count, a decrease in the T cell concentration and natural killers, with sensitization to antigens of the herpes and cornea of the eye.

When giving antiviral etiotropic, anti-inflammatory and a neurotrophic treatment, the recurrence of keratitis was controlled. The surface of the cornea was epithelialized, not stained with fluorescein. The visual acuity increased to 0.6 (Fig.2).

COMBINED TREATMENT OF RECURRENT STROMAL HERPETIC KERATITIS WITH ULCERATION

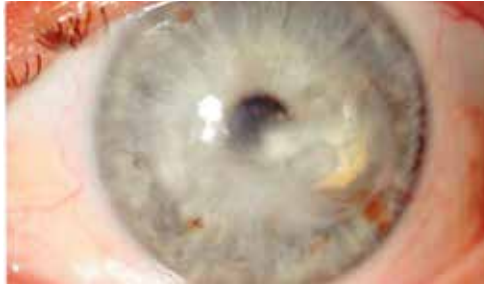

Figure 2: Residual vascularized opacity of the cornea.

For 1.5 years until 2017 the patient received a supportive, tear substitutive and neurotrophic treatment. He regularly came for control examination, recurrence of viral keratitis was not observed. Visual acuity throughout the period was 0.5-0.6.

07.2017. After suffering an acute respiratory viral disease and a severe stressful situation, the patient's condition deteriorated sharply. There was a recurrence of herpetic keratitis with ulceration of the cornea (Fig.3).

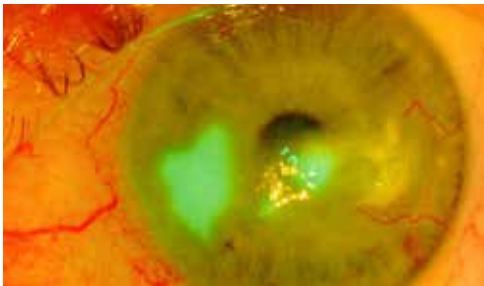


Figure 3: Vascularized corneal opacity. Corneal ulcer.

Uncorrected visual acuity was 0.1. There was expressed pain syndrome.

A microbiological study of the contents of the conjunctival cavity revealed staphylococcus epidermidis at a concentration of $<10^2$.

Despite the anti-viral etiologic and anti-inflammatory conservative treatment, the patient's condition has improved insignificantly. There was a defect in the surface of the cornea and active vascularization along the periphery (Fig.4).

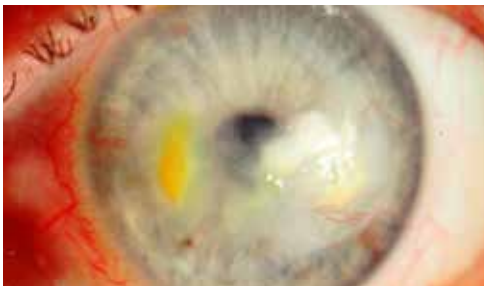


Figure 4: Vascularized corneal opacity. Erosion of the cornea.

The patient underwent surgery - transplantation of the cryopreserved amniotic membrane (TAM) by the method of the biological covering (onlay technique) with episcleral fixation and conjunctiva plasty. A therapeutic contact lens was applied (Fig.5).

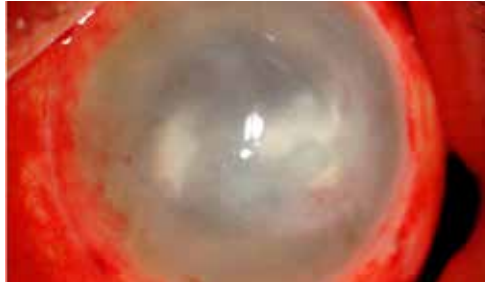

Figure 5: Condition after amnion plastic surgery. Complete coverage of the surface of the cornea by amnion. Therapeutic contact lens.

During the operation, the one layer of cryopreserved amnion was used.

On the third day of the postoperative period, the pain syndrome was stopped, conservative etiotropic and anti-inflammatory treatment was continued. 1.5 months after TAM, the amnion partially resolved on the surface of the cornea. The surface of the cornea was epithelialized, the fluorescein test was negative. The vessels on the corneal surface started to regress. The visual acuity increased up to 0.3 (Fig.6)

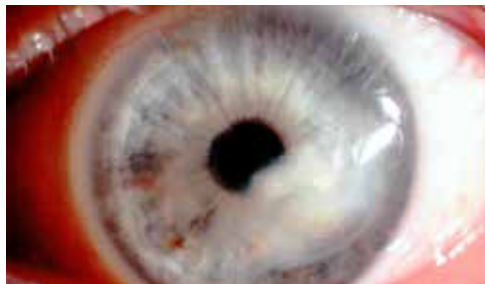

Figure 6: Remnants of the amniotic membrane on the surface of the cornea. Peripheral opacification.

Complete resolution of the amnion, smoothing of the corneal surface, negative fluorescein test were recorded in 3 months after the operation. Pathological flora on the surface of the cornea was not revealed. Vessels on the surface of the cornea became partially emptied. The Schirmer test increased to 10.0 mm, the Norn test - to 12 seconds. Visual acuity increased to 0.5 (Fig.7).

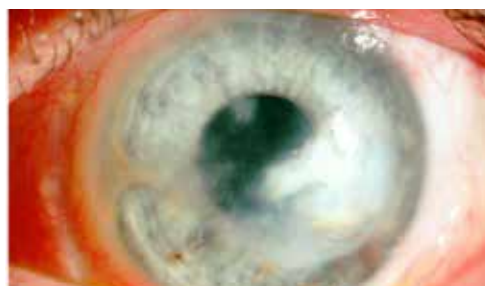

Figure 7: Peripheral opacity of the cornea with partially empty vessels.

COMBINED TREATMENT OF RECURRENT STROMAL HERPETIC KERATITIS WITH ULCERATION

The patient received systemic antiviral and anti-inflammatory treatment in the postoperative period for 5 months. Locally he received the instillations of antiseptics, human recombinant interferon, hormones, vitamins, preservative-free tear drops with trehalose.

The parameters of immunology improved, volume pulse blood filling increased according to RQ to normal age indices, the tonic properties of the small vessels decreased by 20% and the speed of volumetric orbital flow increased by 30%. Visual acuity was 0.5.

In 6 months, the patient underwent anti-recurrence vaccination with the Vaccine herpes according to the individual scheme.

In a year after TAM and given etiotropic treatment, complete epithelization of the corneal surface, regress of pathological vascularization and decrease of the corneal opacity area was registered. The visual acuity increased to 0.6 (Fig. 8).

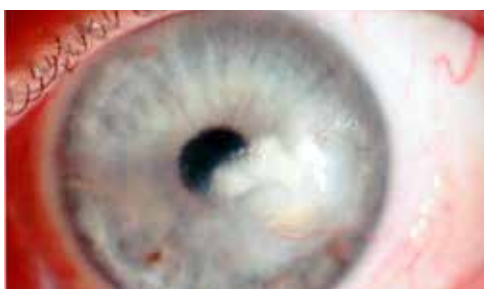

Figure 8 Peripheral opacification of the cornea.

Currently, the patient receives a tear-substitutive therapy (preservative-free drops with trehalose) and neurotrophic treatment in the form of instillations and tableted forms.

The visual acuity remains 0.6D.

★ DISCUSSION ★

At present, the treatment of herpetic infection of the eyes remains a challenge in ophthalmology. Numerous preparations of etiotropic and immunocorrective action have been proposed for the treatment of herpetic diseases, taking into account the etiology, pathogenesis and clinical symptoms. Antiherpetic drugs are divided into 3 groups by the mechanism of action: chemodrugs, specific immunocorrectors, nonspecific immunocorrectors^[2,3,4,5,6].

One of the leading places in the complex antiviral therapy is taken by the new generation of drugs - the interferon inducers - drugs (amixin, neovic,

cycloferon), successfully combining etiotropic and immunomodulatory effects of the action. The drugs induce the formation of endogenous interferons by T- and B-lymphocytes, enterocytes, hepatocytes^[7].

Specific methods are currently used (herpetic vaccine, herpetic immunoglobulin) for ophthalmoherpetic immunotherapy as well as nonspecific immunotherapy (interferons and their inducers, cytokines, vitamin complexes, microelements, etc.). Additionally, tear-substitutive drops, preferably without preservatives are used^[8].

All of the above groups of drugs were used in the complex treatment of our patient.

In the recurrence of herpetic keratitis and the formation of a long-lasting non-epithelializing defect on the cornea, our attention was turned to one of the important new directions in the surgery of the ocular surface - amniotic membrane (AM) transplantation.

Although AM was first used in ophthalmology more than 70 years ago, the widespread use of transplantation of the amniotic membrane (TAM) in patients began in 1995 and showed high results^[9]. Therapeutic keratoplasty using amnion and other plastic materials of long-term storage became more widespread^[10-11].

The most important indications for TAM in reconstructive surgery of the eye surface are persistent defects in the epithelium of the cornea with ulceration of various etiologies^[12,13].

Clinical studies show that AM transplantation assists in epithelialization and differentiation of the epithelium of the eye surface [12-15]. The most important growth factors that promote wound healing were isolated mainly from the amniotic epithelium as well as from the stroma, they are the epidermal and keratocyte growth factor^[14,15].

There are several surgical techniques for using AM. We used the onlay or patch technique. The classical indications for this technique vary from acute burns to acute herpetic keratitis and the acute stage of Stevens-Johnson syndrome. [12,16,17,18] The AM properties are used, in particular, its anti-inflammatory effect, which acts for a limited time^[15,19].

When using the onlay, a large area of AM is temporarily located on the surface of the eye, as a biological covering^[12].

In our clinical case, AM successfully performed its anti-inflammatory and epithelial effects and partially resolved in 1.5 months. Three months after surgery, AM completely resolved, which was accompanied not only by the epithelialization of the surface of the cornea but also by the partial emptying of newly formed vessels.

In the postoperative period our patient underwent herpetic vaccination with the selection of an individual dosage in the phase of remission.

In antiherpes virus therapy, the herpetic vaccine is used to activate cellular immunity, its immunocorrection in the phase of remission. Vaccination has two objectives: prevention of primary infection and the onset of latency as well as a prevention or milder course of the disease. The principle of anti-recurrence therapy of herpetic vaccine is based on the principle of specific immunocorrection through the systemic course of herpetic vaccine in combination with the instillation of interferons or interferonogens^[2,20,21,22].

★ CONCLUSION ★

A clinical case of combined treatment of recurrent stromal herpetic lesions of the cornea with ulceration is presented. The effectiveness of the application of a complex conservative etiotropic, anti-inflammatory, neurotrophic treatment, anti-relapse vaccination and surgical intervention-TAM by the method of overlay is shown. In a year after surgery the patient has no pain syndrome, the corneal surface is epithelialized, and recurrence of herpetic keratitis was not observed. Thus, the combined treatment presented here is effective in severe cases of long-term recurrent herpetic keratitis with a defect on the surface of the cornea.

★ REFERENCES ★

1. Anina E.I. Pathology of the cornea of the eyes among the adult population of Ukraine / E.I. Anina, KV. Martoplyas // The 12th Conference of the Ophthalmologists of Ukraine, 26-28 May, 2010 : materials of the conference. - Odessa, 2010. - p. 5.
2. Kasparov A.A. Treatment of herpesvirus keratitis: 35 years of experience / A.A. Kasparov // New technologies in the treatment of cornea diseases: ALL-Russian scientific and practical conference with international participation. Fedorov's readings, June 25-26, 2004: Col. sci. articles. - M., 2004. - P. 574-580.
3. Dembsky L.K. Some aspects of the organization of treatment of viral keratitis / L.K. Dembsky, O.N. Shirshova, O.V. Mironyuk // Surgical treatment and rehabilitation of patients with ophthalmologic pathology: Sciences.-pract. Conf. with international participation, 2004 p. :theses of the reports. - K., 2004. - P. 99-100.
4. Kasparov A.A. Treatment of herpesvirus keratitis / A. A. Kasparov // Urgent problems of herpesvirus infections. - M., 2004. - P. 31-37.
5. Kasparov A.A. Modern methods of treatment of herpesvirus keratitis // Scientific-practical. conference "Modern methods of diagnosis and treatment of diseases of the cornea and sclera": theses of reports. - M. 2007. - P. 273 - 276.
6. Kaye S. Herpes simplex keratitis / S. Kaye, A. Choudhary // Progress in retinal and eye research. - 2006. - Vol. 25. - No. 4. - P. 355-380.
7. Approaches to immunocorrective therapy in ophthalmology from the perspective of new ideas about congenital immunity. / Kovalchuk L.V., Gankovskaya L.V., Martirosova N.I. [et al.] // Refract. surgery and ophthalmology. - 2008. - No. 1. - P. 4-48.
8. Pozdnyakov V.I. Algorithm for the treatment of severe forms of ophthalmoherpes / V.I. Pozdnyakov, Yu. F. Maichuk, V.V. Pozdnyakova // Urgent questions of inflammatory eye diseases: scientific and practical conference November 20-21, 2001: conference materials. - M., 2001. - P. 151-153.
9. Kim J.C., Tseng S.C.: Transplantation of preserved human amniotic membrane for surface reconstruction in severely damaged rabbit corneas. *Cornea* 1995; 14: 473-84.
10. Trufanov S.V. Use of the conserved amniotic membrane of a man in reconstructive surgery of the eye. Author's Diss. Cand.med. sciences. M.: 2004; - 24 pp.
11. Fedorova E.A. The use of lyophilized amniotic membrane in the treatment of inflammatory diseases of the cornea. Author's Diss. Cand. med. sciences. M.: 2004; - 24 pp.
12. Seitz B: Amniotic membrane transplantation. An indispensable therapy option for persistent corneal epithelial defects. *Ophthalmologe* 2007; 104: 1075-9.
13. Short AJ, Secker GA, Notara MD, et al.: Transplantation of ex vivo cultured limbal epithelial stem cells: a review of techniques and clinical results. *Surv Ophthalmol* 2007; 52: 483-502.
14. Koizumi N.J., Inatomi T.J., Sotozono C.J., Fullwood N.J, Quantock A.J., Kinoshita S.: Growth factor mRNA and protein in preserved human amniotic membrane. *Curr Eye Res* 2000; 20: 173-7.
15. Tseng S.C., Espana E.M., Kawakita T, et al.: How does amniotic membrane work? *Ocul Surf* 2004; 2: 177-87.
16. Sippel K.C., Ma J.J., Foster C.S.: Amniotic membrane surgery. *Curr Opin Ophthalmol* 2001; 12: 269-81.
17. Ueta M, Kweon M.N, Sano Y, et al.: Immunosuppressive properties of human amniotic membrane for mixed lymphocyte reaction. *Clinical and Experimental Immunology* 2002; 129: 464-70.
18. Kheirkhah A, Johnson D.A., Paranjpe D.R., Raju V.K., Casas V, Tseng S.C.: Temporary sutureless amniotic membrane patch for acute alkaline burns. *Arch Ophthalmol* 2008; 126: 1059-66.
19. Thomasen H, Pauklin M, Steuhl K.P., Meller D: Comparison of cryopreserved and air-dried human amniotic membrane for ophthalmologic applications. *Graefes Arch Clin Exp Ophthalmol* 2009; 247: 1691-700.
20. The mechanism of the therapeutic effect of herpetic polyvaccine in chronic ophthalmoherpes and genital herpes / I.F. Barinsky, L.G. Karpovich, E.I. Gubanova et al // Problems of virology. - 2000. - No. 1. - P. 30-33.
21. The significance of focal allergic test with herpetic vaccine in the diagnosis of intraocular herpes / A.A. Kasparov, O. K. Vorobyeva, I.V. Belkina et al // Bulletin. Of ophthalmology. - 1998. - №1. - P. 17-21.
22. Kasparov A.A. Modern methods of treatment of severe corneal infectious diseases / A.A. Kasparov // The 9th congress of ophthalmologists of Russia, June 16-18, 2010: abstracts. - M., 2010. - P. 296-298.



Dr. Päivi VARONEN
FINLAND

.....
VERNAL KERATOCONJUNCTIVITIS
- WOLF IN SHEEP'S CLOTHING
.....

★ INTRODUCTION ★

This is a case report of a young girl with severe allergic symptoms in her eyes, numerous relapses of inflammatory eye disease and sight threatening complications.

★ CASE PRESENTATION ★

5 year old girl, previously diagnosed celiac disease, otherwise healthy. 2/2010 keratitis was diagnosed in her right eye with one suspected bacterial focus at 5 o'clock with an epithelial defect and severe conjunctival hyperemia. Symptoms included redness, pain and photophobia. She was treated with levofloxacin eye drops and chloramphenicol ointment.

3/2010 epithelium was healed, but there was stromal keratitis present with peripheral corneal vascularization at 4-6 o'clock.

Mild topical steroid (in this case hydrocortisone) was added to treatment. Symptoms started to ease, stromal scar at five o'clock and corneal vascularization remained. Antibiotics were discontinued. 16.3. eye was white, no symptoms, topical hydrocortisone and chloramphenicol were discontinued, no monitoring thought to be needed. VA was 0.5/0.6 before and after the treatment. Bacterial culture was answered negative.

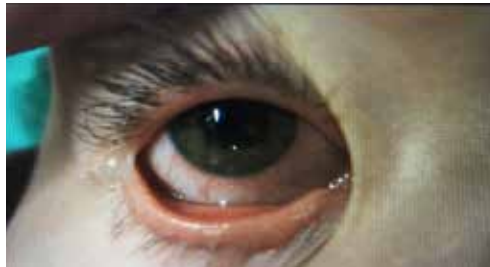

Figure 1: Right eye (unfortunately corneal vascularization is not visible in the picture)

8/2010 again redness, photophobia and now also mucoid discharge. Symptoms were severe. There was conjunctival hyperemia but corneal epithelium was intact, old stromal focus and corneal vascularization seemed to be active again. Again treated with levofloxacin and chloramphenicol. After 5 days epithelial defect and also more active limbal vascularization were now present, and there was microcystic corneal oedema nasally. Dexamethasone eye drops were added to treatment. Again situation got better, two small hordeolums appeared on the upper lid but symptoms eased. 14.9. only artificial tears were left as treatment, status was similar to 16.3.

1/2011 fourth episode. Symptoms and findings were similar to those before, but also conjunctival chemosis occurred with papillary reaction on the palpebral conjunctiva (previously there were no mentioning about tarsal conjunctival findings) and there was mild iritis with corneal punctate epitheliopathy. Levofloxacin and dexamethasone eye drops were started. Bacterial culture, herpes- and adenovirus-PCR were negative. Again topical steroid did its job and inflammation eased.

2-5/2011 right lower lid chalazion got bigger and infected. Additionally corneal erosion occurred with severe symptoms and mild iritis. Topical antibiotics and mydriatics were started as treatment, but inferior corneal oedema occurred. 6/2011 surgical treatment of chalazion treated the inflammation effectively and soon the monitoring could be discontinued.

10/2011 sixth episode. Again severe inflammation and symptoms in the right eye, strong blepharospasm. VA ?/0.32. Right eye is severely hyperemic, there is corneal vascularization 360 degrees and clear cornea only centrally, two new ulcerations have occurred. Papillary cobblestone-like reaction on the palpebral conjunctiva is present. Now left eye also presents thin corneal neovascularization in the periphery, but no other signs of inflammation. Immune-related keratitis is suspected, chloramphenicol and hydrocortisone

**VERNAL KERATOCONJUNCTIVITIS
- WOLF IN SHEEP'S CLOTHING**

eye drops are started o.a. Things get better, VA is now 0.25/0.5. Bacterial and chlamydia cultures, herpes-PCR, cytologic samples and biopsy from conjunctiva are taken in anesthesia. Tests are negative, the disease seems to be non-infectious. PAD shows chronic allergic inflammation, limbal vernal keratoconjunctivitis is given as the most likely diagnosis. Mild topical steroid is started (in this case fluorometholone 1x2 o.a.) Pediatricists find no systemic autoimmune disease.

Monitoring was now discontinued because patient didn't show up on doctor's appointments, obviously there were little or no symptoms. One relapse occurred 3/2012 after discontinuing topical steroid, which was started again with mast-cell stabilizers. It appeared that symptoms were often worse at springtime. Because of poor VA 0.2/0.4 and corneal vascularization and clouding (mainly in right eye), patient was sent to Helsinki University Hospital to see corneal specialist for second opinion and treatment. 11/2012 cyclosporine eye drops were started to treat vernal keratoconjunctivitis, first with concomitant topical fluorometholone, mast-cell stabilizer and artificial tears.

1/2013 VA was 0.32/0.63, tarsal conjunctival papillae and scarring present especially in the right eye, several old scars in both corneas, predominantly in the right eye. There was corneal vascularization 360 degrees in the right eye and superior pannus in the left eye.

2/2013 tarsal papillary inflammation is gone, 8-year-old patient has no symptoms. Pediatricists found no allergies. No relapses occur during follow-up. Topical cyclosporine is continued as maintenance treatment.

3/2015 topical cyclosporine was discontinued by the patient due side effects (hyperemia and burning). Fluorometholone dose was therefore increased to 1x3, then decreased step by step until discontinued 12/2015, when VA was 0.5/0.5, eyes looked good, and only corneal neovascularization and scars were present as a reminder of the unfortunate history of ocular disease. 2/2016 and in the age of 12 years, situation was still good with no medications, and again monitoring was discontinued because patient stopped showing up on doctor's appointments.

Surprisingly it took over two and a half years before history remembered to repeat itself. 17.9.2018 left eye brings our 14-year-old patient back to an ophthalmologist. Until now, no symptoms, VA good, no glasses needed said her private ophthalmologist a year ago. But this year when school started, eyes have been red and watery and photophobic especially after school days, and symptoms start only after few hours at school. Artificial tears and antiallergic drops give little help. Mum says there's mold at school and other kids have symptoms too, four kids changed school last year. Our patient is at school 3 days and home-schooling 2 days a week to ease the symptoms. Eyes are always better at home, and a week off from school eyes feel almost healthy. Now she's seeing an ophthalmologist because her left eye suddenly got dramatically worse. Otherwise status is the same as 2016

when discontinuing treatments, but left eye is now red and there's central epithelial defect on the cornea. This time right eye only has one chalazion on the lower lid. VA 0.5/0.2.

Because epithelial defect looks like a harmless mechanical erosion, chloramphenicol is started as prophylaxis. But epithelial defect and symptoms remain, and levofloxacin doesn't do any better. A week later there's a central chronic looking clouding on the left cornea with oval shaped ulcer centrally. VA is 0.4/0.16. Finally epithelium is healed with 3 days intensive treatment with thick chloramphenicol ointment and an eye patch, and symptoms ease. Central clouding and scar 1mm x 1.5mm and mild thinning of the cornea are still present. Chloramphenicol and topical hydrocortisone are continued.

18.10.2018 topical tacrolimus 0.1% 1x2 o.a. is started with artificial tears and for starters with concomitant topical hydrocortisone. VA is 0.5/0.2. Close monitoring is continued.

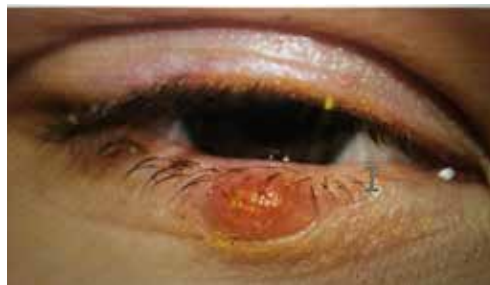

Figure 2: Right eye

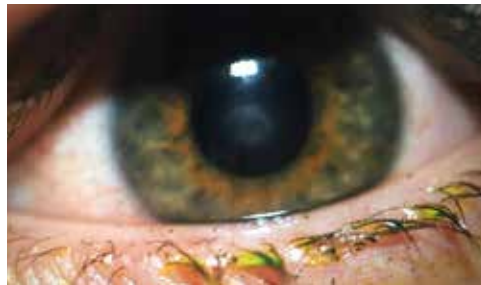

Figure 3: Left eye (corneal vascularization not visible)

★ DISCUSSION ★

Vernal keratoconjunctivitis is usually a seasonal (vernal - springtime) recurring inflammation of cornea and conjunctiva that occurs predominantly in male children, and tends to abate in the mid to late teens. Often family history of atopy is present. Immunopathogenesis involves type I and type IV immunology reactions.

Symptoms include itching, burning, photophobia, blepharospasm, blurred vision, mucoid discharge and pseudoptosis.

Palpebral VKC: papillary hypertrophy, hyperemia, chemosis, sometimes giant papillae resembling cobblestones usually on the upper lid.

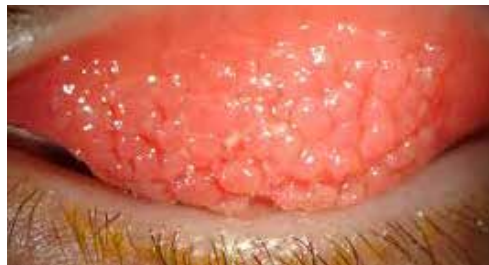

Figure 4: upper lid papillae

Limbal VKC: Limbal thickening, gelatinous membrane and vascular injection, Horner-Trantas dots consisting of eosinophils and epithelial cells may be present in limbus.

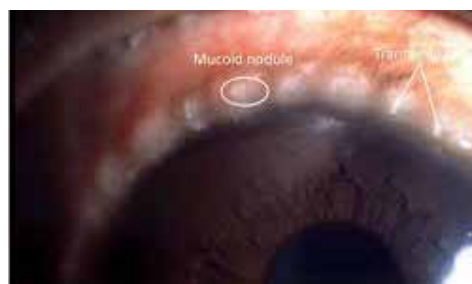

Figure 5: Limbal Vernal

Corneal changes include punctate epithelial erosions, superior pannus, non-infectious epithelial ulcers (often oval or shield-shaped) and sometimes 360 degrees corneal vascularization. Keratopathy is usually associated with upper tarsal lesions and therefore keratopathic changes are often primarily found in the superior cornea.

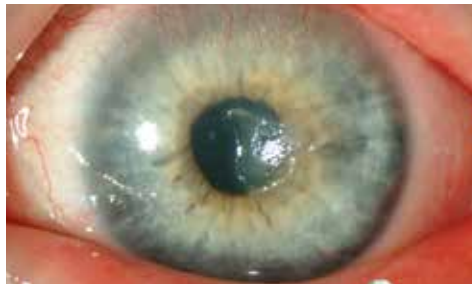

Figure 6: Superior pannus and shield ulcer

Treatment depends on the severity of disease:

- 1) topical antihistamines and mast-cell stabilizers
- 2) topical corticosteroids
- 3) topical immunomodulatory agents (cyclosporine, tacrolimus).

Topical tacrolimus is a relatively new agent treating refractory allergic eye diseases. It seems to be effective treating palpebral VKC and also keratopathic changes. Tacrolimus may be effective when topical steroids and cyclosporines have been insufficient. It may work as steroid-reducing or even steroid-replacing therapy. Careful monitoring is needed, because while transient burning sensation being its major side effect, use of topical tacrolimus also somewhat seems to increase the risk of infectious keratitis (herpetic or bacterial).

Were the parents aware of the potential vision-threatening complications of the disease, or did their kid just have some allergic inflammation in her eyes that sometimes got better and sometimes got worse? Where the parents properly informed of the nature of the disease? Did they (and doctors) understand the importance of careful monitoring? Should the treatment with an anti-inflammatory agent have been started earlier? Would maintenance treatment (without interruptions) with mild topical steroids and/or antiallergic agents have prevented some of the relapses and thus corneal changes causing worsening of vision? What should be done with school, and what will happen with the driving license after four more years pass?

★ CONCLUSION ★

VKC is a potentially sight threatening inflammatory eye disease that needs regular monitoring by an ophthalmologist to prevent non-reversible corneal changes that are associated with tarsal hypertrophic lesions. Treating palpebral disease is crucial.

Topical steroids are effective when antihistamines and mast-cell stabilizers are insufficient, but have side effects (cataract, glaucoma) in long term use, of course dependent of the dose and how potential the steroid is. Here come topical immunomodulatory agents the picture, cyclosporines that have been used for long and tacrolimus that is a newer alternative and seems to be effective sometimes even when treatment with topical steroids and cyclosporines is insufficient.

★ REFERENCES ★

American Academy of Ophthalmology: BCSC 2015-16. External Disease and Cornea. Chapter 7 Clinical Approach to Immune-Related Disorders of the External Eye: 187-91.

Fukushima A, Yuichi O, Nobuyuki E, et al. Therapeutic effects of 0.1% tacrolimus eye drops for refractory allergic ocular diseases with proliferative lesion or corneal involvement. BJO Online First. 10.1136/bjophthalmol-2013-304453.



Dr. Maja VLADISAVLJEVIĆ LJUBAS
General Hospital, Slavonski Brod – CROATIA

.....

TRANSPLANTATION OF AMNIOTIC MEMBRANE AND LIMBAL AUTOGRAFT FOR PATIENTS WITH RECURRENT PTERYGIUM

.....

★INTRODUCTION★

Although many surgical approaches have been developed, recurrent pterygium presents a significant surgical problem.

Amniotic membrane has been used as a surgical material since the 1940s, and the membrane has been shown to have a strong antiadhesive effect. Amniotic membrane has a thick collagen layer and an overlying basement membrane with a single layer of epithelium.

The use of amniotic membranes has been suggested as a replacement for a function substrate, as the presence of normal substrate is essential for normal proliferation and differentiation of epithelial cells. This is also true in the cornea, since the corneal epithelium and underlying stromal cells have been shown to interact intimately through various cytokines.⁽¹⁾

Human amniotic membrane has been used in the management of ocular surface diseases. The usefulness of amniotic membrane has been attributed to its anti-inflammatory, anti-fibrotic, and anti-vascularization effects and also to its ability to enhance epithelial healing.

★ CASE PRESENTATION ★

The patients underwent placement of amniotic membrane and limbal autograft transplantation after excision of pterygia. Two of three patients were with recurrent pterygium and one was with pseudopterygium lateral and medial side.

Human amniotic membrane was obtained at caesarean section and preserved until surgery. After excision of the pterygium and placement of conjunctival autograft the amniotic membrane was placed on the sclera and cornea, and a limbal autograft transplantation was performed using limbal tissues taken from the affected eye.

In this study, a novel surgical technique for amniotic membran transplantation (AMT) with a simple limbal epithelial transplantation (SLET) is described in cases of treating recurrent pterygium.

SLET and AMT (Simple limbal epithelial transplantation and amniotic membrane transplantation)

The surgical technique is shown in detail in video 1, Fig. 1, and Fig.2.

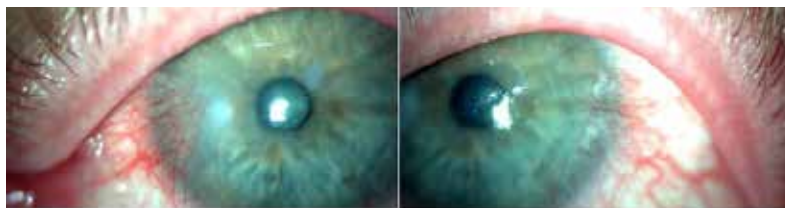

Figure 1: Before treatment (pseudopterygium, nasal and temporal side)

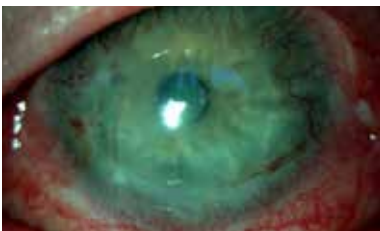

Figure 1: 7 days after operation

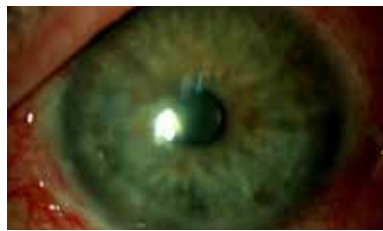

Figure 1: 1 month after operation

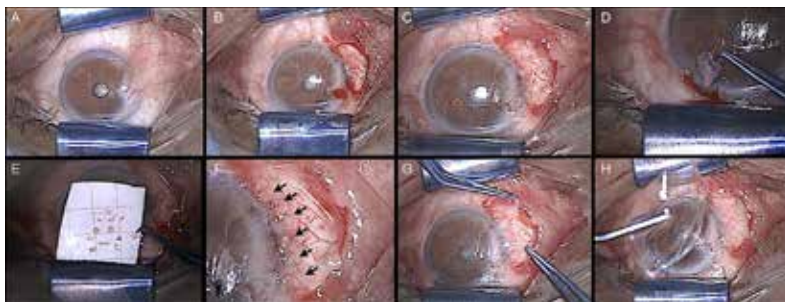


Figure 2: (A) Nasal, temporal or bilateral pterygium are adequate candidates. (B) Resection of pterygium and excess of Tenon's with conventional techniques leaving bare sclera. (C) Placement of the first amniotic membrane. (D) Resection epithelial limbal stem cells graft of 2×2 mm. (E) Slicing of epithelial limbal strip into 8–10 pieces. (F) Alignment of small limbal pieces (arrowheads) close to the limbal area over the amniotic membrane. (G) Placement of a second amniotic membrane covering the small limbal transplants. (H) Placement of a soft contact lens.

TRANSPLANTATION OF AMNIOTIC MEMBRANE AND LIMBAL AUTOGRAFT FOR PATIENTS WITH RECURRENT PTERYGIUM

The eye operated is disinfected and covered according routine protocol.

After adequate local anesthesia the leading edge of the pterygium is dried, instilling alcohol 20% into the well and holding for 40-60 seconds. Absorbing alcohol by applicator and abundant irrigation with BSS.

Pterygium separation starting 2 mm centrally from the edges of the tissue. Excising the pterygium tissue at the base. After that a 2×2 mm area was marked centred on the superior limbus, the conjunctiva was incised, and a sub-conjunctival dissection was carried out until the limbus was reached. A shallow dissection was then carried out 1 mm into the clear cornea, and the limbal tissue was excised . A 360 degree peritomy was performed. After cauterisation of the bleeding points, human amniotic membrane(hAM) graft was placed over the bared ocular surface and secured with fibrin glue. The excess membrane was trimmed and its edge stucked under the surrounding conjunctival margins.

The tissue was then gently held with Lim's forceps and cut into 8 to 10 small pieces with either Vannas scissors or a No 15 surgical blade. The small limbal transplants were placed, epithelial side up, on the hAM and distributed in a circular fashion around the base of excised pterygium avoiding the visual axis. The transplants were also fixed in place with fibrin glue. A soft bandage contact lens was placed on the eye.

Postoperative treatment include :antibiotic and steroid eyedrop treatment at least 4 weeks.

★ RESULTS ★

Two patients were with recurrent pterygium and one was with pseudopterygium, nasal and temporal side. All three were treated with novel procedure AMT and SLET using fibrin glue.

Patients were followed up 1 day, 7 day and 3 weeks after procedure. After surgery, patients are treated with artificial tears, topical dexamethason 0.5% drops every 6 h until full epithelial healing with a 1 month taper. Soft bandage contact lens was removed after 7 days of surgery.

★ DISCUSSION ★

Although the exact mechanism by which the amniotic membrane confers its beneficial effect has not yet been identified, most researchers have suggested that it is the basement membrane that contains factors important for inhibiting inflammation and fibrosis and promoting epithelialization.

The minor ipsilateral simple limbal epithelial transplantation technique for the treatment of pterygium requires less tissue than the conventional conjunctival autograft, leaving healthy conjunctiva if needed for another procedure in the future and offers the advantages of epithelial stem cells, which in the long term may reduce the rate of recurrence significantly.

The amniotic membrane is usually sutured onto the ocular surface using running or interrupted sutures for fixation⁽⁴⁾. However, the placement of sutures inflicts trauma to the ocular surface with prolonged operative time, and hence technical skills are required for an effective suture placement. AMT with SLET using fibrin glue does not require any sutures and eliminates several problems resulting from sutures, such as subconjunctival hemorrhage, infection due to sutures, tissue necrosis, foreign body reaction, and irritation.

Limbal autografts have been used in treating monocular chemical or thermal burn, aniridia, conjunctival squamous cell carcinoma, recurrent or advanced pterygia, and contact lens associated ocular surface abnormality. Limbal autografts have been used successfully to correct limbal dysfunction, acting as a barrier against conjunctival invasion of the cornea and supplying stem cells of the corneal epithelium.

Simple Limbal Epithelial Transplantation (SLET) is a surgical technique first described by Dr. Sangwan in 2012⁽²⁾ for the treatment of limbal stem cell deficiency (LSCD). Since then, several papers have validated its efficacy restoring the ocular surface, renewing the corneal epithelium and avoiding the re-conjunctivalization of the cornea⁽³⁾.

In conclusion, we describe a new technique in which an AM graft is combined with a mini-SLET for pterygium surgery. We found this technique to be easy to learn and believe it can be an interesting solution for those patients in which we want to preserve as much conjunctiva as possible. Although the initials results are encouraging and promising, results are subject to validation as the number of patients and longer follow-up are available in the future.⁽⁵⁾

★ CONCLUSION ★

We have found that the combination of an amniotic membrane transplant to inhibit subconjunctival fibrosis, and a limbal autograft to restore limbal function is an surgical procedure for treating patients with recurrent pterygium.

★ REFERENCES ★

1. Transplantation of amniotic membrane and limbal autograft for patients with recurrent pterygium associated with symblepharon. Jun Shimazaki, Naoshi Shinozaki, Kazuo Tsubota Br J Ophthalmol 1998;82:235-240
2. Sangwan VS, Basu S, MacNeil S, Balasubramanian D. Simple limbal epithelial transplantation (SLET): a novel surgical technique for the treatment of unilateral limbal stem cell deficiency. Br J Ophthalmol. 2012 Jul;96(7):931-4. doi: 10.1136/bjophthalmol-2011-301164. Epub 2012 Feb 10.
3. Basu S, Sureka SP, Shanbhag SS, et al. Simple limbal epithelial transplantation: Long-term clinical outcomes in 125 cases of unilateral chronic ocular surface burns. Ophthalmology 2016; 123:1000-1010.
4. Azuara-Blanco A, Pillai CT, Dua HS. Amniotic membrane transplantation for ocular surface reconstruction. Br J Ophthalmol 1999;83:399-402.
5. Minor ipsilateral simple limbal epithelial transplantation (mini-SLET) for pterygium treatment ;Erick Hernández-Bogantes, Guillermo Amescua, Alejandro Navas, Yonathan Garfias, Arturo Ramirez-Miranda, Alejandro Lichtinger, Enrique O Graue-Hernández BMJ (British Journal of Ophthalmology) Volume99 Issue12



Dr. Dominika WRÓBEL-DUDZIŃSKA

Clinical Hospital No. 1, Department of Diagnostic and Glaucoma Microsurgery – POLAND

.....

MANAGEMENT OF ATYPICAL ACANTHAMOEBA KERATITIS IN A 48 YEAR-OLD WOMAN

.....

★ INTRODUCTION ★

Acanthamoeba keratitis (AK) is an increasingly common vision-threatening corneal parasitic infection seen most often in contact lens wearers. The organism is ubiquitous (has been located in various environments including pools, freshwater lakes, rivers, shower water, hot tubs, tap water, soil, and contact lens solution), existing as both a mobile trophozoite and a double-walled cyst. Diagnosis of AK is challenging due to variable clinical presentation and the nonspecific signs and symptoms in the early stages of infection, that might mimic other infectious organisms. Classic initial presenting symptoms are pain with photophobia, tearing and redness. Clinical signs of the infection are also generally nonspecific, with epithelial defect, microerosions opacities, ring-like stromal infiltrate and lid oedema. Early diagnosis and appropriate therapy are key to good visual outcome.

★ CASE PRESENTATION ★

In March 2017, a 48 year-old woman presented to the cornea clinic of the Medical University of Lublin with complaints of a mild conjunctival hyperaemia, discomfort and decreased visual acuity in her left eye for two weeks. Her BCVA acuity of the left eye was 0.7, and 1.0 of the right eye, intraocular pressure was 14 mmHg in both eyes. Ocular examination disclosed mild conjunctival hyperaemia and minor epitheliopathy resembling dendritic-like ulcer in the lower corneal hemisphere of the left eye, decreased corneal sensation. (Fig.1 A, B)

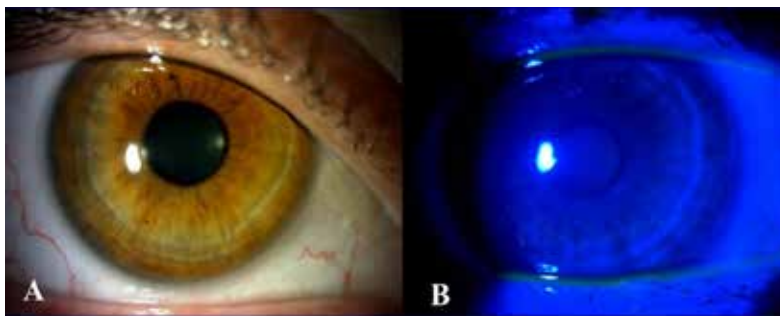


Figure 1: A- mild conjunctival hyperaemia and minor epitheliopathy, B- no fluorescein staining.

Her past ocular history was significant for herpes simplex keratitis of the left eye treated with acyclovir ointment five months before presentation. She claimed to wear contact lenses very occasionally. The patient was then diagnosed as recurrent herpes keratitis and the treatment with topical and oral acyclovir was started. Although a slight improvement was noticed three weeks later (no epitheliopathy in the lower corneal hemisphere), a marked stromal edema (Fig. 2) was present and the visual acuity of the left eye deteriorated to 0,3.

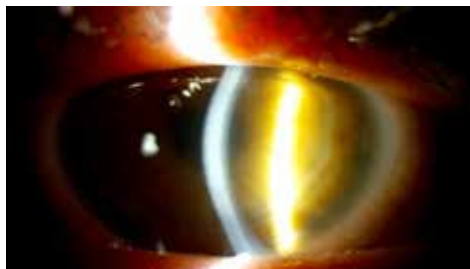

Figure 2: stromal edema

In May, the deeper ulcer was identified in the upper corneal hemisphere (Fig.3). Upon inquiry it was noted that the patient did not complain of any ocular pain.

MANAGEMENT OF ATYPICAL ACANTHAMOEBA KERATITIS IN A 48 YEAR-OLD WOMAN

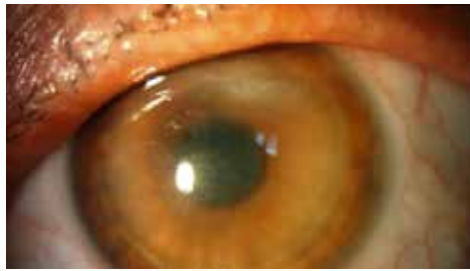

Figure 3: corneal ulceration

In June, the patient developed a dense, mid-peripheral ring-like stromal infiltrate (Fig.4 A, B).

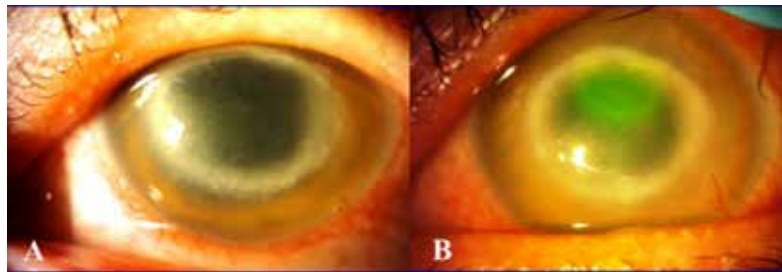


Figure 4: A- mid-peripheral ring-like stromal infiltration, B- epithelial defect with fluorescein staining

Visual acuity of the left eye deteriorated to counting fingers. The confocal microscopy was performed providing images detailing characteristic findings of the AK disease. Moreover, a deep corneal scrapings were harvested and inoculated into a dish of *E. coli* plated over non-nutrient agar. The culture was positive for *Acanthamoeba* spp. The therapy with 0.1% propamidine isetionate, 0.2% polyhexamethylene biguanide, neomycin with fluconazole/ketoconazole (systemic) was introduced.

In September, after three months of amoebicidal therapy a stromal infiltrate failed to improve (Fig.5) and the patient underwent a penetrating keratoplasty. The corneal button was sent to the ocular pathology laboratory. To the last moment before the surgery, the patient did not reported any pain.

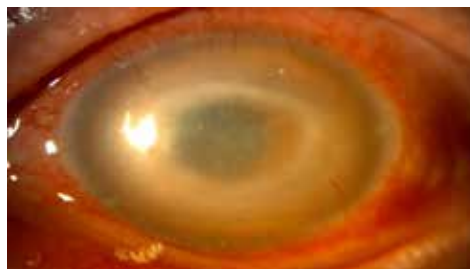

Figure 5: conjunctival hyperaemia, deeper stromal infiltration.

OCULAR PATHOLOGY:

MACROSCOPIC EXAMINATION:

The specimen consisted of a haze corneal button measuring 8mm in diameter.

MICROSCOPIC EXAMINATION:

The corneal epithelium was markedly attenuated and focally detached. A marked stromal edema was present together with focal infiltrations of neutrophils. There was a wide distribution of amoebic cysts and trophozoites within the stroma. Descemet's membrane appears normal, but it was massively covered with inflammatory cells (mainly neutrophils). Only few endothelial cells were identified (Fig.6 A, B).

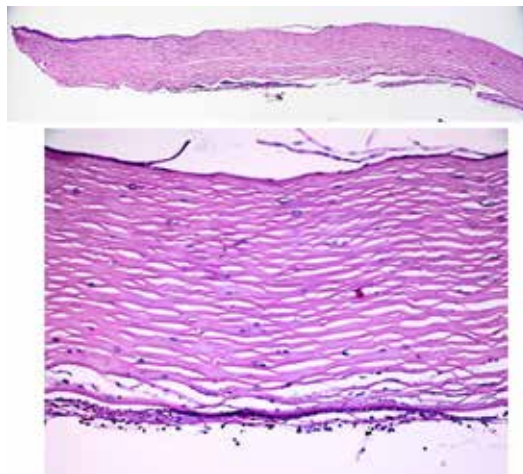


Figure 6: A, B- a wide distribution of amoebic cysts and trophozoites within the stroma

FOLLOW-UP:

During the first follow up visit ocular examination revealed transparent corneal transplant secured with 16 Nylon 10/0 sutures (Fig.7).

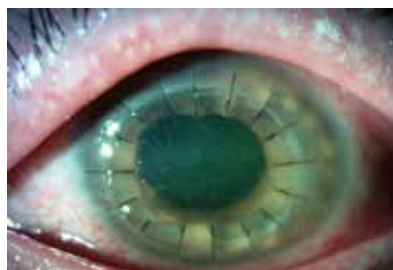

Figure 7: transparent corneal transplant.

In November the transplant lost transparency, few sutures were loosened (Fig.8). A cataract was also diagnosed in the left eye.

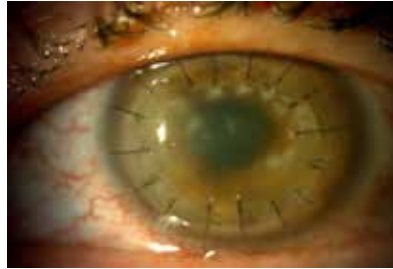

Figure 8: transplant failure with infiltration, loosened sutures.

At the next follow-up visit, our patient's visual acuity was hand-movement. There was melting of the corneal graft and hypopyon in the anterior chamber observed. Unfortunately, conservative treatment (cefazolin intravenously, topical: vancomycin, moxifloxacin, gentamicin, atropine, 0.1% propamidine isetionate, 0.2% polyhexamethylene biguanide) was ineffective so re-transplant together with cataract surgery was performed.

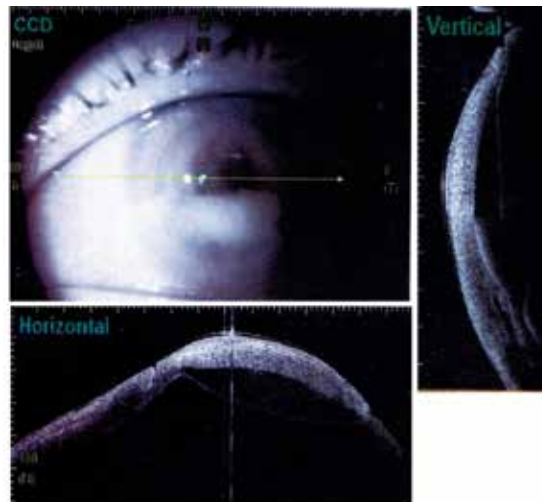


Figure 9: melting of the corneal graft and hypopyon in the anterior chamber.

During the last follow-up visit ocular examination revealed transparent corneal transplant sutured with 16 Nylon 10/0 sutures. Visual acuity was 0.1 in the left eye, intraocular pressure 19 mmHg. Ongoing treatment: dexamethasone, 0.1% propamidine isetionate, 0.2% polyhexamethylene biguanide, 0.1% ciclosporin, artificial tears and orally ciclosporin 100mg, Methylprednisolone 4 mg.

★ DISCUSSION ★

Acanthamoeba keratitis is a potentially vision-threatening infection of the cornea that may create a considerable diagnostic challenge and require prolonged amoebicidal therapy⁽¹⁾. This condition can be often misdiagnosed as herpes keratitis⁽²⁾ or epithelial erosions during the early course of the disease resulting from the presence of an epithelial defect. Severe pain disproportionate to clinical signs is often described as the classical symptom of Acanthamoeba keratitis⁽³⁾. However, a high clinical suspicion must remain for those patients who present with risk factors of Acanthamoeba keratitis in the absence of pain⁽⁵⁾. Other initial presenting symptoms are frequently nonspecific and may include: unilateral photophobia, tearing, redness⁽⁴⁾.

Our case demonstrates an atypical and unusual presentation of Acanthamoeba keratitis. The patient did not complain of any ocular pain in the entire course of her disease. She reported minor discomfort, but not pain. The mechanism for painless Acanthamoeba keratitis is not completely understood⁽⁵⁾, but it is suggested to be a result of either perineuritis⁽⁶⁾, pre-existing neurotrophic cornea (such as herpes keratitis), or pretreatment with topical steroids^(7,8). Our patient was diagnosed as having herpes simplex keratitis five months before presentation, and this situation may have resulted in decreased corneal sensation. These circumstances can explain a painless course of the disease. A painless course of Acanthamoeba keratitis in our patient caused considerable delay in the proper diagnosis and treatment. Also it led to avoidable loss of visual acuity before transplant and finally transplant failure.

★ CONCLUSION ★

Therefore Acanthamoeba keratitis must be considered in the differential diagnosis of keratitis even without the classic signs of severe pain. Using pain as a marker in diagnosing AK may result in misdiagnosis, delayed the proper management and increased visual deficits.

★ REFERENCES ★

1. Chin J., Young AL, Hui M., et al: Acanthamoeba keratitis: 10-year study at a tertiary eye care center in Hong Kong. *Cont Lens Anterior Eye* 2015;38:99-103.
2. Johns K.J., O'Day D.M., Head W.S., et al: Herpes simplex masquerade syndrome: Acanthamoeba keratitis. *Curr Eye Res* 1987;6:207-212.
3. Maycock N.J., Jayaswal R.: Update on Acanthamoeba keratitis: diagnosis, treatment, and outcomes. *Cornea* 2016;35:713-720.
4. Tabin g., Taylor H., Snibson G., Murchison A., Gushchin A., Rogers S.: Atypical Presentation of Acanthamoeba keratitis. *Cornea* 2001;20(7):757-759.
5. Kwok P.W.R., Kam K.W., Jhaji V., Young A.L.: Painless Acanthamoeba keratitis with Normal Vision. *Optom Vis Sci* 2017;94:432-435.
6. Pettit D.A., Williamson j., Cabral G.A., et al: In vitro destruction of nerve cell cultures by Acanthamoeba spp: a transmission and scanning electron microscopy study. *J Parasitol*; 1996;82:769-777.
7. Shukla Kent S., Robert M.C., Tokarewicz A.C., et al: Painless Acanthamoeba keratitis. *Can J Ophthalmol* 2012;47:383-384.
8. Kaiserman I., Bahar I., McAllum P., Srinivasan S., Elbaz U., Slomovic A.R., Rootman D.: Prognostic factors in Acanthamoeba keratitis. *Can J Ophthalmol* 2012;47:312-317.



Mr. Uğur YILMAZ
Pamukkale University, Pamukkale – TURKEY

.....

LIMITED CONJUNCTIVAL FLAP FOR REPAIRING CORNEAL PERFORATION CLOSED TO VISUAL AXIS

.....

★ INTRODUCTION ★

A 62 years old man was referred to our clinic for corneal perforation of left eye. He had a previous story of keratitis refractory to treatment.

★ CASE PRESENTATION ★

On presentation, visual acuity of patient was 10/20 and fingers count in the right and left eye respectively. There was a perforation in superior nasal quadrant, near the pupil border and a positive sieidel test due to aqueous humor leakage in the left eye. Anterior chamber of left eye was shallow and there was nuclear sclerosis, inflammation in anterior chamber and iridocorneal touch as a result of iris prolapse (Figure 1). Firstly, we planned tectonic keratoplasty. But he was taking anticoagulant and antiplatelet drugs for previously cardiac and ischemic diseases and had high risk for general anesthesia. So we decided to perform conjunctival flap for repair of perforation under topical anesthesia.

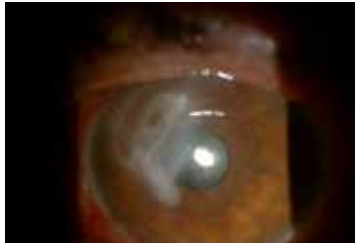

Figure 1: There was a perforation in superionasal quadrant

SURGICAL TECHNIQUE

After topical anesthesia, a conjunctival flap with tenon as wide as perforation diameter was formed between 9 and 12 clock position. We performed a sideport incision by 20 Gauche MVR knife. Anterior chamber was formed after releasing iris from the perforated region of cornea. Tisseel fibrin glue (TFG) (Baxter Healthcare Corporation Deerfield USA) was applied on the perforated region of cornea. Conjunctival flap was pasted on the TFG. After waiting 5 minutes for the formation of a fibrin reaction, 10/0 nylon suture was used for fixation of tenon and conjunctiva. We performed suturation carefully because cornea was so soft and weak around the perforated region. Postoperatively, Dexamethasone drop 4x1 and moxifloksasin eye drop 4 x 1 and cyclopentolate eye drops 2x1 were prescribed.

On the first day, his vision was improved to 4/20. Anterior chamber depth was increased. Siedel test was negative. There was no pain and anterior chamber inflammation. intact flap and sutures were intact (figure2).

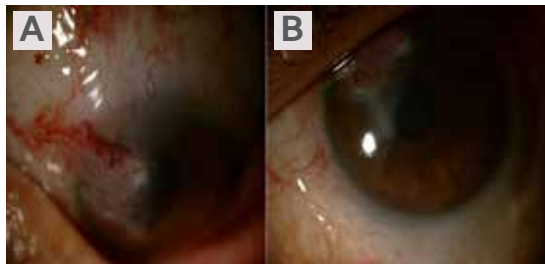


Figure 2: A: conjunctival flap B: formed anterior chamber

On the first week, his vision was 8/20. Anterior chamber depth was normal. Conjunctival flap was well vascularized and sutures were intact (Figure3).

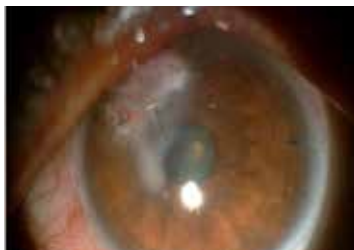

Figure 3

On the first month, his vision was 12/20. Anterior chamber was normal. There was no inflammation. Conjunctival flap was well vascularized and sutures were intact.

On the third month, his vision was 12/20, conjunctival flap was replaced with a smooth corneal surface and vascularisation (figure 4).

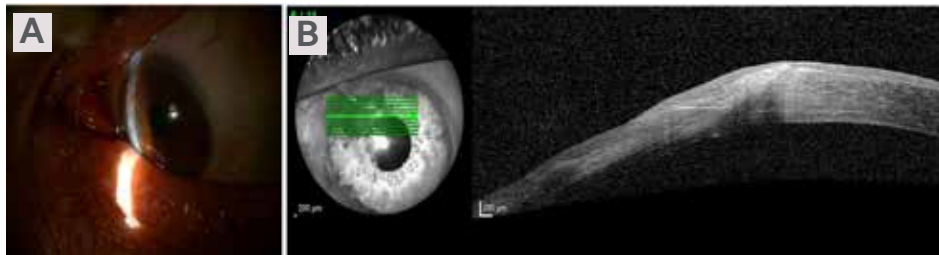


Figure 4: A: Corneal vascularisation B: anterior segment OCT of at the postoperative third month.

★ DISCUSSION ★

There are different options for corneal perforation repair like tectonic keratoplasty⁽¹⁻³⁾, amniotic membrane^[4-7], fibrin glue^[4-6], bandage contact lens^[8], conjunctival flap⁽⁹⁾. There are some disadvantages of these options. Postoperative complications like graft rejection, astigmatism as a significant cause of visual impairment can be seen after tectonic keratoplasty. Bandage contact lens, amniotic membrane and TFG can be insufficient for repairing cornea if perforation is wide. Also they may be combined according to perforation.

Conjunctival flap defined by Gunderson was used for ocular surface diseases and corneal perforation^(10,11). There are some advantages and disadvantages of this technic for corneal perforation. Shortness of surgery time, better vascularity to provide a good wound healing, pain relief, no corneal need and no rejection risk are advantages of conjunctival flap. Poor cosmetic appearance, difficulty in examination and poor vision are disadvantages of this technic.

We used limited size conjunctival flap by using TFG and 10,0 nylon suture. The width of flap was as wide as perforation diameter to avoid of excessive corneal scar and vision loss. Postoperatively, visual axis was open and we achieved improved vision and well wound healing without excessive corneal scar.

★ REFERENCES ★

1. Białasiewicz AA1, Naumann GO. Tectonic keratoplasty in perforated corneal ulcer in Sjögren's syndrome (report of 10 eyes in 8 patients)]. *Klin Monbl Augenheilkd*. 1988 Dec;193(6):554-64.
2. Por YM1, Tan YL, Mehta JS, Tan DT. Intracameral fibrin tissue sealant as an adjunct in tectonic lamellar keratoplasty for large corneal perforations. *Cornea*. 2009 May;28(4):451-5. doi: 10.1097/ICO.0b013e31818ad9d0.
3. Wang F, Li S, Wang T, Gao H, Shi W1. Modified tectonic keratoplasty with minimal corneal graft for corneal perforation in severe Stevens-Johnson syndrome: a case series study. *BMC Ophthalmol*. 2014 Aug 8;14:97. doi: 10.1186/1471-2415-14-97.
4. Duchesne B, Tahj H, Galand A. Use of human fibrin glue and amniotic membrane transplant in corneal perforation. *Cornea* 2001;20:230-2.
5. Hick S, Demers PE, Brunette I, La C, Mabon M, Duchesne B, et al. Amniotic membrane transplantation and fibrin glue in the management of corneal ulcers and perforations: A review of 33 cases. *Cornea* 2005;24:369-77.
6. Kim HK, Park HS. Fibrin glue-assisted augmented amniotic membrane transplantation for the treatment of large noninfectious corneal perforations. *Cornea* 2009;28:170-6.
7. Rodriguez-Ares MT, Touriño R, Lopez-Valladares MJ, Gude F. Multilayer amniotic membrane transplantation in the treatment of corneal perforations. *Cornea* 2004;23:577-83.
8. Arora R, Jain S, Monga S, Narayanan R, Raina UK, Mehta DK, et al. Efficacy of continuous wear pureVision contact lenses for therapeutic use. *Cont Lens Anterior Eye* 2004;27:39-43.
9. Sun YC1,2, Kam JP2, Shen TT2. Modified conjunctival flap as a primary procedure for nontraumatic acute corneal perforation. *Ci Ji Yi Xue Za Zhi*. 2018 Jan-Mar;30(1):24-28. doi: 10.4103/tcmj.tcmj_191_17.
10. Gundersen T. Conjunctival flaps in the treatment of corneal disease with reference to a new technique of application. *AMA Arch Ophthalmol* 1958;60:880-8.
11. Alino AM, Perry HD, Kanellopoulos AJ, Donnemfeld ED, Rahn EK. Conjunctival flaps. *Ophthalmology* 1998;105:1120-3

TROPHY

7th
EDITION

CONTEST

THEA INTERNATIONAL CONTEST OF CLINICAL
CASES IN PATHOLOGIES OF THE EYE

This brochure is produced under the sole responsibility of the authors.
Laboratoires Théa are not involved in the writing of this document.
This brochure may contain MA off-label and/or not validated by health authorities information.



2018 - 2019 EDITION

MANAGING OCULAR SURFACE INFLAMMATION

THE BEST CLINICAL CASES
FROM 22 COUNTRIES



WWW.THEA-TROPHY.COM

Laboratoires Théa • 12, rue Louis Blériot
63017 Clermont-Ferrand Cedex 2 • France
T +33 4 73 98 14 36
F +33 4 73 98 14 38
LABORATOIRES-THEA.COM



Laboratoires Théa