

By the Name of ALLAH the Most Gracious the Most Merciful



Portal Hypertension

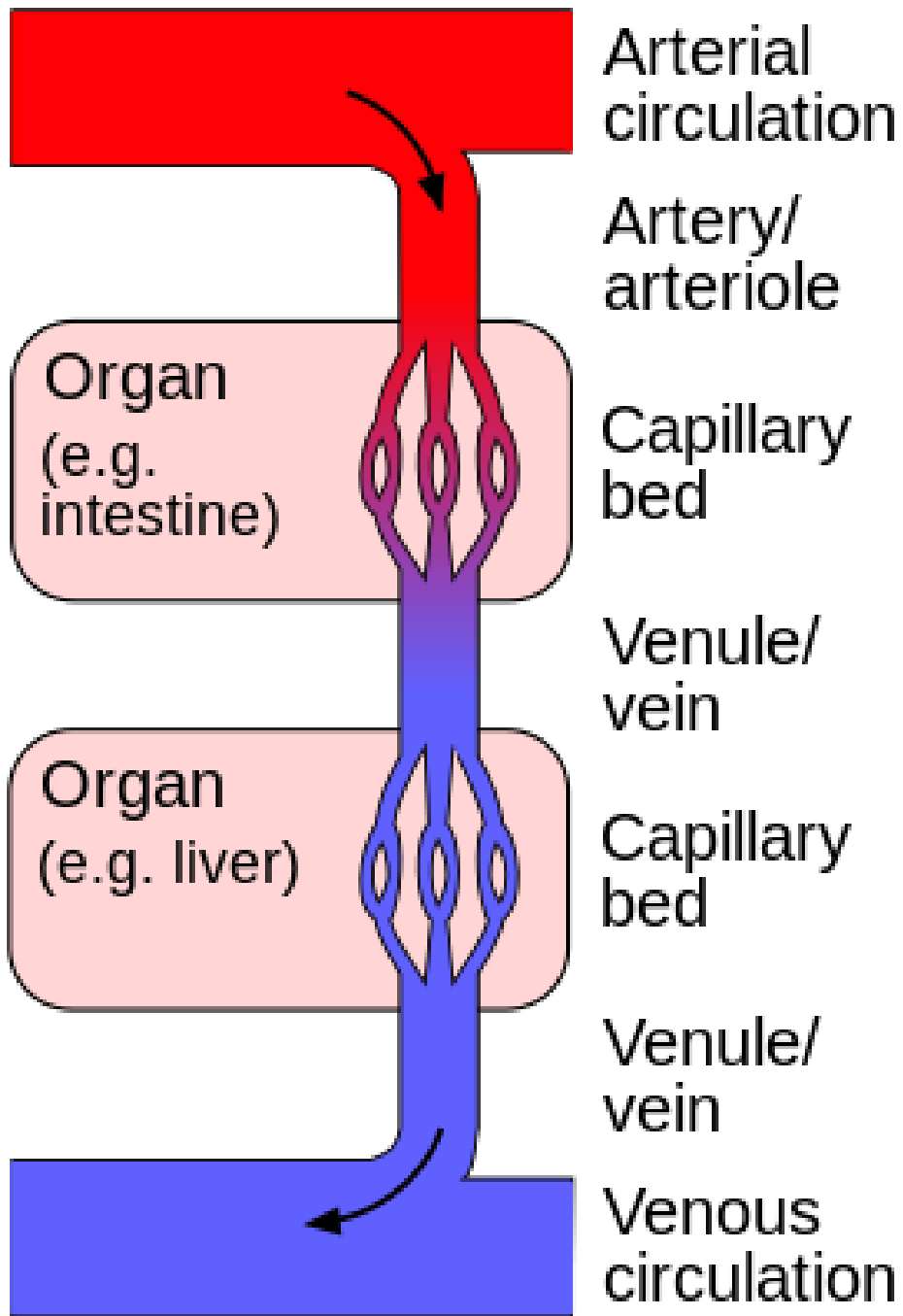
د . أحمد اسامة حسن

Specialist in General Surgery & Laparoscopic Surgery

30th ,November , 2023

To be read in

Bailey & Love's Short Practice of Surgery 28th Edition. P 1203



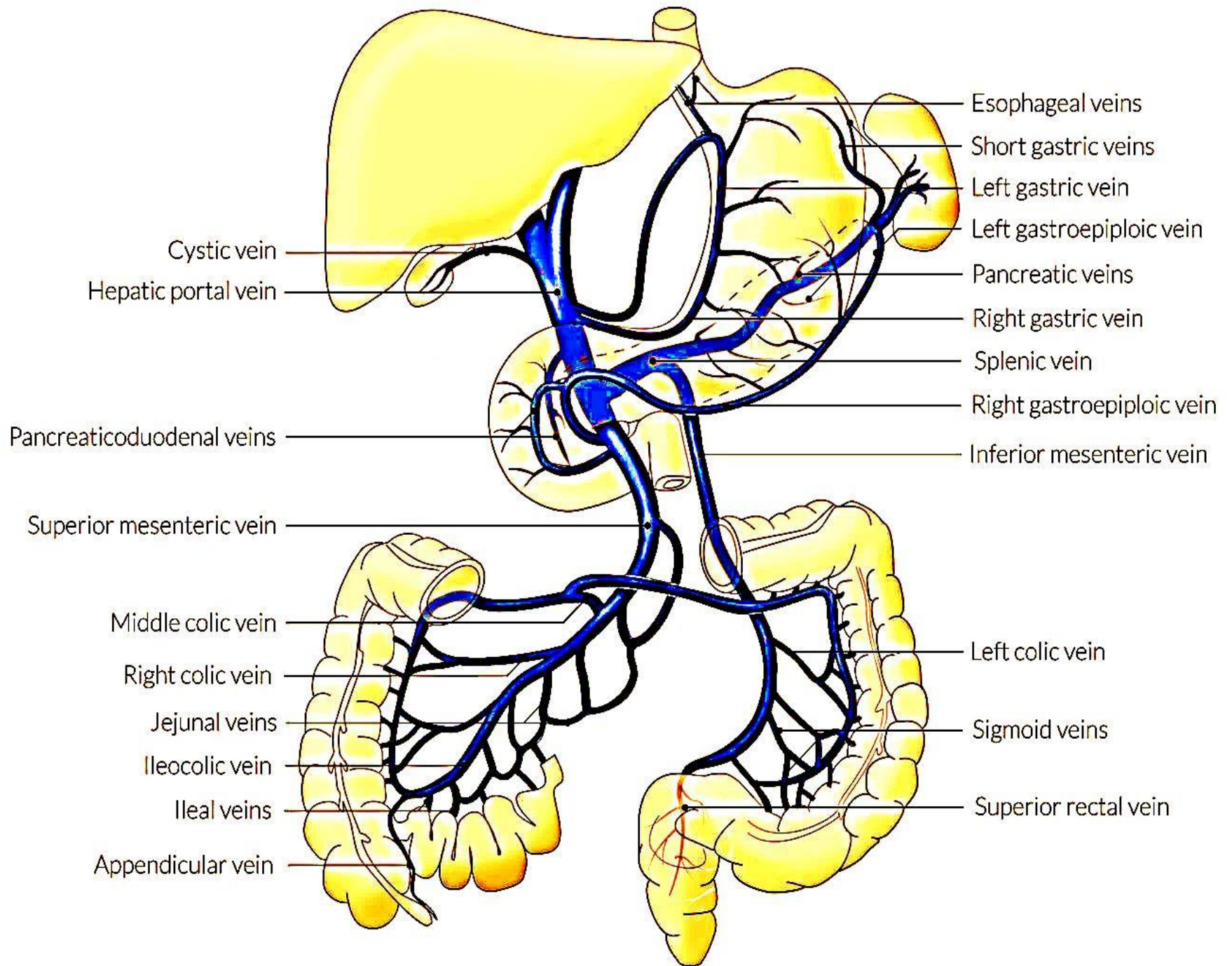
The hepatic portal system.

Hepatic Portal Vein

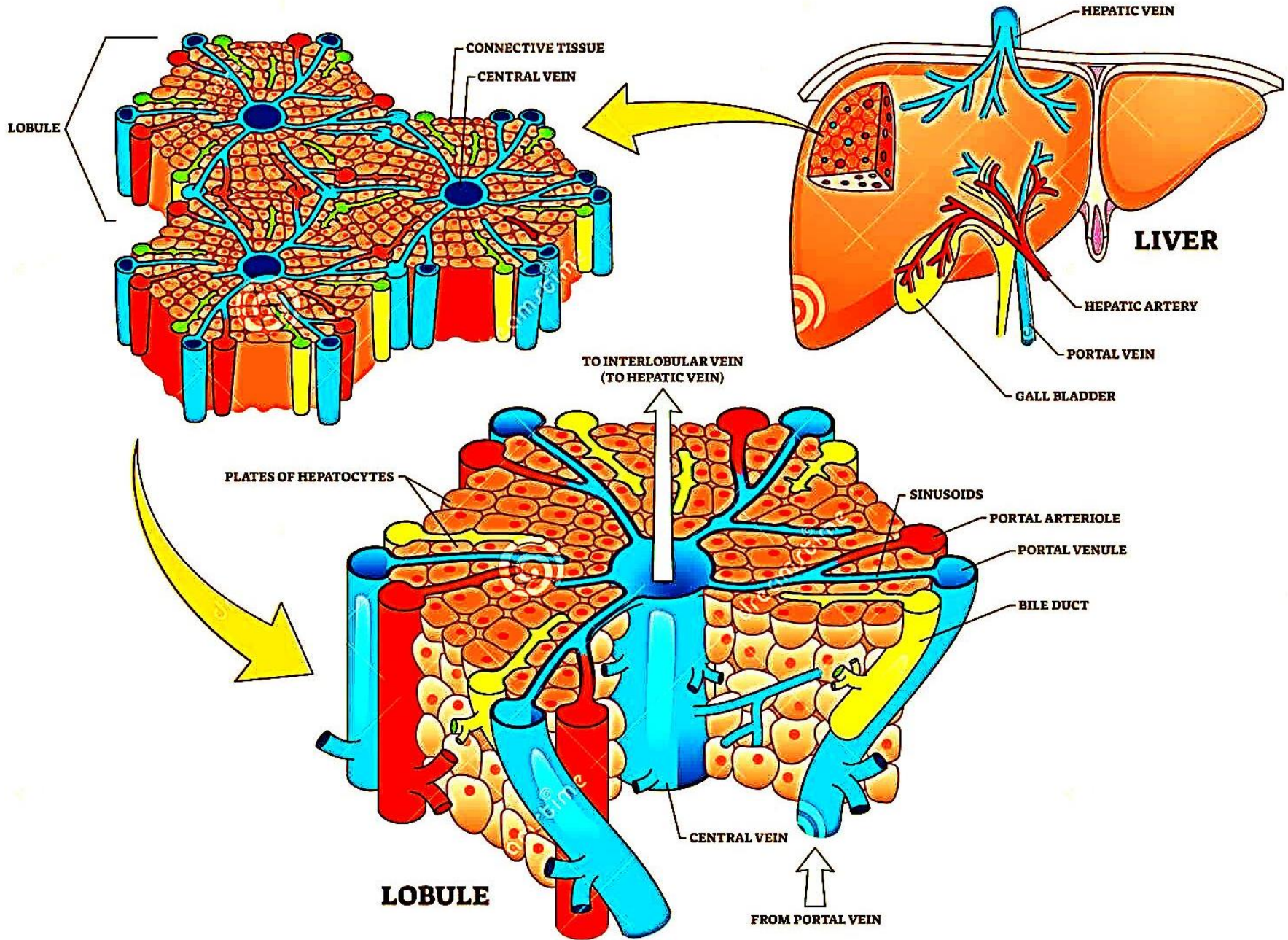
<https://www.youtube.com/watch?v=c0Kny00yB1o>.

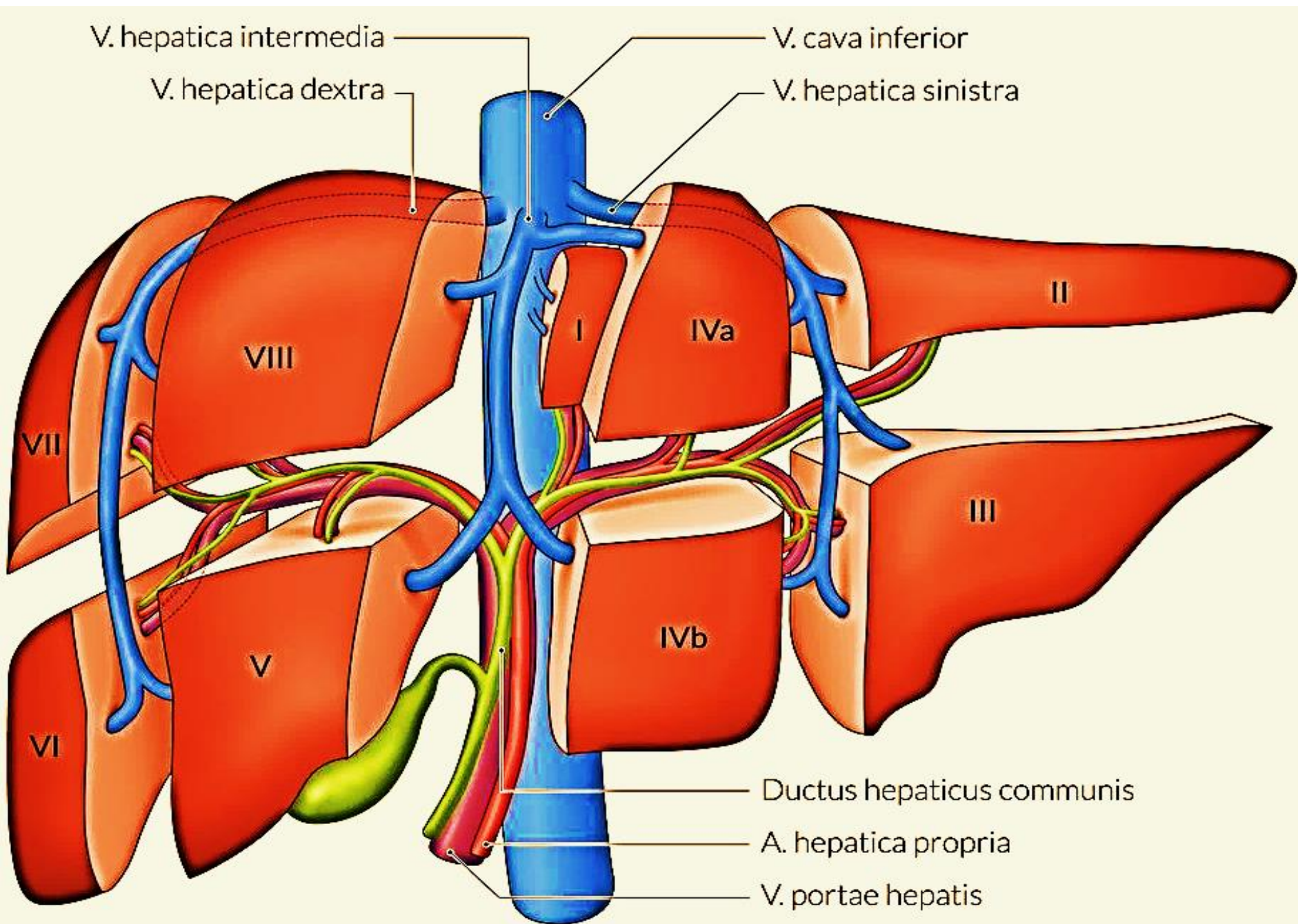
Measurement of portal pressure

<https://www.youtube.com/watch?v=a57GgpVUL5o>



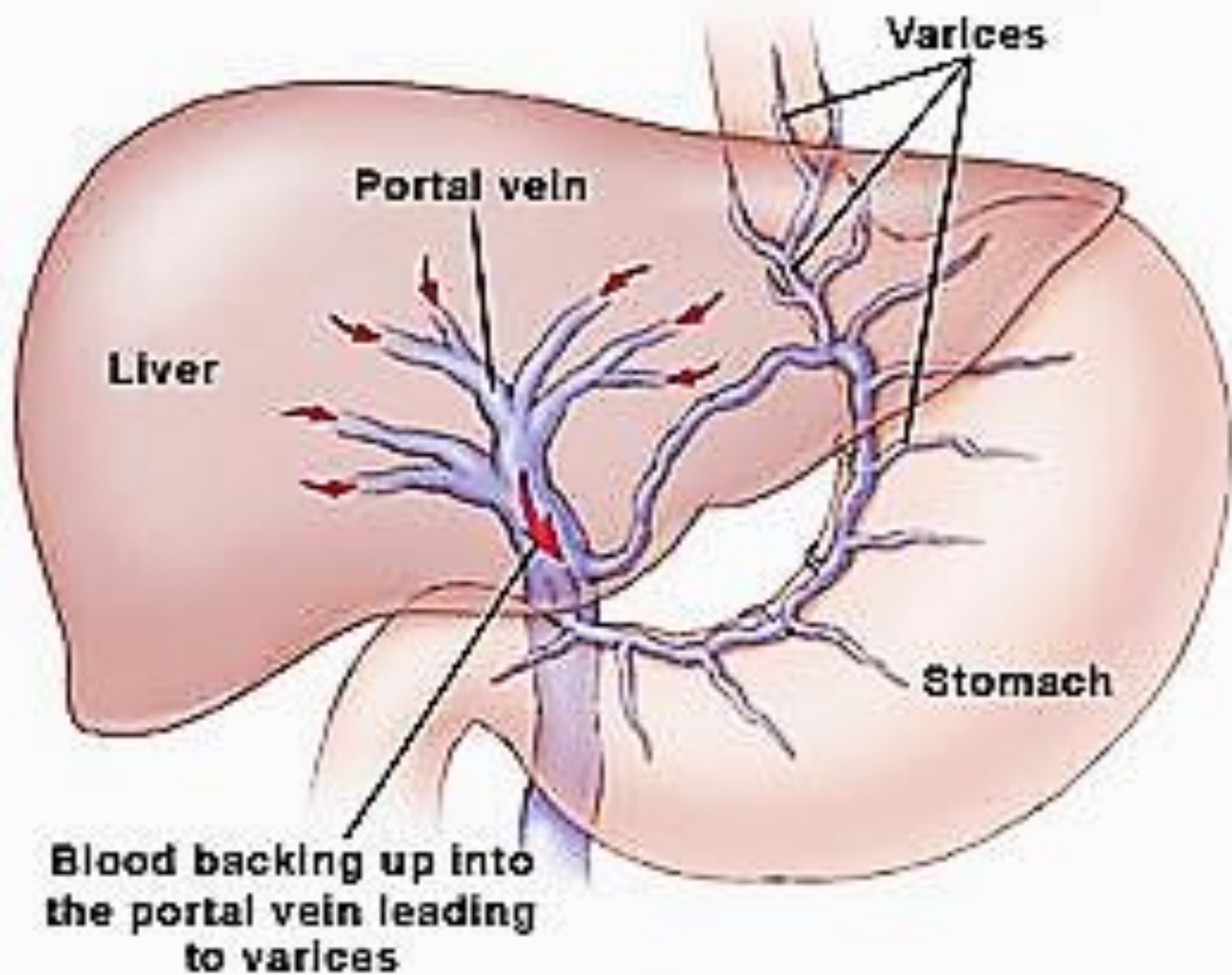
HEPATIC LOBULE





Portal Hypertention

- Is defined as a hepatic venous pressure gradient equal to or greater than 6 mmHg.
- **Hepatic venous pressure gradient (HVPG)** is a clinical measurement of the pressure gradient between the WHVP and the **free hepatic venous pressure (FHVP)**.
- **Wedged hepatic venous pressure (WHVP)** : reflects not the actual hepatic portal vein pressure but the hepatic sinusoidal pressure.
- $HVPG > 12 \text{ mmHg}$ ► Variceal Haemorrhage.
- It is a medical emergency .
- Types : - Cirrhotic
- Non-cirrhotic portal hypertension



Causes of Portal Hypertension

A- Pre-sinusoidal

- Extrahepatic: portal vein thrombosis, splenic vein thrombosis (pancreatitis, pancreatic tumour), myelofibrosis, arterioportal shunt, tropical splenomegaly
- Intrahepatic: schistosomiasis, congenital hepatic fibrosis and portal infiltration (sarcoidosis), drugs and toxins, venoocclusive disease

B- Sinusoidal

- Cirrhosis

C- Post-sinusoidal

- Hepatic vein occlusion (Budd–Chiari syndrome), venoocclusive disease, congestive cardiac failure

Hepatic venous pressure gradient in differential diagnosis of Portal Hypertention

Types	WHVP	FHVP	HVPG	Causes
Presinosoidal	Normal	Normal	Normal	
Sinosoidal	Increased	Normal	Increased	
Postsinosoidal	Hepatic can't be cannulated			Budd–Chiari syndrome
	Increased	Increased	Normal	Rt sided Heart failure

FHVP, free hepatic venous pressure.

HVPG, hepatic venous pressure gradient.

WHVP, wedged hepatic venous pressure.

- Portal hypertension is most commonly due to liver cirrhosis, although it also occurs with extrahepatic portal vein occlusion, intrahepatic veno-occlusive disease and occlusion of the main hepatic veins (Budd–Chiari syndrome).
- It is common in clinical practice and portal hypertension represents a significant clinical challenge, with patients who have often been ill for long periods repeatedly presenting as emergencies.
- Many symptoms are intractable, surgery is technically difficult and procedures and timing must be chosen with extreme care.
- Portal hypertension per se produces no symptoms and is generally diagnosed following presentation with decompensated chronic liver disease causing encephalopathy, ascites or variceal bleeding .

- Surgical involvement occurs in four situations:
- 1 ascites;
- 2 oesophageal varices;
- 3 portosystemic shunting for problems not managed by other methods;
- 4 left-sided portal hypertension and hypersplenism.

There are four portal venous systems :

- The **hepatic portal system**.
- The **hypophyseal portal system** .
- The **renal portal system adrenal medulla capillaries**.
- The **pancreatic portal system**.

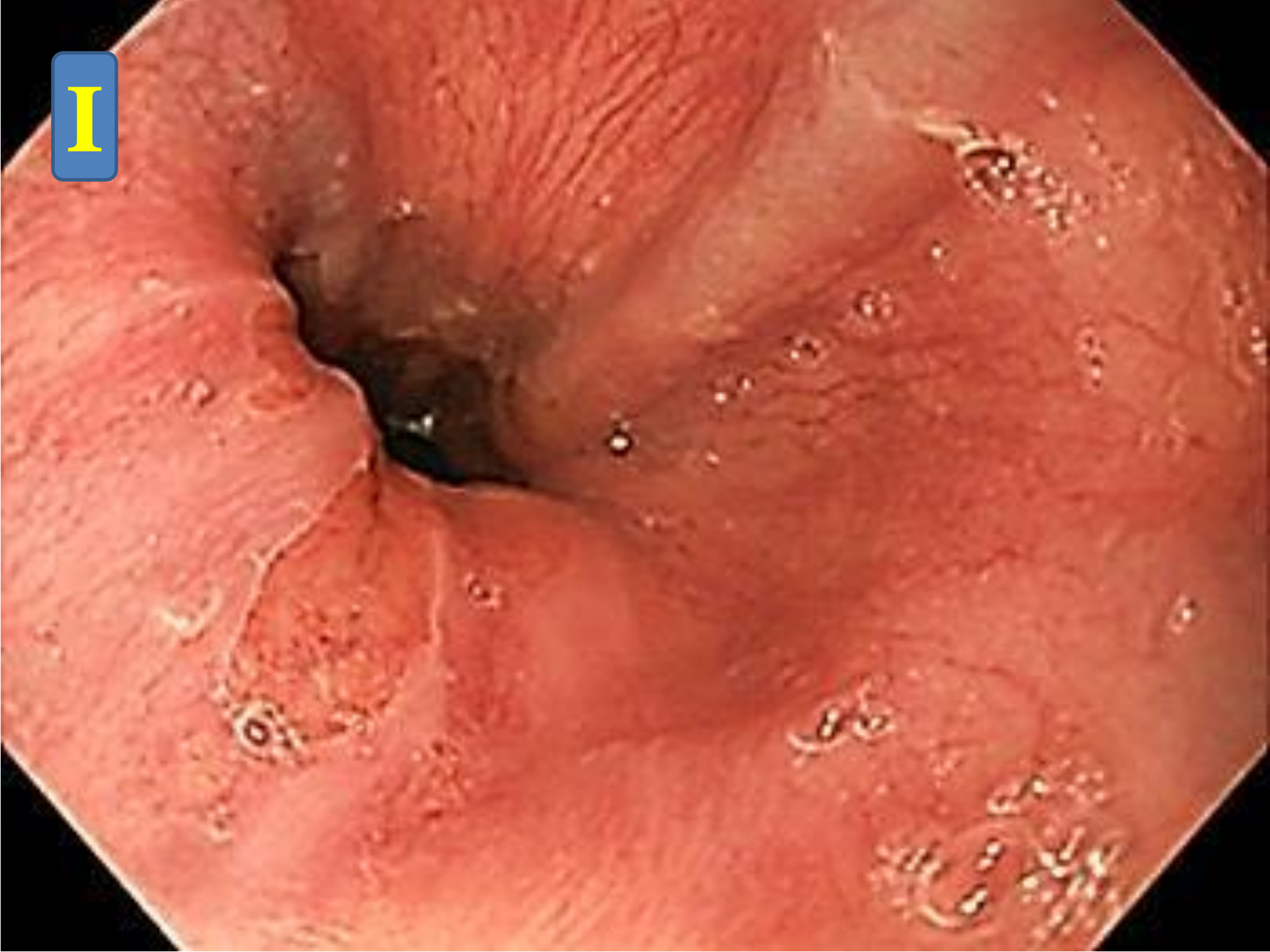Parameters that are used to assess varices:

- Number of strands
- Maximum diameter of the largest strand: less than or greater than 5 mm
- Location in the esophagus (distal, versus lower two-thirds, versus entire esophagus)
- Presence of what are known as red color signs — red patches, varices on varices (see below)

Modified Paquet's classification

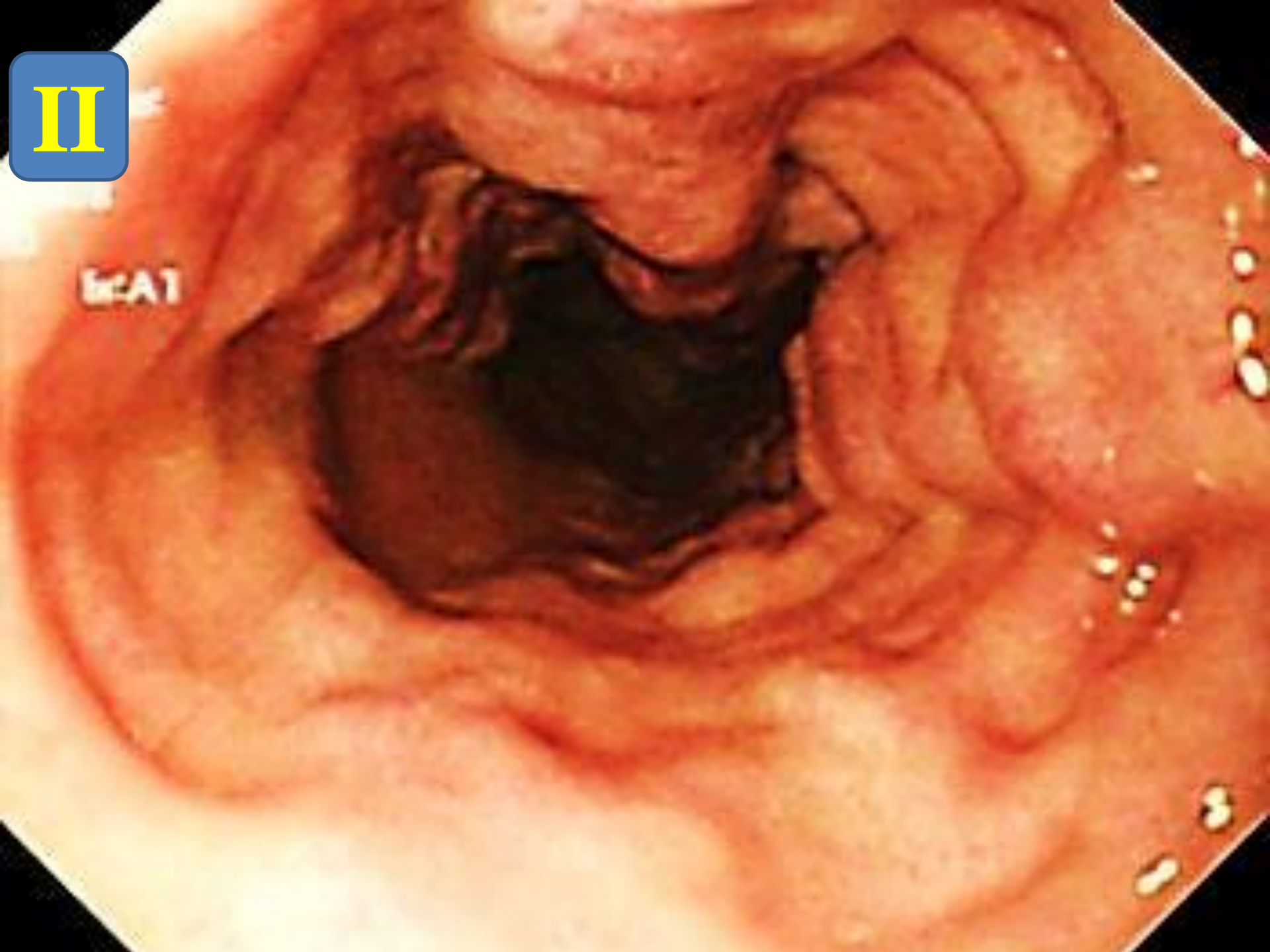
Grade I (Low)	Varices extending just above the mucosal level
Grade II (Moderate)	Varices projecting by one-third of the luminal diameter that cannot be compressed with air insufflation
Grade III (Sever)	Varices projecting up to 50% of the luminal diameter and in contact with each other

I

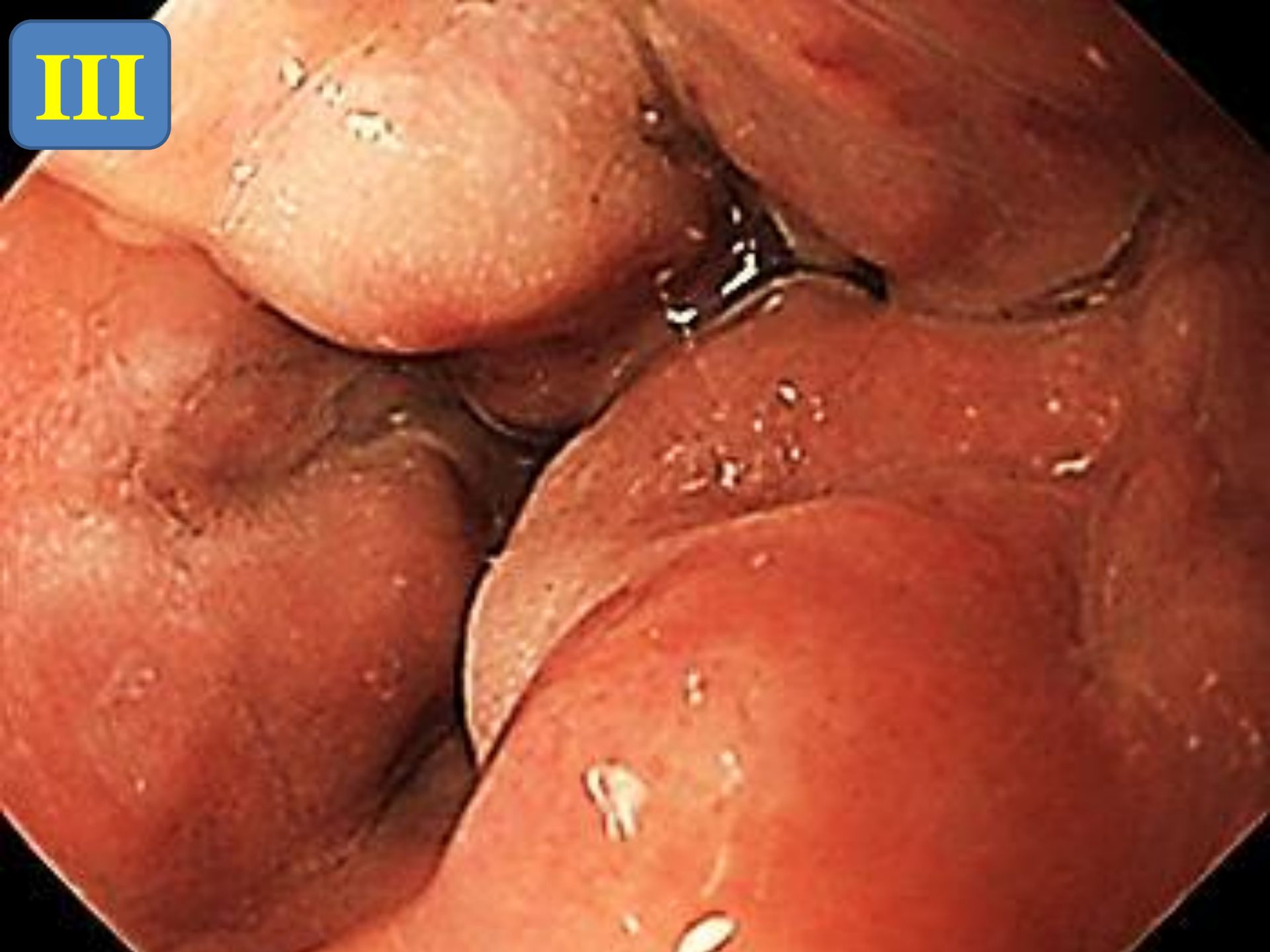

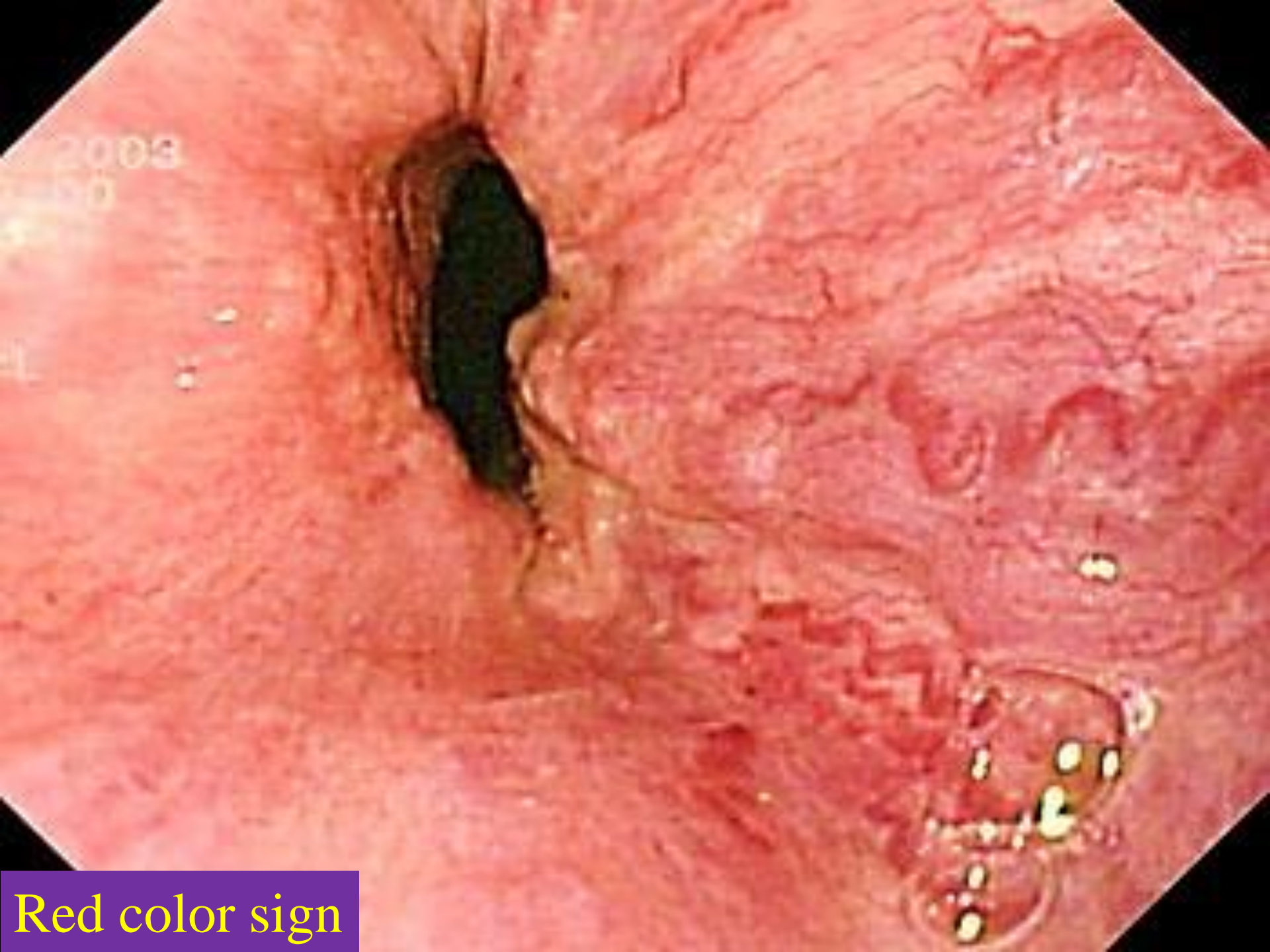II

Es-A1



III





Red color sign

Presentations

- Depends on site of occlusion.
- Portal hypertension per se produces no symptoms .
- It is generally diagnosed following presentation with decompensated chronic liver disease causing: encephalopathy, ascites or variceal bleeding

- Patients usually present with:
- General signs and symptoms of chronic liver disease, manifested by jaundice, ascites, spider nevus, palmar erythema, testicular atrophy, gynecomastia, parotid hypertrophy (Laënnec's cirrhosis), and muscle atrophy.
- Signs of hepatic encephalopathy that may be as subtle as lack of concentration and irritability, or as serious as stupor or coma.

- The portal system has collaterals that intercommunicate with the systemic circulation in an attempt to decompress it.
- These collateral venous systems are part of portal hypertension syndrome. The most clinically important collaterals are esophageal and gastric venous dilatations, since they can bleed acutely.
- The umbilical vein, originating from the left portal vein, may be dilated by **intrahepatic** causes that are manifested by venous dilatations in the anterior abdominal wall (Caput Medusa).

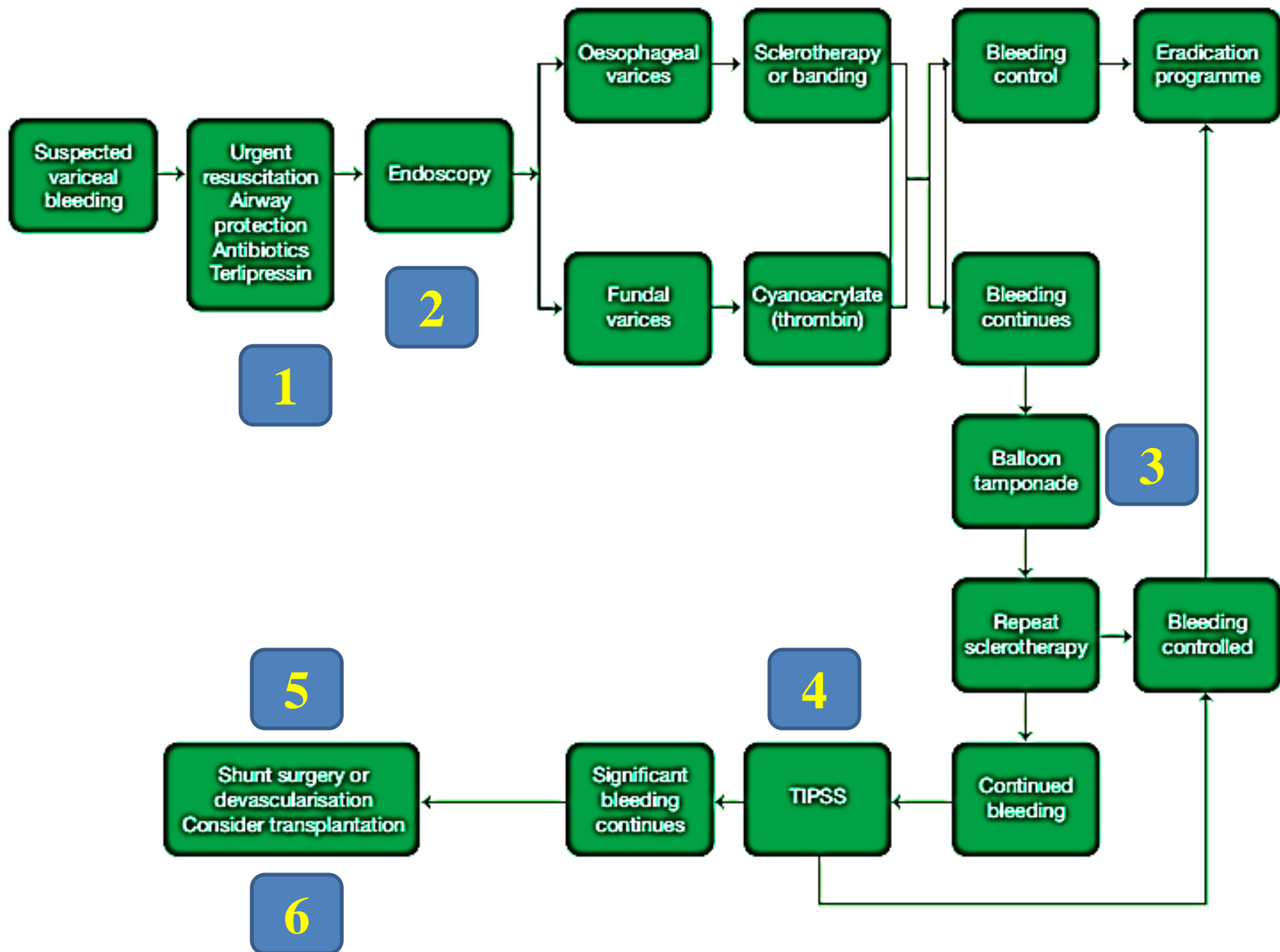
- In the rectum, venous systems of collateral bypass of the inferior mesenteric vein may be seen as rectal varices or hemorrhoidal dilations, which are nonspecific.

- Retroperitoneal collateral circulation cannot be clinically evaluated, and the presence of dorsal venous dilatations is rare and is most often associated with obstruction of the inferior vena cava.
- Although splenomegaly is common in portal hypertension syndromes, there is no proportionality between spleen size and pressure in the portal system Hypersplenism

DDX OF Upper GIT Bleeding.

Home work

Management of Variceal Bleeding



1- Resuscitation

- Varices are ubiquitous in patients with portal hypertension irrespective of the aetiology and usually present with an acute, large-volume haematemesis associated with a high morbidity and significant mortality.
- The lower oesophagus is the most common site and the diagnosis should be suspected in a patient known to have **cirrhosis**, but confirmation of the source is required following initial resuscitation.
- Variceal haemorrhage is a medical emergency and failure to control variceal bleeding with current medical management occurs in 10–20% of cases.
- Patients with massive haemorrhage should be admitted to an intensive therapy unit, venous access obtained through two

large-bore peripheral cannulae and resuscitation commenced, ideally with blood.

- Liver function tests will reveal underlying liver disease and a coagulation profile will identify any coagulopathy.
- Hypervolaemia may increase portal pressure and exacerbate bleeding.
- 10 mg of vitamin K is administered intravenously but a coagulopathy requires FFP and activation of a major transfusion protocol.
- Thrombocytopenia secondary to hypersplenism is treated if the platelet count is $<50 \times 10^9/L$.

- **Treatment protocols** include the use of splanchnic vasoconstrictors, (terlipressin, octreotide and somatostatin) and prophylactic antibiotics.
- When bleeding continues treatment options are sclerotherapy, banding, balloon tamponade and TIPSS. The use of oesophageal balloons should be avoided, which is usually possible when experienced endoscopists are available.
- When the patient is haemodynamically stable the diagnosis should be confirmed endoscopically as 30% will have a non-variceal source of bleeding.
- Variceal bleeding is often associated with hepatic encephalopathy and endotracheal intubation may be required prior to endoscopy to protect the airway and prevent aspiration .

2- Endoscopic treatment

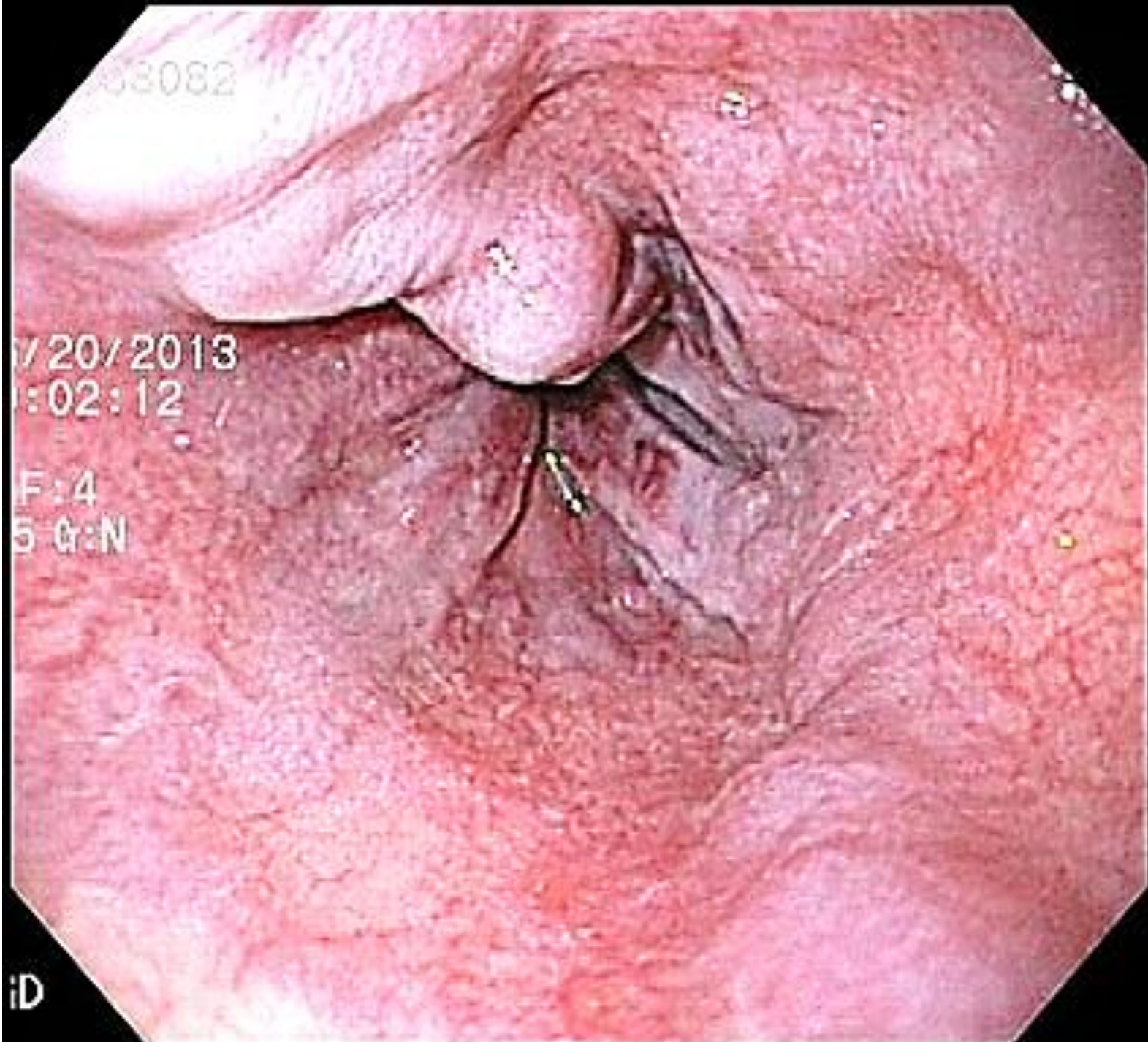
- The two most commonly used endoscopic techniques are :
- Endoscopic **band ligation** to the base of the varix
- Injection of a **sclerosant** into or around the varix.
- Following resuscitation, endoscopy is performed in a head-down position with good suction available. A double-channel endoscope with a bridge is essential to facilitate suction during injection and provide manoeuvrability of the needle, and power washers dramatically improve visualisation.
- Some time should be spent assessing the bleeding, confirming it is variceal and obtaining a stable position. When the bleeding varix or varices are identified only the source should be treated. Sclerotherapy or banding both achieve effective control with banding reducing rebleeding; a single treatment is usually sufficient.

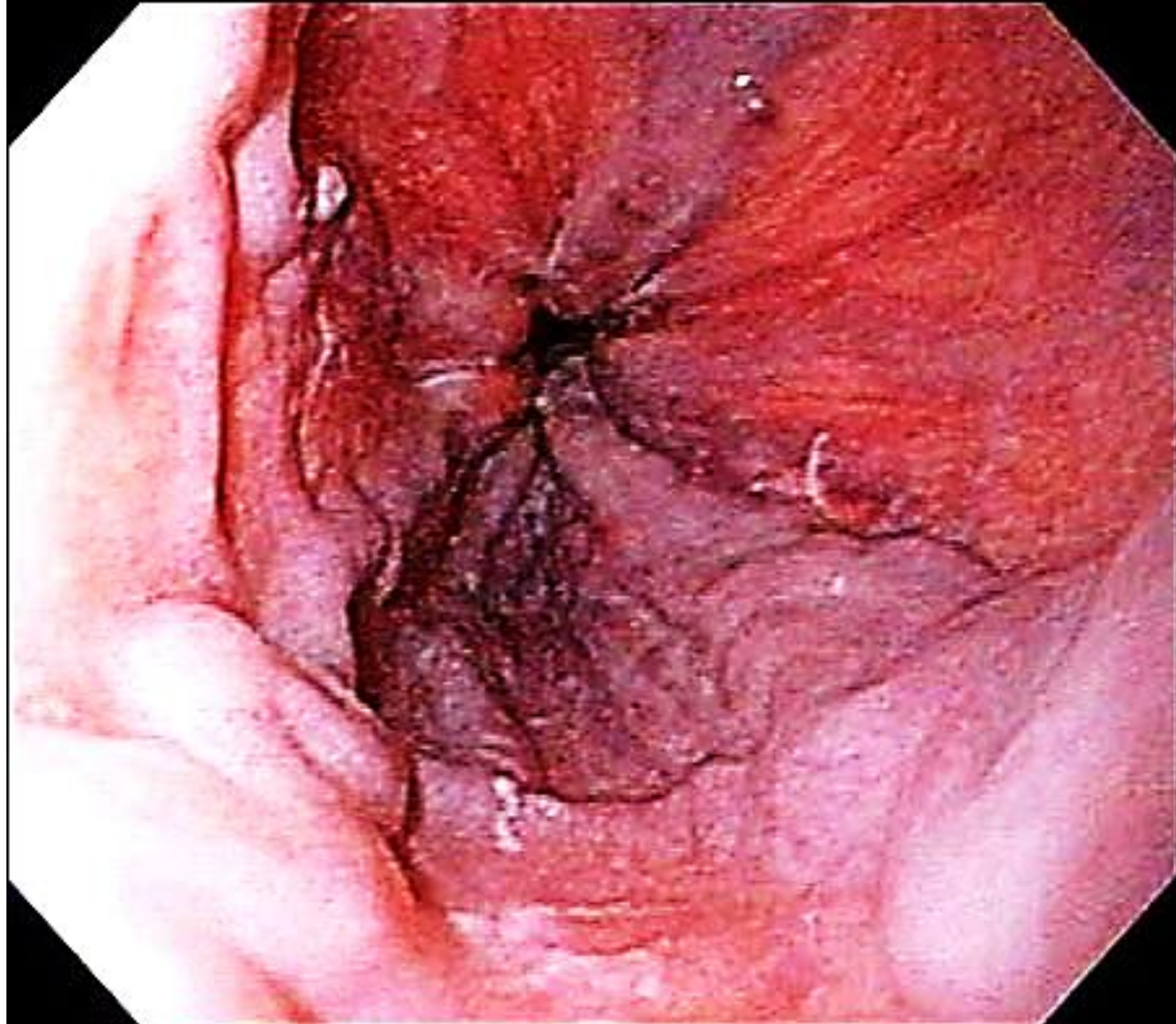
03082

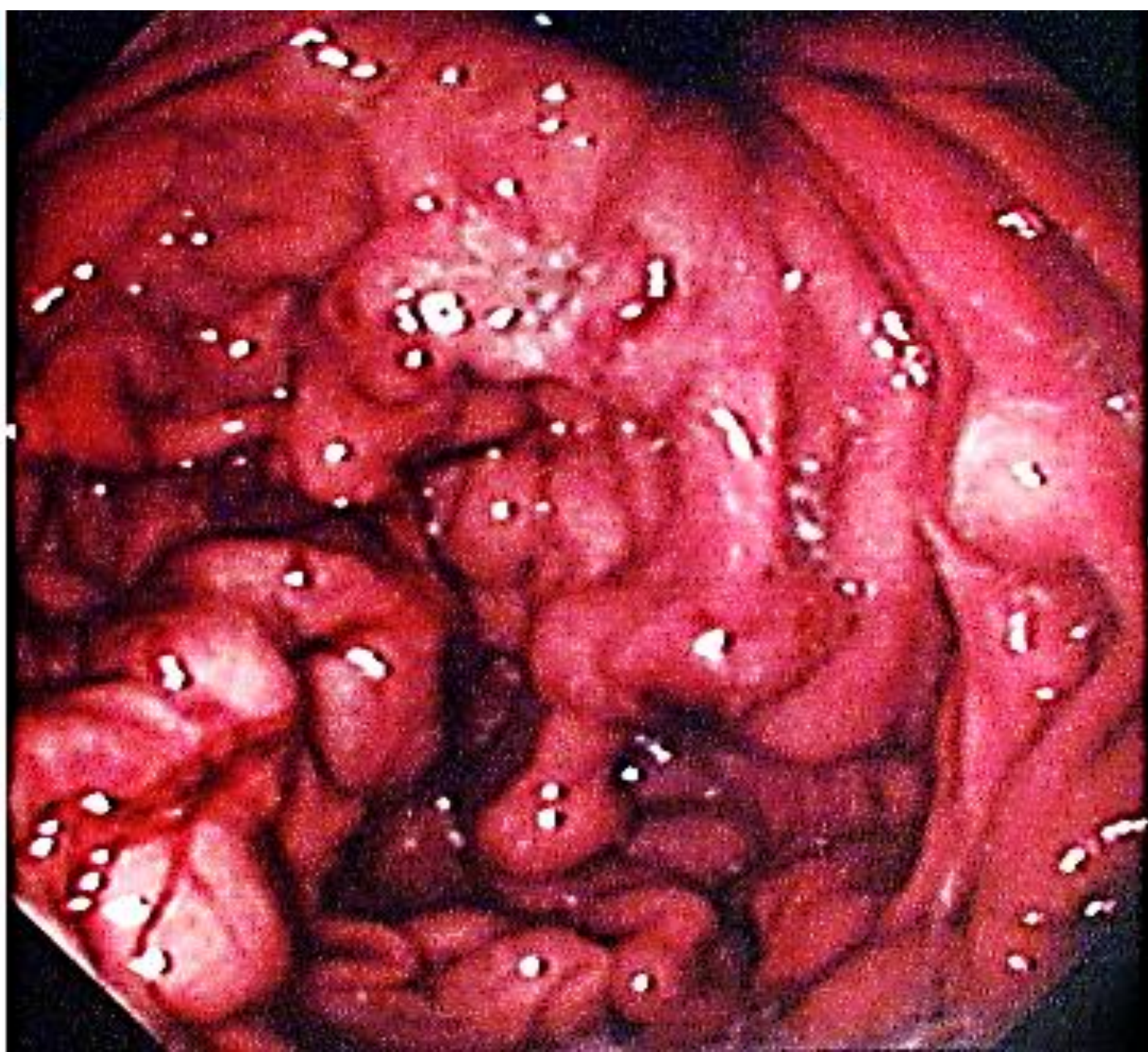7/20/2013
1:02:12

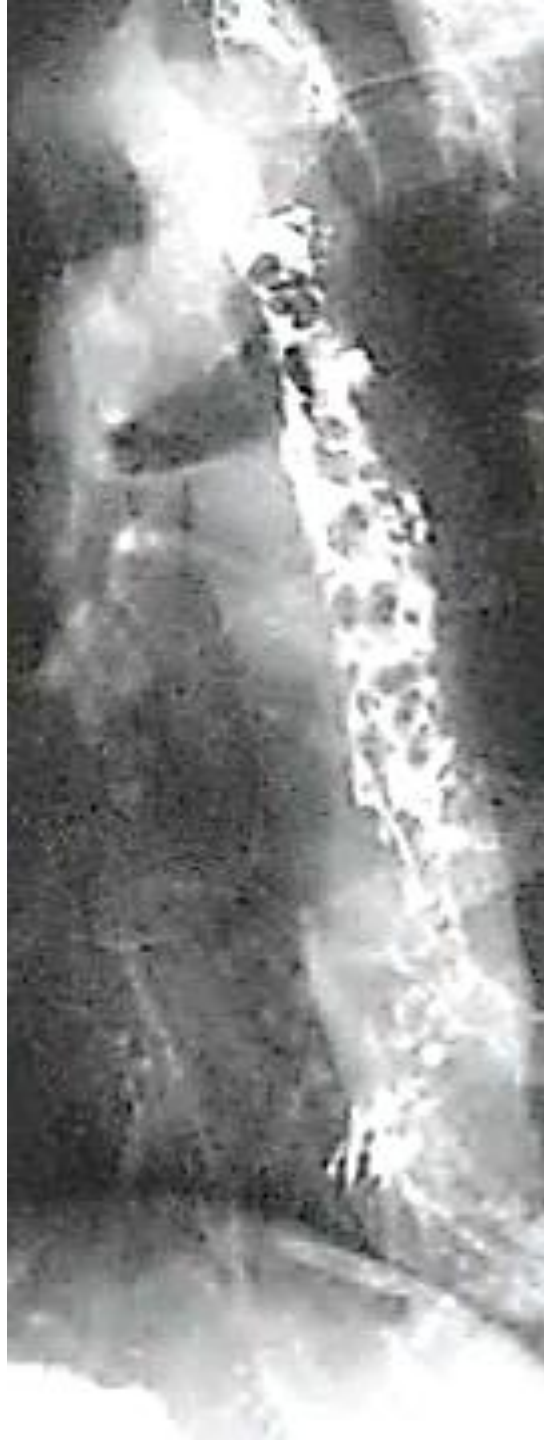F:4
5 G:N

iD

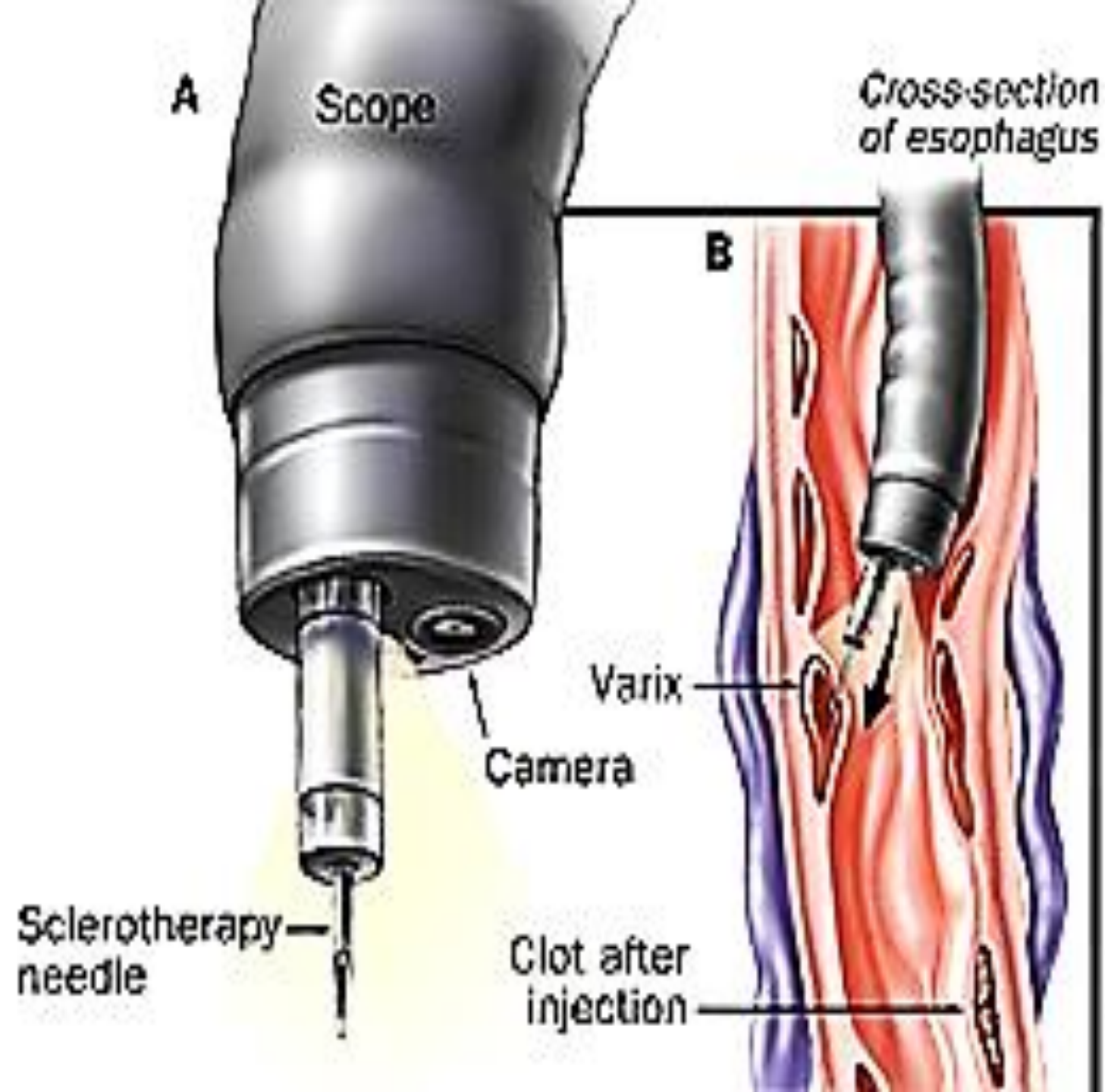






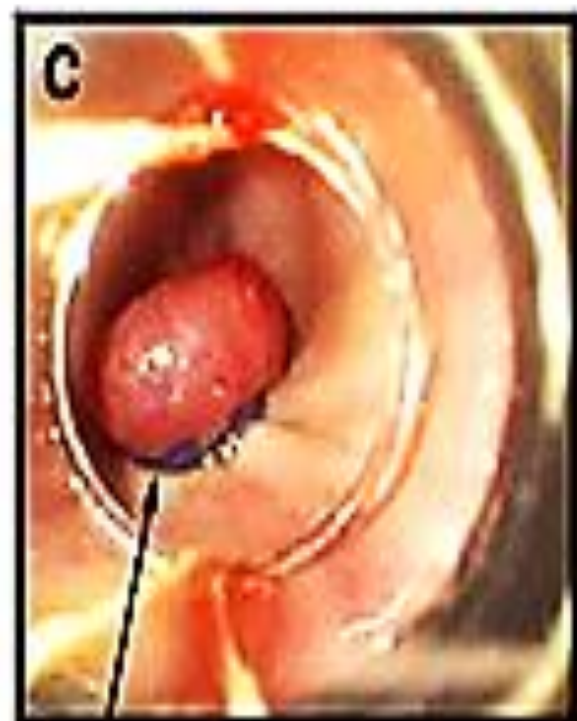
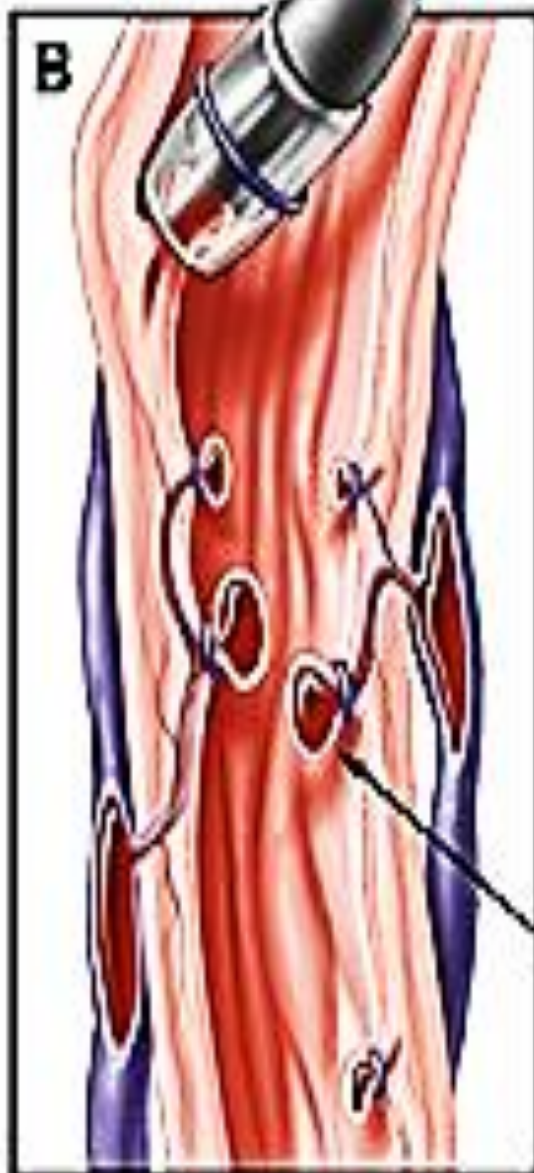
Differential Diagnosis



Scope

A Rubber Band
Ligation
System[®]



Banded
varices

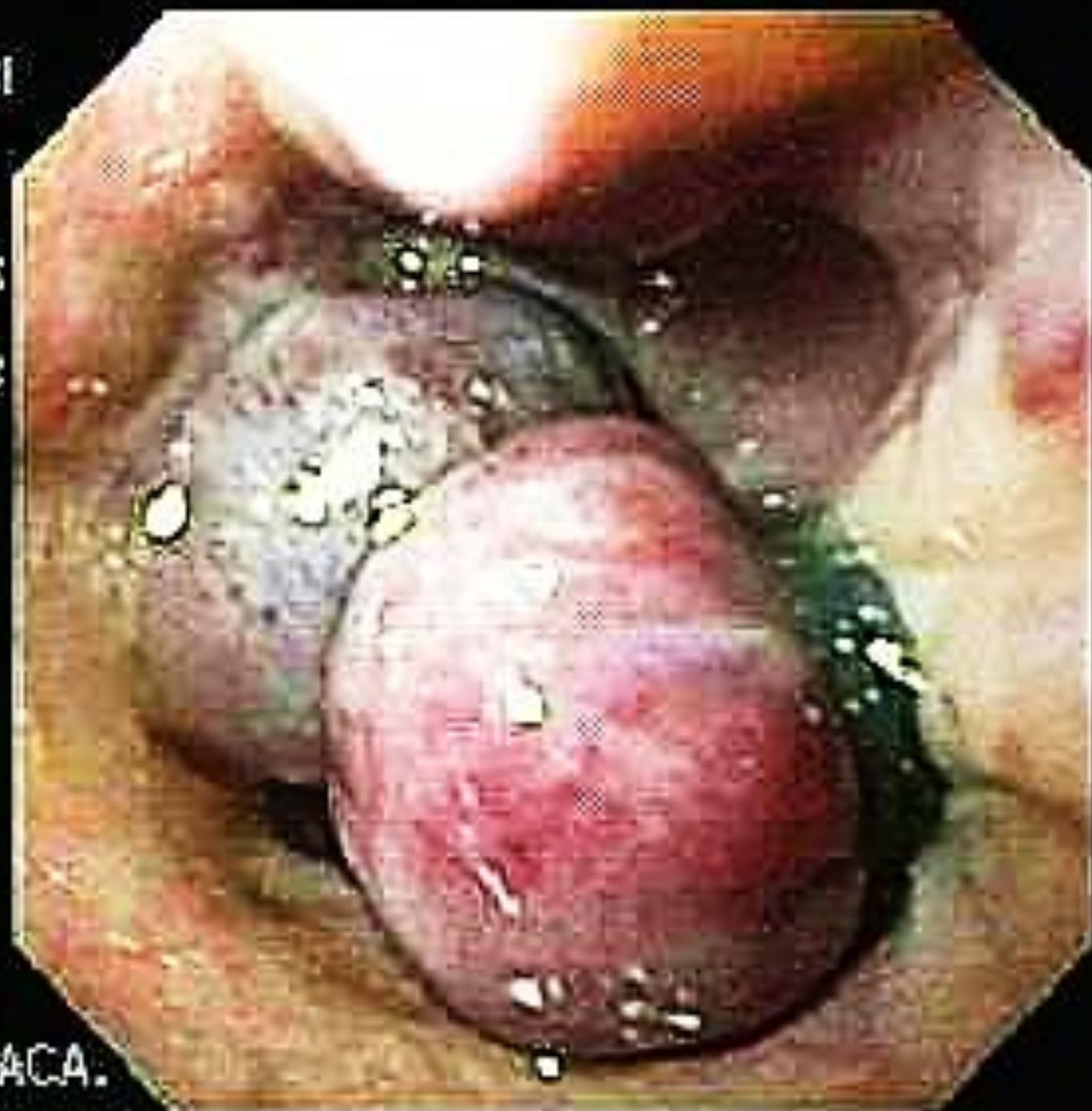YE 55820031

M 40
07/12/1963

09/27/2003
14:36:31

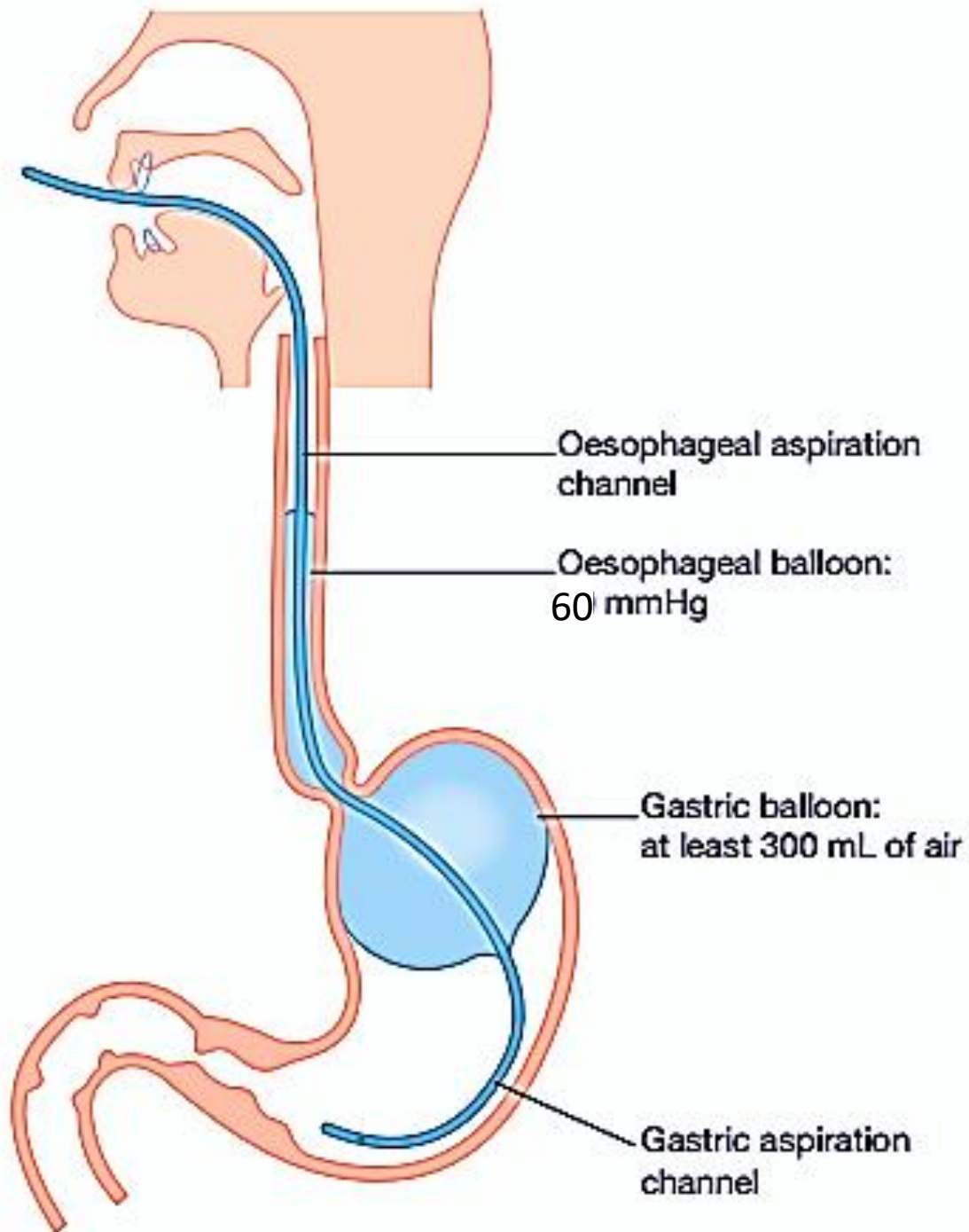
CVP:
D.F:
E:8 G:H

DR. MURRA SACA.

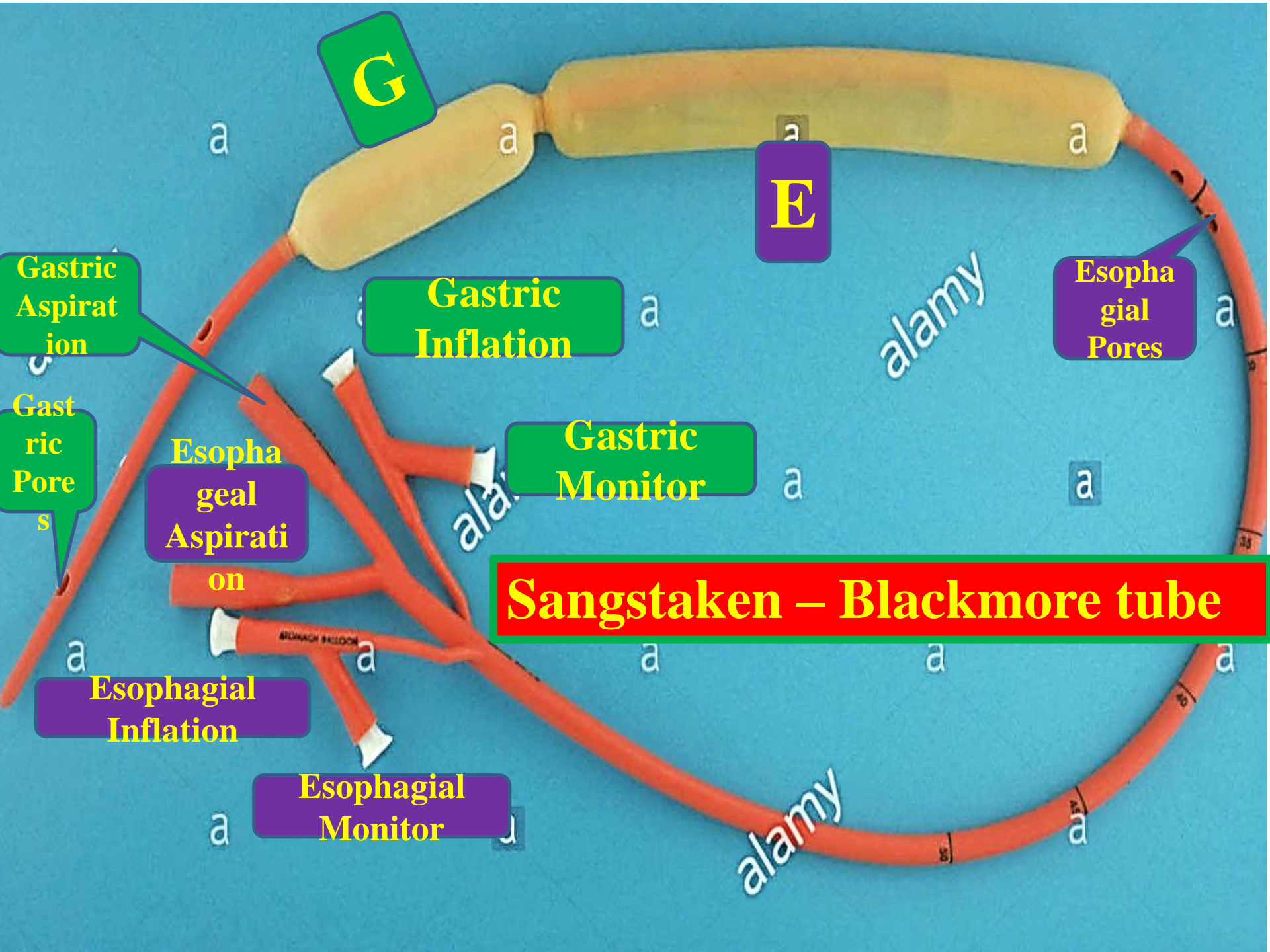


3- Balloon tamponade and self-expanding stents

- Balloon tamponade is effective for massive or refractory variceal bleeding but is only recommended as a 'bridge' to definitive treatment. If the rate of blood loss prohibits endoscopic evaluation, a Sengstaken–Blakemore tube or a Minnesota tube (addition of an oesophageal aspiration port) can be inserted to provide temporary haemostasis .
- Once inserted, the gastric balloon is inflated with 300 mL of air and retracted to the gastric fundus and the oesophagogastric varices tamponaded by inflation of the oesophageal balloon to 60 mmHg. The two remaining channels allow gastric and oesophageal aspiration, and the position of the tube is confirmed radiologically.
- A strict protocol for the management of balloon tamponade is important to avoid complications particularly oesophageal pressure necrosis.
- Recently, self-expanding covered metal oesophageal stents have also been employed for the emergency treatment of oesophageal varices and results are equivalent to balloon tamponade unless the bleeding site is intragastric.



Oesophageal and gastric balloon tamponade with a Sengstaken–Blakemore or Minnesota tube. The tube must be carefully managed.



G

E

Gastric Inflation

Gastric Monitor

Esophageal Pores

Esophageal Aspiration

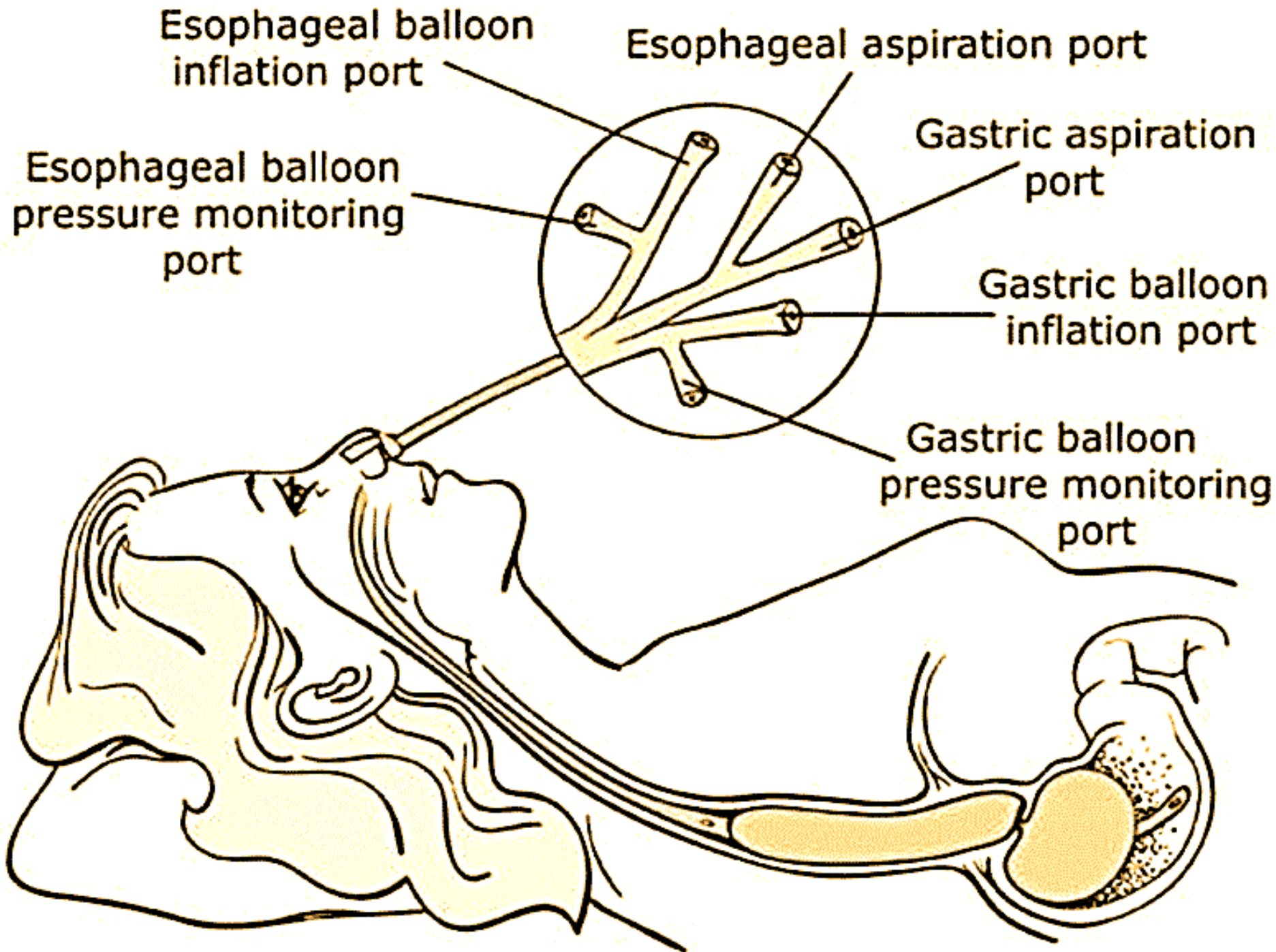
Sangstaken - Blackmore tube

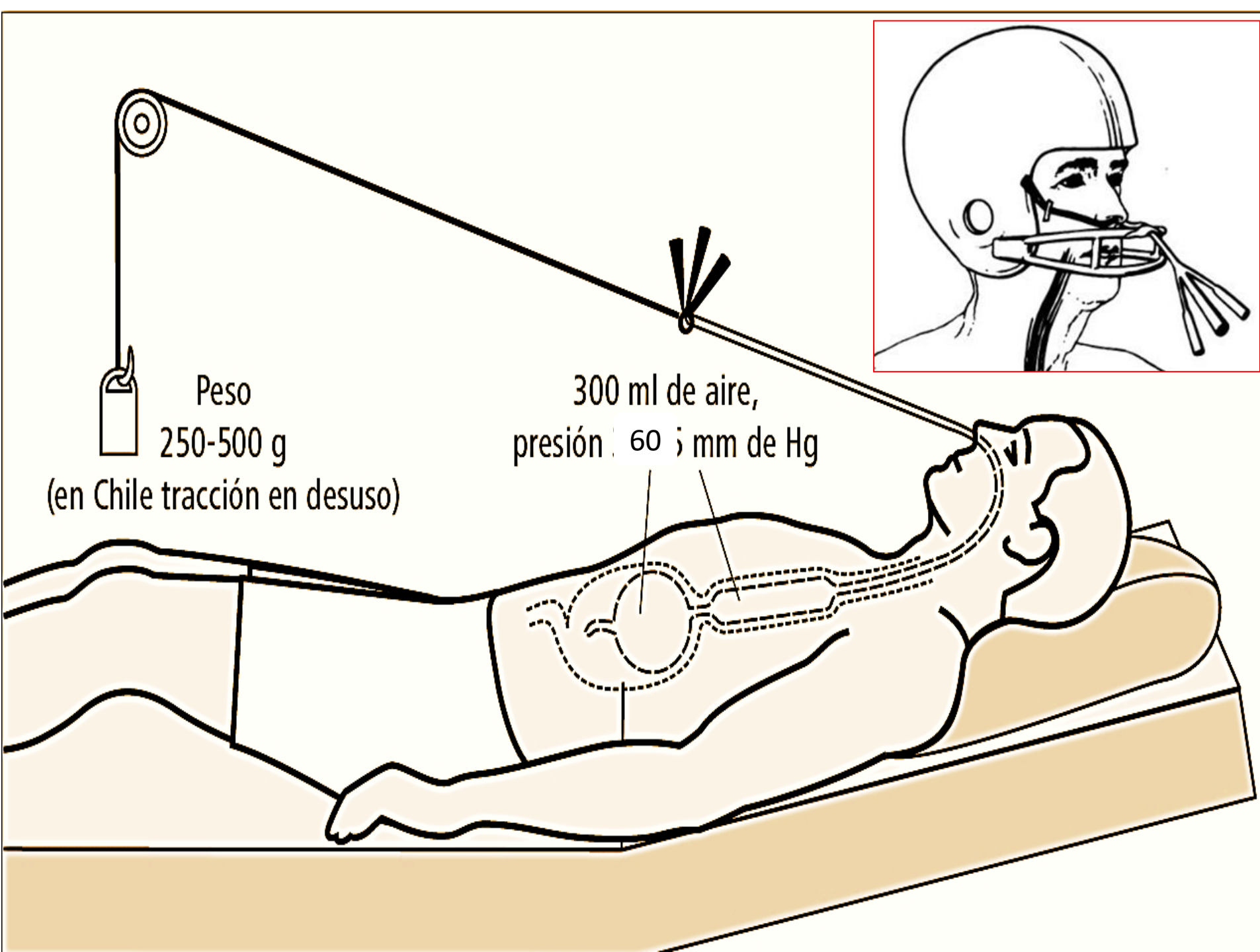
Esophageal Inflation

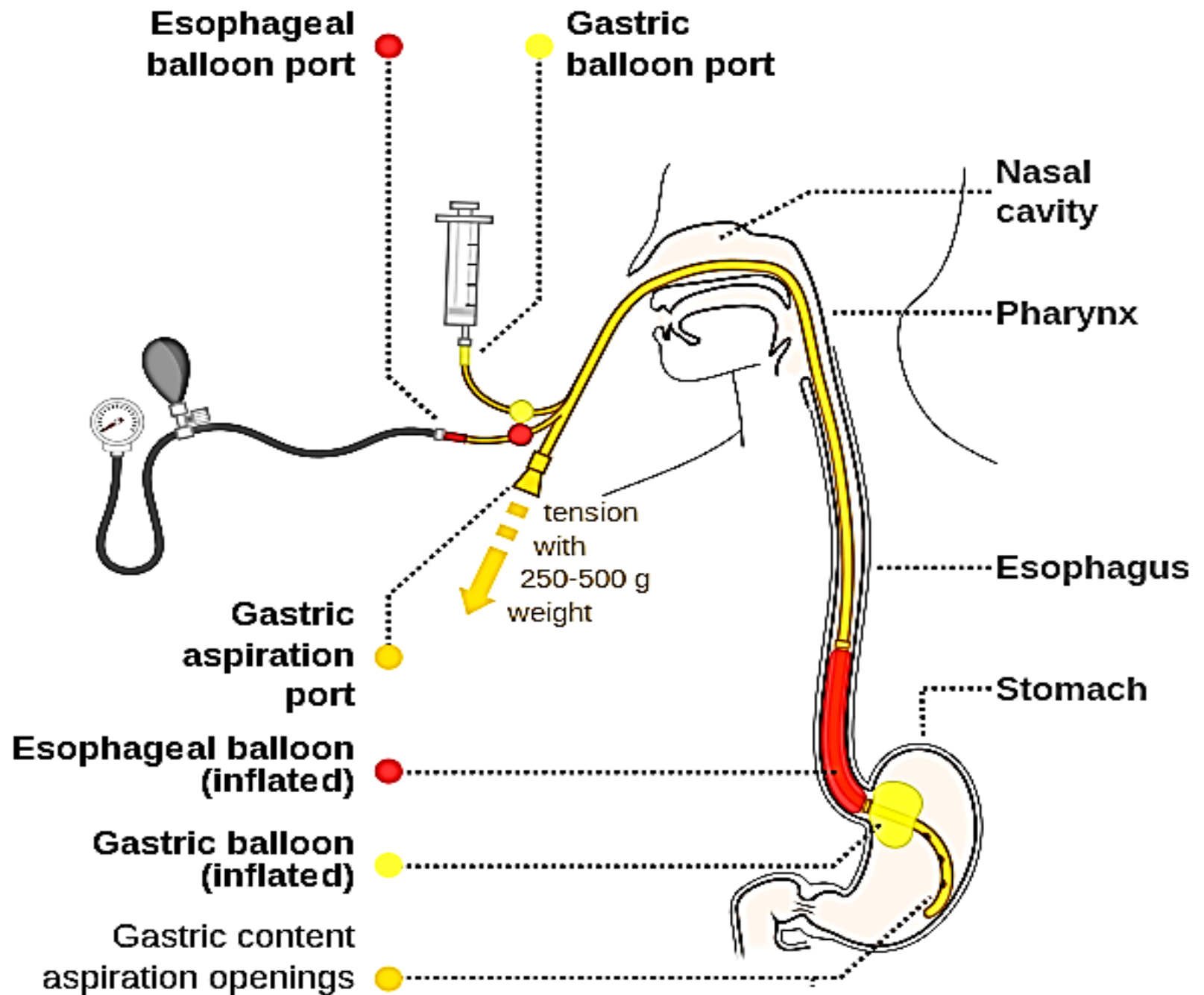
Esophageal Monitor

Gastric Aspiration

Gastric Pores



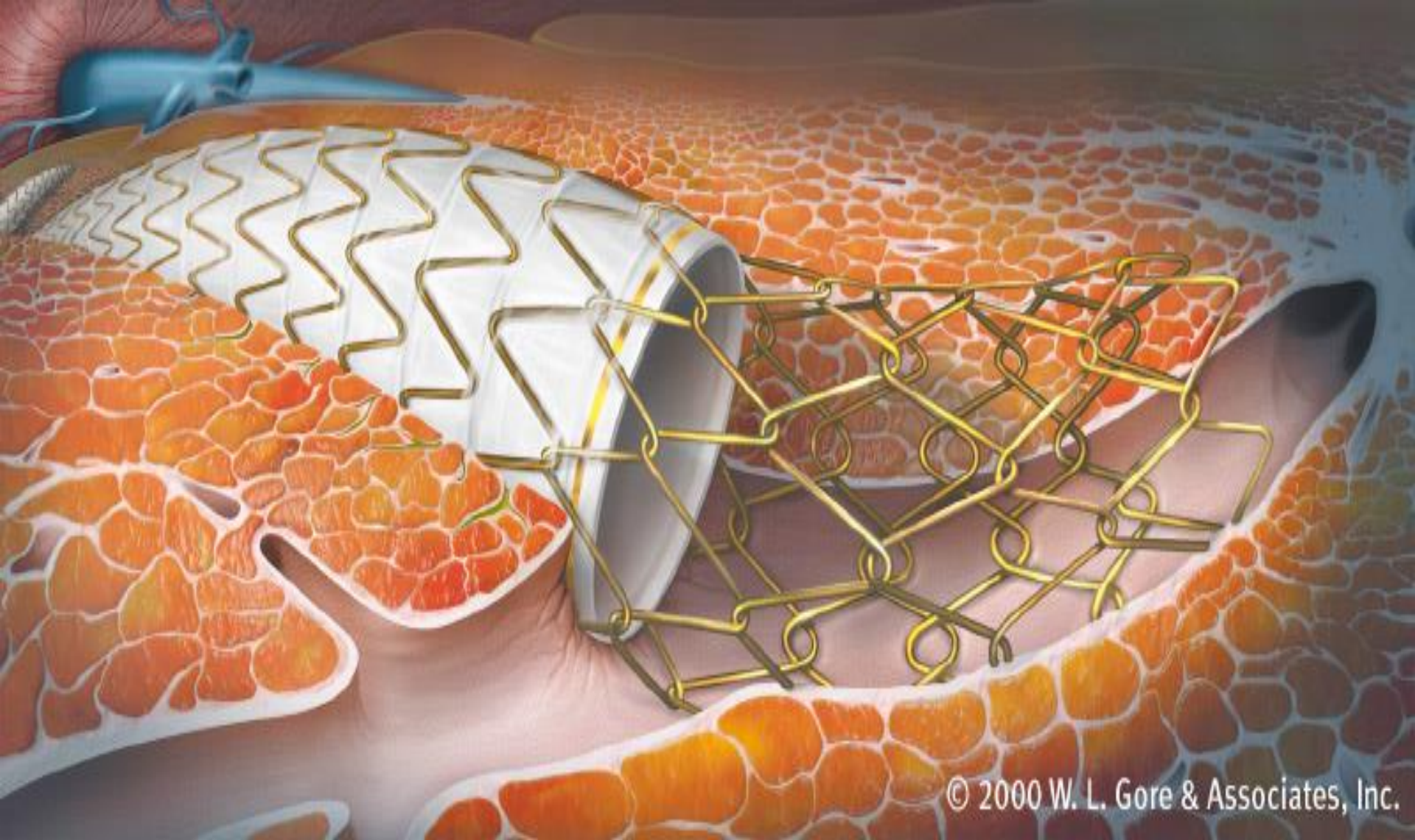




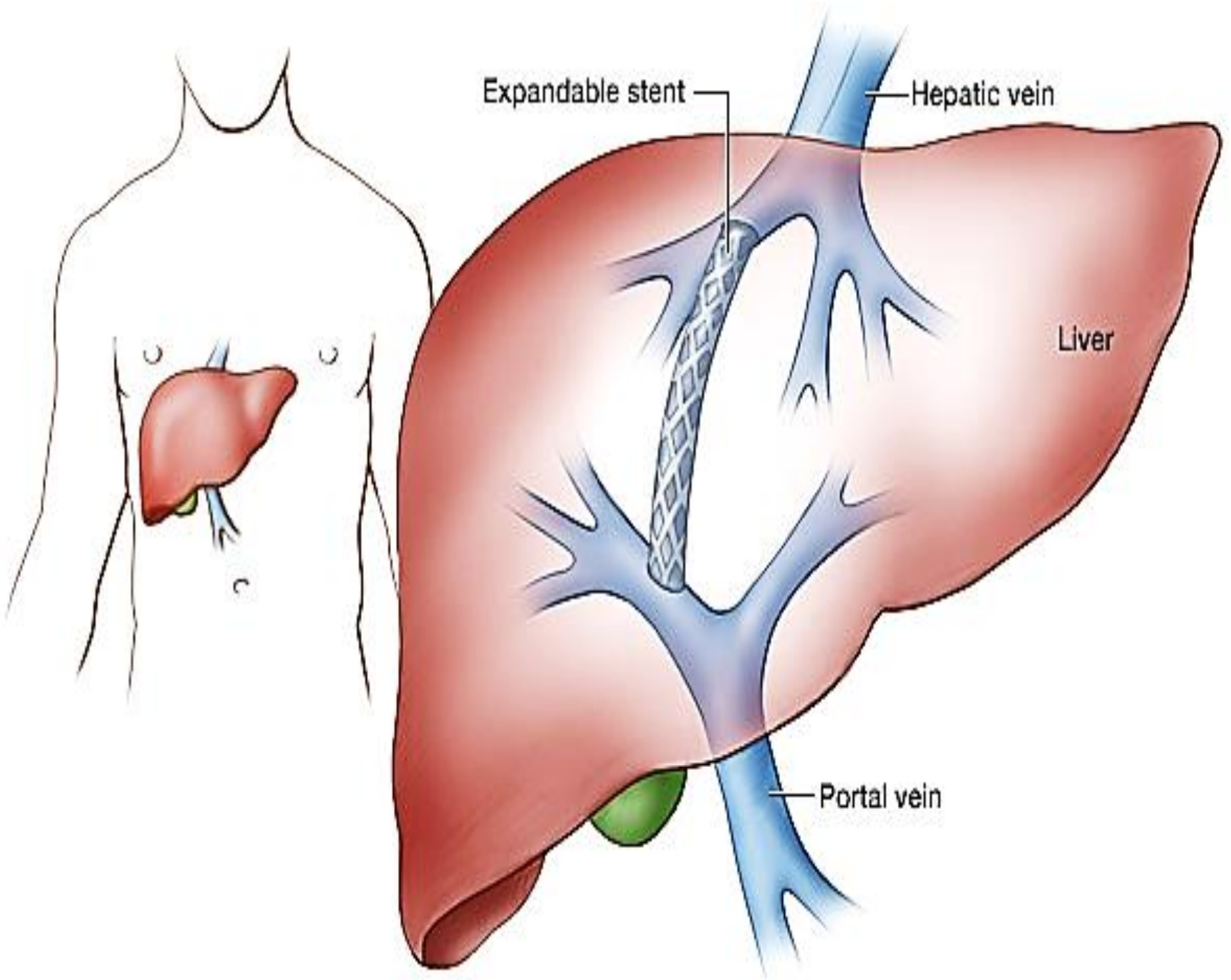
4- Transjugular intrahepatic portosystemic stent shunts

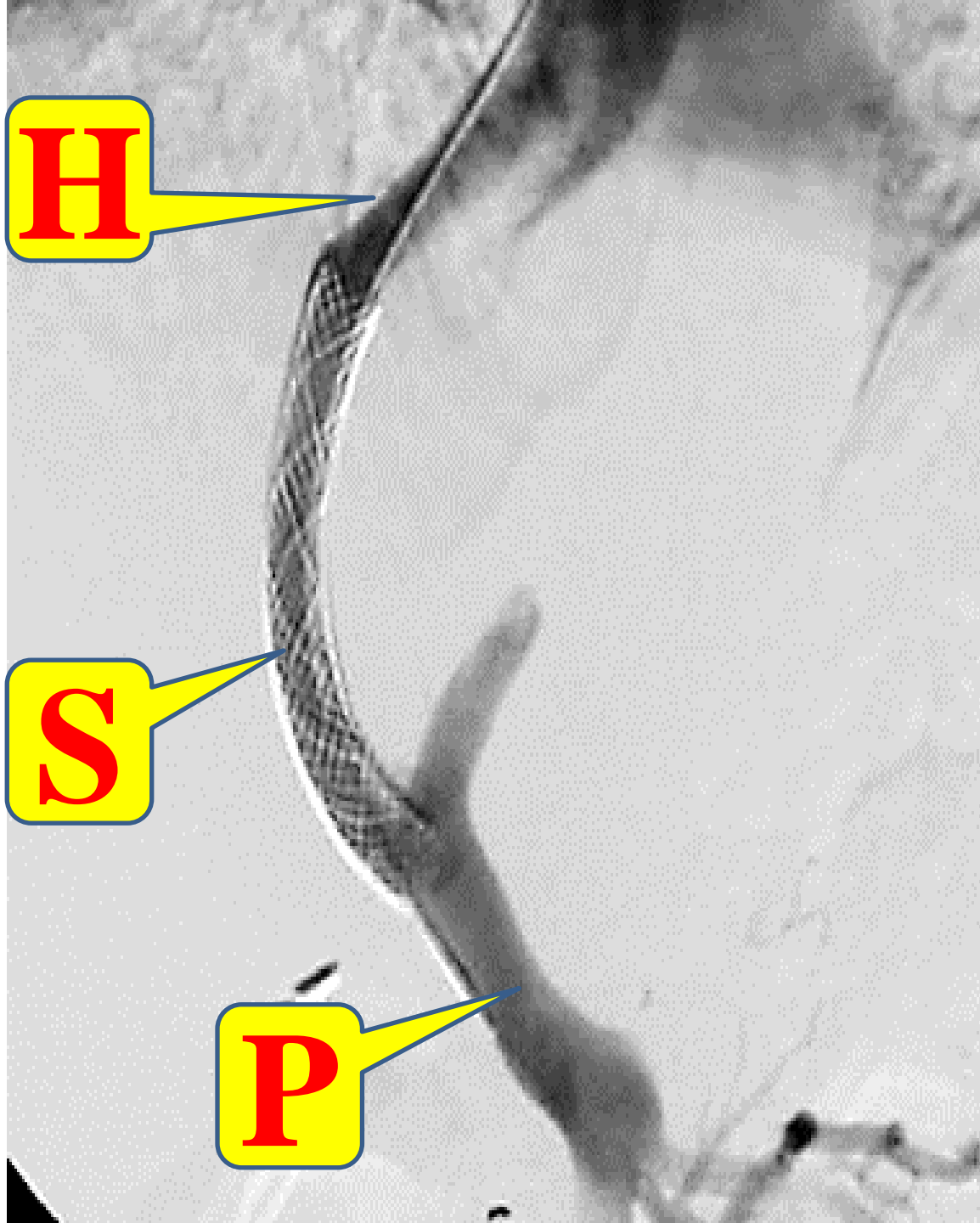
- The emergency management of variceal haemorrhage is extremely difficult when pharmacological and endoscopic therapies have failed.
- Treatment of these patients now relies on TIPSS, a radiological procedure first described in 1969 but not widely available until the development of endovascular stents in 1985. TIPSS has replaced surgical portocaval shunt and is now accepted as the preferred method for treating refractory portal hypertension. A TIPSS is inserted under local anaesthetic, analgesia and sedation using fluoroscopic guidance and ultrasonography. Via the internal jugular vein, superior

- vena cava and hepatic vein, a guidewire is inserted through the hepatic parenchyma into a branch of the portal vein. The tract is dilated; a metallic stent is then inserted and expanded, forming a portovenous channel .A satisfactory drop in portal venous pressure is usually associated with good control of the variceal haemorrhage.
- The main early complication is perforation of the liver capsule, with potentially fatal intraperitoneal haemorrhage. TIPSS occlusion may produce further variceal haemorrhage and occurs more commonly in patients with well-compensated liver disease and good synthetic function. The incidence of post-TIPSS encephalopathy is comparable to that following surgical shunts (40%) and due to portal blood avoiding hepatic detoxification, if severe, flow is reduced by inserting a smaller stent. The main contraindication to TIPSS is portal vein occlusion, and long-term stenosis occurs in 50% of patients at 1 year.



© 2000 W. L. Gore & Associates, Inc.

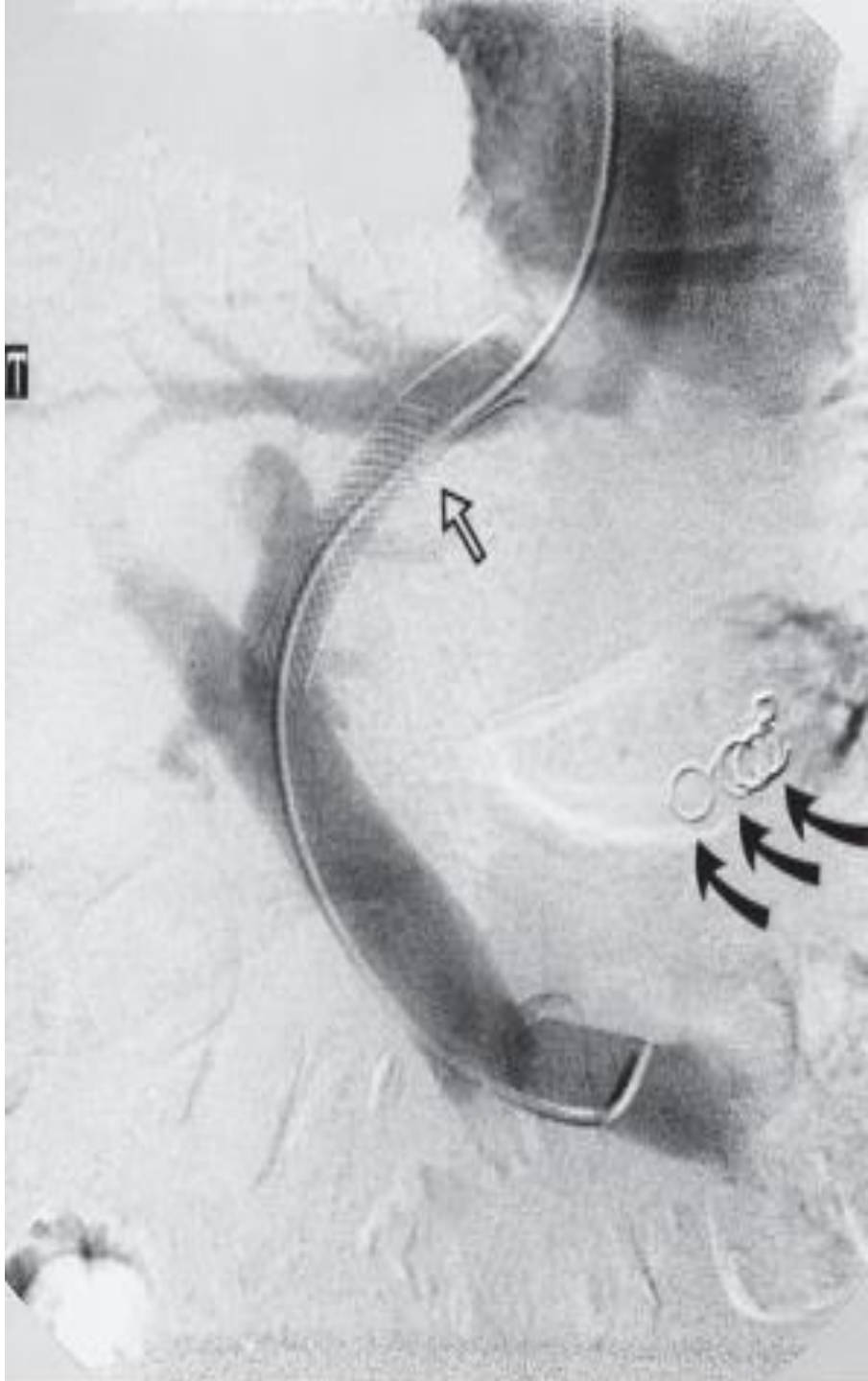




H

S

P



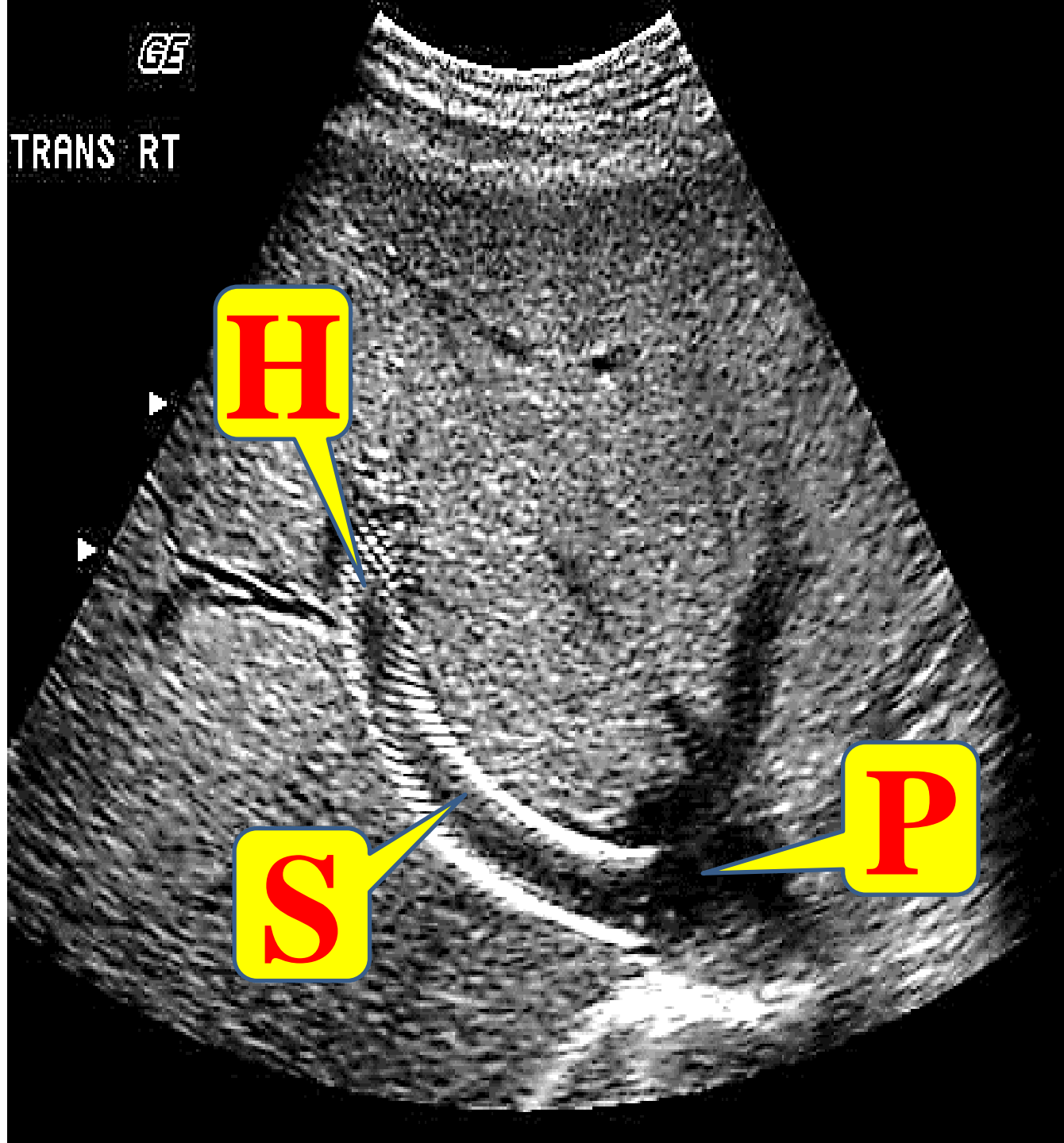
GE

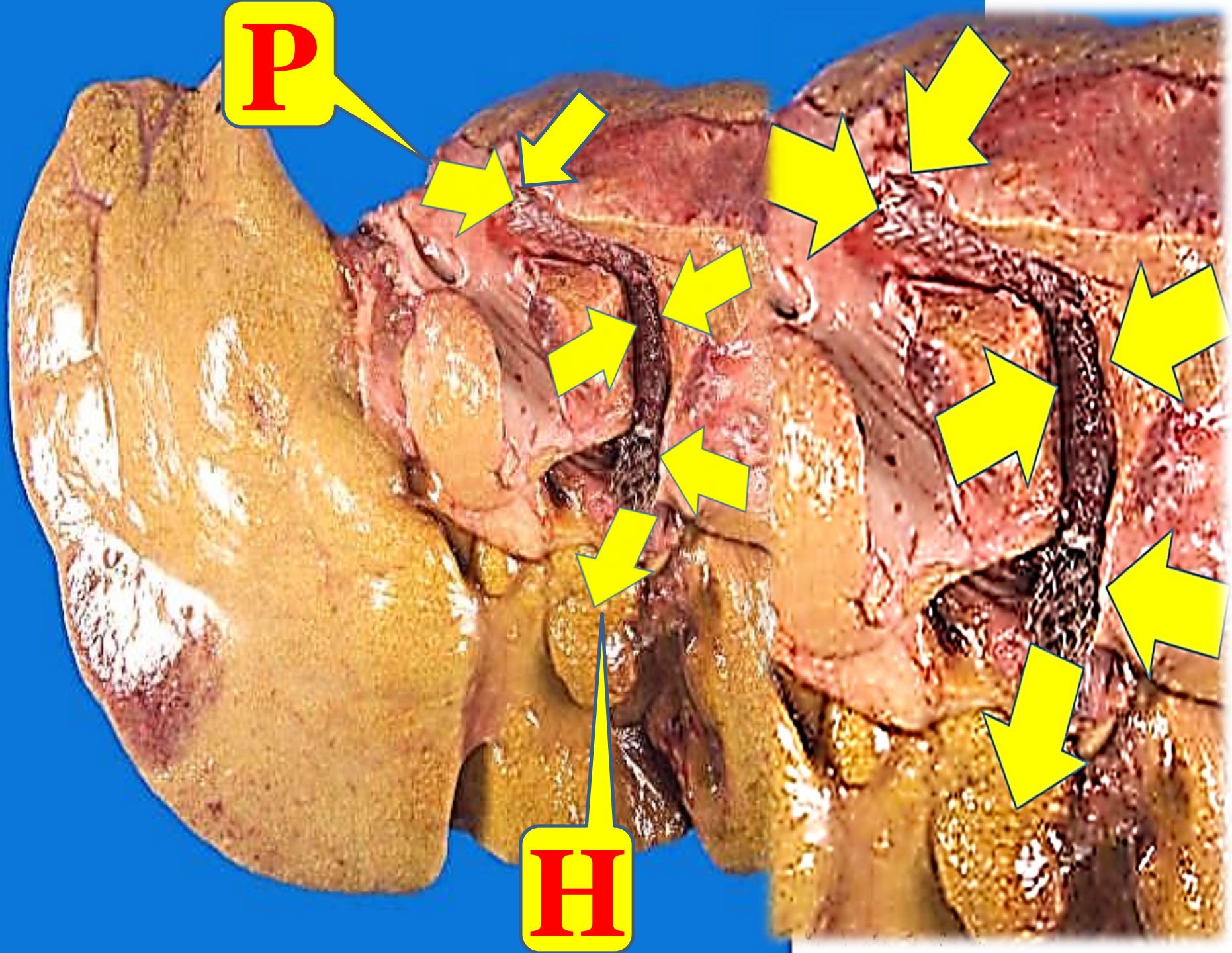
TRANS RT

H

S

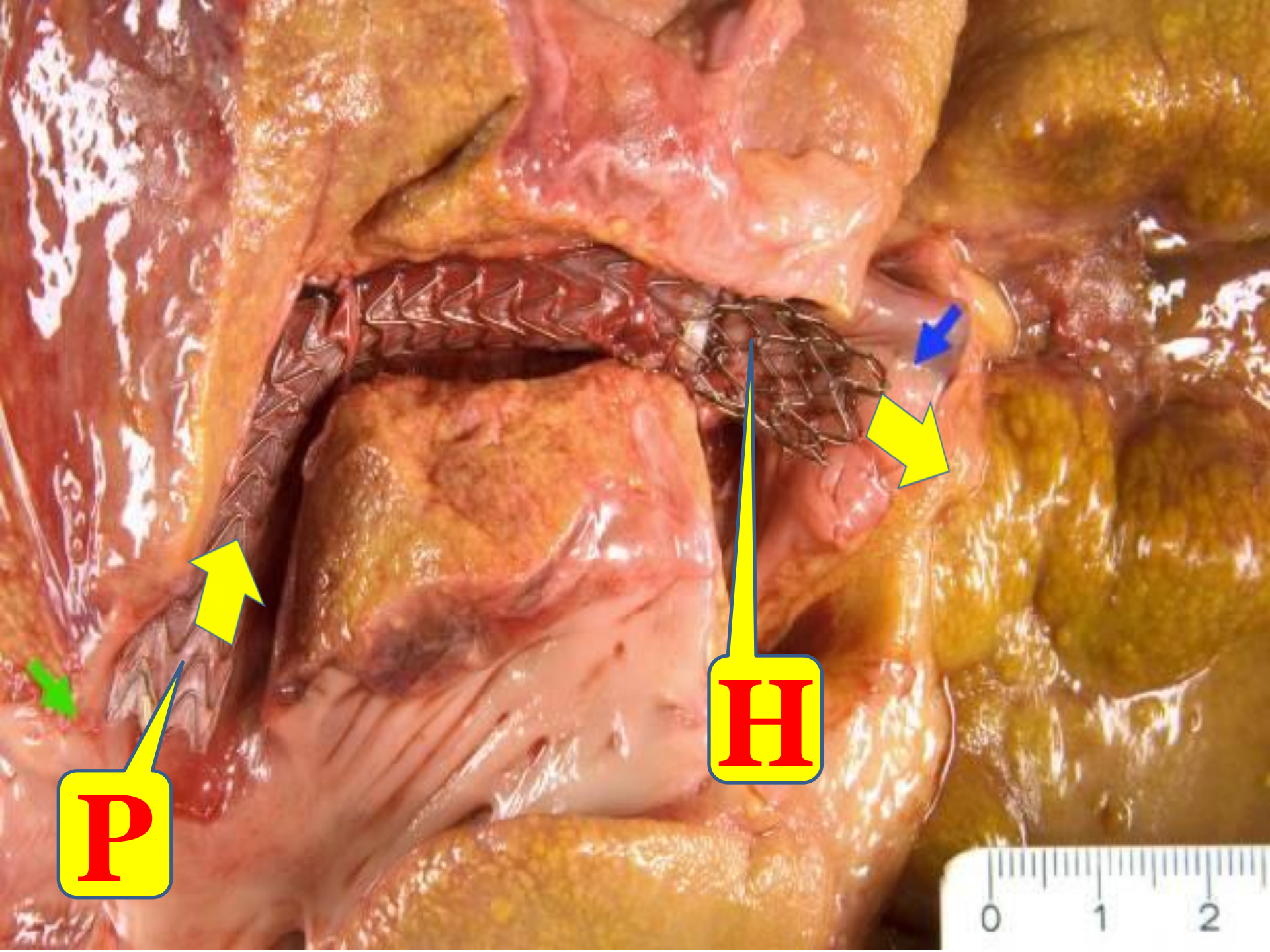
P





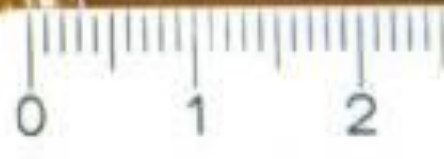P

H



P

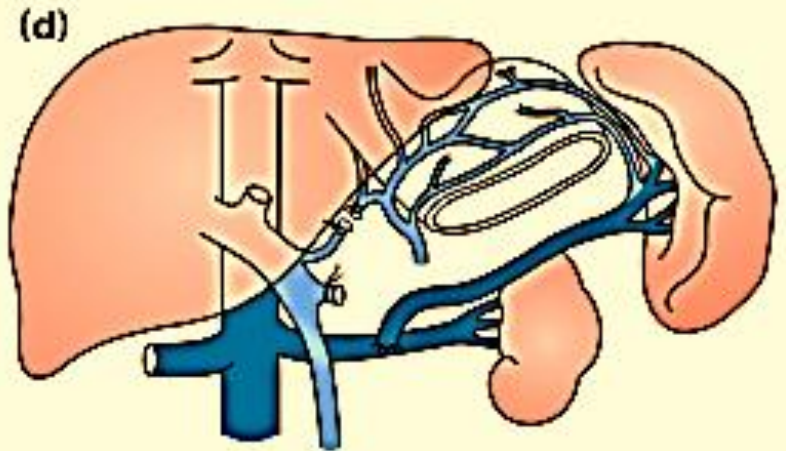
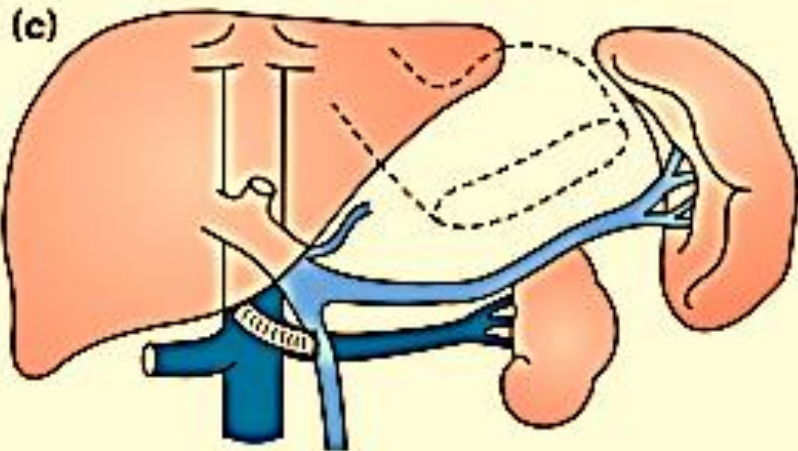
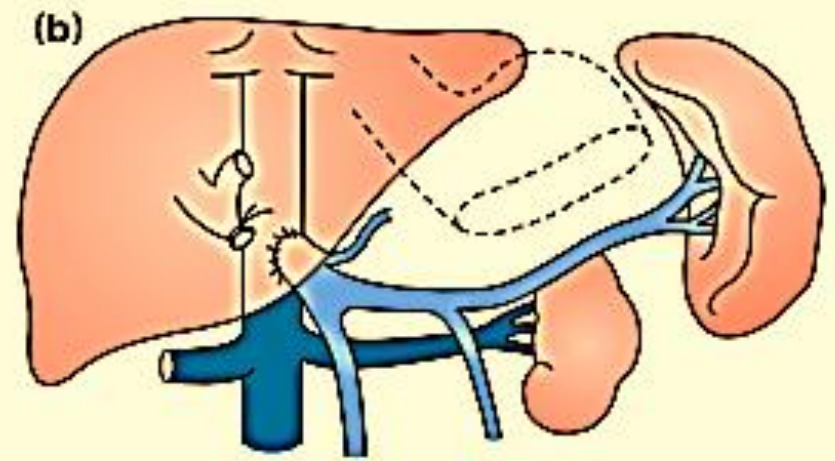
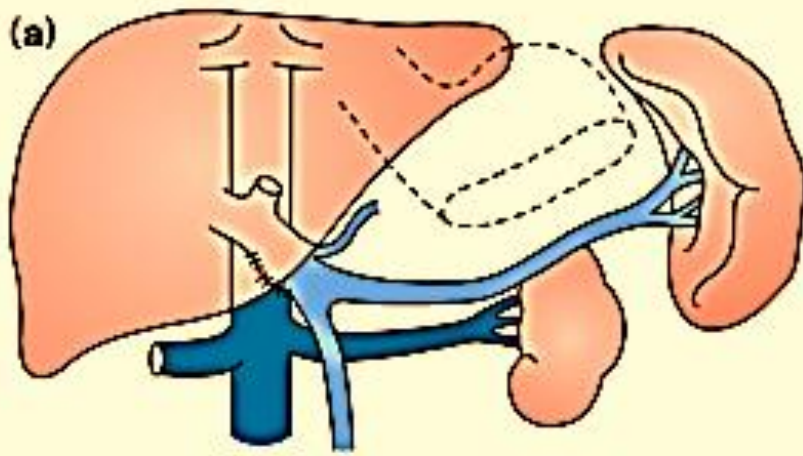
H



5- Surgical Shunts

- The increasing availability of liver transplantation and TIPSS has greatly reduced the indications for surgical portosystemic shunts, which, because of their high morbidity and mortality, are now rarely considered for variceal haemorrhage.
- The current indication is the failure of medical management in non-cirrhotic patients with extrahepatic portal vein occlusion. Surgical shunts selectively prevent rebleeding from oesophageal or gastric varices by reducing portal pressure and are divided into selective, splenorenal and non-selective portocaval.

- Selective shunts attempt to preserve hepatoportal blood flow while decompressing the left side of the portal circulation, which is responsible for oesophageal and gastric varices .
- Selective shunts have a lower incidence of encephalopathy but there is no evidence that prophylactic shunting is beneficial.



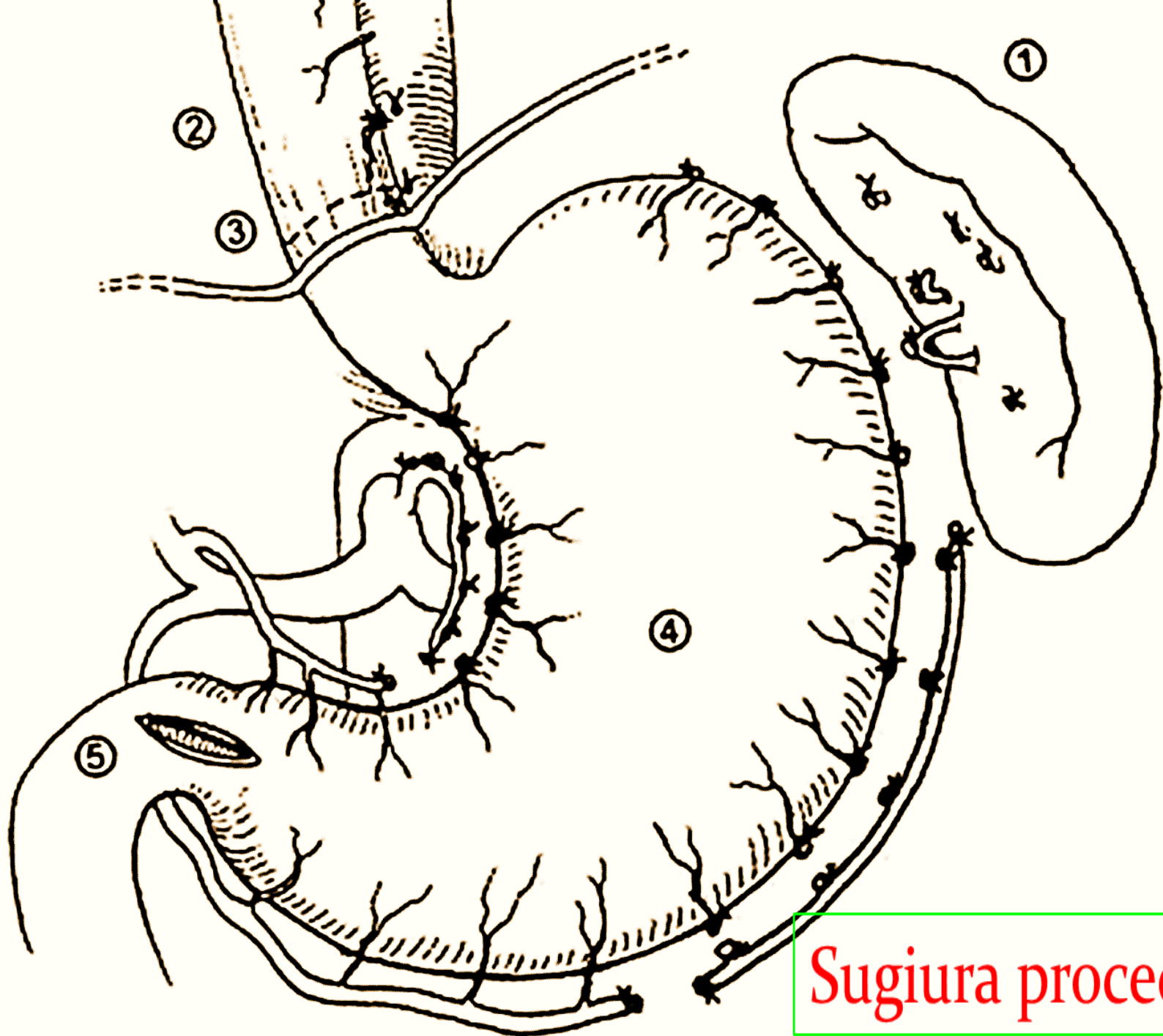
Surgical shunts for portal hypertension involve shunting portal blood into the systemic veins. This commonly involves (a) a side-to-side portocaval anastomosis or (b) end-to-side portocaval mesocaval (c) 'H graft' or (d) splenorenal anastomoses.

Recurrent or refractory variceal bleeding

- **Sugiura procedure**
- It combines splenectomy with oesophagogastric devascularisation, permanently interrupting the intraoesophageal portacaval shunt while preserving perioesophageal varices.
- The surgery is performed on the stomach wall and all venous tributaries are divided as for highly selective vagotomy except on both the lesser and greater curves.
- The upper half of the stomach and 8–10 cm of oesophagus are cleared (less than originally described but avoiding entering the chest).
- After devascularisation with careful preservation of the collateral channels and the vagus, a large oesophageal stapler is introduced into the lower oesophagus, which is transected just above the cardia.

Splenectomy and gastro-oesophageal devascularisation.

- **It consists of :**
- **Devascularization of the abdominal esophagus and cardia and re-anastomosis.**
- **Splenectomy**
- **Selective vagotomy with Pyloroplasty**

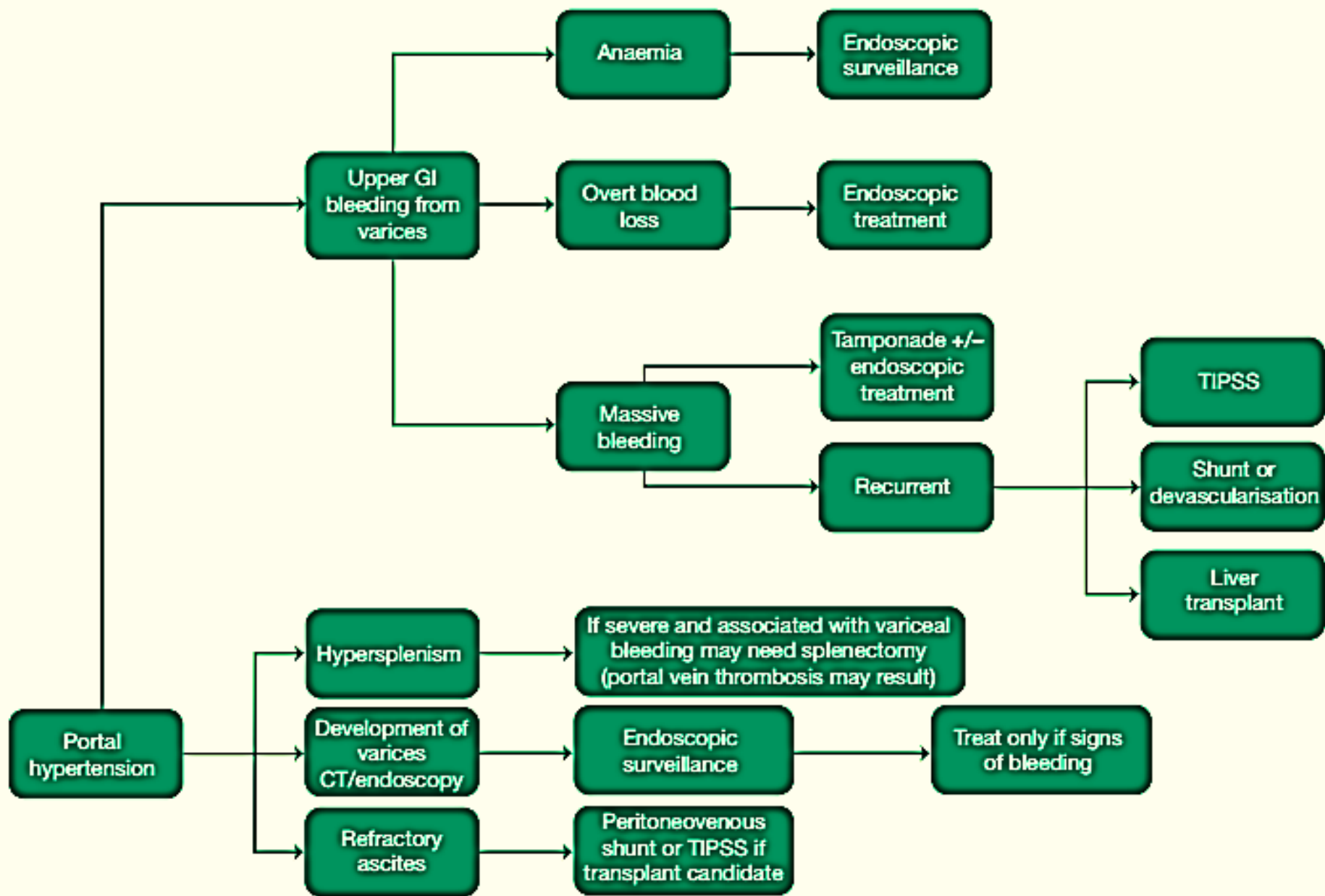


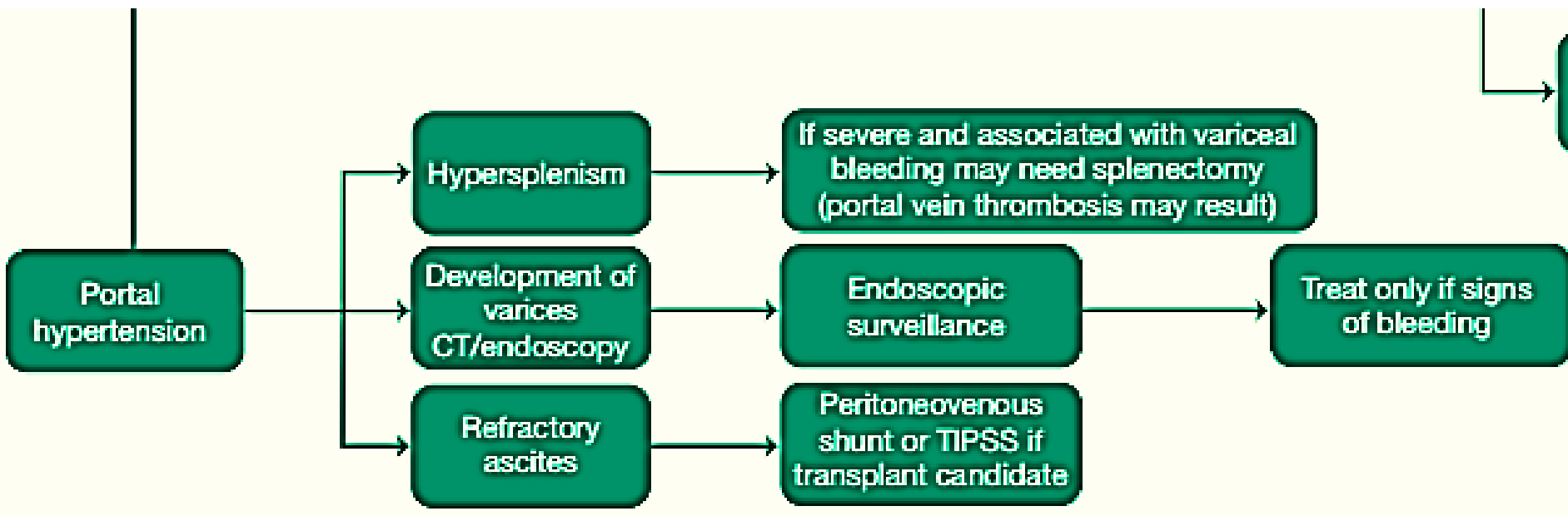
Sugiura procedure

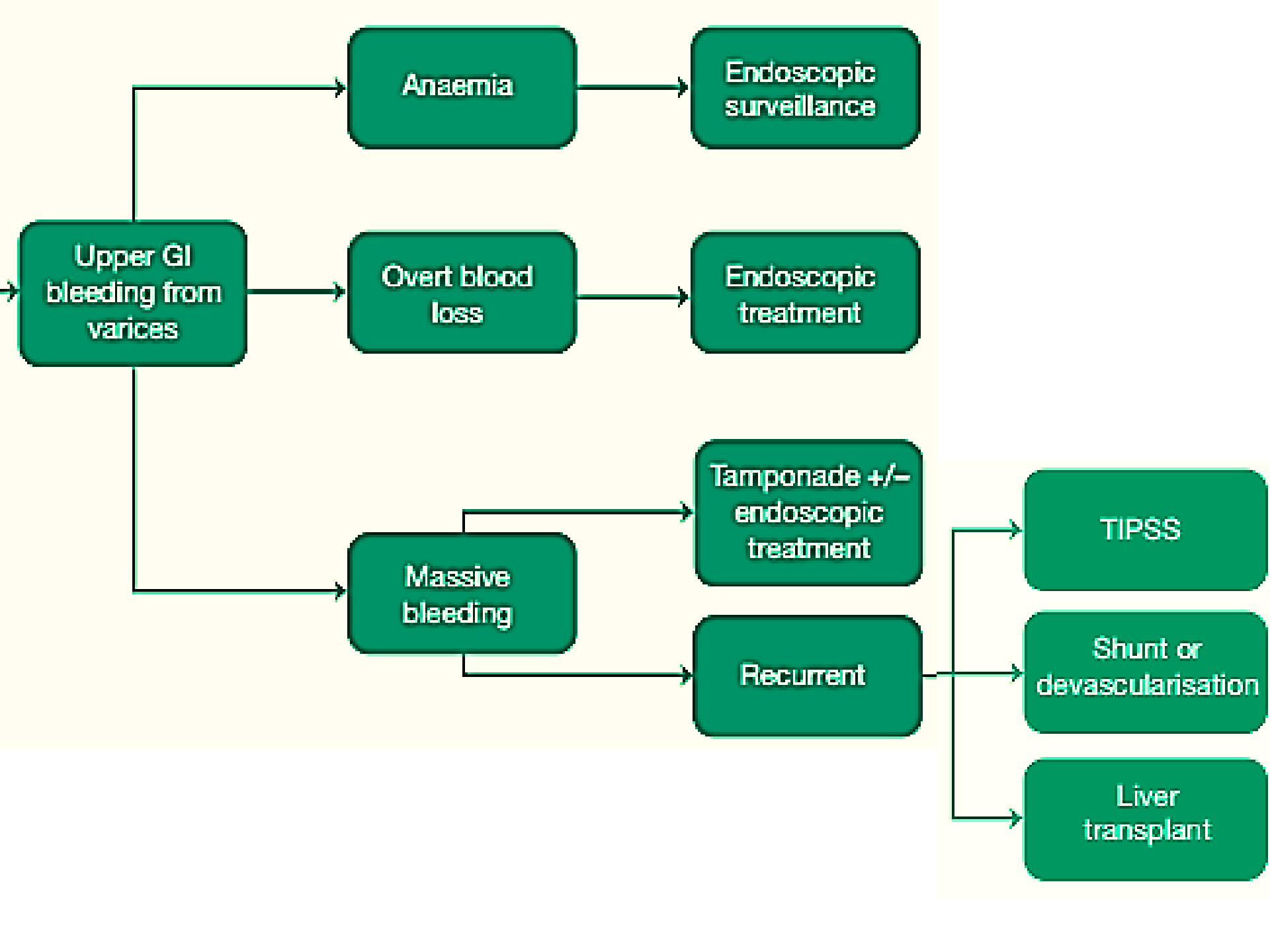
Liver Transplantation

- Liver transplantation is the only therapy that treats portal hypertension and the underlying liver disease and may ultimately be required in patients with variceal bleeding.
- Previous surgical shunts increase the complexity and morbidity of orthotopic liver transplantation and TIPSS should be the preferred management .

Management of Complications







Upper GI bleeding from varices

Anaemia

Endoscopic surveillance

Overt blood loss

Endoscopic treatment

Massive bleeding

Tamponade +/- endoscopic treatment

Recurrent

TIPSS

Shunt or devascularisation

Liver transplant

Management of bleeding oesophageal varices

- Blood transfusion
- Correct coagulopathy
- Oesophageal balloon tamponade (Sengstaken–Blakemore or Minnesota tube)
- Drug therapy (terlipressin ,octreotide and somatostatin)
- Endoscopic sclerotherapy or banding.
- Assess portal vein patency (Doppler ultrasonography or CT)
- TIPSS
- Surgery
- Portosystemic shunts
- Splenectomy and gastric devascularisation (Sugiura procedure)
- Liver transplant.

حَمْدُ اللَّهِ

PRAISE BE TO ALLAH