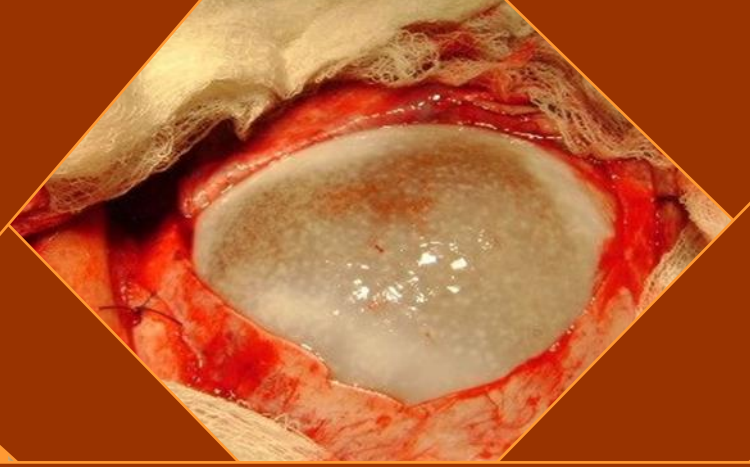

Medical Parasitology

Prof. Dr. Ahmed Ali Mohammed



Lec. 6 Helminths - Cestodes

2. Class: Cestoidea (Tapeworms) General characteristics of cestodes

Cestodes belong to class Cestoidea and orders Pseudophyllidea and Cyclophyllidea. They are segmented, dorsoventrally compressed and tape-like, hence called tapeworms. They vary from a few millimeters to several meters in length. The most conspicuous features of tapeworms are the lack of a mouth or digestive cavity. Adult cestodes, or tapeworms, live attached to the mucosa in the small intestine and absorb food from the intestine of the host.

The adult worm consists of three parts: scolex (head), neck and strobila (body or trunk). **The scolex** is a more or less distended muscular organ. It serves as an organ of attachment. In the parasites of the order Pseudophyllidea, the scolex does not possess suckers, but it normally possesses a pair of longitudinal grooves (bothria) which help in the attachment of the parasite to the small intestine of the host. Whereas the scolex of the parasites of the order Cyclophyllidea normally possesses four suckers. The rostellum (apical protrusion on scolex) is usually present, but may be absent. The rostellum may be armed with hooks or not.

The Neck is the portion of the worm which lies immediately behind the scolex and from which proglottids of the body are continuously generated. The scolex and neck are important structures, since infection persists as long as these portions of the worm remain attached to the host's intestinal wall, even though the greater portion of the strobila may have become free and been evacuated.

The strobila is composed of a chain of proglottids or segments. Three types of proglottids are recognized: immature, mature and gravid. Those near the neck are young immature segments where male and female organs are not differentiated. Behind them are mature segments. These are larger units, each of which contains one and in some species two full sets of male and female genital organs. Therefore, each individual worm is hermaphrodite (monoecious). The gravid proglottids are those farthest away from the scolex. In them the

primary genitalia have atrophied and are completely occupied by the uterus filled with eggs. There is no specialized alimentary or digestive system. Nutrients are absorbed through the worm's integument. The scolex is strictly an organ for attachment, and it does not serve to collect food. Body cavity is absent. Rudimentary (primitive) excretory and nervous systems are present.

The egg in pseudophyllidean cestodes is ovoid, operculated and does not contain any embryo when first laid. In cyclophyllidean cestodes the egg is not operculated and has two coverings. The inner which surrounds the embryo is known as embryophore and the outer is thin and is known as egg-shell. The egg, when first laid, contains a six-hooked (hexacanth) embryo known as oncosphere. In some cases the egg-shell is so thin that it is lost before the egg reaches the exterior with the feces. In such cases the embryophore becomes thick and radially striated for the protection of the embryo.

Life cycle

Cestodes complete their life cycle in two different hosts. However, *Hymenolepis nana* is an exception which is capable of completing its life cycle in a single host. Man is definitive host for most tapeworms which cause human infection. An important exception is *Echinococcus granulosus* (dog tapeworm) for which dog is the definitive host and man is the intermediate host. For *Taenia solium* (pork tapeworm) man is ordinarily the definitive host, but sometimes man acts as the intermediate host and harbors the larval form of this parasite.

The intermediate hosts are mammals, fish or arthropods. They harbor larval stages of the parasite. In the majority of the cestode infections, only one intermediate host is needed. However, in *Diphyllobothrium latum*, two intermediate hosts are required.

Pathogenicity

Tapeworm infections are acquired either by ingestion of the eggs or of larval stages present in meat, fish, etc. Adult tapeworms are intestinal parasites; they tend to do little physical damage to their host. However, large infections can lead to obstruction of the bowel. They may cause diarrhea and loss of appetite. In some cases, absorption of certain nutrients, e.g., vitamin B₁₂ in the case of *Diphyllobothrium latum* infection results in pernicious anaemia. The presence of encysted larval tapeworms in tissues is much more serious, particularly in certain organs such as the brain, liver and lungs, since the cysts can, in some cases, reach a large size.

Laboratory diagnosis

Intestinal infection with adult worms can be diagnosed by demonstration of eggs and sometimes proglottids in the feces. Extraintestinal infections caused by the larvae can be diagnosed by biopsy, serology and radioimaging.

Prophylaxis

Avoidance of eating raw or inadequately cooked food, meat, fish or drinking of contaminated water will prevent transmission of infection to man. Thorough cooking prevents infection. Sanitary disposal of human feces containing the viable eggs of these tapeworms protects the communities. Avoidance of contact with the feces of man prevents the infection with *T. solium*, and avoiding the contact with dog feces prevents the infection with *E. granulosus*.

A. Adult Tapeworm Infections

1. *Taenia saginata* and *Taenia solium*

The common name of *Taenia saginata* is beef tapeworm or the unarmed tapeworm of man. Whereas the common name of *Taenia solium* is pork tapeworm or the armed tapeworm of man.

T. saginata has a worldwide distribution in countries where cattle are raised and inadequately cooked beef is eaten. The name beef tapeworm comes from the fact that beef is the main source of infection. *T. solium* is not as widely distributed as *T. saginata*. It occurs mainly in southern Africa, China, India, Central America, Chile, Brazil, Papua New Guinea, and non-Islamic Southeast Asia where human feces reach pigs and pork is eaten raw or undercooked. *T. solium* is known as pork tapeworm because pork is the main source of infection. It does not occur in Muslims and Jews, who do not eat pork. It is estimated that as many as 100 million people are infected with *T. saginata* and *T. solium*.

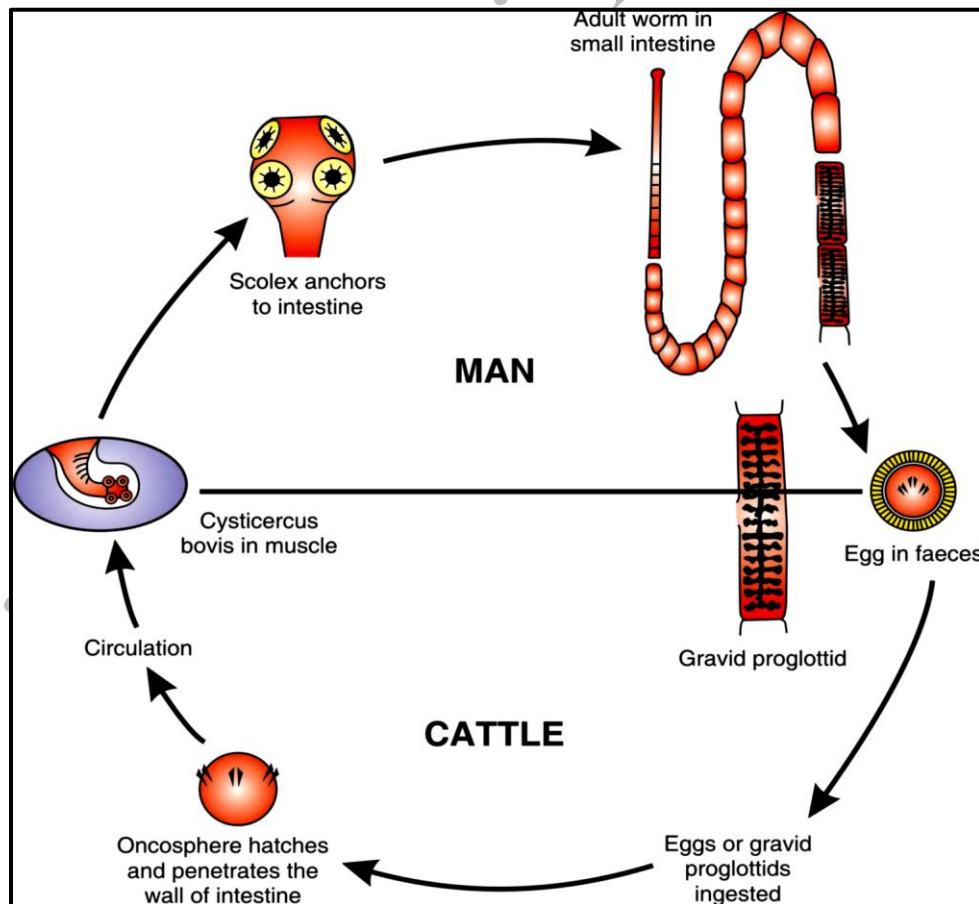
Adult worms of both *T. saginata* and *T. solium* live in the small intestine (upper jejunum) of man. They remain attached to the intestinal mucosa with their suckers. The adult worms consist of scolex (head), neck and strobila which is made up of a large number of proglottids (segments).

Eggs of both species are indistinguishable. They are spherical, brown in colour (bile stained) and measure 31-43 μ m in diameter. They are surrounded by embryophore which is

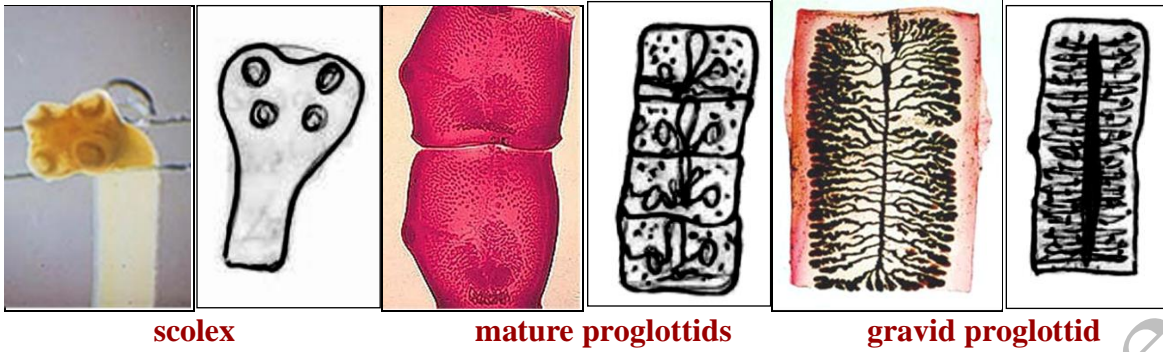
brown, thick-walled and radially striated. Outside this may be present thin transparent shell which represents the remnant of yolk mass. Inside the embryophore is present hexacanth embryo (oncosphere) with three pairs of hooklets. It does not float in saturated solution of common salt. The eggs of *T. solium* are infective to pig and also to man, while those of *T. saginata* are infective only to cattle.

Life cycle of *T. saginata*

T. saginata passes its life cycle in two hosts. The definitive host is man who harbors the adult worm, and the intermediate host is cattle. Eggs or gravid segments are passed out with the feces on the ground. These are ingested by cows or buffaloes while grazing in the field. When they reach the duodenum, the embryophore of the eggs ruptures and liberates oncospheres. With the help of their hooklets they penetrate the wall of the intestine and enter into portal vessels or mesenteric lymphatics. Then they reach general circulation via the liver, right side of the heart, lungs and left side of the heart. From general circulation, they are filtered out in striated muscles where, in 10-12 weeks, they develop into bladder worm known as **cysticercus bovis**.



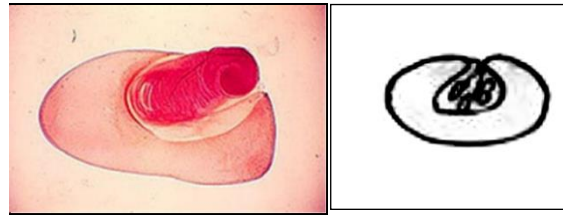
The life cycle



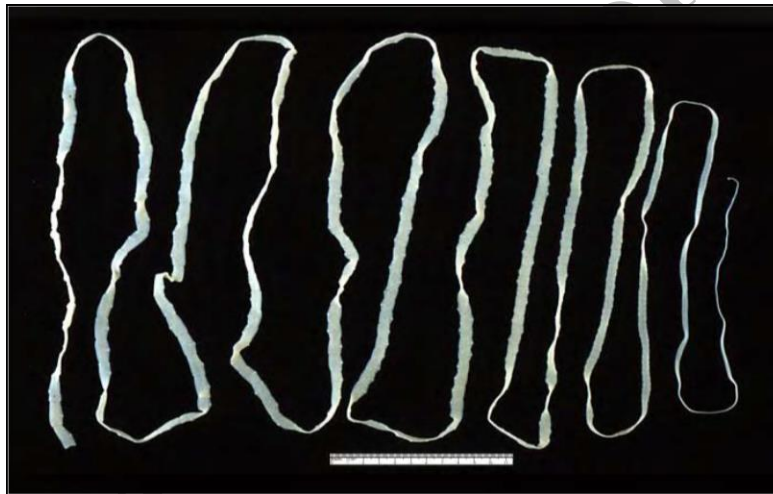
scolex

mature proglottids

gravid proglottid



cysticercus bovis



"*Taenia saginata* adult worm"



Egg of *Taenia* sp.

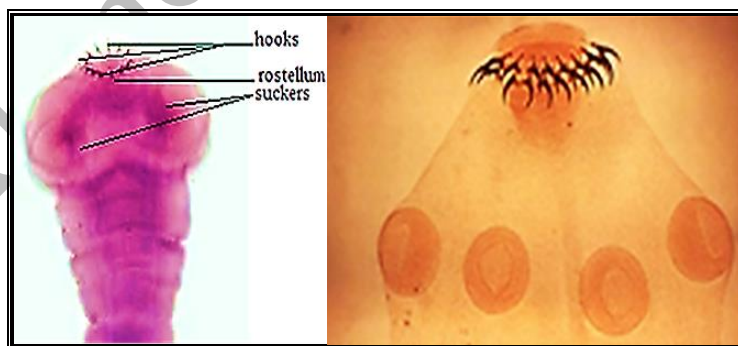
The mature cysticerci are ovoid in shape, milky white, opalescent (glossy or bright) and measure 7.5-10mm in breadth and 4-6mm in length. They have unarmed scolices (scolices without hooklets) invaginated in them. These cysticerci are frequently found in the muscles of mastication (chewing), the cardiac muscle, diaphragm and tongue. The cysticerci can live

in the flesh of the cattle for about 8 months, but can develop further only when ingested by man, its definitive host. **Cysticercus bovis is not found in humans.**

Man acquires the infection by eating raw or undercooked beef containing encysted larval stage (cysticercus bovis). The larvae hatch out in the small intestine, the scolices evaginate (evaginate) and anchor to the mucosal surface by means of their suckers and develop into adult worms. They grow to sexual maturity in 2-3 months, lay eggs which are passed out in feces along with the gravid segments and the cycle is repeated.

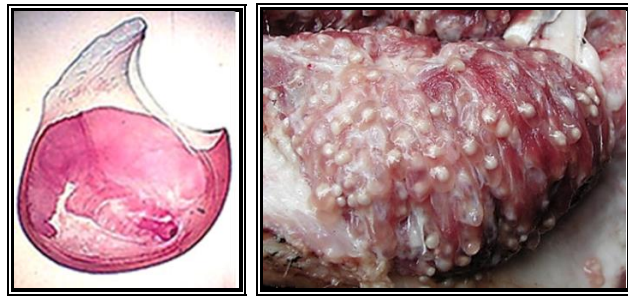
Life cycle of *T. solium*

The parasite passes its life cycle in two hosts. The definitive host is man and the intermediate host is usually the pig but man may occasionally serve as the intermediate host also. The adult worm lives in the small intestine of man and the gravid segments come out with the feces in chains of 5 or 6. Whole segment or eggs from disintegrated segment are eaten up by pig, a highly coprophagous animal. When they reach the duodenum, the embryophore of the eggs ruptures and liberates the oncospheres. With the help of their hooklets they penetrate the wall of the intestine and enter into portal vessels or mesenteric lymphatics. Then they reach general circulation via the liver, right side of the heart, lungs and left side of the heart. From general circulation, they are filtered out in striated muscles where, in 7-9 weeks, they develop into bladder worm known as **cysticercus cellulosae**. The muscles which are most commonly selected are those of the tongue, neck, shoulder and ham. The cardiac muscle is also involved.



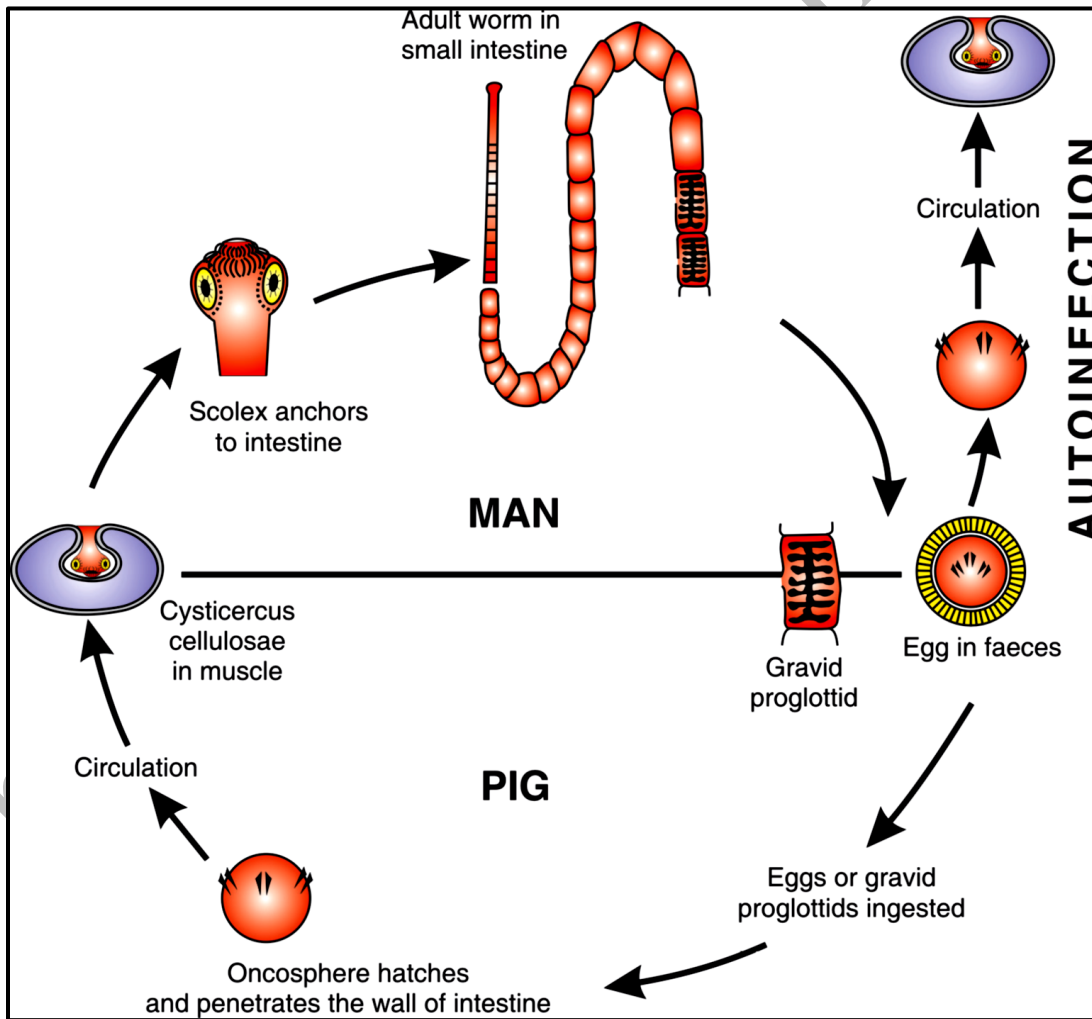
“The scolex of *Taenia solium*”.

Mature cysticercus cellulosae is an opalescent (bright), ellipsoidal (oval) body and measures 8-10mm in breadth and 5mm in length. Its long axis lies parallel to the muscle fibres. It has an invaginated scolex with its four suckers and a rostellum with a double row of alternating large and small hooklets.



cysticercus cellulosae

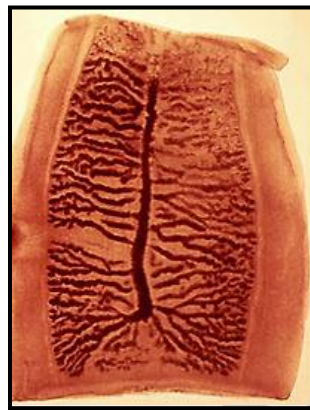
Man acquires the infection by eating raw or undercooked pork containing encysted larval stage (*Cysticercus cellulosae*). The larvae hatch out in the small intestine, the scolexes evaginate and anchor to the mucosal surface by means of their suckers and hooklets, and develop into adult worms. They grow to sexual maturity in 2-3 months. Gravid segments pass out with the feces in chains of 5 or 6 and the cycle is repeated.



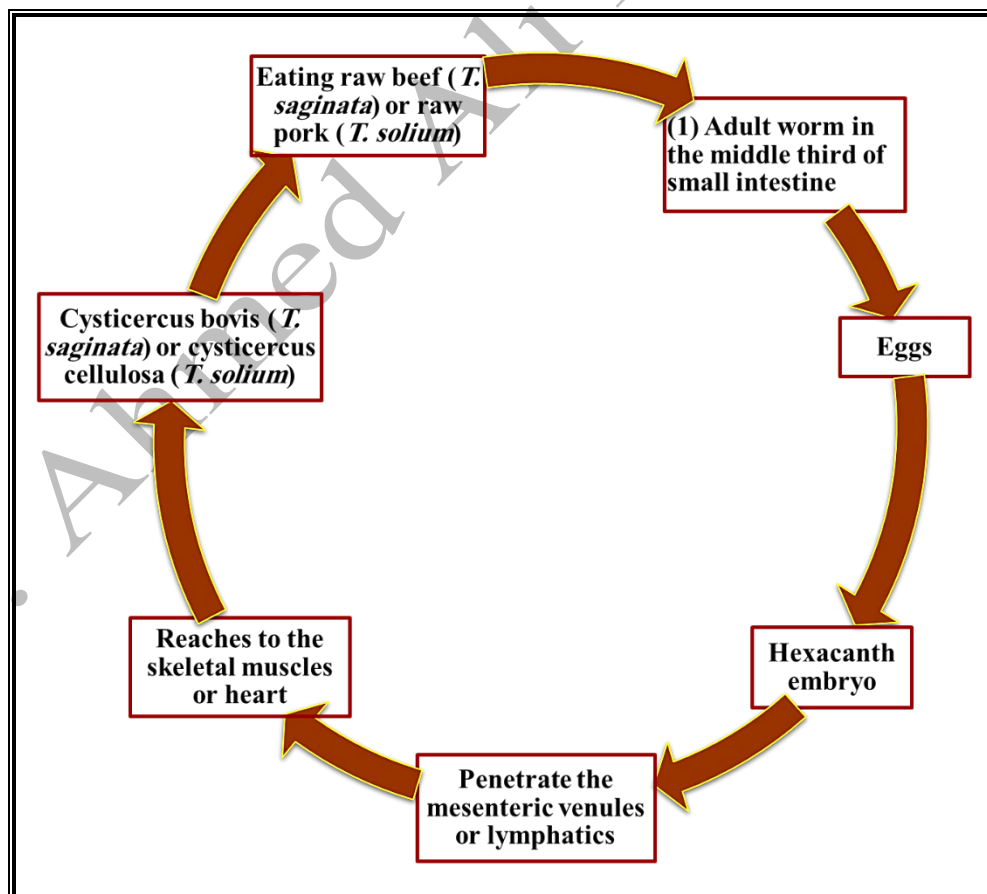
The life cycle

Cysticercus cellulosae can also develop in man as follows:

1. By ingesting the eggs with contaminated water or food.
2. A man harboring adult worms may autoinfect oneself either by unhygienic personal habits or by reverse peristaltic movements of the intestine whereby the gravid segments are thrown into the stomach, equivalent to the swallowing of thousands of eggs. Further development to cysticercus cellulosae in man is similar to that in pig.



T. saginata Gravid proglottid



“Scheme for the life cycle of *T. saginata* & *T. solium*”.

Pathogenesis

Adult worms in the small intestine usually produce no symptoms. But at times, they may cause vague abdominal discomfort, indigestion, persistent diarrhea or diarrhea alternating with constipation and loss of appetite. Large infections may lead to obstruction of the bowel.

Cysticercosis is a disease caused by the larval stage of *T. solium*, an important public health problem of the tropical countries including India. *Cysticercus cellulosae* may develop in any organ and the effects produced depend on the location of cysticerci. They usually occur in large numbers, sometimes they may occur singly. They usually develop in the subcutaneous tissues and muscles forming visible nodules. It may also develop in the brain leading to epileptic attacks and in anterior and vitreous chambers of the eye.

Laboratory diagnosis

-The diagnosis of *T. saginata* and *T. solium* infections can be carried out by:

1. Demonstration of characteristic eggs in the stool by direct smear and concentration method by sedimentation technique (formalin-ether sedimentation). They do not float in saturated solution of common salt. However, for detecting eggs, anal swabs are superior to the methods using feces.
2. Since eggs of both *T. saginata* and *T. solium* are similar, therefore, for the species diagnosis, the demonstration of gravid proglottids and scolices is essential.

-The diagnosis of cysticercosis can be carried out by:

1. Biopsy of subcutaneous nodule It may reveal cysticerci.
2. X-ray of skull and soft tissue: It may reveal calcified cysticerci.
3. CT scan of the brain: It can accurately locate the lesion in the brain.
4. Differential leucocyte count: It reveals eosinophilia.
5. Serological tests: Serological tests such as IHA, IFA and ELISA can be used for the demonstration of specific antibodies in the serum.

Treatment

Praziquantel and Niclosamide can be used for the treatment of human tapeworm infection. A single dose of four tablets (each of 500mg) of niclosamide is effective against adult *T. saginata* and *T. solium* in the intestine. However, for the treatment of *T. solium* infection

praziquantel is the drug of choice because it not only kills the adult tapeworm in a single dose, but, when taken in high doses over 3-7 days kills the cysticerci too. When treating the patient with *T. solium* infection nausea and especially vomiting should be avoided, otherwise eggs or proglottids with eggs may enter the stomach and later into the small intestine leading to cysticercosis.

To readily eliminate the segments from the bowel, a purgative may be given 1-2 hours after anthelmintic treatment. The patient must be instructed for careful washing of hands after defecation and for safe disposal of feces for at least four days following therapy.

Prophylaxis of *T. saginata* infection

1. All beef to be eaten by man should be inspected for cysticerci. However, inspection procedures for bovine cysticercosis do not always detect infection.
2. Thorough cooking of beef ensures complete protection.
3. Proper sanitary disposal of feces. Cattle should not be allowed to feed or graze on ground polluted by human feces or sewage. This will control cattle infection.
4. In order to break the parasite life cycle, infected people should be treated.

Prophylaxis of *T. solium* infection

1. Personal hygiene.
2. General sanitary measures.
3. Avoid food and water contamination with *T. solium* eggs.
4. Strict veterinary inspection of pork in all slaughter houses with condemnation of “measly pork” (infected pig).
5. Thorough cooking of pork ensures complete protection.
6. Pickled or salted pork is not necessarily safe.
7. Pigs should not have access to human feces.
8. Avoid eating raw vegetables grown on soil irrigated by sewage water.
9. In order to break the parasite life cycle, infected people should be treated.

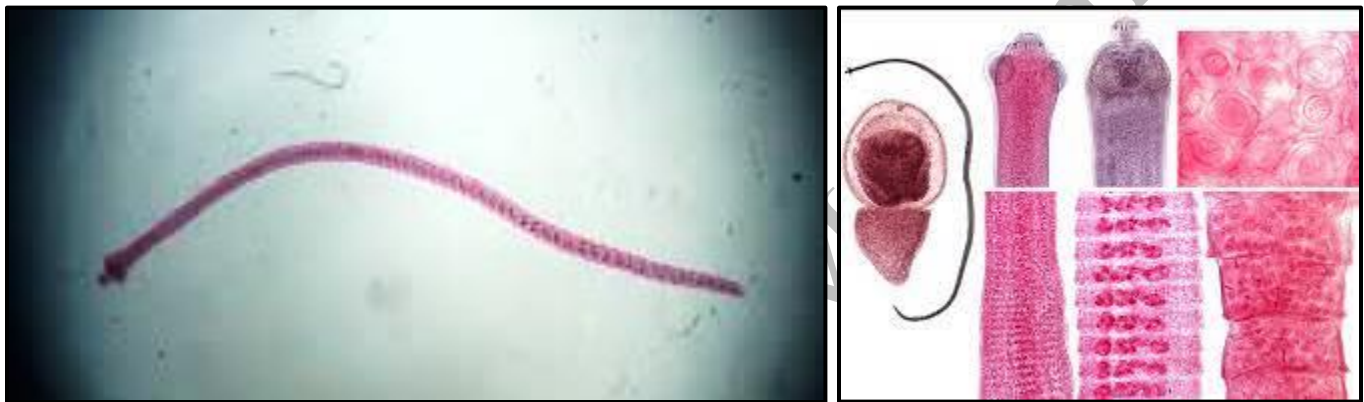
2. *Hymenolepis nana*

Its common name is the dwarf tapeworm. *H. nana* is the smallest tapeworm infecting humans. The name *Hymenolepis* refers to thin membrane covering the egg (*hymen*= membrane, *lepis*= covering) and *nana* mean small size (*nanus*= dwarf or small). It was first

discovered by Bilharz (1851) in the small intestine. It infects not only humans but also rodents such as mice and rats. In rodents the tapeworm is regarded by some as a special strain (*H. nana* var. *fraterna*), but cross-infections in both directions are possible.

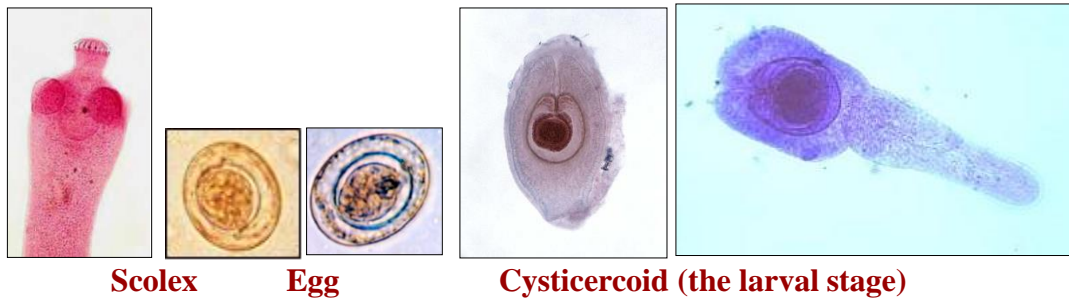
H. nana has a worldwide distribution and is one of the more common causes of cestode infections in humans, particularly in children. In humans the adult tapeworms are found in the upper two-thirds of the ileum, whereas in mice and rats they are found in the posterior part of the ileum.

The adult tapeworm is small reaching only 4-5cm in length and 1mm in diameter. Like other tapeworms, it consists of scolex, neck and strobila.



Adult worm

The **scolex** is globular, has four cup-shaped suckers and a retractile rostellum armed with a single row of 20-30 hooklets. The **neck** is long and slender and is situated posterior to the scolex. The strobila consists of about 200 proglottids. A mature proglottid measures 0.15-0.3mm in length and 0.8-1mm in breadth. Genital pores are marginal and are situated on the same side. The uterus is a transverse sac with lobulated walls and the testes are round and three in number. The life span of the adult worm is about two weeks. In an infected person 1,000-8,000 worms may be present. The **egg** is spherical or oval, hyaline, 35-40 μ m in diameter. It has a smooth, thin and colorless outer shell and an inner membrane (embryophore), containing a hexacanth embryo (oncosphere). The space between two membranes is filled with yolk granules and 4-8 polar filaments emerged from polar thickenings at either end of the embryophore. It is non-bile-stained and floats in saturated solution of common salt.



Life cycle

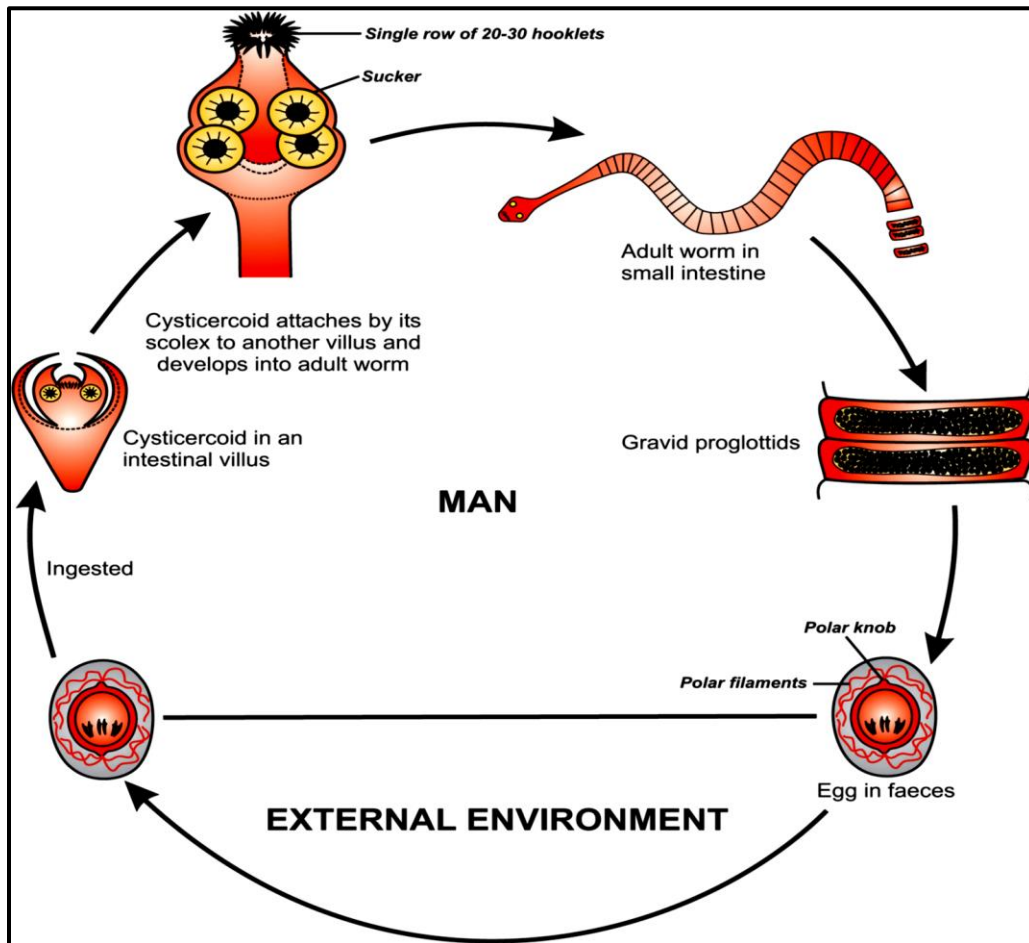
H. nana is the only cestode which is capable of completing its life cycle in a single host. It has two types of life cycle, **direct** and **indirect cycle**.

-Direct cycle

Eggs, and proglottids with eggs are passed in the feces of the infected humans and rodents. Man acquires infection by the ingestion of food or water contaminated with these (fecal-oral route). In the lumen of the small intestine, a free oncosphere (hexacanth embryo) is liberated from the egg. It penetrates into a villus of the anterior part of the small intestine and develops into cysticercoid larva in about four days. Thereafter, the villus ruptures and the cysticercoid becomes free in the lumen of the small intestine. Later, it attaches by its scolex to another villus further down, and in the course of two weeks or more develops into an adult tapeworm. Strobilization is rapid and in about 30 days after the infection, the eggs, and proglottids with eggs begin to appear in feces and the cycle is repeated. In heavy infections, the eggs may hatch in the intestine before passing out in the feces, develop into a cysticercoid larva, and then grow into adult worms without leaving the host (resulting in **autoinfection**). This can lead to **hyperinfection** with very heavy worm burdens and severe clinical symptoms.

-Indirect cycle

H. nana has an indirect life cycle with an insect as the intermediate host. Insects include grain and flour-eating beetles such as species of *Tribolium* and *Tenebrio*, fleas such as *Xenopsylla cheopis*, *Pulex irritans* and *Ctenocephalides canis*, and moths. These insects or their larvae eat the eggs of *H. nana*. They crush the egg shell, and enzymes in the gut stimulate the oncosphere to free itself from the enclosing membrane. In the gut lumen, the oncosphere penetrates the gut wall by means of its six hooklets and glandular secretions. In the body cavity of the insect, the oncosphere transforms into cysticercoid larva, which is infective to final host. Man is infected by accidental ingestion of these infected beetles, fleas and moths. In the intestine the cysticercoid larva is released and develops into adult worm.



Pathogenicity

H. nana, even in large numbers, is well tolerated. The mechanism by which symptoms are produced is an allergic reaction, and in heavy infections enteritis may be produced. The infection is more common in children. Patient develops headache, dizziness, anorexia, pruritus of nose and anus, abdominal pain, diarrhea, restlessness, epileptiform convulsions and eosinophilia in more than 5%.

Laboratory diagnosis

The diagnosis is made by the demonstration of characteristic eggs in feces by direct microscopy, salt floatation and formalin-ether sedimentation methods. Eggs are infectious, therefore, unpreserved stools should be handled with care.

Treatment

Praziquantel is effective against *H. nana* infections, but higher doses than used for other tapeworm infections are usually required. The drug of second choice is Niclosamide.

Prophylaxis

Personal hygiene, sanitary improvements, uncontaminated food and water and rodent control are the measures for prevention of *H. nana* infection.

B. Larval Tapeworm infection

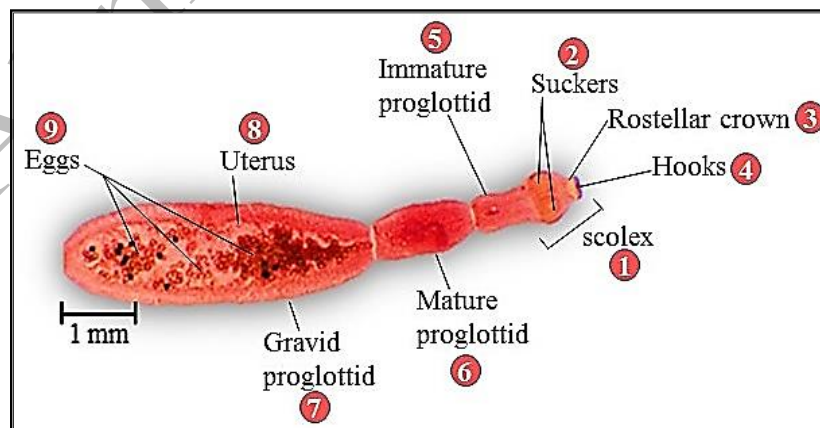
Ex: *Echinococcus granulosus*

The common names of this worm is the dog tapeworm, the hydatid worm. the adult *E. granulosus* was described by Hartmann in the small intestine of dog in 1695 and the larval form (the hydatid cyst) was subsequently described by Goeze in 1782.

E. granulosus is worldwide, but it is more common in sheep and cattle-raising countries. It occurs mainly in South America, North Africa, Eastern Australia, Asia and also sporadically in the Middle East, Mongolia, Eastern Europe and the UK.

Adult worm resides in the small intestine of dog and other canine animals (wolf, fox and jackal). Larval form is seen in man and other intermediate hosts (sheep, goat, cattle, pig and horse). The dog and sheep are optimum definitive and intermediate hosts respectively and the cycle of transmission is maintained between them.

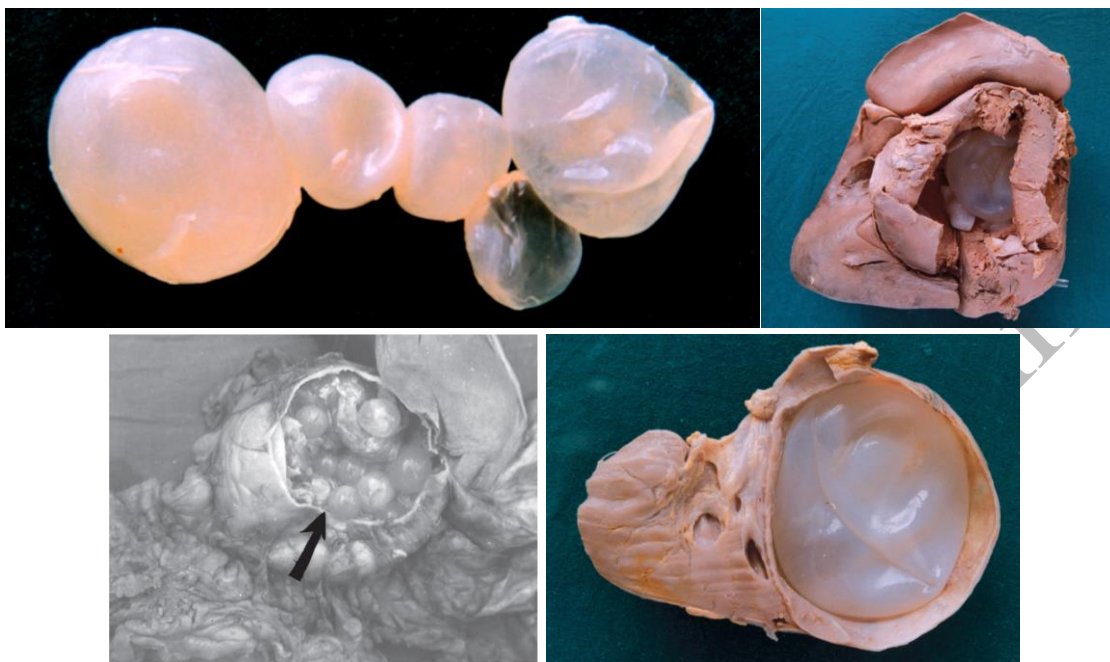
It is a small tapeworm measuring 3-6mm in length. It consists of a scolex, neck and strobila. The **scolex** is pyriform in shape and measures about 300µm in diameter. It possesses four suckers and a protrusible rostellum with two circular rows of hooklets. The **neck** is short and thick. **Strobila** consists of three segments (occasionally four). The first segment is immature, the second is mature and the third (and the fourth when present) is gravid.



Echinococcus granulosus adult worm.

The eggs are indistinguishable from those of other *Taenia* species. These are spherical, brown in colour and measure 31-43µm in diameter, and contain hexacanth embryos with

three pairs of hooklets. The larval form is found within the hydatid cyst which develops in the intermediate host.



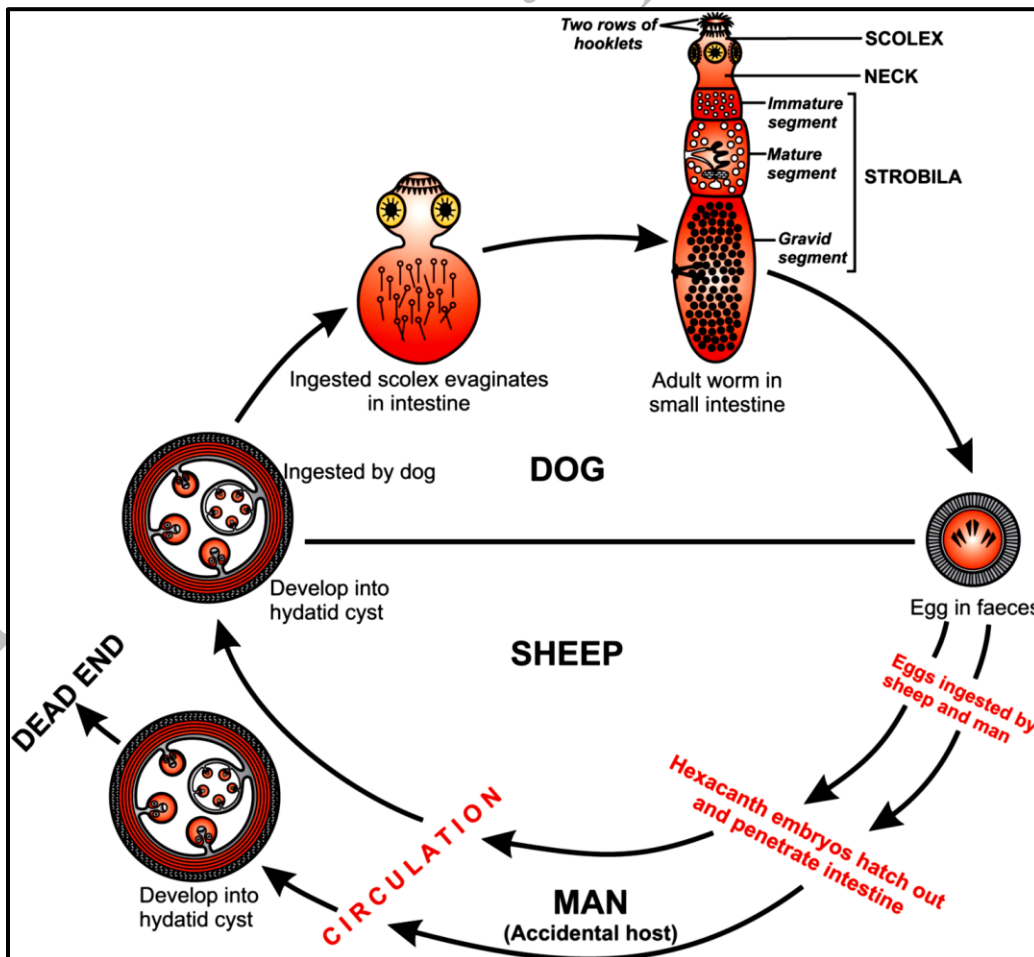
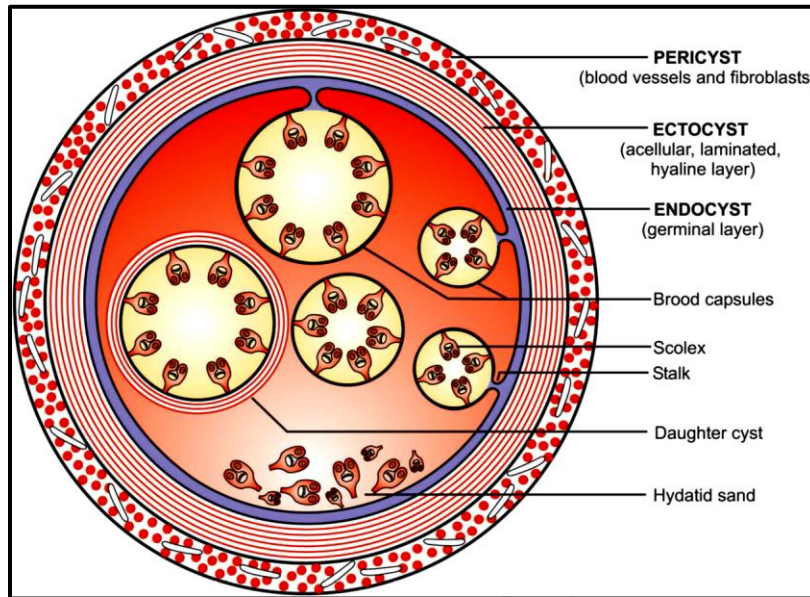
Hydatid cysts

Life cycle

E. granulosus passes its life cycle in two hosts. The adult worm lives attached to the mucosa of the small intestine of dog and other canine animals. The eggs are discharged in the feces. These are swallowed by the intermediate hosts while grazing in the fields. Man acquires the infection by a direct contact with infected dog or by allowing the dog to feed from the same dish or by ingesting water or food contaminated with dog's feces containing eggs of *E. granulosus*. In the duodenum the hexacanth embryos called oncospheres hatch out. These penetrate the intestinal wall and enter into the radicles of portal vein and are carried to the liver. The liver acts as the first filter where 60-70% of human infections are located. Some embryos may pass through the hepatic capillaries and enter the pulmonary circulation. Lungs act as the second filter. A few of these embryos may pass pulmonary circulation too and enter general circulation and may lodge in various organs like brain, heart, spleen, kidneys, genital organs, muscles, bones, etc.

Wherever the embryos settle, an active cellular reaction consisting of monocytes, giant cells and eosinophils takes place around the parasite. A large number of the parasites may thus be destroyed by host defence mechanism. Some of the embryos, however, escape destruction and develop into hydatid cysts. The cellular reaction in these cases gradually disappears, followed by the appearance of fibroblasts and the formation of new blood

vessels. Fibroblasts lay fibrous tissue, which envelops the growing embryo. This is known as **pericyst**. This merges with the surrounding normal tissue. The parasite derives its nutrition through this layer. In old cysts the pericyst may become sclerosed or calcified and parasite within it may die.



Inside the pericyst, the embryo develops into a fluid-filled bladder known as **hydatid cyst**. From the inner side of the cyst, **brood capsules** with a number of **scolices** are developed. When animals that serve as intermediate hosts are slaughtered, the viscera may not be disposed off properly and may be consumed by animals that serve as definitive hosts. The adult worms then develop in the intestine of definitive host. These lay eggs which are passed in the feces of the infected animals and the cycle is repeated. Since dog has no access to the hydatid cysts developed in the viscera of man, therefore, the life cycle of the parasite comes to a dead end.

Pathogenicity

E. granulosus causes cystic echinococcosis or hydatidosis or hydatid disease in man. The hydatid cyst represents the larval form of the parasite. The disease is generally acquired during childhood though it does not manifest before adult life. The cyst wall secreted by the embryo consists of two layers:

1. Ectocyst

It is the outer layer, tough, it is acellular, laminated, hyaline membrane up to 1mm in thickness. It resembles the white of a hard-boiled egg. It is elastic, therefore, when excised or ruptured, it curls on itself thus exposing the inner layer containing brood capsules, scolices and daughter cysts.

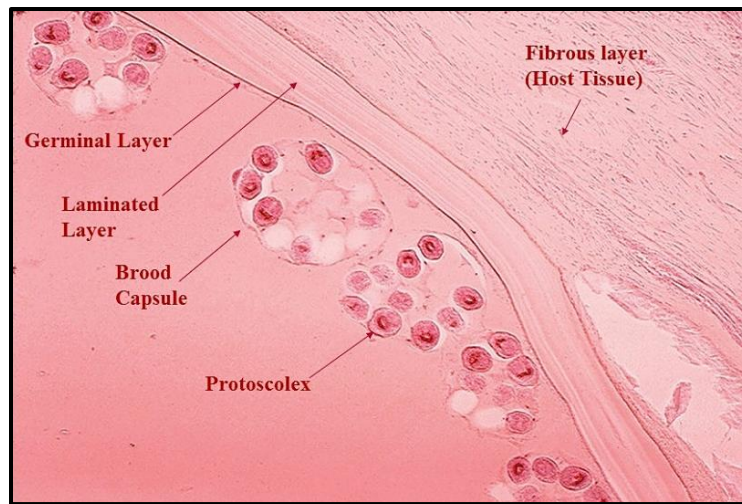
2. Endocyst

It is the inner germinal layer. It consists of a number of nuclei embedded in a protoplasmic mass. It measures 22-25 μ m in thickness. It gives rise to ectocyst on outside and brood capsules and scolices on inside. It also secretes the hydatid fluid. When the embryos break free from the membrane and float in the fluid within the cyst, they are known as hydatid sand.

The hydatid fluid is clear, colorless or pale yellow. It is slightly acidic (pH 6.7) and contains sodium chloride, sodium sulphate, sodium phosphate and sodium and calcium salts of succinic acid. It is antigenic, therefore, it is used for **Casoni test** and when absorbed it leads to anaphylactic shock. Centrifuged deposit of the hydatid fluid shows hydatid sand which consists of brood capsules, free scolices and hooklets.

If the cyst ruptures, either spontaneously in the body or during surgery, the danger from death from anaphylactic shock is high. Metastatic cystic lesions can also develop in virtually any of the visceral organs if the primary cyst ruptures. If the cyst material seeds the

peritoneal lining, massive proliferation can occur with vascular invasion and spread to other organs.



Section in the hydatid cyst of *Echinococcus granulosus*.

Acephalocysts

Some cysts are sterile and never produce brood capsules; some become sterile by bacterial invasion or calcification. In other cysts the brood capsules never produce scolices; hence they are called **acephalocysts**. If ingested by definitive host these cysts do not lead to infection.

Endogenous daughter cyst

Sometimes a fragment of the germinal layer may detach and develop into daughter cyst inside the mother cyst. This is known as endogenous daughter cyst. It also has both ectocyst and endocyst with brood capsules and scolices. Grand daughter cysts may also be formed.

Exogenous cyst

In case of hydatid disease of bone, because of high intracystic pressure, herniation or rupture of germinal and laminated layer may occur through some weaker part of the bone resulting in formation of exogenous cyst.

Clinical disease

Hydatid disease in humans is potentially dangerous; however, cyst size and organ location will greatly influence the outcome. In untreated or in inadequately treated patients mortality is more than 90% within 10-15 years of diagnosis.

Liver cysts

The majority of hydatid cysts occur in the liver, causing symptoms that may include chronic abdominal discomfort, occasionally with a palpable or visible abdominal mass. Liver cysts tend to occur more frequently in the right lobe. If a cyst becomes infected with bacteria, it resembles an abscess. If the cyst ruptures, either spontaneously, from trauma, or during surgery, there may be serious allergic reactions, including skin rash, anaphylactic shock, or death.

Lung cysts

Cysts in the lungs are usually asymptomatic until they become large enough to cause cough, shortness of breath, or chest pain. Cyst rupture may lead to expectoration (sputum) of hydatid fluid or membranes, followed by the development of infection and a lung abscess. If the rupture occurs into the lung, it may cause pneumothorax and empyema, allergic reactions, and even anaphylactic shock.

Other sites

Other organs which may also be involved include spleen (3-5%), central nervous system and heart (1-1.5%), kidneys, bones, muscles, female genital tract, eyes, etc. leading to visible swelling and pressure effects.

Location of cyst in relation to age

It is well-known that hydatid cysts are most commonly found in liver and lungs; but lung, brain, spinal, and orbital cysts have been more commonly seen in younger patients.

Laboratory diagnosis

It can be carried out by the following methods:

1. Casoni test:

It is an immediate hypersensitivity skin test which was introduced by Casoni in 1911. Antigen for the Casoni's test is sterile hydatid fluid drawn from unilocular hydatid cysts from sheep, pig, cattle or man. The fluid is filtered, tested for sterility and stored in sealed ampoules under refrigeration. For the test, 0.2 ml of the antigen is injected intradermally in one arm. For control, an equal amount of sterile normal saline is injected intradermally on the other arm. The control fades almost immediately, while the tested site in positive case develops a large wheal measuring 5cm or more in diameter with multiple pseudopodia

within 30 minutes. This test has a low sensitivity (55-70%) and gives false positive reactions in patients suffering from other cestode infections.

2. Differential leucocyte count: this may reveal eosinophilia (20-25%).

3. Serological tests

Serodiagnosis of hydatid cyst may be carried out by ELISA, radioimmunoassay (RIA), complement fixation, IHA, bentonite flocculation and latex agglutination tests.

4. Examination of cyst fluid

This test reveals scolices, brood capsules and hooklets. Because leakage of fluid in the adjoining tissue may lead to anaphylactic shock, therefore, the fluid aspirated from surgically removed cyst should be examined and diagnostic puncture of cyst is not recommended.

5. Histological examination

Histological examination of surgically removed cyst reveals different layers of the hydatid cyst, i.e., pericyst, ectocyst and endocyst.

6. Radiodiagnosis

X-ray, ultrasound and CT scan are also helpful in the diagnosis of hydatid cyst.

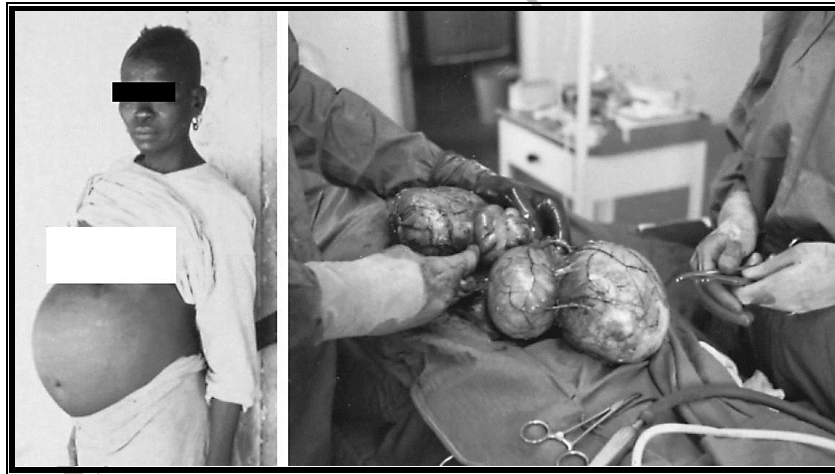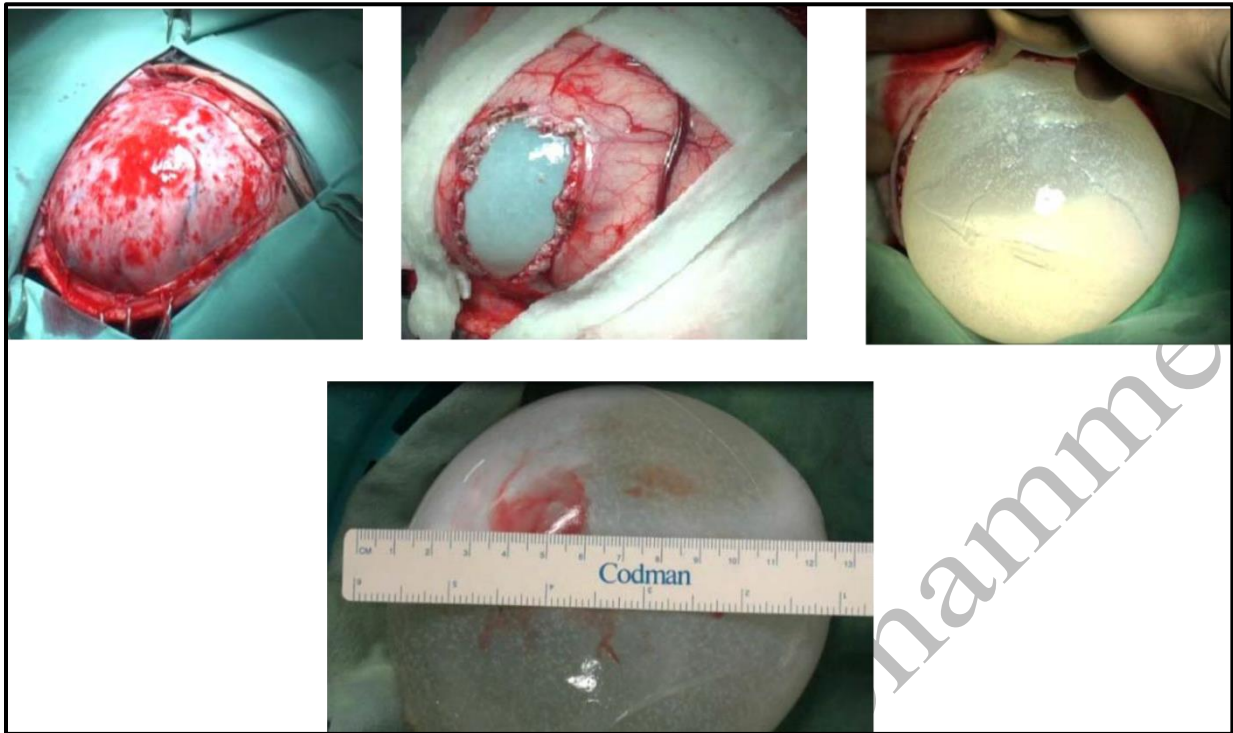Treatment

Surgical removal of the hydatid cyst which can be performed in about 90% of the patients, has few complications and the best prognosis. It is the preferred treatment when cysts are larger than 10cm in diameter, secondarily infected, or located in the brain or the heart. However, leakage from ruptured cysts may spread the disease to other organs. Therefore, the consequences of spilling of its contents should be avoided because it could lead to anaphylactic shock should. There may be recurrences in 2-25% of cases after surgery. Therefore, postoperative chemotherapy may be given for at least two years after radical surgery. Praziquantel and albendazole are the chemotherapeutic agents for the treatment of hydatid cyst. Benzimidazole treatment should be administered in the perioperative period.

Prophylaxis

E. granulosus infection can be prevented by:

1. Strict personal hygiene.
2. Dogs should not be allowed to eat the carcasses of slaughtered animals in endemic areas.
3. Reduction of stray dog population.



Hydatid cysts