

Compendium

New Alternatives for Minimally Invasive Management of Uroliths: Ureteroliths

Alice Defarges, DVM, DACVIM

University of Guelph

Allyson Berent, DVM, DACVIM

The Animal Medical Center
New York, New York

Marilyn Dunn, DMV, DACVIM

Université de Montreal

Abstract: Ureterolithiasis is a serious clinical problem in small animal veterinary medicine, and management can be challenging and frustrating. Various traditional surgical treatment options exist but are associated with significant morbidity and mortality. In humans, minimally invasive treatment options have overtaken traditional surgical removal. This article reviews the current literature on the management of ureteral stone disease, including various types of lithotripsy, and discusses some of the newer minimally invasive options available for small animal veterinary patients. It is important to realize that much of the data in this article is only published in abstract form and is largely one institution's experience with these novel techniques. Articles on minimally invasive management of lower urinary tract uroliths and nephroliths were published in the January 2013 and February 2013 issues, respectively.

For more information, please see the companion articles: "New Alternatives for Minimally Invasive Management of Uroliths: Lower Urinary Tract Uroliths" (January 2013) and "New Alternatives for Minimally Invasive Management of Uroliths: Nephroliths" (February 2013).

Most ureteroliths in dogs (>30% to 60%) and cats (>98%) are composed of calcium oxalate.¹⁻³ Because these stones cannot be dissolved medically, they must pass spontaneously, remain in place, or be removed. Dissolution of obstructive ureteroliths is contraindicated regardless of their composition because the time required will result in excessive kidney damage. The traditional approach to ureteral stones causing partial obstructions has been medical management (intravenous fluid therapy, mannitol diuresis via constant-rate infusion [CRI] and α -adrenergic blockade with or without amitriptyline therapy)⁴; if this approach failed, these stones were often monitored and left in the ureter due to the presumed low risk:benefit ratio of attempted surgical removal. Based on the literature in cats, it is clear that surgical intervention results in a higher rate of obstruction removal than medical management alone,² but the morbidity and mortality rates associated with traditional surgery are high. Less invasive alternatives that result

Dr. Berent discloses that she is a consultant for Ininiti Medical, LLC and Norfolk Vet.

Dr. Dunn discloses that she is a consultant for Ininiti Medical and Vétotoquinol.

in immediate renal decompression and stabilization of associated azotemia, a decreased risk of iatrogenic ureteral stricture or urine leakage/uroabdomen, and a decreased recurrence of ureteral obstruction by concurrent nephroliths or surgery-associated edema are being investigated, with promising outcomes to date (TABLE 1).

Effects of Obstructive Ureteroliths

If one or more ureteroliths are obstructing urine flow, are causing hydroureter/hydronephrosis, or are associated with discomfort, hemorrhage, or concurrent pyelonephritis, removal or provision of some form of urinary bypass is indicated immediately, regardless of stone composition, as time is critical. If the ureteral obstruction is complete, decompression of the renal pelvis becomes imperative to preserve the function of the ipsilateral kidney.³ In studies of normal dogs, renal pelvis and ureteral pressures have been shown to increase dramatically immediately following a ureteral obstruction; after this increase in pressure, the renal blood flow diminishes to 40% of normal in the first 24 hours if the obstruction is not corrected. Within 2 weeks of continuous complete ureteral obstruction, the renal blood flow drops to 20% of normal.^{3,5} The increase in pressure generated by a ureteral obstruction is transmitted to the entire nephron, and concurrent vasoactive mediator release, leukocyte influx, and subsequent fibrosis result in a decrease in glomerular filtration rate (GFR).⁵ The longer the ureter remains obstructed,

Table 1. Considerations for Various Interventional Procedures in Patients With Partial or Complete Ureteral Obstruction^a

Procedure	Cats	Dogs
Medical management (aggressive diuresis)	<ul style="list-style-type: none"> Indicated within 48 h of ureteral obstruction Contraindicated if patient is unstable (hyperkalemic, excessively overhydrated, becoming oliguric, or has cardiac disease) 	<ul style="list-style-type: none"> Indicated within 48 h of ureteral obstruction Contraindicated if patient is unstable (hyperkalemic, excessively overhydrated, becoming oliguric, or has cardiac disease)
Nephrostomy tube	<ul style="list-style-type: none"> Indicated for urgent decompression of the renal pelvis if ESWL and ureteral stenting not available Renal pelvis must be >10 mm Surgically placed; percutaneous placement not recommended because of increased risk of uroabdomen due to mobility of feline kidneys 	<ul style="list-style-type: none"> Indicated for urgent decompression of the renal pelvis if ESWL and ureteral stenting not available Renal pelvis must be >10 mm Percutaneously placed
ESWL	<ul style="list-style-type: none"> Indicated for ureteroliths <3 mm Add ureteral stent if ureterolith is 3–5 mm or obstruction is present 	<ul style="list-style-type: none"> Indicated for ureteroliths <5 mm Add ureteral stent if ureterolith is >5 mm or obstruction is present
Ureteral stents	<ul style="list-style-type: none"> Indicated for obstructive ureteroliths (any degree of hydroureter and hydronephrosis) Placed antegrade via nephrostomy access Placed retrograde via cystoscopy or ureterotomy 	<ul style="list-style-type: none"> Indicated for any obstructive ureterolith Placed retrograde (cystotomy or cystoscopy) or antegrade (percutaneous or surgical nephrostomy access)
Ureteroscopy	Not performed because of small patient size	<ul style="list-style-type: none"> Indicated for dogs >18 kg Ureteral stents placed when complete
SUB	<ul style="list-style-type: none"> Indicated if placement of ureteral stent is not possible or has failed Indicated for ureteral strictures or very proximal ureteral obstructions Indicated for ureteral stent reactions 	<ul style="list-style-type: none"> Indicated for ureteral stent reactions or intolerance or recurrence of occlusion
Ureterotomy or ureteral reimplantation	If deemed appropriate by attending surgeon	If deemed appropriate by attending surgeon

ESWL = extracorporeal shock-wave lithotripsy, SUB = subcutaneous ureteral bypass.

^aImmediate treatment of partial ureteral obstruction is typically recommended.⁴

the more significant, irreversible damage occurs.³ In one study, after 7 days of obstruction, the GFR was permanently diminished by 35%, even after the obstruction was relieved, and the recovery of 65% of kidney function took approximately 5 weeks to occur.³ When the obstruction lasted for 14 days, the GFR was permanently diminished by 54%, and this 46% recovery took more than 4 months to occur. These numbers were obtained in dogs without preexisting renal or ureteral disease, so extrapolation of a worse outcome might be expected in feline and canine patients with chronic obstructions, previous and/or exhausted renal hypertrophy compensation, and preexisting renal insufficiency. These data suggest that aggressive and timely intervention is necessary when a ureteral obstruction is diagnosed and that the “watch and wait method” should be avoided.

Traditional Management
Medical Management

Because medical management has been shown to be effective in some cats (8% to 17%) and surgical management has been shown to be associated with a high postoperative complication rate

(31% in cats and ~35% in dogs) and perioperative mortality rate (18% in cats and 25% in dogs),^{2,6} medical management should be considered before any surgical intervention; however, more aggressive management should be considered in cases that fail to improve with medical management alone. In cats, medical management appears to be more effective for stones in the distal third of the ureter than for stones in the proximal ureter and to be more effective for stones smaller than 2 to 3 mm.

Medical management should consist of administering aggressive IV fluid therapy while monitoring and controlling central venous pressure, body weight, electrolyte concentrations, and hydration status. The fluid therapy protocol I (A. B.) recommend includes administering a maintenance rate (e.g., 50 to 60 mL/kg/d) of 0.45% saline mixed with 2.5% dextrose and a replacement fluid such as Plasma-Lyte (Abbott Animal Health) or lactated Ringer solution (avoiding saline, if possible, to reduce sodium load) to correct hydration status and promote diuresis (e.g., 45 to 75 mL/kg/d); however, I generally do not administer >120 mL/kg/d. In patients without cardiac compromise, I (A. B.) typically choose a CRI of mannitol, starting with a bolus at 0.25 to 0.5 g/kg over 20

to 30 minutes followed by a CRI at 1 mg/kg/min for 24 h. If, after 24 hours, there is no evidence of improvement based on imaging and serial blood work, the CRI is discontinued.⁴ Other medical alternatives include amitriptyline,⁷ α -adrenergic blockage (prazosin or tamsulosin),⁸ or glucagon therapy.^{9,10}

If medical management fails or the patient is unstable (e.g., hyperkalemic, excessively overhydrated, oliguric, developing progressive hydronephrosis), immediate renal decompression should be considered. If immediate resolution (via ureterotomy, ureteral reimplantation, ureteral stenting, or a subcutaneous ureteral bypass) is not possible, then the two best options are to (1) place a nephrostomy tube or (2) initiate intermittent hemodialysis or continuous renal replacement therapy (CRRT).⁴ I (A. B.) recommend immediate renal pelvis decompression over hemodialysis or CRRT if the patient is stable enough to undergo anesthesia and the operator is comfortable with the procedure.⁴ Renal pelvis decompression halts the damage being done by the increased hydrostatic back pressure, whereas hemodialysis stabilizes a patient while the ureteral obstruction persists, resulting in ongoing renal injury.

Many patients with ureteral obstruction have concurrent urinary tract infections (75% of dogs and 10% to 30% of cats)^{2,11}; therefore, broad-spectrum antimicrobial therapy is recommended for all patients, and urine culture and sensitivity testing should be part of the workup.⁶

Surgical Management

Traditional surgical intervention has included ureterotomy, neo-ureterocystostomy, ureteronephrectomy, or renal transplantation. Kyles et al² reported procedure-associated complication and mortality rates of >30% and 18%, respectively, in more than 150 cats that underwent at least one of these procedures. These cases were seen at two universities where microsurgical expertise was available and a renal transplant program existed. The morbidity and mortality rates may be higher in environments where operating microscopes and microsurgical experience and expertise are not available.

Many of the complications associated with surgery are due to site edema, recurrence of stones that pass from the renal pelvis to the surgery site, stricture formation, persistent obstructions, missed ureteroliths, and ureterotomy-associated or nephrostomy tube-associated urine leakage. In the Kyles et al study,² patients that underwent a ureterotomy for treatment of a ureteral obstruction (the most commonly considered procedure in practice) had a perioperative mortality rate of 25%. Of 88 cats that survived surgery, major postoperative complications were observed in 27 and resulted in the death of 16 (18% of 88 cats). Uroabdomen developed in four of the 27 cats (15%) in which a ureteroneocystostomy was performed. Three of these cats required a second surgery. Overall, 27% (3 of 11) of the cats that underwent a second surgery because of uroabdomen were subsequently euthanized or died due to serial complications (uroabdomen, ureteral strictures, sepsis).

When ureterotomy or ureteroneocystostomy is unsuccessful, a ureteronephrectomy may be required, which is not ideal in any patient with concurrent renal azotemia (50% to 97% of cats and 25% to 50% of dogs),^{2,4,6,11} particularly because >30% of all cats ultimately

develop chronic kidney disease^{12,13} and the disease being treated is ureteral in origin. Preserving renal function is considered necessary. Chronic kidney disease is common in cats when ureteral obstruction is diagnosed, with 75% to 97% of cats reported to be azotemic with a unilateral obstruction.^{2,4,11,14} Persistent azotemia is a common problem even after a successful intervention (40% to 70% of cats).^{2,11}

Another major concern is that in the Kyles et al study, 40% of feline patients developed a second ureteral obstruction, and of these cats, 85% had evidence of nephrolithiasis documented at the time of the first surgery.² Nephroliths have the potential to pass into and obstruct the ureter during postobstructive diuresis, which can occur immediately after surgery. Unfortunately, removing a nephrolith in a cat is challenging and potentially harmful, and it is impossible to predict whether a nephrolith will become an obstructive ureterolith. Also, a concurrent nephrotomy increases the risks for postoperative complications and is likely to worsen renal function.² In a 2011 study of 75 cats with ureteral obstructions,¹¹ 86% had evidence of nephrolithiasis of the ipsilateral kidney at the time of the ureteral obstruction; however, because these patients underwent stent placement, subsequent ureteral obstruction by a nephrolith was of little concern.

Despite all of the surgical concerns, the survival rates are still dramatically higher for cats that have surgery performed than for cats treated with medical management alone. In the Kyles et al study, the 6-, 12-, and 24-month survival rates for cats that survived for 1 month after ureteral surgery (61 of 71 cats) were 91%, 91%, and 88%, respectively.² The 6-, 12-, and 24-month survival rates for cats treated medically that survived for 1 month after diagnosis (42 of 52 cats) were 72%, 66%, and 66%, respectively.²

Results after ureterotomy were also reported in 16 dogs.¹¹ The mortality rate (death related to azotemia or to clinical signs related to the urinary system) in this study was 25% (4 of 16 dogs). Of the 12 dogs that were followed, 17% (2 of 12) required an additional surgery within 4 months for ureteral stricture or recurrent ureteroliths.⁶ Most dogs (88%; 14 of 16) had urinary tract infections at diagnosis, and 50% (8 of 16) had concurrent nephrolithiasis. Ten (62.5%) dogs presented to the hospital with elevated blood urea nitrogen and/or creatinine concentrations. Of the eight dogs that had elevated creatinine concentrations before surgery, four were in the normal range when reevaluated postoperatively. Two dogs had mildly elevated creatinine concentrations but an appropriate urine specific gravity (1.029 and 1.039) postoperatively. Three dogs that had suspected renal azotemia at presentation based on elevated creatinine concentrations and a urine specific gravity ≤ 1.030 remained azotemic postoperatively. Unfortunately, GFR was not measured pre- and postoperatively in any dog to determine quantitative changes in renal function. Postoperatively, two dogs had worsening azotemia; these dogs survived 8 and 90 days. None of the dogs in this study underwent postmortem examination.

Minimally Invasive Options

Stents

The use of ureteral stents in dogs and cats has been investigated as a less invasive alternative to traditional surgery that may result in

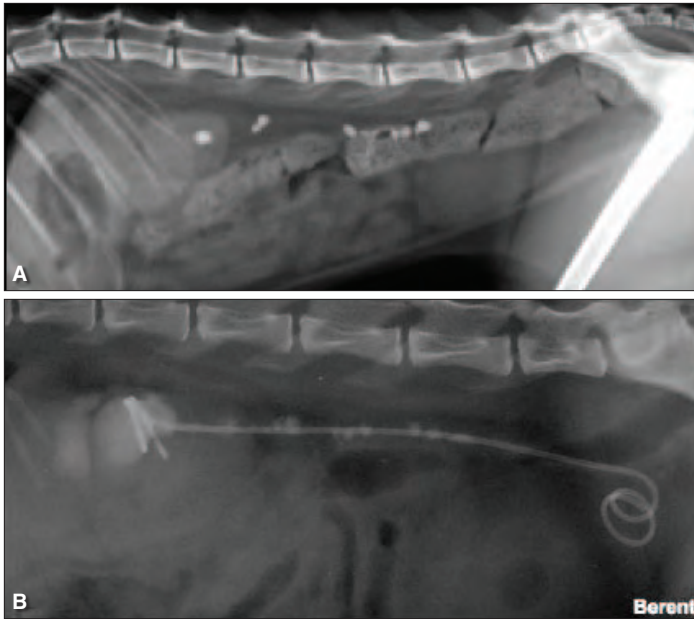


Figure 1. Lateral abdominal radiographs of a cat with numerous ureteral stones causing a ureteral obstruction (A) before and (B) after ureteral stent placement.

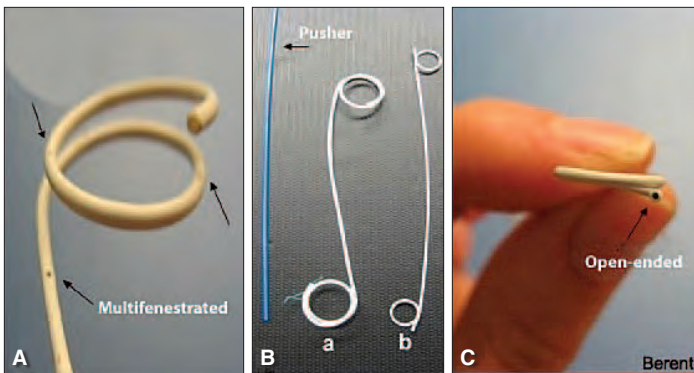


Figure 2. Double-pigtail ureteral stents. (A) Close-up view of the renal end of a double-pigtail ureteral stent showing the loop that goes in the renal pelvis and the multiple fenestrations along the length of the catheter. (B) Ureteral stents. One (a) is variable length with 1.5 loops on each end, and the other (b) has 1 loop on each end. The blue catheter allows the surgeon to push the distal end of the stent into the urinary bladder. (C) End-on image of the end of the tip of the ureteral stent showing where the guide wire is placed to keep the stent straight during placement and where urine drains through.

immediate renal decompression, stabilization of associated azotemia, a decreased risk of ureteral stricture or ureteral leakage/uroabdomen, and a decreased recurrence of ureteral obstruction.¹¹ Placement of a double-pigtail ureteral stent, via either minimally invasive techniques (endoscopy and interventional fluoroscopy in most dogs) or surgery (nephrostomy access in most cats), could potentially circumvent complications of surgery alone (e.g., leakage, stricture, reobstruction) and quickly stabilize the patient (**FIGURE 1**, **FIGURE 2**, and **FIGURE 3**). Typical ureteral stent sizes are 2.5 Fr for cats and 3.7, 4.7, or 6 Fr for dogs. Ureteral stents have many benefits: (1) immediate decompression of the renal pelvis, (2) passive ureteral

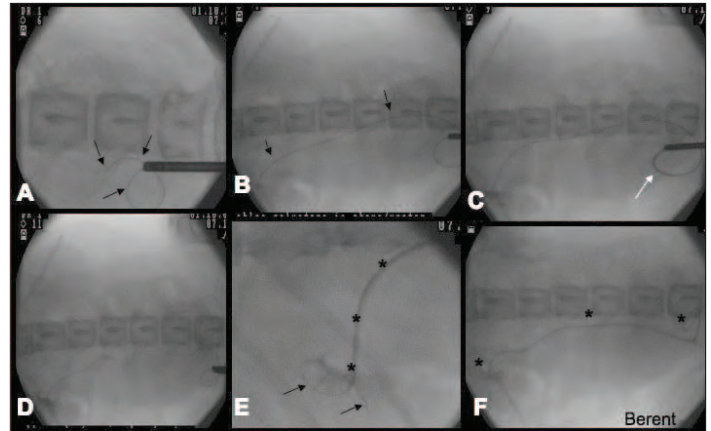


Figure 3. Endoscopic and fluoroscopic placement of a ureteral stent in a female dog. (A) Guide wire (black arrows) being advanced up the right ureter through the endoscope. (B) Guide wire (black arrows) being advanced into the renal pelvis under fluoroscopic guidance. (C) Open-ended ureteral catheter (white arrow) being advanced over the guide wire to perform a ureteropyelogram. (D) Retrograde ureteropyelogram under fluoroscopic guidance. (E) Guide wire (black arrows) replaced through the catheter and ureteral stent (black asterisks) being advanced over the guide wire up the ureter. (F) Ureteral stent (black asterisks) in place, forming one loop in the renal pelvis and a second loop in the urinary bladder.

dilation for urine and stone passage, (3) prevention of strictures and leakage associated with surgical or nonsurgical procedures, and (4) prevention of a ureteral obstruction after extracorporeal shock-wave lithotripsy (ESWL).⁴ All of these benefits have been clearly documented in human medicine and, more recently, in veterinary medicine, with the placement of ureteral stents in more than 100 feline and 150 canine ureters for various indications in my practice (A. B.).^{4,8,11,15} The risks of stent placement need to be understood, and owners must be educated on these risks before considering this option (**TABLE 2**). Most of the risks are seen months to years after stent placement, are typically not life threatening, and are relatively easy to address on an outpatient basis. The greatest risks are associated with device placement, as the stent can be very difficult to place in some patients, and appropriate training and experience with the procedure are critical to its success.

Extracorporeal Shock-Wave Lithotripsy

Ureteroliths can also be treated by ESWL in dogs and cats.³ With a traditional wet lithotripter, reintervention was reported to be necessary in >50% cases.^{16,17} The focal zone of a dry lithotripter is smaller than that of a wet lithotripter^{16,17} and more powerful over the stone, which enhances stone fragmentation during a single treatment but makes it easier to miss stones during patient movement and respiratory excursions.¹⁸ Newer dry units have better imaging capacity (fluoroscopy) that can identify stones with better accuracy, improving treatment success. In one study of five cats with ureterolithiasis treated by ESWL (wet unit), only one cat had complete resolution of the ureterolith, and partial fragmentation occurred in two other cats; however, these fragments were still

³For more information about ESWL, see "New Alternatives for Minimally Invasive Management of Uroliths: Nephroliths," in the February 2013 issue of *Compendium*.

Table 2. Immediate, Short-Term, and Long-Term Complications of Minimally Invasive Procedures to Manage Ureteroliths

Procedure	Complications			
	Operative	Postoperative (<1 wk)	Short-Term (1 wk–1 mo)	Long-Term (>1 mo)
Ureteral stent placement in cats	<ul style="list-style-type: none"> • Ureteral perforation by guide wire (little clinical consequence) • Leakage if concurrent ureterotomy needed • Eversion of ureteral mucosa during stent passage • Ureteral tear during stent passage 	<ul style="list-style-type: none"> • Fluid overload during postobstructive diuresis (<5%) • Failure of creatinine level to improve (<5%) • Mortality <8%, typically due to nonurinary causes (pancreatitis or congestive heart failure) 	<ul style="list-style-type: none"> • Dysuria (self-limiting; 7–14 d) • Inappetence (temporary) 	<ul style="list-style-type: none"> • Dysuria (38%); nearly all respond to prednisolone and/or prazosin • UTI (30%; 34% preoperatively) • Reobstruction (19%) <ul style="list-style-type: none"> —Stricture recurrence (54%) —Adhesions around ureter (23%) • Obstructive pyelonephritis (8%) • Chronic hematuria (18%) • Stent migration (6%) • Ureteral reflux (1%)
Ureteral stent placement in dogs	<ul style="list-style-type: none"> • Endoscopic failure (~5%) • Ureteral perforation (<1%) • Urine leakage (<1%) • Ureteral tear (<1%) 	<ul style="list-style-type: none"> • Mortality <1% 	<ul style="list-style-type: none"> • Dysuria (<1%) 	<ul style="list-style-type: none"> • Proliferative tissue at ureterovesicular junction (25%) • UTIs (~10%; >60% pre-op) • Migration (<5%) • Occlusion (<5%) • Dysuria (<3%)
SUB	<ul style="list-style-type: none"> • Renal pelvis penetration by guide wire (<5%) • Kinking of catheters (<1%) • Inability to place SUB device (<1%) 	<ul style="list-style-type: none"> • Urine leakage (5%) • Fluid overload (<5%) • Failure of creatinine level to improve (<5%) • Blockage of system (5%) (blood clot, purulent material, device failure) • Mortality 5.6% 	<ul style="list-style-type: none"> • Dysuria (<2%) • Inappetence (temporary) 	<ul style="list-style-type: none"> • UTI (15%; 35% preoperatively) • Blockage of system (7%) (stones, 6%; purulent material, 1%) • Dysuria (<2%)

SUB = subcutaneous ureteral bypass, UTI = urinary tract infection.

too large to pass down the ureter.¹⁹ In my (A. B.) experience, success in stone fragmentation and passage was seen in two of an additional five cats, suggesting an approximate 30% passage rate overall (3 of 10). However, larger studies are needed to confirm these results.

In my experience (A. B.), in one cat with multiple ureteroliths, improvement in azotemia was documented after ESWL despite little change in appearance of the ureteroliths, likely reflecting improvement to a partial obstruction with fragmentation. In another cat, a partially obstructive ureterolith was successfully fragmented after two lithotripsy treatments. However, increased obstruction was observed between treatments in this case.²⁰

Ureteroscopy

Contrary to human medicine, ureteroscopy is rarely performed in veterinary patients. In my (A. B.) practice, most dogs with ureteral

obstructions have an endoscopic stent placed, and may also undergo ESWL. If the patient is large enough (at least 39.6 to 44 lb [18 to 20 kg]), ureteroscopy can be considered. However, in my experience, most dogs with ureterolithiasis are small terrier or toy breeds, making this an uncommon procedure.

Ureteroscopy is performed via cystoscopy so that the ureterovesicular junction can be identified. A guide wire is advanced retrograde up the ureteral orifice under cystoscopic and fluoroscopic guidance. A ureteral catheter is then advanced over the guide wire into the distal ureter for a retrograde ureteropyelogram. This helps to localize the stones and the path of the ureter and renal pelvis. The guide wire is readvanced up the ureter until it is curled inside the renal pelvis. The catheter and cystoscope are then removed, and a flexible ureteroscope is inserted over the wire and advanced up the ureter to the level of the stone. Often,

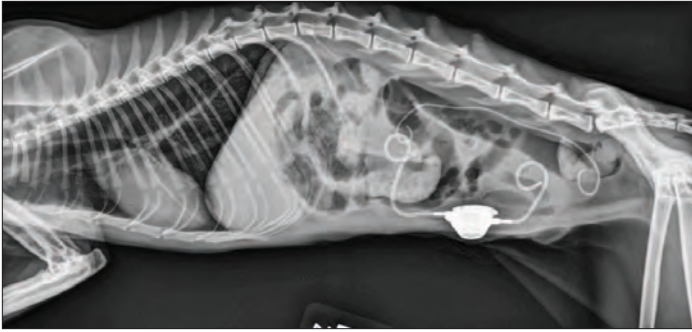


Figure 4. Lateral radiograph of a cat with a subcutaneous ureteral bypass.

a second safety wire is placed before ureteroscopy advancement, using a dual-lumen catheter, and a ureteral dilator (8 to 10 Fr) is needed to gain easier access into the distal ureter with the ureteroscopy. Once the scope is in place and the stone is identified, a laser fiber is passed through the working channel of the ureteroscopy until it contacts the stone and laser lithotripsy is performed. The fragments are subsequently removed using a stone retrieval basket. After this procedure, a temporary double-pigtail ureteral stent is placed to ensure adequate urine passage, as temporary ureteral edema may occur and small, residual stone fragments may transiently obstruct the lumen.

Special Considerations for Ureteroliths in Cats

Feline ureteroliths are typically more frustrating than canine ureteroliths due to the normal small diameter of the feline ureter (<0.4 mm) and the surgical limitations. In cats, ESWL and ureteroscopy are not typically possible or advised. The use of a double-pigtail ureteral stent to bypass feline ureteroliths, allowing for passive ureteral dilation and immediate renal pelvis decompression with stabilization of azotemia, has been a relatively effective approach in my (A. B.) practice. The stent can be placed endoscopically, fluoroscopically, or, more commonly, surgically with fluoroscopic assistance^{4,11,14,21} (FIGURE 1 and FIGURE 3). Surgical placement with fluoroscopic guidance has a procedural success rate of more than 95%; with endoscopic and fluoroscopic guidance, the success rate is 20%. There are relatively few major long- or short-term complications (TABLE 2), and the stents are typically left in place long-term; in my (A. B.) experience to date, the longest duration of stent patency in a feline ureter is more than 4 years. Stents have classically been placed in feline patients that were considered difficult or nonsurgical candidates, requiring multiple ureterotomy procedures and/or with concurrent nephroliths (86% of cases).¹⁵ As the success of stent placement has improved and better stents have been designed, more patients have been considered candidates for this intervention. As stated above, the main consideration is ensuring that the person placing the stent has appropriate training and experience with the device. Those with less experience may encounter many more complications with stent placement.

For cats that are poor traditional surgical candidates, that have ureteral strictures or very proximal ureteral obstruction, or in which stent placement is unsuccessful, a newer procedure can

Box 1. Hospitals Equipped for Minimally Invasive Management of Ureteroliths

The Animal Medical Center

New York, NY 10065
 Contact: Dr. Allyson Berent
 E-mail: Allyson.Berent@AMCNY.org
 Phone: (212) 838-8100

Currently performing ESWL, SUB, and ureteral stenting (canine and feline)

The Ohio State University

Columbus, OH
 Contact: Dr. Brian Scansen
 Phone: (614) 292-3551

Currently performing ureteral stenting (canine and feline)

University of Guelph

Ontario Veterinary College
 Canada
 Contact: Alice Defarges
 E-mail: adefarge@uoguelph.ca
 Phone: (519) 823-8830

Currently performing SUB and ureteral stenting (canine and feline)

Purdue University School of Veterinary Medicine

West Lafayette, IN 47906
 Contact: Dr. Larry Adams
 E-mail (Referral desk): PUSAH@purdue.edu

Currently performing ESWL, SUB, and ureteral stenting (canine and feline)

University of California, Davis

William R. Pritchard Veterinary Medical Teaching Hospital
 Davis, CA
 Contact: Dr. William Culp or Dr. Carrie Palm
 Phone: (530) 752-1393

Currently performing SUB and ureteral stenting (canine and feline)

University of Montreal

Montreal, QC
 Canada
 Contact: Dr. Marilyn Dunn
 Phone: (450) 778-8111

Currently performing SUB and ureteral stenting (canine and feline)

ESWL = extracorporeal shock-wave lithotripsy, SUB = subcutaneous ureteral bypass.

be considered. This procedure, called a *subcutaneous ureteral bypass* (SUB), has been performed in 90 cats and five dogs to date.¹⁵ It involves the placement of a nephrostomy tube and a cystostomy tube that are connected subcutaneously to a shunting port, allowing for urine drainage from the kidney directly to the bladder, bypassing the ureter (FIGURE 4). Further investigation is necessary before this procedure can be broadly recommended; however, outcomes have been favorable.¹⁵ The longest period for which an SUB device has

remained in place is 3.5 years, and the short- and long-term complications seen with this device are fewer and less severe than those seen with ureteral stents in cats. For feline ureteral strictures, we feel that the SUB device is a better treatment option than ureteral stents because of the higher rate of stent occlusion with ureteral strictures (~50%) compared with an SUB device (0%) so far.

It is important to understand that ureteral stenting or the placement of an SUB device should only be performed by those trained in these procedures (**BOX 1**), as they can be extremely challenging. The success rates given here are those of one institution with extensive experience with both of these devices. These procedures are not recommended to be considered in all facilities or in all patients.

Overall, the long-term success rate of stents and SUBs in feline patients is high, and reobstruction rates are lower than those seen with traditional surgery.

Conclusion

In general, the minimally invasive management of veterinary urolithiasis is following the trend seen in human medicine. Over the past 5 to 10 years, great strides have been made in adapting human technology for veterinary patients. Small adjustments to various devices have already allowed many hurdles to be crossed, and more will be overcome over the next few decades. Newer treatment options are being investigated, and outcomes are promising, although these modalities still require thorough investigation, extensive training, and publication. As yet, most of these interventional options are currently available only at a few institutions around the world.

References

1. Low WW, Uhl JM, Kass PH, et al. Evaluation of trends in urolith composition and characteristics of dogs with urolithiasis: 25,499 cases (1985-2006). *J Am Vet Med Assoc* 2010;236:193-200.
2. Kyles AE, Hardie EM, Wooden BG, et al. Management and outcome of cats with ureteral calculi: 153 cases (1984-2002). *J Am Vet Med Assoc* 2005;226:937-944.
3. Wilson DR. Renal function during and following obstruction. *Annu Rev Med* 1977; 28:329-339.
4. Berent AC. Ureteral obstructions in dogs and cats: a review of traditional and new interventional diagnostic and therapeutic options. *J Vet Emerg Crit Care* 2011;21:86-103.
5. Coroneos E, Assouad M, Krishnan B, et al. Urinary obstruction causes irreversible renal failure by inducing chronic tubulointerstitial nephritis. *Clin Nephrol* 1997;48:125-128.
6. Snyder DM, Steffey MA, Mehler SJ, Drobatz KJ. Diagnosis and surgical management of ureteral calculi in dogs: 16 cases (1990-2003). *N Z Vet J* 2005;53:19-25.
7. Achar E, Achar RA, Paiva TB, et al. Amitriptyline eliminates calculi through urinary tract smooth muscle relaxation. *Kidney Int* 2003;64:1356-1364.
8. Wanajo I, Tomiyama Y, Tadachi M, et al. The potency of KUL-7211, a selective ureteral relaxant, in isolated canine ureter: comparison with various spasmolytics. *Urol Res* 2005; 33:409-414.
9. Berent AC, Weisse CW, Todd KL, Bagley DH. Use of locking-loop pigtail nephrostomy catheters in dogs and cats: 20 cases (2004-2009). *J Am Vet Med Assoc* 2012;241(3):348-357.
10. Forman MA, Francey T, Cowgill LD. Use of glucagon in the management of acute ureteral obstruction in 25 cats. [abstract] *J Vet Intern Med* 2004;18:417.
11. Berent AC. Ureteral stenting for feline ureteral obstructions: technical and clinical outcomes: 74 ureters (2006-2011). Oral research communications of the 21st ECVIM-CA Congress. *J Vet Intern Med* 2011;25(6):1470-1509.
12. Ross SJ, Osborne CA, Kirk CA, et al. Clinical evaluation of dietary modification for treatment of spontaneous chronic kidney disease in cats. *J Am Vet Med Assoc* 2006; 229:949-957.
13. Elliot J, Barber PJ. Feline chronic renal failure: clinical findings in 80 cases diagnosed between 1992-1995. *J Small Anim Pract* 1998;39:78-85.
14. Berent AC, Weisse C, Bagley D, et al. Ureteral stenting for feline ureteral obstructions: technical and clinical outcomes. [abstract] *J Vet Intern Med* 2009;23:688.
15. Berent AC. The use of subcutaneous ureteral bypass for the treatment of feline ureteral obstructions. [abstract] *J Vet Intern Med* 2010;25(6):1470.
16. Lulich JP, Adams LG, Grant D, et al. Changing paradigms in the treatment of uroliths by lithotripsy. *Vet Clin North Am Small Anim Pract* 2009;39:143-160.
17. Lane IF. Lithotripsy: an update on urologic applications in small animals. *Vet Clin North Am Small Anim Pract* 2004;34:1011-1025.
18. Lingeman JE. Extracorporeal shock wave lithotripsy. Development, instrumentation, and current status. *Urol Clin North Am* 1997;24:185-211.
19. Adams LG, Senior DF. Electrohydraulic and extracorporeal shock-wave lithotripsy. *Vet Clin North Am Small Anim Pract* 1999;29:293-303.
20. Lane IF. Extracorporeal shock wave lithotripsy for canine and feline ureteroliths. *Proc ACVIM* 2005.
21. Berent AC. Ureteral stenting: a new alternative to feline ureterolithiasis? *Proc ACVIM* 2008.