

# Encephalitozoon cuniculi Infection in Rabbits

Carly N. Jordan, BS, MS  
Anne M. Zajac, DVM, PhD  
David S. Lindsay, PhD

Virginia–Maryland Regional College of Veterinary Medicine

**ABSTRACT:** *Encephalitozoon cuniculi* is an important protozoan parasite of pet rabbits. It most commonly infects the brain and kidneys, causing clinical signs such as head tilt, ataxia, and hindlimb paralysis, although most cases of infection are subclinical. Transmission of this parasite primarily occurs transplacentally or by ingestion or inhalation of spores passed in the urine. Although no prevalence data exist for infection in rabbits in the United States, serologic studies indicate that exposure is common among rabbits throughout Europe and Africa.

**E**ncephalitozoon *cuniculi* is an obligate intracellular parasite in the phylum Microsporida, which is defined by its resistant spore stage.<sup>1</sup> Microsporidia receive little attention in veterinary medical curricula because they are considered important only as parasites of rabbits and fish. Microsporidia are important parasites of humans as well, with some species causing severe disease and death in immunocompromised individuals. Microsporidia are among the smallest protozoa known and have the smallest genome (i.e., 2.9 million base pairs) of all eukaryotes.<sup>1</sup> Microsporidia have many characteristics in common with prokaryotes. For example, they lack mitochondria, centrioles, and peroxisomes. In addition, the Golgi apparatus is atypical and primitive, and ribosomes of Microsporidia closely resemble those of prokaryotes.<sup>2</sup> Sequencing of microsporidial genes has suggested a relationship with fungi.<sup>3</sup> This theory is supported by the presence of chitin in the spore wall and by intranuclear division.

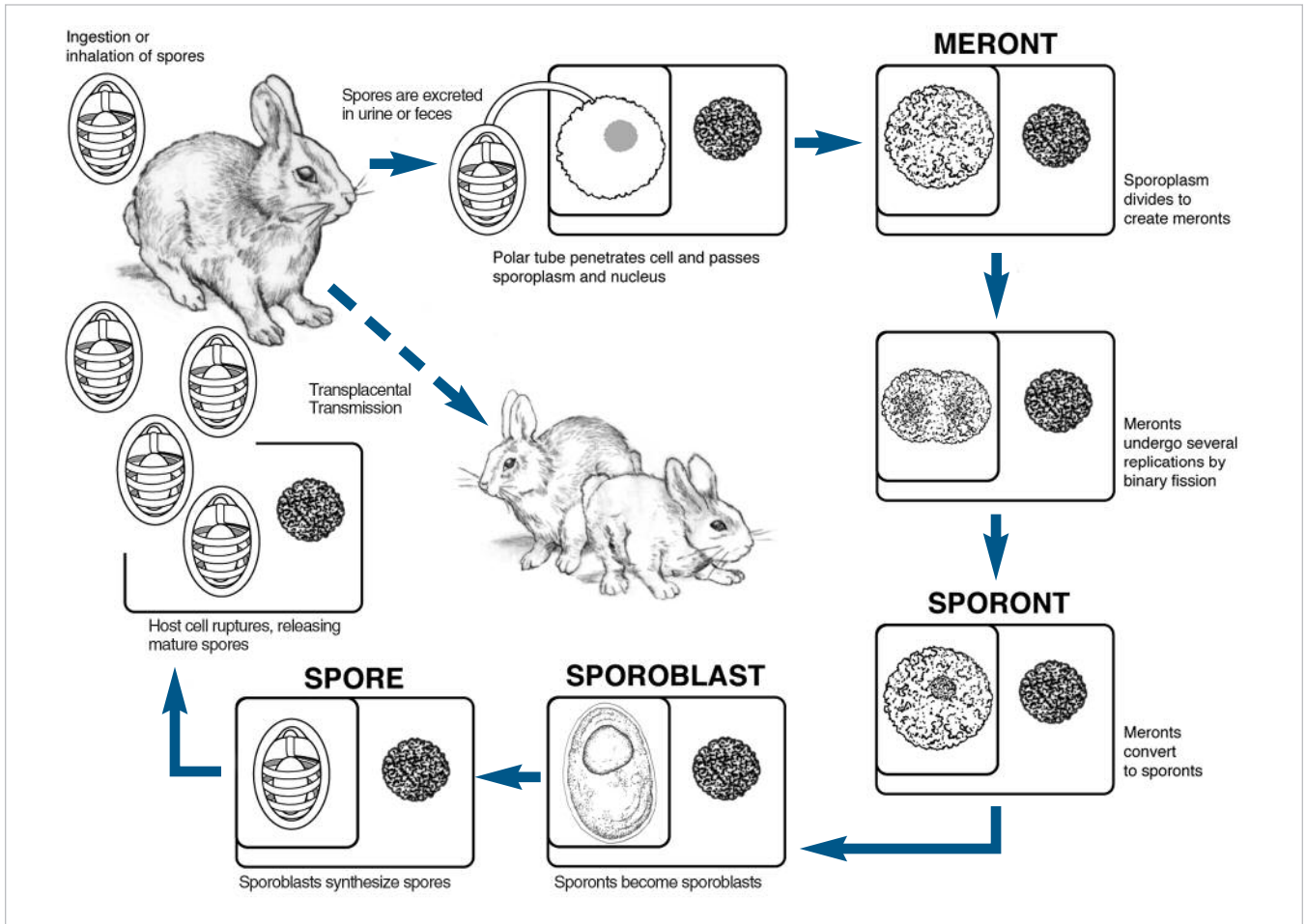
## LIFE CYCLE OF ENCEPHALITOZOON CUNICULI

The life cycle of *E. cuniculi* takes 3 to 5 weeks to complete.<sup>4</sup> Hosts are infected by ingestion or inhalation of spores or by transplacental transmission<sup>1</sup> (Figure 1). The spore penetrates a host cell via the polar tube. The polaroplast swells, and the anchoring disk stabilizes the tube. The polar tube is inverted while extruded, and membranes from the polaroplast connect with the tube to extend its length.<sup>1</sup> The extrusion occurs with great force and allows penetration of the host cell without disturbance of the host cell membrane. The posterior vacuole swells and forces the sporoplasm and nucleus through the polar tube<sup>5</sup> (Figure 2). The tip of the polar tube inside the host cell envelopes the sporoplasm to become the parasite's outer membrane.<sup>1</sup>

The sporoplasm divides, creating meronts, the major proliferative stage that divides by binary fission. This stage exists in a parasitophorous vacuole (PV) lined by the host cell membrane. Meronts may undergo several replications before converting into sporonts.<sup>4</sup> In most species, the sporonts exist within a PV.

Send comments/questions via email  
[editor@CompendiumVet.com](mailto:editor@CompendiumVet.com)  
or fax 800-556-3288.

Visit [CompendiumVet.com](http://CompendiumVet.com) for  
full-text articles, CE testing, and CE  
test answers.



**Figure 1.** Life cycle of *E. cuniculi*. The cellular details are visible only by using transmission electron microscopy.

Sporonts convert to sporoblasts, either immediately or after one division. Sporoblast is the stage that synthesizes the polar tube and its accessory organelles to become mature spores.<sup>2</sup> Once a host cell is full of mature spores, the cell bursts, and the spores are released (Figure 3). These spores are resistant to environmental factors and can remain viable for several years. Spores are passed in the urine of rabbits, beginning around 35 days after infection, and continue to be excreted for 2 to 3 months.<sup>6</sup>

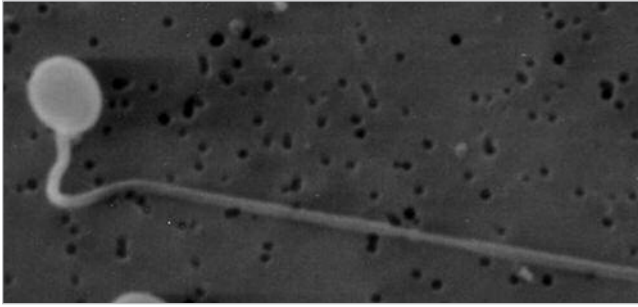
## ENCEPHALITIZOONOSIS

*E. cuniculi* was first identified in 1922 in a colony of research rabbits and is now recognized as a common pathogen infecting pet rabbits.<sup>7-9</sup> There have been no large-scale studies of encephalitozoonosis in rabbits in the United States, but surveys conducted in Europe have shown high rates of infection in asymptomatic rab-

bbits (7% to 42%) and those with neurologic signs (40% to 85%; Table 1).

Adult rabbits are infected by ingestion or inhalation of spores passed in the urine, but vertical transmission can also occur. Transplacental transmission has been confirmed by detection of *E. cuniculi* DNA in placentas and fetuses delivered by cesarean section.<sup>10</sup> Screening and culling of infected weanlings can eliminate the pathogen in a breeding colony.<sup>11</sup> The infectious dose required to cause disease in 50% of rabbits is only 46 *E. cuniculi* spores.<sup>12</sup>

The route of *E. cuniculi* infection in rabbits begins with invasion of the intestinal epithelium, where parasites undergo several rounds of replication.<sup>13</sup> From there, infective spores are disseminated throughout the body—first to the heart, lungs, liver, and spleen. To this point, rabbits are usually asymptomatic, and damage to these organs is limited. The final destinations of *E. cuniculi* in rabbits are the kidneys, eyes, and brain, where the para-



**Figure 2.** Scanning electron micrograph showing a spore of *E. cuniculi* with its polar tube extruded.

site reaches equilibrium with the host's immune response.<sup>13</sup> The parasite may reside in these organs indefinitely without ever causing clinical signs in an animal. However, some rabbits are more affected by invasion of these organs, and clinical disease occurs. Rabbits younger than 6 weeks of age are more likely to develop severe disease.<sup>4</sup>

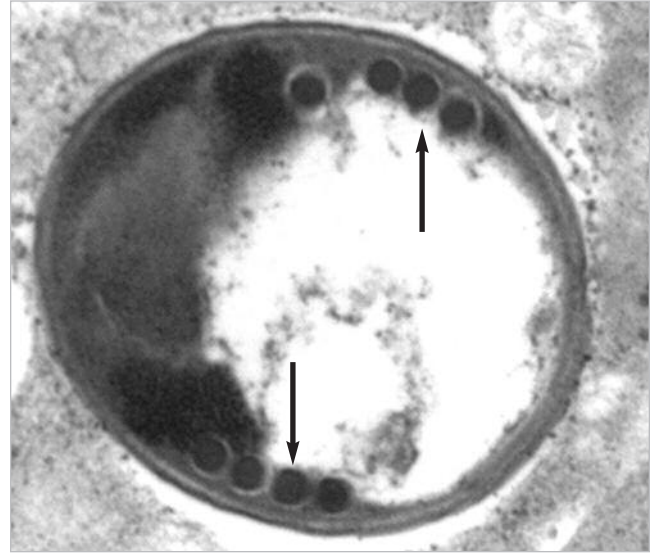
### Neurologic Disease

Most *E. cuniculi* infections are asymptomatic, but when clinical signs are observed, they are usually neurologic. The onset of disease in rabbits can be sudden, and severe cases may be rapidly fatal. Early signs of disease include vestibular disease, head tilt, and ataxia. Hindlimb weakness or paralysis is common with loss of postural reactions and sluggish spinal reflexes.<sup>14</sup> Head tremors and seizures may occur because of an inflammatory response to ruptured brain cells.<sup>15</sup> Seizures typically occur suddenly, and some rabbits are left blind or comatose, whereas others recover completely. Rabbits chronically affected by *E. cuniculi* may demonstrate stargazing, loss of balance, and swaying or nodding when at rest.<sup>16</sup> Animals may become aggressive and lose sight or hearing.

Examination of brain tissue typically demonstrates meningoencephalitis with perivascular cuffing, and focal granulomas of glial cells and lymphocytes may also be observed.<sup>16</sup> Multifocal mineralization is also observed in some cases.<sup>14</sup> Brain lesions are usually not observed for at least 8 weeks after antibodies are first detected or approximately 3 months after infection.<sup>16</sup>

### Kidney Disease

Infection of the kidneys may lead to polydipsia and polyuria as well as urinary incontinence, although it is not clear whether this is due to neurologic or kidney disease.<sup>17</sup> Gross examination of the kidneys reveals a



**Figure 3.** Transmission electron micrograph showing a cross-section of an *E. cuniculi* spore. The arrows point to polar tube coils.

characteristic pitted appearance with irregular grayish white spots and depressions.<sup>18,19</sup> The kidneys are shrunken, fibrotic, and pale. Histologic examination reveals granulomatous interstitial nephritis with infiltration by macrophages.<sup>19</sup> Degeneration of renal tubules is also observed.<sup>16,20</sup>

Blood biochemistry may show a mild elevation in blood urea, with levels around 150 mg/dl. Creatinine concentrations can reach 6 mg/dl, and serum potassium may also be elevated.<sup>16</sup> Some animals experience anemia and low hemoglobin and erythrocyte counts.

### Ocular Disease

Ocular disease is common in *E. cuniculi*-infected rabbits. Some researchers believe that *E. cuniculi* spores infect the developing lens in utero, when the lens capsule is thin or absent.<sup>16</sup> Infection of the lens results in phacoclastic uveitis, another condition that may also be caused by pasteurellosis. The anterior lens capsule ruptures, leading to zonal granulomatous lens uveitis, with inflammation occurring near the capsule break.<sup>16</sup> Severe inflammation of the globe can lead to loss of vision. Cataracts may occur as a result of disruption of the lens fibers, although vision is usually retained.

### DIFFERENTIAL DIAGNOSIS

Presentation of encephalitozoonosis in rabbits may be easily confused with disease caused by several other

**Table 1. Prevalence of *E. cuniculi* in Rabbits as Determined by Serologic Surveys**

Location	Health	No. Tested	No. Positive	% Positive	Study
Slovakia	No information available	571	238	41.7%	Halánová et al <sup>38</sup>
Switzerland	Asymptomatic	292	22	7.5%	Deplazes et al <sup>39</sup>
	Neurologic signs	72	61	84.7%	Deplazes et al <sup>39</sup>
W. Yorkshire, UK	Asymptomatic	38	14	36.8%	Harcourt-Brown et al <sup>18</sup>
	Neurologic signs	58	23	39.7%	Harcourt-Brown et al <sup>18</sup>
	Ocular lesions	8	8	100%	Harcourt-Brown et al <sup>18</sup>
Spain	No information available	22	2	9.1%	Lores et al <sup>40</sup>

pathogens. The differential diagnosis in rabbits presenting with neurologic signs should include infection with *Toxoplasma gondii*, *Baylisascaris procyonis*, *Listeria monocytogenes*, and *Pasteurella multocida*.<sup>20</sup> Serologic methods may be used to identify infections with *T. gondii* or *L. monocytogenes*. Postmortem diagnosis of *T. gondii* or *B. procyonis* infection can be determined by histopathologic examination of brain tissue.

*P. multocida* infection in rabbits is common, and clinical signs of infection closely resemble those due to

## METHODS OF DIAGNOSIS

### Serology

Serologic testing is the most common method of diagnosing *E. cuniculi* infection. In naturally infected rabbits, antibodies to *E. cuniculi* are usually detectable by 4 weeks after infection, with peak titers observed around 9 weeks.<sup>4,22</sup> The indirect immunofluorescent antibody (IFA) test is the gold standard for serologic diagnosis of Microsporidia infection, and IFA titers greater than 1:20 are considered positive.<sup>23</sup> Monoclonal and polyclonal

*Serologic surveys in Europe report the prevalence of *E. cuniculi* in rabbits with neurologic disease to be 40% to 85%.*

encephalitozoonosis, although the most common clinical signs associated with *P. multocida* are upper respiratory tract infection and pneumonia. *E. cuniculi* infection causes central vestibular disease in rabbits, and *P. multocida* infection typically causes peripheral vestibular disease.<sup>21</sup> However, *P. multocida* infection can also result in central lesions if abscesses form along the vestibular tract.<sup>16</sup>

Hematology can be useful in differentiating between *E. cuniculi* and *P. multocida* infections. No hematologic changes are associated with *E. cuniculi* infection, but patients with pasteurellosis often have neutrophilia and left shift.<sup>16</sup> Radiography of the head may show changes in the tympanic bullae associated with chronic otitis media due to *P. multocida* infection. Serology is useful only for ruling out pathogens, as a high percentage of rabbits have been exposed to one of these pathogens.

antibodies have been developed for *E. cuniculi* infection for use in IFA tests on an experimental basis and in some diagnostic laboratories.<sup>24–26</sup>

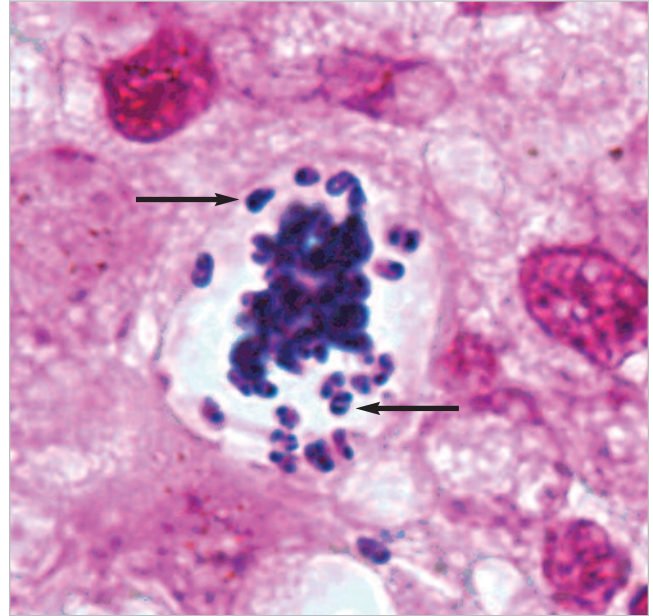
ELISA is another method of serologically diagnosing Microsporidia infection. Two groups of researchers have evaluated ELISA for diagnosing *E. cuniculi* infection by comparing the results with IFA. One group examined 135 rabbits diagnosed with infection by histology and 75 rabbits without a history of illness.<sup>27</sup> A few samples were positive by only one method, but no statistically significant differences were calculated between the sensitivities and specificities of the two assays.<sup>27</sup> Another group used a modified ELISA (dot-ELISA) to detect antibodies to *E. cuniculi* in rabbits, dogs, squirrel monkeys, and mice. Comparison of the dot-ELISA with IFA showed agreement between the two assays.<sup>28</sup>

### Light Microscopy

Examination of tissue samples or secretions is another common method of diagnosing *E. cuniculi* infection in rabbits. Kidney biopsy can reveal spores approximately 5 weeks after antibodies are first produced or approximately 9 weeks after infection.<sup>20</sup> In infected patients with uveitis, *E. cuniculi* spores can be found in the liquefied lens cortex. Several staining techniques are available for identifying Microsporidia spores; however, current staining methods can, at best, identify Microsporidia but cannot distinguish between *Encephalitozoon* spp. These methods are also hindered by the fact that Microsporidia are often mistaken for bacteria or yeasts.

Calcofluor white M2R is a chemofluorescent stain commonly used to identify Microsporidia in urine sediments, fecal smears, and respiratory lavages.<sup>29</sup> This is the most sensitive method of staining Microsporidia, and the procedure can be completed in only 15 minutes.<sup>29</sup> However, this stain is not specific for Microsporidia, and spores may be confused with yeasts or other particulate matter in the sample.<sup>30</sup> Because a compound microscope with an ultraviolet light source is needed for this staining method, it is used only in diagnostic laboratories.

Chromotrope-based (modified trichrome) staining methods are also used to identify Microsporidia in feces, urine sediment, or respiratory secretion samples. Chromotrope stains color spores pinkish-red, and quick-hot Gram's-chromotrope stains color spores dark violet.<sup>31</sup> Characteristic morphologic features of Microsporidia that are visible using these stains are a belt-like stripe, a



**Figure 4.** Gram-stained mouse adrenal tissue showing gram-positive spores of *E. cuniculi* (arrows).

### Electron Microscopy

Transmission electron microscopy, although impractical for most veterinarians, can be used to differentiate among the four species of Microsporidia that most commonly infect humans and companion animals: *E. cuniculi*, *Encephalitozoon intestinalis*, *Encephalitozoon hellem*, and *Enterocytozoon bieneusi*. *Ent. bieneusi* is slightly smaller than *Encephalitozoon* spp: *Ent. bieneusi* is  $0.5 \times 1.5 \mu\text{m}$ , whereas *Encephalitozoon* spp range from  $1$  to  $1.5 \times 2$  to  $2.5 \mu\text{m}$ .<sup>1</sup> The number of polar

*Clinical signs of E. cuniculi infection in rabbits are primarily neurologic, including head tilt, paralysis, and seizures.*

vacuole, and gram-positive granules. Spores may be confused with bacteria or yeasts.

Giemsa and Gram's stains are not recommended for fecal smears because they do not differentiate between Microsporidia and bacteria or yeast that may be present in the sample. However, Giemsa stains may be useful in urine or tissue samples, and spores stain light blue.<sup>30</sup> Microsporidia spores are gram-positive in gram-stained tissue sections (Figure 4), which can aid in identification in histologic samples.

tube coils is useful in differentiating between *Encephalitozoon* spp (Table 2). *E. intestinalis* can be distinguished from all other *Encephalitozoon* spp by examination of the PV within an infected host cell. All *Encephalitozoon* species develop within a PV, but *E. intestinalis* is the only species of Microsporidia known to exist in a septated PV that isolates each developing spore<sup>32</sup> (Figure 5). *Ent. bieneusi* does not create a PV; instead, it develops in direct contact with the host cell cytoplasm.<sup>8</sup>

**Table 2. Morphologic Characteristics of Common Microsporidia**

	<i>E. cuniculi</i>	<i>E. intestinalis</i>	<i>E. hellem</i>	<i>Ent. bieneusi</i>
Spore dimensions (µm)	1.5 × 2.5	1.2 × 2	1 × 2.5	0.5 × 1.5
No. of polar tube coils	5–7 (single row)	4–7 (single row)	4–9 (single row)	4–5 (double row)
Development in host cell	PV	Septated PV	PV	Direct contact with cytoplasm

*PV* = parasitophorous vacuole.

### Molecular Techniques

Polymerase chain reaction (PCR) testing can be used to positively identify species of Microsporidia from feces, urine, or tissue samples. Specific primers are available for *E. cuniculi*, *E. intestinalis*, and *E. hellem* that amplify diagnostic fragments of 549, 520, and 546 base pairs, respectively.<sup>31</sup> This method is a definitive way to identify Microsporidia at the species level, but PCR testing is available only in select research laboratories.

### TREATMENT

Very little information is available on treating microsporidiosis in animals. Albendazole is the most common drug used to treat human Microsporidia infections. Albendazole acts by interfering with the polymerization of β-tubulin, thereby preventing nuclear division.<sup>33</sup> In vitro models have shown that albendazole is more than 90%

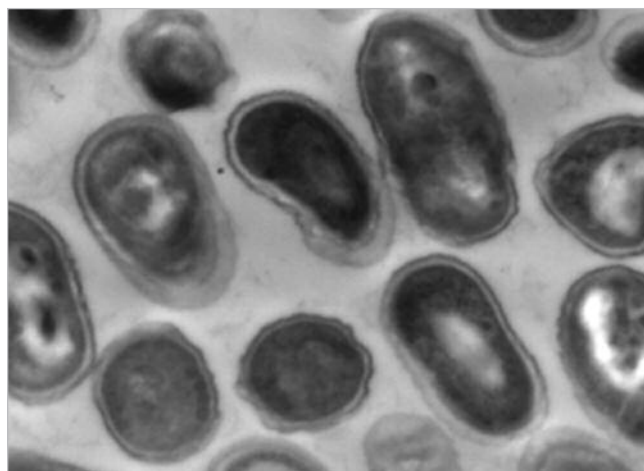
effective in inhibiting the growth of *E. cuniculi*.<sup>34</sup> No drugs have been approved to treat *E. cuniculi* infection in rabbits. However, treating rabbits with albendazole (15 mg/kg PO q24h) can reduce clinical signs of disease and help stop passage of spores in urine.<sup>4,18</sup>

One case report<sup>35</sup> describes the use of oral albendazole together with topical prednisolone in the successful treatment of a rabbit with phacoclastic uveitis.

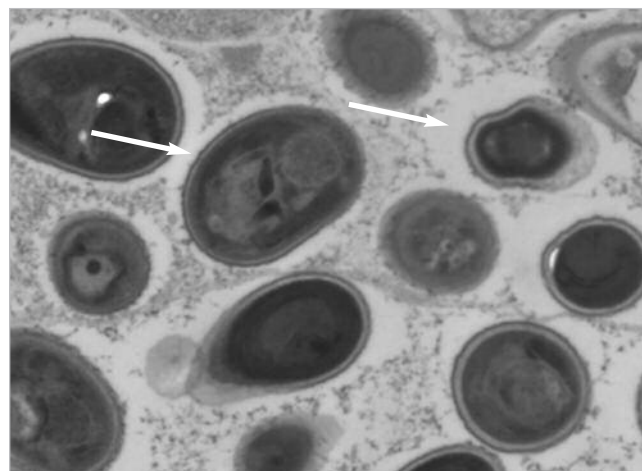
Phacoemulsification of the lens was performed after the rabbit did not respond well to initial treatment with 1% topical prednisolone, but 4 months after surgery, the rabbit presented with keratitis and a large inflammatory mass. The rabbit was treated with albendazole (30 mg/kg PO) for 4 weeks, and then the dose was reduced to 15 mg/kg PO for an additional 4 weeks.<sup>35</sup> Prednisolone (1%) was also administered as often as every 6 hours. After 8 weeks of treatment, the inflammation resolved but the cornea was slightly scarred.<sup>35</sup>

A related drug, fenbendazole, has been shown to prevent and treat *E. cuniculi* infection in rabbits. Eight naturally infected rabbits were treated with fenbendazole for 4 weeks; afterward, no parasites could be isolated from brain tissue.<sup>36</sup> One group of four rabbits was administered fenbendazole (0.1 ml/kg PO bid for 7 days) in suspension before experimental inoculation

**Figure 5. Transmission electron micrographs of *Encephalitozoon* spores.**



*E. cuniculi* spores developing within kidney cells.



Arrows point to septa surrounding *E. intestinalis* spores.

with *E. cuniculi*, and treatment continued for 21 days after inoculation.<sup>36</sup> The other group of four rabbits was fed 20 mg/kg of fenbendazole in pellet form from 7 days before to 2 days after infection. Both treatments were sufficient to prevent infection. The rabbits did not seroconvert, and spores were not isolated from the brain tissue of rabbits from either group when they were examined 120 days after infection.<sup>36</sup>

Anecdotal evidence suggests that tetracyclines may be administered to suppress *E. cuniculi*, although they are not sufficient to clear infections. They can be given in water at a concentration of 500 mg/L or as oral doses of 20 mg/kg bid.<sup>4</sup>

In mild cases, clinical signs can be treated using steroids to control inflammation. Corticosteroids are most effective for treating uveitis, and dexamethasone can be given at a dose of 2 mg/kg SC or IM.<sup>4</sup> However, corticosteroid administration may enhance parasite infection, so animals should be closely monitored.<sup>37</sup>

## CONCLUSION

*E. cuniculi* is an important pathogen of rabbits, and serologic surveys suggest that infection is common throughout Europe and Africa. Clinical signs usually result from infection of the brain and include ataxia, hindlimb paralysis, and seizures. Infection of the kidneys and eyes is also common, and clinical signs of ocular infection may include uveitis and cataracts. Transmission of the parasite occurs transplacentally or by ingestion or inhalation of spores. Serum antibodies to *E. cuniculi* may be identified using immunologic assays such as ELISA and IFA. Samples from urine, feces, and tissue can be tested via PCR testing for the presence of *E. cuniculi* DNA. No drugs are currently licensed for treating microsporidial infection in rabbits, but several reports suggest that human treatments are effective in controlling clinical signs and reducing parasite shedding. Although no direct evidence of animal-to-human transmission exists, it is widely accepted that *E. cuniculi* is a zoonotic parasite, and immunocompromised pet owners should be made aware of the risks.

## REFERENCES

- Weiss LM: Microsporidia: Emerging pathogenic protists. *Acta Trop* 78:89–102, 2001.
- Bigliardi E, Luciano S: Cell biology and invasion of the Microsporidia. *Microbes Infect* 3:373–379, 2001.
- Vossbrinck CR, Andreadis TG, Weiss LM: Phylogenetics: Taxonomy and the Microsporidia as derived fungi, in Lindsay DS, Weiss LM (eds): *World Class Parasites, vol 9: Opportunistic Infections: Toxoplasma, Sarcocystis, and Microsporidia*. Norwell, Kluwer Academic Publishers, 2004, pp 189–213.
- Richardson VCG: The head and neck. *Rabbits: Health, Husbandry and Diseases*. Oxford, UK, Blackwell Science, 2000, pp 130–131.
- Lom J, Dyková I (eds): Microsporidia (Phylum *Microspora* Sprague, 1977), in *Developments in Aquaculture and Fishes Science, vol 26: Protozoan Parasites of Fishes*. Amsterdam, The Netherlands, Elsevier, 1992, pp 125–157.
- Paré JA, Paul-Murphy J: Rabbits: Diseases of the reproductive and urinary systems, in Quesenberry KE, Carpenter JW (eds): *Ferrets, Rabbits, and Rodents*, ed 2. St. Louis, Saunders, 2004, p 191.
- Snowden KF: Zoonotic Microsporidia from animals and arthropods with a discussion of human infections, in Lindsay DS, Weiss LM (eds): *World Class Parasites, vo. 9: Opportunistic infections: Toxoplasma, Sarcocystis, and Microsporidia*. Norwell, Kluwer Academic Publishers, 2004, pp 123–134.
- Wasson K, Peper RL: Mammalian microsporidiosis. *Vet Pathol* 37:113–128, 2000.
- Wright JH, Craighead EM: Infectious motor paralysis in young rabbits. *J Exp Med* 36:135–140, 1922.
- Baneux PJ, Pognan F: In utero transmission of *Encephalitozoon cuniculi* strain type I in rabbits. *Lab Anim* 37:132–138, 2003.
- Howell JMC, Edington N: The production of rabbits free from lesions associated with *Encephalitozoon cuniculi*. *Lab Anim* 2:143–146, 1968.
- Cox JC, Hamilton RC, Pye D, Edmonds JW: The infectivity of *Encephalitozoon cuniculi* in vivo and in vitro. *Z Parasitenkd* 72:65–72, 1986.
- Cox JC, Hamilton RC, Attwood HD: An investigation of the route and progression of *Encephalitozoon cuniculi* infection in adult rabbits. *J Protozool* 26:260–265, 1979.
- Nast R, Middleton DM, Wheler CL: Generalized encephalitozoonosis in a Jersey wooly rabbit. *Can Vet J* 37:303–305, 1996.
- Deeb BJ, Carpenter JW: Rabbits: Neurologic and musculoskeletal diseases, in Quesenberry KE, Carpenter JW (eds): *Ferrets, Rabbits, and Rodents*, ed 2. St. Louis, Saunders, 2004, pp 203–209.
- Harcourt-Brown F: *Textbook of Rabbit Medicine*. Oxford, UK, Butterworth Heinemann, 2002.
- Kimman TG, Akkermans JP: *Encephalitozoon cuniculi* in a rabbit-breeding colony. *Tijdschr Diergeneeskd* 112:1405–1409, 1987.
- Harcourt-Brown FM, Holloway HK: *Encephalitozoon cuniculi* in pet rabbits. *Vet Rec* 152:427–431, 2003.
- Wesonga HO, Munda M: Rabbit encephalitozoonosis in Kenya. *Lab Anim* 26:219–221, 1992.
- Redrobe S: Urogenital system and disorders, in Flecknell PA (ed): *British Small Animal Veterinary Association: Manual of Rabbit Medicine and Surgery*. Quedgeley, BSAVA, 2000, p 54.
- Boydell P: Nervous system and disorders, in Flecknell PA (ed): *British Small Animal Veterinary Association: Manual of Rabbit Medicine and Surgery*. Quedgeley, BSAVA, 2000, p 59.
- Cox JC, Gallichio HA: Serological and histological studies on adult rabbits with recent, naturally acquired encephalitozoonosis. *Res Vet Sci* 24:260–261, 1978.
- Didier PJ, Didier ES, Snowden KS, et al: Encephalitozoonosis, in Greene CE (ed): *Infectious Diseases of the Dog and Cat*. Philadelphia, WB Saunders, 1998, pp 465–470.
- Alfa Cisse O, Ouattara A, Thellier M, et al: Evaluation of an immunofluorescent-antibody test using monoclonal antibodies directed against *Enterocytozoon bieneusi* and *Encephalitozoon intestinalis* for diagnosis of intestinal microsporidiosis in Bamako (Mali). *J Clin Microbiol* 40:1715–1718, 2002.
- Aldras AM, Orenstein JM, Kotler DP, et al: Detection of Microsporidia by indirect immunofluorescence antibody test using polyclonal and monoclonal antibodies. *J Clin Microbiol* 32:608–612, 1994.
- Enriquez FJ, Ditrich O, Palting JD, Smith K: Simple diagnosis of *Encephalitozoon* sp. microsporidial infections by using a panspecific antiexospore monoclonal antibody. *J Clin Microbiol* 35:724–729, 1997.
- Boot R, Hansen AK, Hansen CK, et al: Comparison of assays for antibodies to *Encephalitozoon cuniculi* in rabbits. *Lab Anim* 34:281–289, 2000.
- Beckwith C, Peterson N, Liu JJ, Shaddock JA: Dot enzyme-linked immunosorbent assay (dot ELISA) for antibodies to *Encephalitozoon cuniculi*. *Lab Anim Sci* 38:573–576, 1988.

29. Didier ES, Orenstein JM, Aldras A, et al: Comparison of three staining methods for detecting Microsporidia in fluids. *J Clin Microbiol* 33:3138–3145, 1995.
30. Garcia LS: Laboratory identification of the Microsporidia. *J Clin Microbiol* 40:1892–1901, 2002.
31. del Aguila C, Croppo GP, Moura H, et al: Ultrastructure, immunofluorescence, western blot, and PCR analysis of eight isolates of *Encephalitozoon (Septata) intestinalis* established in culture from sputum and urine samples and duodenal aspirates of five patients with AIDS. *J Clin Microbiol* 36:1201–1208, 1998.
32. Chu P, West AB: *Encephalitozoon (Septata) intestinalis*: Cytologic, histologic, and electron microscopic features of a systemic intestinal pathogen. *Am J Clin Pathol* 106:606–614, 1996.
33. Gross U: Treatment of microsporidiosis including albendazole. *Parasitol Res* 90(suppl 1):S14–S18, 2003.
34. Bacchi CJ, Weiss LM: Chemotherapy of microsporidiosis: Benzimidazoles, fumagillin and polyamine analogues, in Lindsay DS, Weiss LM (eds): *World Class Parasites, vol 9: Opportunistic infections: Toxoplasma, Sarcocystis, and Microsporidia*. Norwell, Kluwer Academic Publishers, 2004, pp 159–188.
35. Stiles J, Didier E, Ritchie B, et al: *Encephalitozoon cuniculi* in the lens of a rabbit with phacoclastic uveitis: Confirmation and treatment. *Vet Ophthalmol* 7:233–238, 1997.
36. Suter C, Muller-Doblies UU, Hatt JM, Deplazes P: Prevention and treatment of *Encephalitozoon cuniculi* infection in rabbits with fenbendazole. *Vet Rec* 148:478–480, 2001.
37. Horvath M, Leng L, Stefkovic M, et al: Lethal encephalitozoonosis in cyclophosphamide-treated rabbits. *Acta Vet Hung* 47:85–93, 1999.
38. Halánová M, Cisláková L, Valencáková A, et al: Serological screening of occurrence of antibodies to *Encephalitozoon cuniculi* in humans and animals in Eastern Slovakia. *Ann Agric Environ Med* 10:117–120, 2003.
39. Deplazes P, Mathis A, Muller C, Weber R: Molecular epidemiology of *Encephalitozoon cuniculi* and first detection of *Enterocytozoon bieneusi* in faecal samples of pigs. *J Eukaryot Microbiol* 43:93S, 1996.
40. Lores B, del Aguila C, Arias C: *Enterocytozoon bieneusi* (Microsporidia) in faecal samples from domestic animals from Galicia, Spain. *Mem Inst Oswaldo Cruz* 97:941–945, 2002.

## ARTICLE #1 CE TEST



This article qualifies for 2 contact hours of continuing education credit from the Auburn University College of Veterinary Medicine. Paid subscribers may purchase individual CE tests or sign up for our annual CE program. Those who wish to apply this credit to fulfill state relicensure requirements should consult their respective state authorities regarding the applicability of this program. To participate, fill out the test form inserted at the end of this issue or take CE tests online and get real-time scores at [CompendiumVet.com](http://CompendiumVet.com).

### 1. Transmission of *E. cuniculi* infection in rabbits occurs by

- a. ingestion of spores.
- b. inhalation of spores.
- c. transplacental transmission.
- d. all of the above

### 2. Which is the major proliferative stage of Microsporidia?

- a. spore
- b. meront
- c. sporont
- d. sporoblast

### 3. Antibodies to *E. cuniculi* infection are usually detectable by \_\_\_\_\_ weeks after infection, and spores are shed in urine by \_\_\_\_\_ days after infection.

- a. 4; 21
- b. 4; 35
- c. 5; 21
- d. 5; 35

### 4. The \_\_\_\_\_ is(are) not commonly infected by *E. cuniculi*.

- a. brain
- b. liver
- c. kidneys
- d. eyes

### 5. The infectious dose required for initiating *E. cuniculi* infection in rabbits is \_\_\_\_\_ spores.

- a. 12
- b. 23
- c. 46
- d. 64

### 6. Which clinical sign is not typically observed during the acute stage of infection in rabbits?

- a. head tilt
- b. ataxia
- c. vestibular disease
- d. aggressive behavior

### 7. Which pathogen(s) should be included in the differential diagnosis of *E. cuniculi* infection?

- a. *T. gondii*
- b. *P. multocida*
- c. *Eimeria stiedae*
- d. a and b

### 8. What is the gold standard for diagnosis of *E. cuniculi* infection?

- a. Gram's stain
- b. IFA testing
- c. ELISA
- d. PCR testing

### 9. Spores of *E. cuniculi* develop

- a. in direct contact with the host-cell cytoplasm, together with other spores.
- b. in direct contact with the host-cell cytoplasm, isolated from one another.
- c. within a PV, together with other spores.
- d. within a PV, isolated from one another.

### 10. Which drug is approved for treating *E. cuniculi* infection in rabbits?

- a. albendazole
- b. fenbendazole
- c. dexamethasone
- d. none of the above