

## Virological and histological re-evaluation of Labrea hepatitis

Raymundo Paraná,<sup>1</sup> Zilton Andrade,<sup>2</sup> Luiz Antônio R de Freitas,<sup>2</sup> Aluizio Prata,<sup>3</sup> Alan Kay,<sup>4</sup> João Barberino Santos<sup>5</sup>

<sup>1</sup> Gastro-Hepatology Unit – Federal University of Bahia, Brazil. - <sup>2</sup> CPqGM-Oswaldo Cruz Foundation, Bahia, Brazil. - <sup>3</sup> Tropical Medicine Unit, Federal University of Uberaba, Brazil. - <sup>4</sup> INSERM Unité 871, Lyon, France. - <sup>5</sup> Tropical Medicine Unit, University of Brasilia, Brazil.

Acta Gastroenterol Latinoam 2008;38:284-290

### Summary

**Background:** a peculiar form of fulminant hepatitis known as Labrea hepatitis, probably related to hepatitis B and D, has been reported in Brazilian Amazon as early as the 1930s. **Methods:** we reviewed the post-mortem liver biopsies of 9 patients with Labrea Hepatitis. Immunostaining for HBV and HDV antigens were performed. **Results:** we found several important characteristics in the liver tissues: 1) moderate hepatocellular necro-inflammation, 2) hepatocellular ballooning, 3) ballooned hepatocytes with fat droplets surrounding the nucleus (morula-like cells or spongicytes) 4) mild to moderate necrosis and/or mild porto-septal fibrosis. Hepatitis B surface antigen (HBsAg) was identified in 7 of the 9 cases and was concentrated in the Morula-like cells. Hepatitis B core antigen (HBcAg) was present in 5 cases, mostly in the hepatocyte's nucleous. The hepatitis D virus antigen (HDV Ag) was present in 5 cases, mostly in the cytoplasm and concentrated in the Morula-like cells. **Conclusion:** labrea hepatitis is a fatal disease mostly affecting isolated communities in the Amazon. Evidence implicates HBV and HDV in the etiology of this disease, but this hypothesis needs to be confirmed with genotyping and sequencing research on HBV DNA and HDV RNA extracted from the liver and sera of these patients.

**Key words:** labrea Hepatitis, Fulminant Hepatitis, Hepatitis D, Hepatitis B, Amazonia.

### Reevaluación viológica e histológica de la hepatitis de Labrea

#### Resumen

**Introducción:** la hepatitis B y D son endémicas en América del Sur. En esta región fueron descritas for-

mas fulminantes de hepatitis relacionadas con la co-infección HVB-HVD. En Brasil es llamada Hepatitis de Labrea. **Métodos:** nuestro grupo estudió en forma retrospectiva 9 casos de Hepatitis de Labrea submetidos a necropsia durante los años 70. En el estudio histológico del hígado fueron realizadas inmunotinciones para el HVB y el HVD. **Resultados:** las peculiaridades más importantes encontradas en el tejido hepático fueron: 1) solamente necro-inflamación hepatocelular moderada; 2) balonización hepatocelular; 3) presencia de hepatocitos balonizados conteniendo gotas de grasas rodeando el núcleo (células similares a mórulas o espongiocitos) y 4) leve a moderada necrosis y leve fibrosis porto septal. El antígeno de superficie (HBs Ag) estuvo presente en 7 de los 9 casos. El HBs Ag estuvo fuertemente concentrado en las células similares a mórula. El HBc Ag estuvo presente en 5 de 9 casos, la mayoría en el núcleo de los hepatocitos. El HDV Ag estuvo presente en 5 casos, la mayoría en el citoplasma, concentrado también en las células similares a mórula. **Conclusión:** la hepatitis de labrea es una enfermedad mortal que usualmente compromete familias de comunidades aisladas del Amazonas. Existen evidencias asociando cepas peculiares del HVB y HVD en la etiología de esta enfermedad, datos que precisan ser confirmados. La extracción del DNA y el RNA del HVD del hígado, así como la obtención del suero de estos pacientes para genotipificar y secuenciar estos virus será necesario para resolver este enigma. | **Palabras claves:** hepatitis de Labrea, hepatitis fulminante, hepatitis D, hepatitis B, Amazonia.

In South America, a peculiar form of fulminant hepatitis known as Labrea hepatitis, or Labrea black fever, has been described since the 1930s.<sup>1,2</sup> To date, outbreaks of the hepatitis with clinical and histopathological features similar to the first documented cases continue to cause deaths in the Amazon regions, mainly among Amerindians.<sup>3</sup>

**Correspondencia:** Raymundo Paraná  
Serviço de Hepatologia, Av. Juacy Magalhães Jr 2096 sala 510  
Salvador-BA 41920000. Brasil.  
E-mail: unif@svm.com.br

The histopathology of this rare disease has been studied only since the 1970s after the work of Barberino Santos. The separate characterizations of Labrea Hepatitis were consolidated because most cases were reported in the county of Labrea, Alto Purus, in the state of Amazonia. A minority of Labrea hepatitis cases were reported in other areas of the Brazilian Amazon.<sup>4,5</sup>

Labrea hepatitis has been described epidemiologically as a unique form of fulminant hepatitis, mainly present in the western Amazon regions. Outbreaks of the disease occur periodically among isolated Amerindian populations and sometimes in non-Amerindians as well. The hallmark of this disease is the presence of ballooned hepatocytes with cytoplasm filled with fat droplets surrounding the nuclei.<sup>6</sup>

Building on Barberino Santos' research, we reexamined 9 cases of Labrea hepatitis in light of new reports on similar diseases in other South American countries and using immunostaining techniques for HBV and HDV.

**Material and methods**

We reviewed the histology of 9 cases of Labrea hepatitis diagnosed in the 1970s. Liver tissue samples from these patients had been fixed in 10% formalin solution and stored in ambience temperature until they were examined in this study.

Liver samples were embedded in paraffin and stained with hematoxylin & eosin (H&E), reticulin, picrosirius red, and periodic acid-Schiff stain.

Because of the stability of immunostaining for HBV and HDV markers in liver tissues collected as much as 5 decades before, we tested for AgHBs as well as AgHBc using the indirect immunoperoxidase technique with alkaline phosphatase as recommended by the Brazilian Pathology Society.<sup>7,8</sup>

**Tabla 1.** Demographics data of nine cases of labrea fever.

Case Nº	Identification	GENDER	Age (years)
1	MNA	female	11
2	APL	male	11
3	PRS	male	4
4	BIP	male	16
5	MFS	female	10
6	IQF	female	8
7	MSS	male	2
8	LFN	male	9
9	ARS	male	11

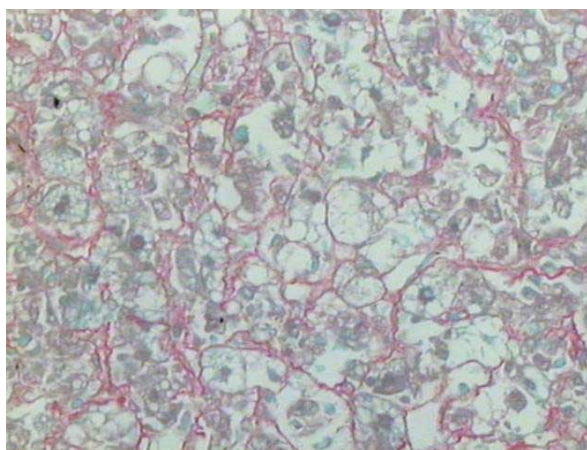
The HDV antigen was measured with direct fluorescence using a monoclonal anti-HDV antibody as described before.<sup>9</sup>

**Results**

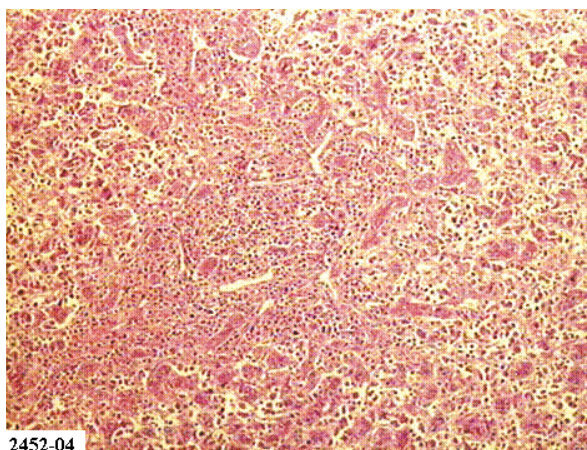
**Clinical and histological features**

All 9 cases presented similar clinical and histopathological features with a range of intensity. Remarkable characteristics included: 1) moderate hepatocellular necro-inflammation, 2) hepatocellular ballooning, 3) fat droplets surrounding the nuclei in ballooned hepatocytes (morula-like cells or spongiocytes), 4) mild to moderate necrosis, and 5) mild porto-septal fibrosis. (Figures 1 and 2).

**Figure 1.** Hematoxylin & eosin and picrosirius red showing ballooned hepatocytes with morula-like cells, little inflammation, and moderate fibeosis (40x).



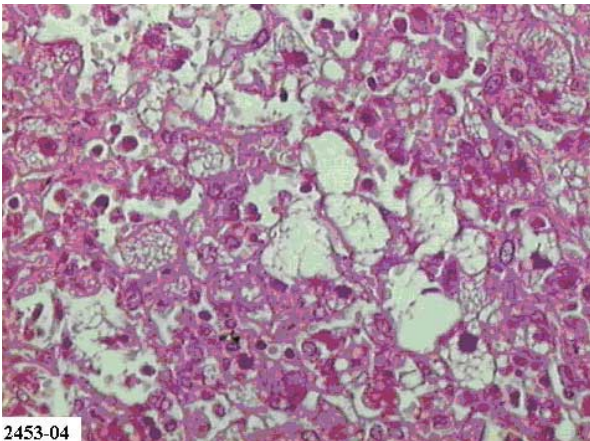
**Figure 2.** H&E staining showing inflammation and parenchima detrabeculation.



2452-04

Other histological features were spot coagulation necrosis, lobular inflammation, and parenchyma detrabeculation, which were similar to histological features described in eclampsia. (Figure 3) In one

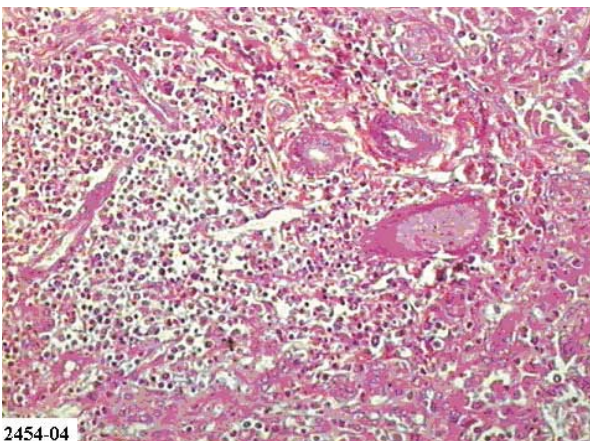
**Figure 3.** *H&E staining showing abundant morula-like cells (40x).*



case, the features of ballooning, apoptosis, and cholestasis were especially pronounced.

In several cases, periportal necrosis was more pronounced, and portal and septal fibrosis were present. (Figure 4).

**Figure 4.** *H&E staining showing portal inflammation with mild peace-meal necrosis (40x).*



In 2 cases, the clinical pictures were compatible with a chronic hepatitis with varying degrees of portal and parenchyma inflammation; however, morula-like cells were always identified.

All 9 patients were under 20 years old and lived in Labrea City or nearby areas. According to the medical records, they presented an icterohemorrhagic fever followed by encephalopathy and death. All had

gastrointestinal bleeding. The patients died within 1 to 7 days of hospitalization. The necropsy showed cerebral edema and hemorrhage in the gastrointestinal tract and other organs.

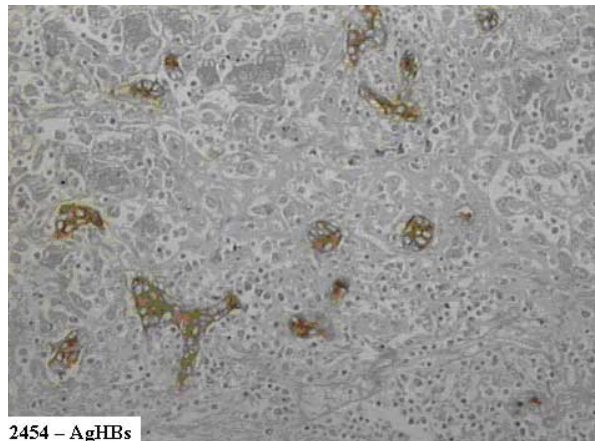
#### **Tissue HBV and HDV markers**

HBsAg was identified in 7 of the 9 cases. The HBsAg was dispersed primarily in the hepatic parenchyma, but also concentrated in the Morula-like cells. (Figure 5).

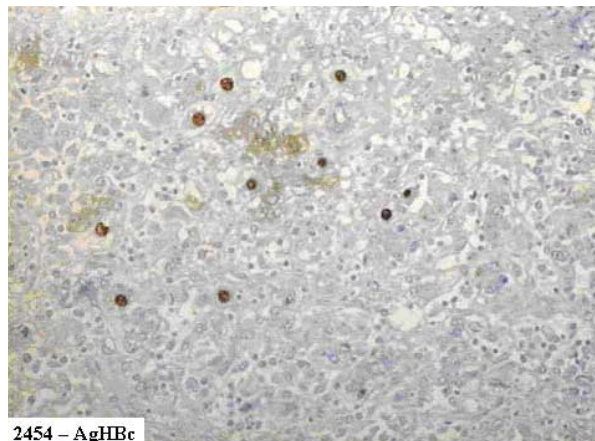
The HBcAg was present in 5 of the 9 cases and was seen primarily in the hepatocyte's nucleus, but a mild stain in cytoplasm was observed in two cases. (Figure 6).

The HDV Ag was present in 5 cases, mostly in the cytoplasm of the hepatocytes and, like the other antigens, was also concentrated in the Morula-like cells. (Figure 7).

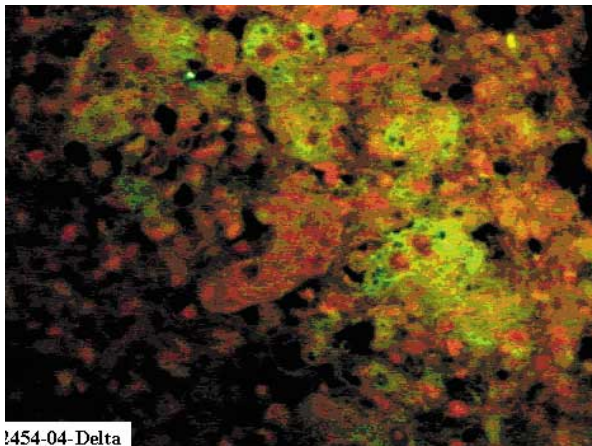
**Figure 5.** *Immunoperoxidase for HBsAg showing antigen to be more concentrated in morula-like cells (20x).*



**Figure 6.** *Immunoperoxidase staining showing HBcAg in nucleus and cytoplasm of hepatocytes (20x).*

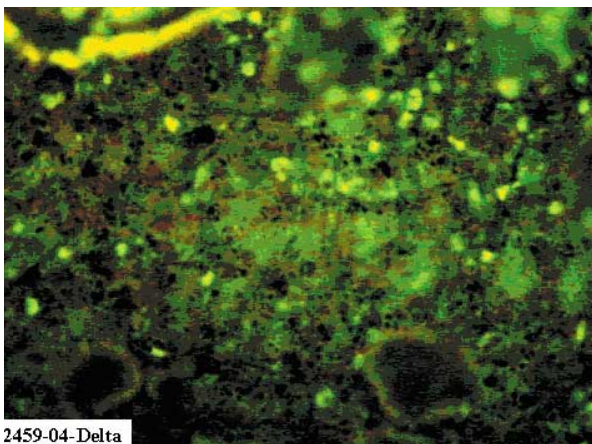


**Figure 7.** Immunofluorescence showing HDV Ag displayed in cytoplasm of hepatocytes.



1454-04-Delta

**Figure 8.** Immunofluorescence showing abundant HDV in cytoplasm and nucleus of hepatocytes.



2459-04-Delta

Laboratory Test Results

Few laboratory tests were performed because of the rapid deterioration to death. Case 3 was the only case with more complete laboratory.

- Case 1.  
Blood examination for malaria parasites: Negative  
Sediment urinary examination: presence of hematiás
- Case 2.  
Blood examination for malaria parasites: Negative
- Case 3.  
Blood examination for malaria parasites: Negative  
Sickle cell test: Negative  
Hematocrit: 30%  
Hemoglobin: 9g/dl  
Leucocytes: 3 800/mm<sup>3</sup>; myelocytes 4%; segmented neutrophils 54%; monocytes 0%; lymphocytes 36%; eosinophils 6%; basophils 0%.  
Sedimentation rate: 12mm  
Urea: 15mg%  
Bilirubin: 0,5mg%; direct: 0,2mg%; indirect: 0,3mg%  
Protein: 3,0g%; albumin: 1,5g%; globulin: 1,5g%  
Urinary examination: density 1000; glucose ++; proteins +; presence of pigments and biliary salts; piocytes 3-4/field; hematiás: 3-4/field.
- Case 5.  
Blood examination for malaria parasites: Negative  
Hematocrit: 30%  
Hemoglobin: 9,5g/dl  
Leucocytes: 9 100/mm<sup>3</sup>; myelocytes 74%; neutrophils 38%; monocytes 4%; lymphocytes 46%; eosinophils 3%; basophils 2%.  
Sedimentation rate: 8mm  
Proteins: 4,6g%; albumin: 2,4g%; globulin: 2,2g%  
Urine examination: density 1015; absence of pigments and biliary salts; piocytes 6-8/field; urate crystals.
- Case 9.  
Hemoglobin: 9,5g/dl  
Leucocytes: 18 000/mm<sup>3</sup>;  
Sedimentation rate: 100mm

No laboratory tests were performed for cases 4, 6, 7, or 8.

**Principals signs and symptoms in nine cases of Labrea hepatitis**

Cases	Asthenia	Anorexia	Muscle Pain	Abdominal Pain	Fever	Headache	Vomits	Jaundice	Adenomegaly	Hepatomegaly	Black Vomit	Melena	Encephalopathy	Coma
1	+	+	+	+	+	+	+	+	-	-	+	-	+	+
2	+	+	+	+	+	+	+	+	-	-	+	-	+	+
3	+	?	+	+	+	+	+	+	+	+	+	+	+	+
4	+	?	+	+	+	+	+	+	-	-	-	-	+	+
5	+	+	?	+	+	+	+	+	-	-	-	-	+	+
6	+	+	-	+	+	-	+	+	+	+	+	-	+	+
7	+	+	+	+	+	+	+	+	-	+	+	-	+	+
8	?	+	+	+	+	+	+	+	+	-	-	-	+	+
9	+	+	?	+	+	+	+	+	-	+	-	-	+	+

Legend: + positive data; -negative data; ? no recorded

**Discussion**

The clinical characteristics of Labrea hepatitis, including the young age of patients, familial clustering, and rapid fatality have been well documented

since the disease was first described. In the nine patients we studied, all died within a few days and most presented signs and symptoms consistent with hemorrhagic fever, although hepatic encephalo-

pathy was evident.

The etiology of the disease has not been well established, but studies have implicated the hepatitis B and D viruses. From the 1970s to 1990s, both viruses were found to be involved in fulminant hepatitis in many countries, but severe hepatitis D cases have clinical and histopathological characteristics similar to fulminant hepatitis caused by other hepatotropic viruses.<sup>10-12</sup> The unique epidemiological, clinical, and histopathological features separate Lebrea hepatitis from other fulminant hepatitis related to hepatotropic virus infections.<sup>13,14</sup>

Lebrea hepatitis was firstly reported in Brazilian Amazon during the 1930s by Costa, but its histopathology was first studied in depth in the 1970s by Barberino Santos, who lived in this area, treated many patients, performed autopsies, and collected tissue samples from various organs. The liver samples he collected were studied by expert pathologists who described the histopathological features of the disease.

Although the disease was first reported and described in Brazil, similar diseases were reported in Ecuador, Peru, Colombia, and Venezuela, and those cases were also found to be related to HBV and HDV infections.<sup>15-19</sup>

In recent years, researchers have observed that most cases had positive serology to HBV and/or HDV infections.<sup>20,21</sup> Despite strong argument in favor of HDV superinfection in HBV carriers as the etiology of the disease, some cases had no serological markers for these viruses.<sup>22-24</sup>

In one study, the serum sample from one patient who died from Labrea hepatitis but had no serologic markers for HBV and HDV, induced a severe HDV hepatitis when it was inoculated in a Woodchuck carrying the Woodchuck hepatitis virus. (Paraná and Bensabath, unpublished data). This data strongly argue in favor of an HBV/HDV etiology for Labrea hepatitis.

Labrea hepatitis causes a 100% mortality within a few days after the patient becomes symptomatic. It is therefore possible that the patient may not have enough time to express serum virological markers for co-infection. In cases of superinfection, which is common, HBV repression by HDV may be responsible for the false-negative serology in some patients. In addition, tissue samples were usually collected post-mortem and used for immunostaining after a long period of storage. We cannot rule out the possibility that technical problems in immunostaining

due to long-term liver tissue preservation resulted in negative antigen findings. Autolysis was seen in 5 of the 9 liver samples examined in this study.<sup>25,26</sup>

In the 1980s, cases similar to Lebrea hepatitis were reported in Central African Republic. French researchers reported the same etiological association with HBV/HDV.<sup>27</sup> The histological features of these African cases of fulminant hepatitis were also similar to Lebrea hepatitis.<sup>27-29</sup>

Among the histopathological features of Lebrea hepatitis, morula-like cells are considered the hallmark of this mysterious disease. These cells are so named because of their morphology. Some researchers have called them spongiocytes.

We observed only mild to moderate hepatocellular necro-inflammation, which differed from classic fulminant viral hepatitis.<sup>30,31</sup> Some of the liver injuries appeared inconsistent with the clinical severity of the disease. Some cases presented mild to moderate necrosis and a varying degree of portal fibrosis which could be the result of having been a HBV carrier before.

Similar aspects were also described in experimental models of Woodchucks carrying the Woodchuck hepatitis virus. When inoculated with sera from patients of a fulminant hepatitis in Central African Republic, the animals developed a similar disease as the humans and all died in a few days. In contrast, the control animals inoculated with sera from a European patient who died from the classic fulminant hepatitis D developed acute hepatitis D but survived. The presentation of the hepatocytes differed between animals that had received the African and the European inocula.<sup>32</sup>

The histopathology of Lebrea hepatitis needs to be clarified. Morula-like cells are observed in other diseases such as Raye's syndrome, eclampsia and acute liver failure in pregnancy, and its cause is related to mitochondrial damage. However, ballooning is the most pronounced in Labrea hepatitis. It is possible that mitochondrial damage is induced by the virus or an unknown toxic co-factor, but there are no data so far to clarify the observations.

There is additional evidence to support a possible cytopathic effect of specific strains of HBV and HDV. Isolates from infected animals was shown to carry mutations in the HDV genome.<sup>33</sup> A more pathogenic mutant Delta strain cannot be ruled out.

Other authors have suggested that the Genotype III of HDV is more cytopathic than other HDV genotypes, especially if the patient is a superinfected

HBV genotype F carrier. It was also reported that the Genotype III HDV is prevalent in Brazilian Amazon.<sup>34,35</sup>

Furthermore, steatosis has been associated with a direct cytopathic effect of other hepatotropic viruses such as Hepatitis C virus (HCV) genotype 3. High HCV viral load is related with more pronounced liver steatosis without other risk factors for fatty liver disease.<sup>36</sup>

Another characteristic of Labrea hepatitis is the abundant expression of HBsAg and HDV Ag in the cytoplasm of the morula-like cells, which is rare in humans.<sup>37</sup> Direct toxic hepatocyte damage is a well known phenomenon in patients HBV or HCV after liver transplantation, but in those cases steatosis is not usually present.<sup>38</sup>

Generally, HDV superinfection has been shown to strongly reduce HBV replication, and thus a display of HBsAg or HBcAg in hepatocyte nucleus and cytoplasm would not be expected in HDV superinfection.<sup>39</sup> However, in our study, the HDV superinfection did not appear to have suppressed HBV.

In conclusion, Labrea hepatitis is a fatal disease that usually affects those living in isolated communities. There is evidence to implicate special HBV and HDV strains in the etiology of this disease, but this hypothesis needs to be confirmed. HBV-DNA and HDV-RNA extracted from liver and sera of these patients for genotyping and sequencing will help solve this puzzle.

## References

- Bauer JH, Kerr JA. Una enfermedad pirética confundida con la Fiebre Amarilla en la costa del Atlántico de Colombia. *Bol Oficina Sanit Panam* 1933;12:696-715.
- Costa EA. Febre Negra do Rio Purus. Algumas Observações acerca de um surto na "Praia do Inferno" Boca do Acre - Amazonas. *Gaz Med Brachia* 1970;70:148-175.
- Brasil. Ministério da Saúde/ Gerência de Doenças Emergentes e Re-emergentes. Vigilância das Síndromes Febris Ictéricas e/ ou Hemorrágicas Agudas: A Experiência Brasileira. Relatório de atividades apresentado a OPAS, 2002.
- Santos JB. Febre negra na região de Lábrea (AM): Estudo clínico, epidemiológico e histopatológico. *Rev Pat Trop* 1983;2:53-143.
- Dias LB. Hepatites na Amazônia. *Rev Pa Med* 1981;3:7-21.
- Andrade ZA, Santos JB, Prata A, Dourado H. Histopatologia da hepatite de Lábrea. *Rev Soc Bras Med Trop* 1983; 16:31-40.
- Alves VAF, Bacchi CE, Vassalo J. Manual de imuno-histoquímica. São Paulo: Sociedade Brasileira de Patologia; 1999.
- Simonetti SRR, Schatzmayr HG, Barth OM, Simonetti JP. Detection of hepatitis B Virus antigens in paraffin-embedded liver specimens from Amazon region, Brazil. *Mem Inst Oswaldo Cruz* 2002;97:105-107.
- Rizetto M, Canese MG, Aricò S, Crivelli O, Trepo C, Bonino F, Verme G. Immunofluorescence detection of new antigen-antibody system (d/anti-d) associated to Hepatitis B virus in liver and in serum of HBsAg carriers. *Gut* 1977; 18:997-1003.
- Govindarajan S, Cock QM, Peters RL. Morphologic and immunohistochemical features of fulminant delta hepatitis. *Hum Pathol* 1985;16:262-267.
- Masada CT, Shaw BW Jr, Zetterman RK, Kaufman SS, Markin RS. Fulminant hepatic failure with massive necrosis as a result of hepatitis A infection. *J Clin Gastroenterol* 1993;17:158-162.
- Acharya SK, Dasarathy S, Kumer TL, Sushma S, Prasanna KSU, Tandon A, Sreenivas V, Nijhawan S, Panda SK, Nanda SK, Irshad M, Joshi YK, Duttagupta S, Tandon RK, Tandon BM. Fulminant hepatitis in a tropical population: clinical course, cause, and early predictors of outcome. *Hepatology* 1996;23:1448-1455.
- Dias LB, Coura JR. Hepatite de Lábrea. Estudo de revisão em viscerotomias hepáticas dos anos de 1934 a 1940. *Rev Inst Med Trop São Paulo* 1985;27:242-248.
- Dias LB, Moraes MAP. Hepatite de Lábrea. *Rev Inst Med Trop São Paulo* 1973.
- Hadler SC, De Monzon M, Ponzetto A, Anzola E, Rivero D, Mondolfi A, Bracho A, Francis DP, Gerber MA, Thung S, Gerin J, Maynard JE, Popper H, Purcell RH. Delta virus infection and severe hepatitis, an endemic in Yucpa Indians of Venezuela. *Ann Int Med* 1984;100:339-344.
- Buitrago B, Popper H, Hadler SC, Thung SN, Gerber MA, Purcell RH, Maynard JE. Specific histologic features of Santa Marta hepatitis: A severe form of hepatitis -virus infection in Northern South America. *Hepatology* 1986; 6:1285-1291.
- Manock SR, Kelley PM, Hyams KC, Douce R, Smalligan RD, Watts DM, Sharp TW, Casey JL, Gerin JL, Engle R, Alava-Alprecht A, Martinez CM, Bravo NB, Guevara AG, Russell KL, Mendoza W, and Vimos C. An outbreak of fulminant hepatitis delta in the Waorani, an indigenous people of the Amazon basin of Ecuador. *Am J Trop Med Hyg* 2000;63:209-213.
- Le Pelletier L, Lecant A, Destombes P, Serie CH. La fièvre noire amazonienne en Guyane Française. *Arch Inst Pasteur de la Guyane Française et de L'Inini* 1968;21:79-82.
- Ljunggren KE, Patarroyo ME, Engle R, Purcell RH, Gerin JL. Viral hepatitis in Colombia: A study of the "hepatitis of the Sierra Nevada de Santa Marta". *Hepatology* 1985;5: 299-304.
- Bensabath G, Hadler SC, Soares MC, Fields H, Dias LB, Popper H, Maynard JE. Hepatitis delta virus infection and Labrea hepatitis. Prevalence and role of fulminant hepatitis in the Amazon Basin. *JAMA* 1987;258:479-483.
- Fonseca JC. [Hepatitis D]. *Rev Soc Bras Med Trop* 2002; 35:181-190.

22. Fonseca JCF, Ferreira LCL, Brasil LML, Castilho MC, Moss R, Barone M. Fulminant Labrea hepatitis. The role of hepatitis A (HAV), B (HBV), C (HCV), and D (HDV) infection (Preliminary report). *Rev Inst Med Trop Sao Paulo* 1992;34:609-612.
23. Pereira FEL, Musso C, Lucas EA. Labrea-like hepatitis in Vitória, Espírito Santo State, Brazil: report of a case. *Rev Soc Bras Med Trop* 1993;26:237.
24. Andrade ZA, Barbosa Junior AA. Hepatite de Lábrea em Salvador, BA? (Apresentação de um possível caso). *Mem Inst Oswaldo Cruz* 1983;78:491-496.
25. Fonseca JCF, Ferreira LCL, Guerra ALPS, Passos LM, Simonetti JP. Hepatite fulminante e febre negra de lábrea: Estudo de cinco casos procedentes de Codajás, Amazonas, Brasil. *Rev Soc Bras Med Trop* 1983;16:144-147.
26. Fonseca JCF, Gayotto LCC, Ferreira LCL, Araújo JR, Alecrim WD, Santos RTM, Simonetti JP, Alves VAF. Labrea hepatitis -Hepatitis B and delta antigen expression in liver tissue: report of three Autopsy cases (preliminary report). *Rev Inst Med Trop São Paulo* 1985;27:224-227.
27. Andrade ZA, Lesbordes JL, Ravisse P, Parana R, Prata A, Barberino JS, and Trepo C. Fulminant hepatitis with microvesicular steatosis (a histologic comparison of cases occurring in Brazil - Labrea hepatitis - and central Africa - Bangui hepatitis). *Rev Soc Bras Med Trop* 1992;25:155-160.
28. Lesbordes JL, Ravisse P, Georges AJ, Chevallier P, Pichoud C, Vitvitski L and Trepo C. Studies on the role of HDV in an outbreak of fulminant hepatitis in Bangui (Central African Republic). *Prog Clin Biol Res* 1987;234:451-459.
29. Lesbordes JL, Ravisse P, Georges AJ, Beuzit Y, Ave P, Enamra D, Meunier DM, Georges MC, Gonzalez JP, Chevalier P. Role of delta viruses in fulminating hepatitis in Central Africa Article in French. *Ann Interne Med (Paris)* 1987; 138:199-201.
30. Craig JR, Govindarajan S, Decock KM. Delta viral hepatitis. Histopathology and course. *Pathol Annu* 1986;21:1-21.
31. De Paola D, Strano AJ, Hopps HC. Labrea hepatitis (Black Fever). A problem in geographic pathology. *Inter Pathol Bul Inter Acad Pathology* 1968;9:43-49.
32. Parana R, Gerard F, Lesbordes JL, Pichoud C, Vitvitski L, Lyra LG, Trepo C. Serial transmission of spongiocytic hepatitis to woodchucks (possible association with a specific delta strain). *J Hepatol* 1995;22:468-473.
33. Langon T, Fillon C, Pichoud C, Hantz O, Trepo C and Kay A. Analysis of a Hepatitis delta Virus Isolate from the Central African Republic. *Res Virol* 1998;149:171-185.
34. Parana R, Kay A, Molinet F, Viana S, Silva LK, Salcedo JM, Tavares-Neto J, Lobato C, Rios-Leite M, Matteoni L, D'Oliveira A Jr, Taui P, Trepo C. HDV genotypes in the Western Brazilian Amazon region. A preliminary report. *Am J Trop Med Hyg* 2006;75:475-479.
35. Casey JL, Niro GA, Engle RE, Vega A, Gomez H, McCarthy M, Watts DM, Hyams KC, and Gerin JL. Hepatitis B virus (HBV)/hepatitis D virus (HDV) coinfection in outbreaks of acute hepatitis in the Peruvian Amazon basin: the roles of HDV genotype III and HBV genotype F. *J Infect Dis* 1996;174:920-926.
36. T Asselah, L Rubbia-Brandt, P Marcellin and F Negro. Steatosis in chronic hepatitis c: why does it really matter? *Gut* 2006;55:123-130.
37. Rizzetto M. The delta agent. *Hepatology* 1983;3:729-737.
38. Fonseca JCF, Gayotto LCC, Ferreira LCL, Araújo JR, Alecrim WD, Santos RTM, Simonetti JP, Alves VAF. Labrea hepatitis -Hepatitis B and delta antigen expression in liver tissue: report of three Autopsy cases (preliminary report). *Rev Inst Med Trop São Paulo* 1985;27:224-227.
39. Lefkowitz JH Hepatobiliary pathology. *Curr Opin Gastroenterol* 2002;18:290-298.
40. Krajden S, Bishai F, Huang S, Ronald A, Harris F, Kempston J, Anderson J, Keston S. Clinicopathological study of fulminant hepatitis: confection with hepatitis B virus and delta agent. *CMAJ* 1986;135(Suppl. 11):1282-1285.