



What's new in *Malassezia* infections?

Ariya Chindamporn

Chulalongkorn University

MMTN-Taipei

Nov 18th 2018; 8:35 am. – 9:05 am.



Malassezia spp.

Family: Malasseziaceae

Kingdom: Fungi

Subkingdom: Karya

Phylum: Basidiomycota

Class: Exobasidiomycetes



Kwonchun J., et al., 2012

Malassezia spp.

- Lipophilic unipolar budding yeast
- Normal flora (skin microbiota) / immunocompromised hosts
- Involved in a variety of skin disorders
 - Hypo/hyper pigment: Pityriasis versicolor (PV)
 - Seborrheic dermatitis/dandruff (SD/D)
 - Pityrosporum folliculitis (PF)
 - Atopic dermatitis (AD), etc
- Found on surfaces rich in sebaceous glands *ie.* scalp, trunk, back, breast etc.
 - Unable to synthesize lipids.
 - In enucleated keratocytes of stratum corneum in skin
 - In follicle infundibulum, exposed to sebum lipids: triglycerides, fatty acids, etc.
- Factors related to infection & colonization:
 - Temperature
 - Humidity
 - Cutaneous microenvironment
 - Host defense mechanisms

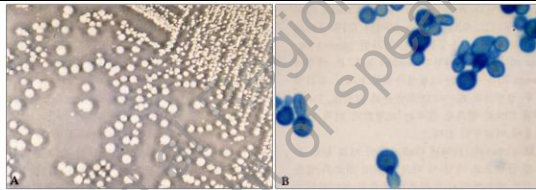
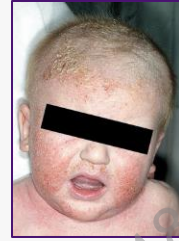

Fig. 2. *Malassezia globosa*. (A) Medium-sized, light cream color, friable and crevated flat colonies with a pointed button center (Leeming and Notman medium, 34°C, 14 days). (B) Spherical, circular cells with buds on a narrow base (Parker Quinck-KOH stain, $\times 1,000$). Data from the article of Ahn (Korean J Med Mycol 1998;3:81-88)⁷.

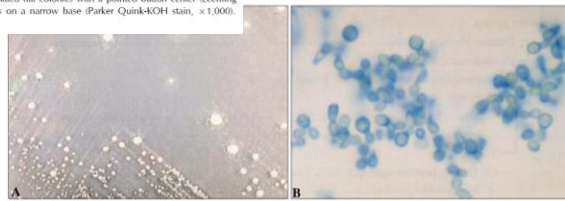


Fig. 3. *Malassezia nympha*. (A) Small-sized, circular, umbonate, entire, dull colonies (Leeming and Notman medium, 34°C, 14 days). (B) Small, spherical or oval cells with buds on a relatively narrow base (Parker Quinck-KOH stain, $\times 1,000$). Data from the article of Ahn (Korean J Med Mycol 1998;3:81-88)⁷.

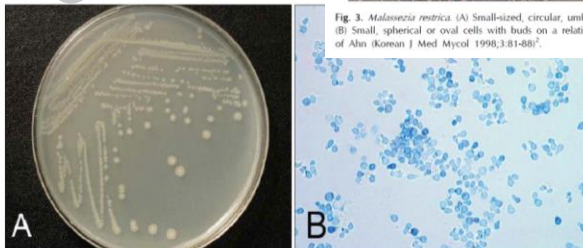
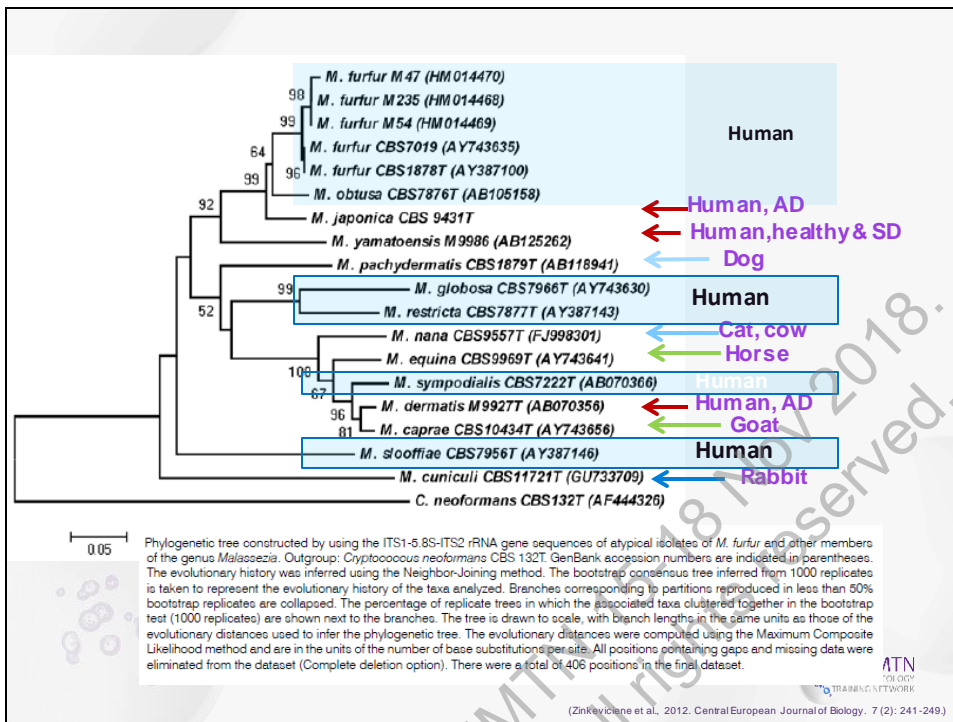


Fig. 4. *Malassezia dermatitis*. (A) Large-sized, circular, smooth colonies (Leeming and Notman medium, 34°C, 14 days). (B) Spherical, oval, or ellipsoidal vegetative cells with monopolar budding (Parker Quinck-KOH stain, $\times 1,000$). Data from the article of Lim et al. (Korean J Dermatol 2007;45:1020-1030)¹².

Ann Dermatol Vol. 27, No. 6, 2015



Malassezia spp.

Table 1

Distribution of *Malassezia* species

Species	Primary distribution	Disease associations
Human associated		
<i>M. globosa</i>	Skin of all humans, face, scalp, back.	Dandruff/seborrheic dermatitis, Pityriasis versicolor
<i>M. restricta</i>	Skin of all humans, ear, face, scalp. Domestic cats.	Dandruff/seborrheic dermatitis, Pityriasis versicolor
<i>M. sympodialis</i>	Skin of all humans, face, scalp.	Atopic eczema
<i>M. furfur</i>	Unclear. Human skin via culture, less in molecular studies.	Neonatal invasive/septic infections.
<i>M. dermatis</i>	Only species found in blood and urine. Rare, human skin.	Mostly unknown, reported changes in atopic dermatitis.
<i>M. slooffiae</i>	Rare, human skin. Occasionally animals.	Unknown.
<i>M. arunalokei</i>	Rare, human skin, India.	Unknown.
<i>M. japonica</i>	Rare, human skin, Japanese female.	Unknown, reported in atopic dermatitis.
<i>M. yamatoensis</i>	Rare, human skin.	Unknown.
<i>M. obtusa</i>	Rare, human groin, nasal vestibule, and also from animals	Unknown, reported in atopic dermatitis.
Animal associated		
<i>M. pachydermatis</i>	All animals, likely very diverse and species specific associations.	Healthy and diseased skin of many animals. Potential role in inhalational allergy.
<i>M. equina</i>	Horse	Healthy and diseased skin.
<i>M. nana</i>	Domestic cat, cow, horse ear	Healthy and diseased skin.
<i>M. caprae</i>	Goat	
<i>M. cuniculi</i>	Rabbit	
<i>M. brasiliensis</i>	Parrot (Brazil)	
<i>M. psittaci</i>	Parrot (Brazil)	

Mycology

***Malassezia arunalokei* sp. nov., a Novel Yeast Species Isolated from Seborrheic Dermatitis Patients and Healthy Individuals from India**

Prasanna Honnavar, Gandham S. Prasad, Anup Ghosh, Sunil Dogra, Sanjeev Handa, Shivaprakash M. Rudramurthy
D. W. Warnock, Editor

- Prospective case-control study
- Conducted in villages in provinces in
 - Northwestern India (Punjab; Badashapur, Karial, Salimgarh, Nial, Brass, and Bhunderpeni)
 - Northern India (Haryana; Firozpur, Lalpur, Taparian, Galodi, UjjarM, ajri, Mirjapur and Rathouli)
- Study in December 2011 - February 2013
- Subjects included 124 SD/D patients and 55 healthy control subjects.



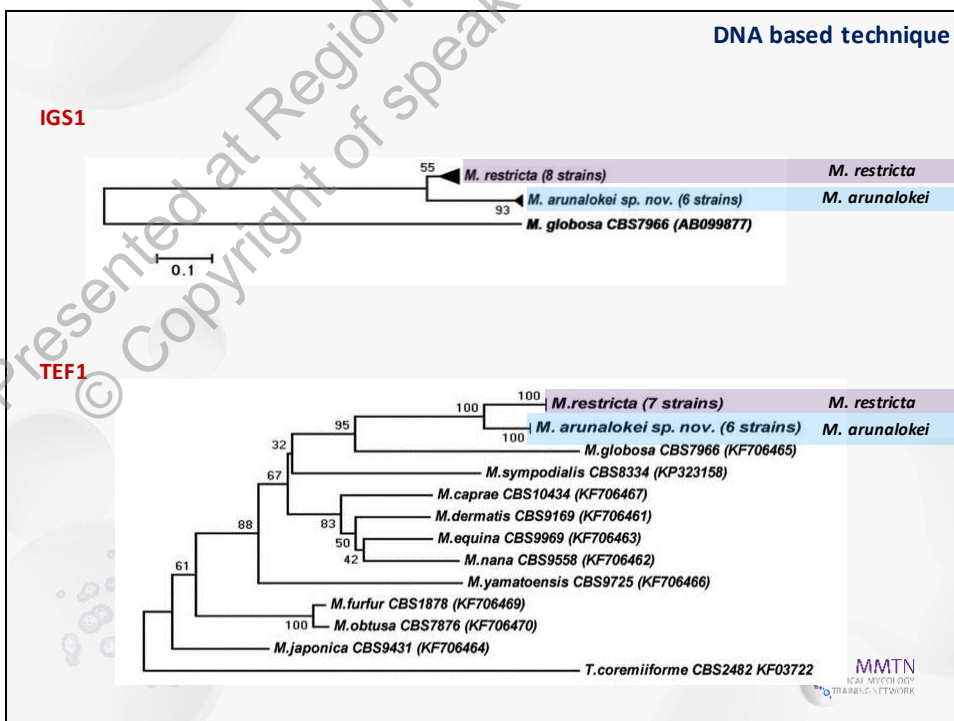
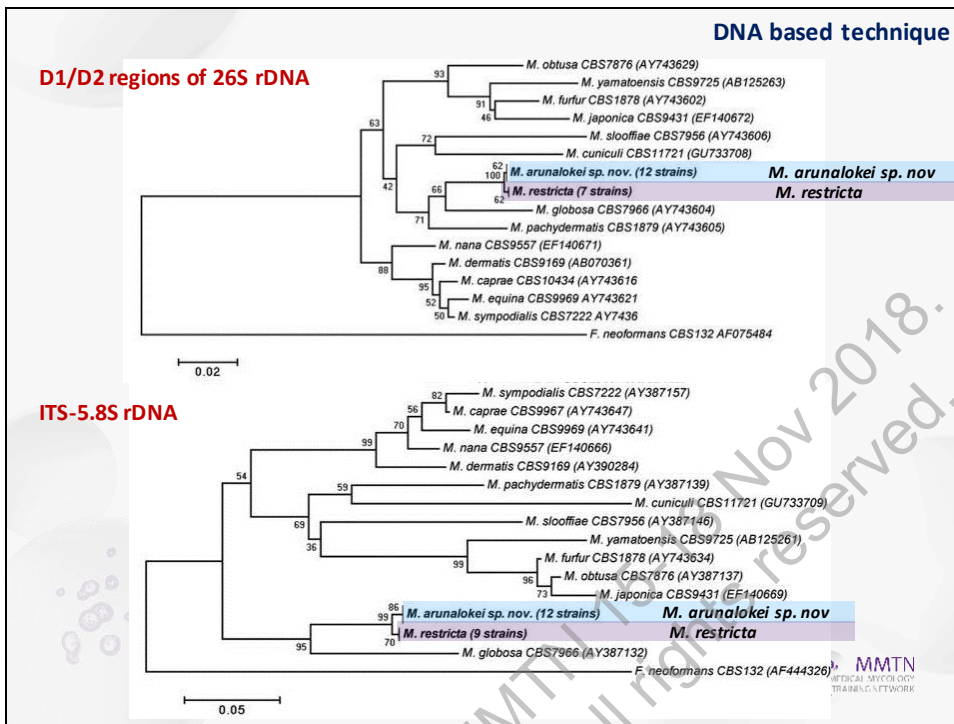
TABLE 1 Distribution of *Malassezia* spp. among SD/D patients and healthy individuals


Species yielding growth	SD/D patients (n = 124)		Controls (n = 55)	
	Scalp (n = 87 [70%])	Nasolabial fold (n = 31 [25%])	Scalp (n = 35 [63.6%])	Nasolabial fold (n = 12 [21.6%])
<i>M. globosa</i>	31 (25)	6 (4.8)	18 (32.7)	4 (7.2)
<i>M. furfur</i>	18 (14.5)	17 (13.8)	5 (9.1)	4 (7.2)
<i>M. globosa</i> + <i>M. restricta</i>	10 (8)	0	6 (10.9)	0
<i>M. restricta</i>	21 (16.9)	4 (3.2)	4 (7.3)	3 (5.4)
<i>M. arunalokei</i> sp.nov.	7 (5.6)	4 (3.2)	2 (3.6)	1 (1.8)
No growth	37 (30)	95 (75)	20 (36.4)	45 (78.4)

* *Malassezia* spp. yielding growth from samples of patients (n = 124) and controls (n = 55).

<i>M. arunalokei</i> sp. nov	Scalp	Nasolabial fold
Patients	5.6%	3.2 %
Controls	3.6 %	1.8%



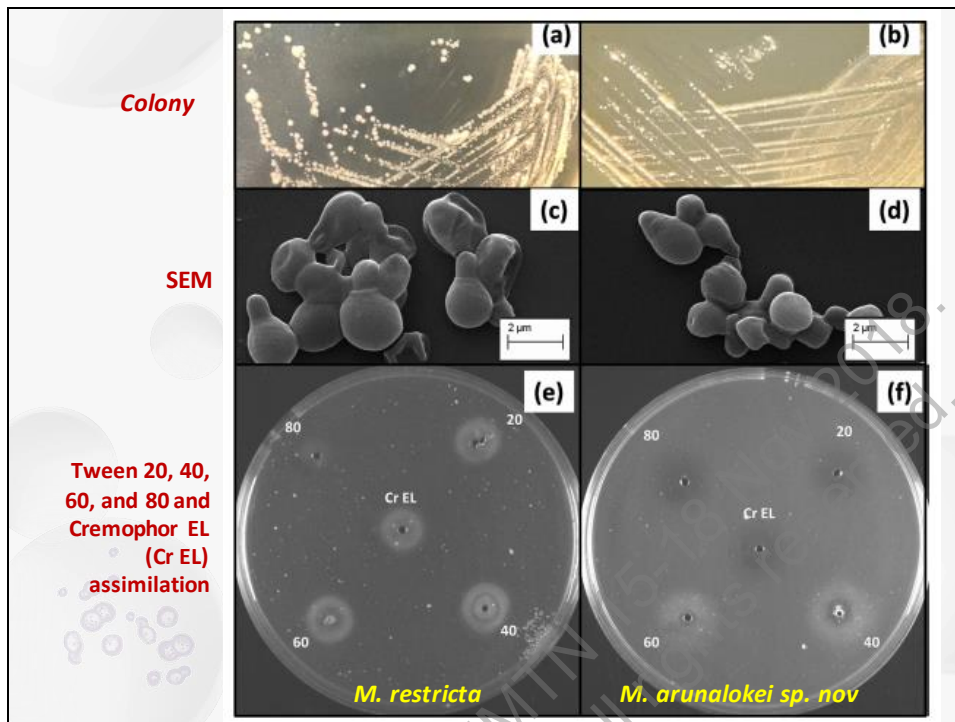




Phenotypic characteristics of *Malassezia* spp.

Species	Cell morphology	Growth on mDA	Lipid dependency	Utilization					Activity		Growth at	
				Tween 20	Tween 40	Tween 60	Tween 80	Cremonphor EL	Catalase	β-Glucosidase	37°C	40°C
<i>M. furfur</i>	Globose, ellipsoidal, cylindrical	+	+	+	+	+	+	+	+(-)	-(w)	+	+
<i>M. pachydermatis</i>	Ellipsoidal	+	+	+	+	+	+	+	+(w)	+(-)	+	+
<i>M. sympodialis</i>	Ellipsoidal	+	+	-	+	+	+	- (w)	+	+	+	+
<i>M. globosa</i>	Globose	+	+	-	- ppt	- ppt	-	-	+	-	-(w)	-
<i>M. obtusa</i>	Ellipsoidal, cylindrical	+	+	-	-	-	-	-	+	+	-(w)	-
<i>M. slooffiae</i>	Ellipsoidal, cylindrical	+	+	+	+	+	- (w)	-	+	-	+	+
<i>M. dermatis</i>	Ellipsoidal, globose	+	+	+	+	+	+	w (+)	+	?	+	+
<i>M. japonica</i>	Globose, ellipsoidal	+	+	-	w	+	-	?	+	?	+	-
<i>M. nana</i>	Ellipsoidal	+	+	v	+	+	w	-	+	-	+	v
<i>M. yamatoensis</i>	Ellipsoidal	+	+	+	+	+	+	?	+	+	+	-
<i>M. caprae</i>	Globose, ellipsoidal	+	+	-	+	+	+ (-)	-	+	+ (-)	-(w)	-
<i>M. equina</i>	Ellipsoidal	+	+	w	+	+	+	-	+	-	w	-
<i>M. cuniculi</i>	Globose	-(w)	+	-	-	-	-	-	+	+	+	+
<i>M. restricta</i>	Globose, ellipsoidal	+	+	-	- ppt	- ppt	-	-	-	-	v	-
<i>M. arunaloeki</i>	Ovoid, globose	+	+	-	- ppt	- ppt	v	- ppt	-	-	-	-

© 2018 MMTN



Persoonia 41, 2018: 56–70
www.ingentaconnect.com/content/nhrv/pimj

RESEARCH ARTICLE

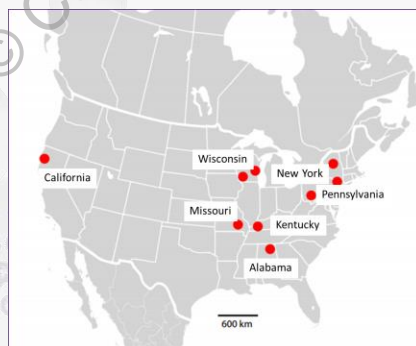ISSN (Online) 1878-9080
<https://doi.org/10.3767/persoonia.2018.41.04>



***Malassezia vesperilionis* sp. nov.:**
a new cold-tolerant species of yeast isolated from bats

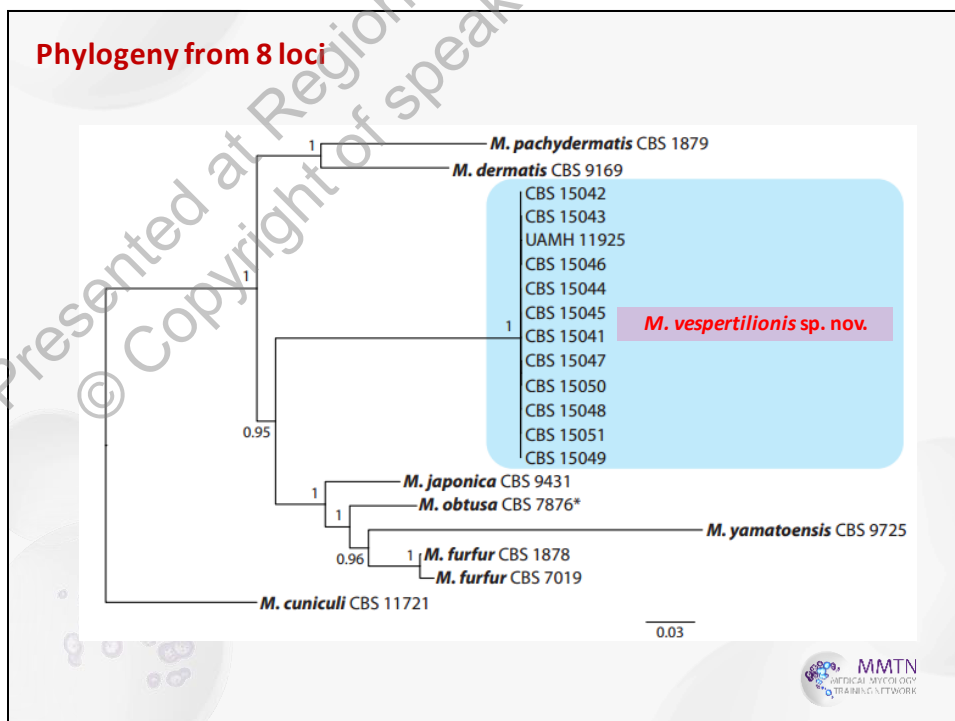
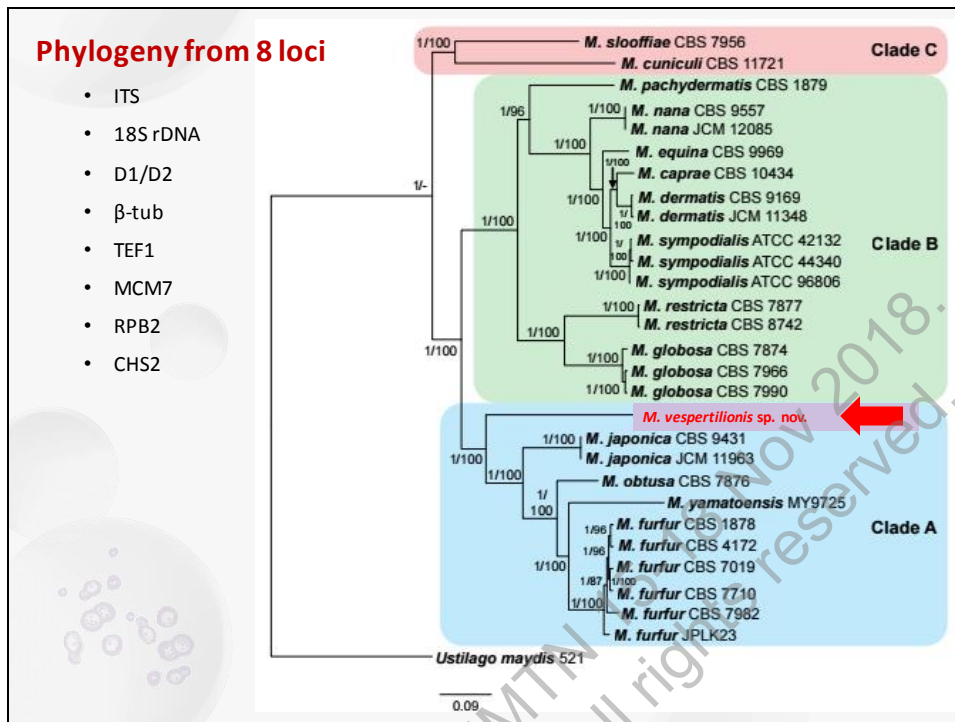
J.M. Lorch¹, J.M. Palmer², K.J. Vanderwolf^{1,3}, K.Z. Schmidt¹, M.L. Verant^{1,3},
 T.J. Weller⁴, D.S. Blehert¹

- Prospective study under the U.S. Geological Survey - National Wildlife Health Center (NWHC) Animal Care : Microbiota of bags
- Totally 264 wing-swabbed samples from bags: 30 sites in 7 states



Hibernating bats,
 such as these *Myotis* sp.,





Malassezia vespertilionis sp. nov.

- **Lipid dependent**
- Growth at all tested temp.
 - 7°C
 - **24°C** (Optimal growth)
 - 30°C, 37°C, 40°C
- Optimal temp. of other *Malassezia* spp. : **32°C**

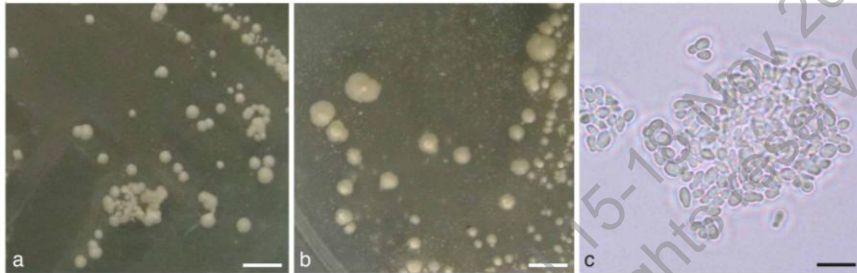


Fig. 5 Colony and cell morphology of *M. vespertilionis* sp. nov. grown on Leeming and Notman Agar at 24 °C. a. Colony size and morphology after 10 d of growth; b. colony size and morphology after 40 d of growth; c. cell morphology of 10-d-old culture. — Scale bars: a, b = 4 mm; c = 5 μ m.

Canine *Malassezia*-associated skin diseases

- Seborrheic dermatitis, Otitis externa
- Clinical aspects
 - localize or generalize scaling, inflammation and itch

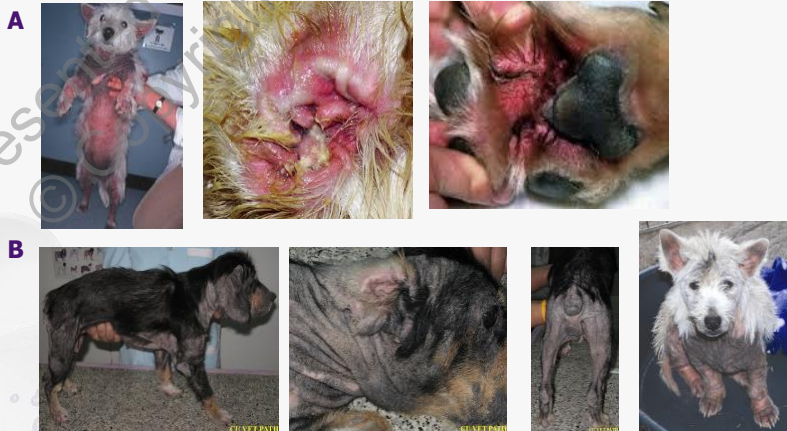

Fig 3. Clinical aspects of CSD, primary acute lesions (A) and secondary chronic lesions (B)

First Case of Catheter-related *Malassezia pachydermatis* Fungemia in an Adult in Korea

- A 62-year-old male – no contact with dogs
- Undergone radical total gastrectomy with adjuvant chemotherapy for poorly differentiated (stage IIIa, T2bN2M0) tubular adenocarcinoma a month previously presented to the emergency room of Chonbuk National University Hospital in May 2014
 - Abdominal pain Ileus and an intraabdominal abscess.
 - D2: Lipid infusion
 - On hospital D 32,
 - BT: 37°C.; WBC count 1.6×10⁹ /L
 - C-reactive protein level 1,122.1 nmol/L,
 - Blood culture: 5-6 hr. Positive – Iden.
 - By Vitek2/VitekMS : *M. pachydermatis*
 - ITS: 100% homology
 - MIC: Etest: FLZ 32 ug/ml; 5FC: >32 ug/ml; VO: 0.25 ug/mL
- Risk factor : ?? Might be catheter ????

Ann Lab Med 2019;39:99-101

19

Table 1: Cases of *M. pachydermatis* systemic infection reported in adults to date

No. Case	Predisposing Diagnosis	Age/ Sex	Prophylactic antifungal agents	Reported risk factors		Not considered risk factors (to date)		Outcome	Reference
				Arterial catheterization	Contact with a potential carrier, including animals	Lipid infusion	Intravascular devices		
1	Acute myeloid leukemia	21/M	No	N/M	Yes	No	Two central catheters	Died	3 (Lautenbach <i>et al.</i> , 1998)
2	Acute myeloid leukemia	69/M	Posaconazole	N/M	No	N/M	Peripherally inserted central catheter line	Improved	4 (Choudhury <i>et al.</i> , 2014)
3	Leprosy, Pneumonia	53/M	No	No	No	No	Midline catheter	Fully recovered	5 (Roman <i>et al.</i> , 2015)
Present patient	Gastric cancer	62/M	No	Yes	No	Yes	Chemoport	Died	

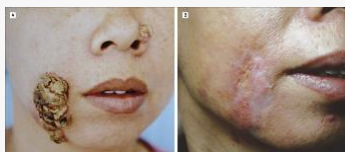
Abbreviations: N/M, not mentioned; M, male.

Ann Lab Med 2019;39:99-101

20

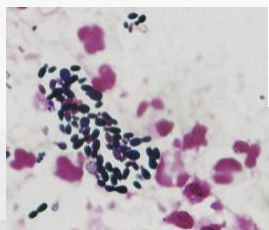
From: **Granulomatous Skin Infection Caused by *M. pachydermatis* in a Dog Owner**

- A 46-yr-old woman presented with an asymptomatic papule on her face in Jan. 2004
- Chronic inflammatory granuloma, numerous purple-red round or ovoid spores in the superficial necrotic tissue, and sparse red spores in the dermis.
- The skin lesions healed after oral fluconazole and cryotherapy.



A verrucous plaque on the right side of the face and a hemispheroid nodule on the left ala nasi.

B, After treatment, hypopigmented scar on the right side of the face



Secretion smear :

Gram +ve, Yeast spores
×1000

Optimal Temp.

- 25°C to 41°C
- seems to be sensitive to the cold
- Catalase -ve

Arch Dermatol. 2006;142(9):1181-1184. doi:10.1001/archderm.142.9.1181

Copyright © 2014 American Medical Association. All rights reserved.

Table 1. Fluconazole (FLZ), itraconazole (ITZ), posaconazole (POS), and voriconazole (VOR) minimum inhibitory concentration (MIC, $\mu\text{g/ml}$) data, standard deviation (SD), and Epidemiological Cut-off Values (ECV) of *Malassezia pachydermatis* and *Malassezia furfur* from different sources.

Isolates	Antifungal drug	Range	MIC _m (SD)	MIC ₅₀	MIC ₉₀	Modal MIC	ECV	No. of isolates (%) MIC>ECV
<i>M. pachydermatis</i> Dog skin	FLZ	4->64	13.8 (14.8)	8	32	8	32	4/62* (6.4)
	ITZ	0.008-0.125	0.013 (0.024)	0.008	0.016	0.008	0.032	2/62 (3.2)
	POS	0.008-0.032	0.013 (0.007)	0.016	0.032	0.016	0.064	0 (0)
<i>M. furfur</i> Human blood and sterile site	VOR	0.016-0.50	0.074 (0.091)	0.064	0.064	0.064	0.25	2/62 (3.2)
	FLZ	8->128	85 (41.8)	64	128	128	512	4/60 ^o (6.6)
	ITZ	0.032-8	0.6 (1.5)	0.25	1	0.25	1	4/60 ^v (6.6)
<i>M. furfur</i> Human skin	POS	0.016-8	0.4 (1.1)	0.25	0.5	0.25	1	4/60 (6.6)
	VOR	0.064-8	1.3 (1.3)	1	2	1	4	1/60 (1.7)
	FLZ	8->128	77 (60.3)	128	>128	>128	>512	7/18 ^o (38.9)
	ITZ	0.064-16	1.1 (3.7)	0.25	0.5	0.25	1	1/18 ^o (5.5)
	POS	0.032-0.25	0.6 (1.8)	0.125	0.25	0.25	1	1/18 (0)
	VOR	0.064-8	1.9 (2.4)	2	2	2	8	0/18 (0)

Note: Percentage of isolates for which the MIC was greater than the ECV is also reported. MIC₅₀ and MIC₉₀: MICs at which 50% and 90%, respectively, of isolates tested were inhibited.

*Two strains showed MIC>ECV for FLZ and ITZ and two for FLZ and VOR.

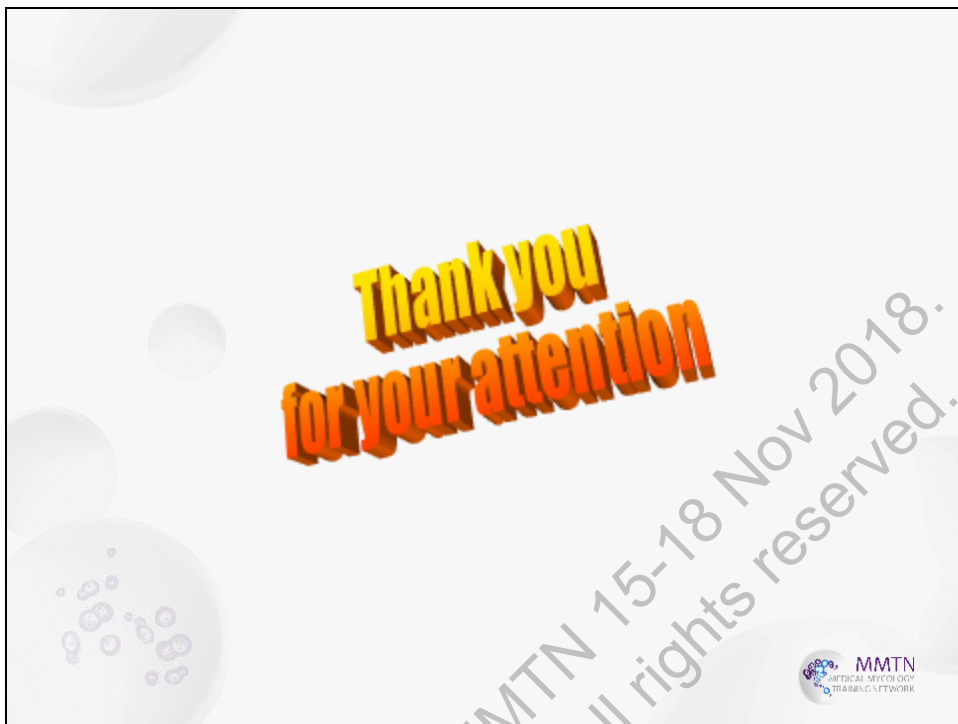
^oThe isolates showed MIC>ECV only for FLZ.

^v Two strains showed MIC>ECV for ITZ and POS and one for ITZ, POS, and VOR.

^o The strain showed MIC>ECV for ITZ and POS.

- 62 *M. pachydermatis* from dogs-dermatitis & 78 *M. furfur* strains from humans bloodstream
- ITZ & POS lower MICs than VOR and FLZ, regardless of the *Malassezia* species.
- The MIC data for azoles of *M. pachydermatis* were four two-fold dilutions lower than those of *M. furfur*.
- Based on the ECVs, about 94% of *Malassezia* strains might be categorized within a susceptible population for all azoles

Calzavara C et al. Med Myco; 2015



Presented at Regional MMTN 15-18 Nov 2018.
© Copyright of speaker. All rights reserved.