

Are your **MRI contrast agents** cost-effective?

Learn more about generic **Gadolinium-Based Contrast Agents**.



FRESENIUS  
KABI

caring for life

**AJNR**

## **Intervertebral Disk-Space Infection after Chymopapain Injection**

Ziad L. Deeb, Sandra Schimel, Richard H. Daffner, Anthony R. Lupetin, Frank G. Hryshko and John B. Blakley

*AJNR Am J Neuroradiol* 1985, 6 (1) 55-58

<http://www.ajnr.org/content/6/1/55>

This information is current as  
of April 27, 2024.

# Intervertebral Disk-Space Infection after Chymopapain Injection

Ziad L. Deeb<sup>1</sup>  
 Sandra Schimel<sup>1</sup>  
 Richard H. Daffner<sup>1</sup>  
 Anthony R. Lupetin<sup>1</sup>  
 Frank G. Hryshko<sup>1</sup>  
 John B. Blakley<sup>2</sup>

Four patients who had received chymopapain injections for treatment of herniated lumbar disks were evaluated by computed tomography (CT) because of persistent low back pain and suspicion of infection. Irregularity of the vertebral end-plate and a mottled appearance of the vertebral bodies suggested the diagnosis of disk-space infection in all four cases. CT-guided biopsy of the disk space was performed in each case, and bacterial cultures demonstrated staphylococcal infections, which were treated accordingly. Diskitis secondary to chymopapain injection is rare because of the precautions that are usually taken. No antibiotics are used routinely with such injections, although systemic antibiotics have been used in diabetics for prophylaxis.

Intervertebral disk-space infections have been reported frequently in the orthopedic literature [1–5]. There is a latent period between the onset of symptoms and appearance of abnormalities on conventional radiography. Radioisotope scanning can contribute to early diagnosis [6], but it is not specific. More recently, computed tomography (CT) has been used to investigate the specific early findings of disk-space infection [7, 8].

Chymopapain is being used with increasing frequency in the nonoperative treatment of lumbar disk disease. The procedure is considered safe and involves few complications [9]. We report our experience with four cases of suspected intervertebral disk-space infection secondary to chymopapain injection, in which CT was used for evaluation and for guidance of biopsies that confirmed the diagnosis in each case.

## Materials and Methods

The charts of 164 patients who underwent chemonucleolysis with chymopapain during a 1-year period at our institution were reviewed. Four patients had disk-space infection secondary to this treatment. The radiographic examinations and clinical findings in these four cases were reviewed.

All four patients had CT scans to evaluate persistent low back pain after chymopapain treatment for disk herniations. All four patients also had been evaluated with lumbosacral CT scanning before the enzymatic intervention. In each case, the diagnosis was confirmed by cultures of blood and/or needle aspirates from the affected disk space.

## Case Reports

### Case 1

A 55-year-old man was admitted with chronic low back pain. He had had back surgery in 1974, resulting in short-term relief of his symptoms. CT of the lumbosacral spine showed a laminectomy at L5–S1 with minimal disk bulging (figs. 1A and 1B). A myelogram demonstrated nerve-root irregularities that were thought to correlate with the clinical findings. Intraoperative diskography was performed by the surgeon under fluoroscopic guidance, and contrast

This article appears in the January/February 1985 issue of *AJNR* and the April 1985 issue of *AJR*.

Received February 21, 1984; accepted after revision August 20, 1984.

Presented in part at the annual meeting of the Radiological Society of North America, Washington, DC, November 1984.

<sup>1</sup> Department of Diagnostic Radiology, Allegheny General Hospital, 320 E. North Ave., Pittsburgh, PA 15212-9986. Address reprint requests to Z. L. Deeb.

<sup>2</sup> Department of Orthopedic Surgery, Allegheny General Hospital, Pittsburgh, PA 15212-9986.

*AJNR* 6:55–58, January/February 1985

0195–6108/85/0601–0055 \$00.00

© American Roentgen Ray Society



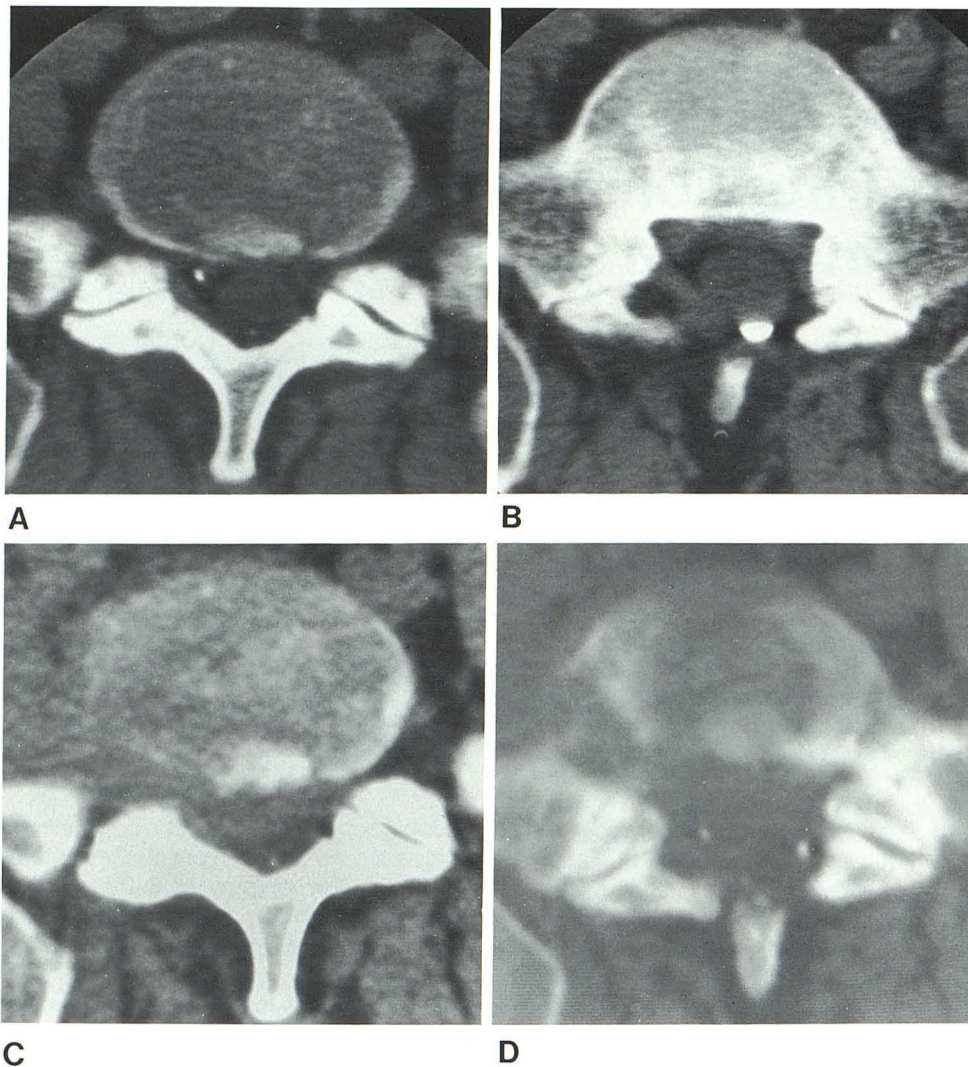


Fig. 1.—Case 1. CT scans before (A and B) and 4 months after (C and D) chemonucleolysis with chymopapain. A, Normal L5–S1 disk; minimal bulging, but no herniation is seen. Changes on the myelogram prompted surgery. B, Normal-appearing S1 vertebral end-plate with previous laminectomy and residual Panthopaque and scarring. C, After chymopapain treatment, L5–S1 disk margins on right side fade into a paraspinal soft-tissue mass. Paraspinal and intraspinal fat planes are obliterated. D, Bone destruction on right side of S1 vertebral body; lesion has irregular edge, not seen on pretreatment scan (cf. B).

material was injected before chymopapain instillation. Symptoms persisted unchanged after chemonucleolysis, and he was readmitted 4 months later for increased low back pain. CT scans obtained at this time demonstrated mottling and destruction of the bone, suggesting infection (figs. 1C and 1D). A CT-guided biopsy was positive for *Staphylococcus aureus*. The patient was treated, but developed a pelvic abscess, seen on follow-up CT 2 weeks later.

#### Case 2

A 57-year-old man was admitted with acute low back pain radiating to his left leg. He had undergone fusion of the lumbosacral spine in 1969 for low back problems, but had been doing well. Admission CT demonstrated degenerated disks at the L4–L5 and L5–S1 levels, with disk bulging at L4–L5. Because of the acute nature of the problem and clinical suspicion of L4–L5 herniation, he underwent chemonucleolysis with chymopapain injection. Repeat CT scanning was performed 5 weeks later because symptoms were unchanged. CT demonstrated mottled end-plates and destruction of bone at the L4–L5 level, suggesting disk-space infection. A CT-guided biopsy was positive for *Staphylococcus aureus*, for which he was treated.

#### Case 3

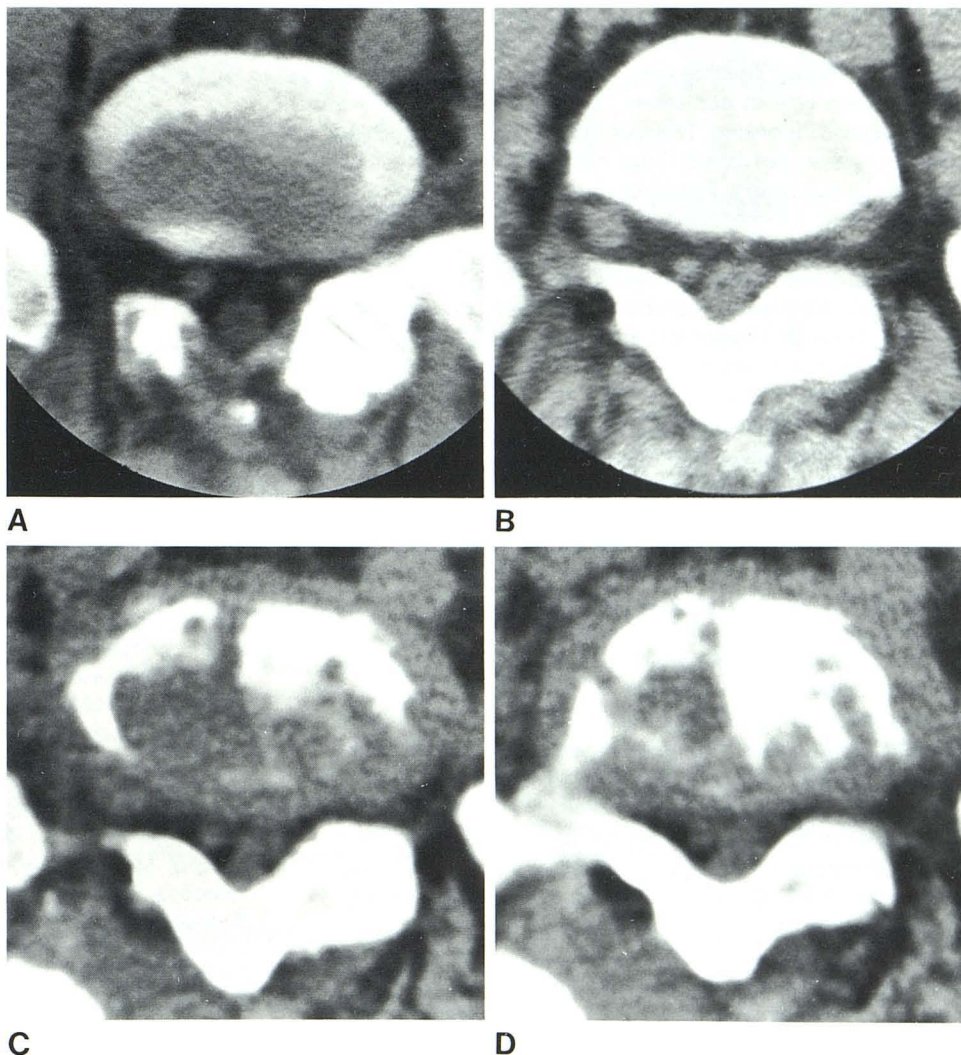
A 40-year-old man was admitted with chronic low back pain 2 years after two back operations that failed to provide complete relief of pain. Admission CT showed laminectomies with fusion at the L4–L5 and L5–S1 levels; disk herniation was present at L4–L5 with intraspinal scarring (figs. 2A and 2B). Chemonucleolysis with injection of chymopapain was performed at L4–L5 and L5–S1. Low back pain persisted unchanged, and repeat CT scanning was performed 6 weeks later. CT at this time showed destruction of the end-plates at the L4–L5 and L5–S1 disk spaces, suggesting infection (figs. 2C and 2D). A CT-guided biopsy was positive for *Staphylococcus epidermidis*. Blood cultures also were positive. He was treated and discharged.

#### Case 4

A 40-year-old man had had chronic low back pain since undergoing a laminectomy and fusion for back problems in 1978. He was admitted for recent onset of pain radiating to the right leg. Admission CT showed a herniated disk at the L4–L5 level in addition to the operative



Fig. 2.—Case 3. CT scans before (A and B) and 6 weeks after (C and D) chemonucleolysis with chymopapain. A, Mild right lateral disk herniation at L5–S1. B, Normal-appearing L5 vertebral end-plate. C, After chymopapain treatment, disk bulging is seen with irregular borders. D, Mottled appearance indicates destruction of end-plate of vertebral body due to disk-space infection.



changes. He underwent chemonucleolysis of the affected disk with chymopapain injection. Low back pain persisted after surgery with no significant change in the leg pain. Repeat CT 3 months later demonstrated mottled bone destruction at the L4–L5 level, suggesting disk-space infection. A CT-guided biopsy was positive for *Staphylococcus epidermidis*, for which he was treated.

## Results

Typical CT changes of disk-space infection were noted in all four patients. Lytic bone destruction producing a mottled appearance of the adjacent end-plates was a universal finding. Persistent low back pain after chymopapain injection prompted reexamination by CT at intervals ranging from 5 weeks to 4 months after chemonucleolysis. In the case with the longest interval before reevaluation (case 1), the patient developed a paraspinal abscess that ruptured into the pelvis. All patients responded to antibiotic treatment with no signifi-

cant neuromuscular sequelae. Treatment was based on positive cultures of organisms obtained from blood and/or needle aspirates from the affected disk space.

## Discussion

Chemonucleolysis using chymopapain for treatment of herniated lumbar disks was introduced in the late 1960s [10]. Its safety and efficacy has been stressed repeatedly in the medical literature [9]. However, sensitivity reactions of varying degrees of severity have been reported [11]. Death due to hypotension under general anesthesia after chymopapain injection has been documented [12], and sudden hypotension after administration of a small test dose of chymopapain has also been reported [13]. Transverse myelitis at the midthoracic level developed in one patient 21 days after lumbar disk chemonucleolysis with chymopapain [14], and this was irreversible. The overall reported incidence of the various reac-



tions ranges from less than 1% to 1.5% [11, 15].

Infection of the disk space has not been reported previously as a complication of chymopapain treatment. Considering the 2.5% infection rate in our series, the absence of other reported cases is surprising. The fact that we obtained biopsies in all our suspected cases may help to explain the high incidence in our series. End-plate irregularities seen on CT are not specific for the diagnosis, as they may reflect local reaction to the chymopapain injection with resultant fusion of the vertebral bodies affected.

Disk-space infections, regardless of cause, present with the same clinical and radiographic findings [6]. Staphylococci were the offending organisms in our four cases. All were primary disk infections secondary to intraoperative diskography with chymopapain injection for disk obliteration. This mode of pathogenesis has not been reported previously in the radiologic literature.

Evaluation by CT was efficient, and CT was definitive in suggesting the diagnosis. The examinations were easy to perform, with no patient discomfort. A great advantage of CT over conventional or other diagnostic radiologic procedures is its ability to demonstrate the paraspinal soft tissues. This proved to be very important in one of our cases, which had pelvic involvement.

Radionuclide scans, although as sensitive as CT, are less specific [5]. Surgical edema, and probably also disk changes secondary to chemonucleolysis, will yield false-positive results in the early postoperative course. Plain-film radiographs and conventional tomography will reveal bone destruction, but soft-tissue changes may be overlooked. Moreover, bone changes are detected much earlier on CT than on conventional radiography.

The differential diagnosis of disk-space infection on CT is limited with a recent history of chemonucleolysis and previous "negative" CT scans available for comparison. Mottling of the vertebral end-plates is suggestive of infection. Metastatic intervertebral disk disease is uncommon, and its occurrence in the immediate postoperative period would be unlikely. Schmorl nodes and surgical removal of the vertebral end-

plate would not be expected to produce paraspinal soft-tissue swelling.

#### REFERENCES

1. Digby JM, Kersley JB. Pyogenic non-tuberculous spinal infection: an analysis of thirty cases. *J Bone Joint Surg [Br]* **1979**;61:47-55
2. Golimbu C, Firooznia H, Rafii M. CT of osteomyelitis of the spine. *AJNR* **1983**;4:1207-1211, *AJR* **1984**;142:159-163
3. Griffiths HD, Jones DM. Pyogenic infection of the spine: a review of twenty-eight cases. *J Bone Joint Surg [Br]* **1971**;53:383-391
4. Kemp HBS, Jackson JW, Jeremiah JD, Hall AJ. Pyogenic infections occurring primarily in intervertebral discs. *J Bone Joint Surg [Br]* **1973**;55:698-714
5. Stauffer RN. Pyogenic vertebral osteomyelitis. *Orthop Clin North Am* **1975**;6:1015-1027
6. Norris S, Ehrlich MG, Keim DE, Guiterman H, McKusick KA. Early diagnosis of disc-space infection using gallium 67. *J Nucl Med* **1978**;19:384-396
7. Price AC, Allen JH, Eggers FM, Shaff MI, James AE Jr. Intervertebral disk-space infection: CT changes. *Radiology* **1983**;149:725-729
8. Lardé D, Mathieu D, Frija J, Gaston A, Vasile N. Vertebral osteomyelitis: disk hypodensity on CT. *AJNR* **1982**;3:657-661, *AJR* **1982**;139:963-967
9. Javid MJ, Nordby EJ, Ford LT, et al. Safety and efficacy of chymopapain (chymodiactin) in herniated nucleus pulposus with sciatica. *JAMA* **1983**;249:2489-2494
10. Smith L. Enzyme dissolution of the nucleus pulposus in humans. *JAMA* **1964**;187:137-140
11. Hall BB, McCulloch JA. Anaphylactic reactions following the intradiscal injection of chymopapain under local anesthesia. *J Bone Joint Surg [Br]* **1983**;65:1215-1219
12. DiMaio VJM. Two anaphylactic deaths after chemonucleolysis. *J Forensic Sci* **1976**;21:187-190
13. Bruno LA, Smith DS, Bloom MJ, et al. Sudden hypotension with a test dose of chymopapain. *Anesth Analg* **1984**;63:533-535
14. Eguro H. Transverse myelitis following chemonucleolysis. *J Bone Joint Surg [Br]* **1983**;65:1328-1329.
15. Watts C. Complications of chemonucleolysis for lumbar disc disease. *Neurosurgery* **1977**;1:2-5