



E-ISSN: 2708-0064
P-ISSN: 2708-0056
IJCRS 2021; 3(2): 26-28
<http://www.allcasereports.com>
Received: 13-06-2021
Accepted: 22-07-2021

Dr. Mounika Katyayani K
Senior Resident, Department
of Pediatrics, NRI Medical
College, Chinakakani, Guntur,
Andhra Pradesh, India

Dr. Vamsikrishna Reddy K
Assistant Professor,
Department of Pediatrics, NRI
Medical College, Chinakakani,
Guntur, Andhra Pradesh,
India

Dr. Vamsikrishna P
MBBS Graduate, NRI Medical
College, Chinakakani, Guntur,
Andhra Pradesh, India

Dr. Kanta Kumari P
Associate Professor,
Department of Pediatrics, NRI
Medical College, Chinakakani,
Guntur, Andhra Pradesh,
India

Dr. Vijaya Laxmi B
Professor and HOD,
Department of Pediatrics, NRI
Medical College, Chinakakani,
Guntur, Andhra Pradesh,
India

Corresponding Author:
Dr. Mounika Katyayani K
Senior Resident, Department
of Pediatrics, NRI Medical
College, Chinakakani, Guntur,
Andhra Pradesh, India

A rare case of metabolic disorder- Alkaptonuria

Dr. Mounika Katyayani K, Dr. Vamsikrishna Reddy K, Dr. Vamsikrishna P, Dr. Kanta Kumari P and Dr. Vijaya Laxmi B

DOI: <https://doi.org/10.22271/27080056.2021.v3.i2a.35>

Abstract

Alkaptonuria is a rare genetic disorder of tyrosine metabolism, due to deficiency of the enzyme homogentisate 1, 2 dioxygenase. This results in characteristic features like blackish urine discoloration, ochronosis, arthropathy, cardiac valve deterioration. In this paper, the authors present a case report of a 4-month-old boy who was brought by his mother to the well-baby clinic, with a chief complaint of black staining of nappy, a few hours after voiding. A qualitative examination of urine after an hour of the collection showed dark black discoloration. Quantitative examination reveals the presence of homogentisic acid to the extent of 200mg/dl. The Diagnosis of Alkaptonuria was confirmed and the infant was started on Vitamin C and put under regular follow-up.

Keywords: Alkaptonuria, homogentisic acid, homogentisic acid dioxygenase, ochronosis

Introduction

Alkaptonuria (AKU), or "black urine disease" is a rare metabolic disorder with an incidence of about 1 in 250000 [1]. The disease is due to a deficiency of homogentisate 1, 2 dioxygenase (HGD), an important enzyme in tyrosine catabolism [2] therefore AKU is characterized by accumulation of homogentisic acid (HGA) in the body and gets excreted in excessive amounts in urine [3]. We report a case of a 4-month-old boy who presented to the well-baby clinic with a complaint of black staining of the nappy.

Case Report

A 4-month-old baby boy, born to a second-degree consanguineous couple, first in birth order, was brought with a history of black discoloration of diapers after voiding urine since the first week of life. The infant was born through normal vaginal delivery (NVD) at term, cried immediately after birth, with a birth weight of 3kilograms, delivered at Guntur general hospital in Andhra Pradesh, India. No significant antenatal, natal, and postnatal problems. The baby was exclusively breastfed and immunized as per the national immunization schedule.

On examination, the child was alert and active, weighing 6.5kilograms and length of 64centimetres. Head circumference was 40 centimeters. Development in all domains was normal. General and systemic examination revealed no abnormality. Diapers were found to have been changed to black color after an hour of voiding urine.

Investigations

Urinary qualitative examination revealed P^H 5.5, normal colored urine upon collection (Figure1a) but turned black when left for an hour at room temperature (Figure1b). Urinary benedict test showed green supernatant with yellow-orange precipitate (Figure2b). Urinary ammoniacal silver nitrate test showed green-black precipitate (Figure3b), and urinary ferric chloride test showed violet color (Figure4b) all that signified the presence of HGA. Quantitative analysis of urine by gas chromatography-mass spectrometry performed in the reference laboratory revealed HGA levels of 200mg/dl (Normally HGA is not present in urine), which confirmed the diagnosis of Alkaptonuria.



Fig 1a: Fresh urine sample;



Fig 1b: Dark discoloration of urine when left at room temperature for an hour




Fig 2a, b: Positive benedict test: 5ml benedict solution taken in a clean test tube (Figure 2a) 5drops of urine added and heated to it, green supernatant with yellow-orange precipitate is observed (Figure2b)indicating the oxidative property of HGA




Fig 3a, b: Positive ammonia Cal silver nitrate test:5ml urine collected in a clean test tube (Figure3a), 5drops of ammoniacal silver nitrate is added to it and immediately greenish-black precipitate is produced (Figure3b) indicating the presence of HGA




Fig 4a, b: Positive ferric chloride test: 5ml urine is collected in a clean test tube (Figure4a), 4drops of 10% Ferric chloride solution is added to it intense violet color is observed (Figure4b) indicating phenols of HGA complexing with Iron

Treatment

The infant is started on Vitamin C200mg/day oral with dietary restriction of phenylalanine and tyrosine.

Follow-up

The parents of the infant were counseled with regard to the possible course and consequences of the disease, put on appropriate therapy, and were advised for follow-up every month. At 10months follow-up, the infant showed no complications.

Discussion

AKU is known to be the first human condition to have a typical Mendelian recessive inheritance. The deficiency of the enzyme HGD (normally present in kidneys and liver) in AKU is due to mutations within the gene located on chromosome 3q13.11. This enzyme is required in the metabolism of tyrosine during the step when HGA is converted to methyl acetoacetate, causing accumulation of HGA. The accumulated HGA oxidizes to benzoquinone acetate which rapidly polymerizes to black-colored alkapton bodies [4, 5]. The oxidative property of HGA is responsible for reducing copper reagent in benedict solution yielding a green supernatant with yellow-orange precipitate. Childhood AKU often presents with dark discoloration of urine upon prolonged exposure to room temperature for several hours. So, the condition is usually masked until adulthood. The delay in the disease identification can cause slow accumulation of alkapton bodies in the cartilage and mesenchymal tissues, leading to pigmentation of tissues (ochronosis) often noticed in teeth, buccal mucosa, nails, skin, sclera in later life. Almost all adults with AKU have arthritis of the hips, knees, and spine. Cardiac involvement in AKU is usually in the form of mitral and aortic valvulitis. However, myocardial infarction is a common cause of death in these patients [6, 7, 8].

Apart from dietary phenylalanine and tyrosine restriction, initiation of vitamin C therapy, Nitisinone, a drug approved by US food and drug administration, dramatically reduces urinary HGA excretion [9]. This compound is known to inhibit 4hydroxyphenylpyruvicdioxygenase, the enzyme which produces HGA (Figure 5)

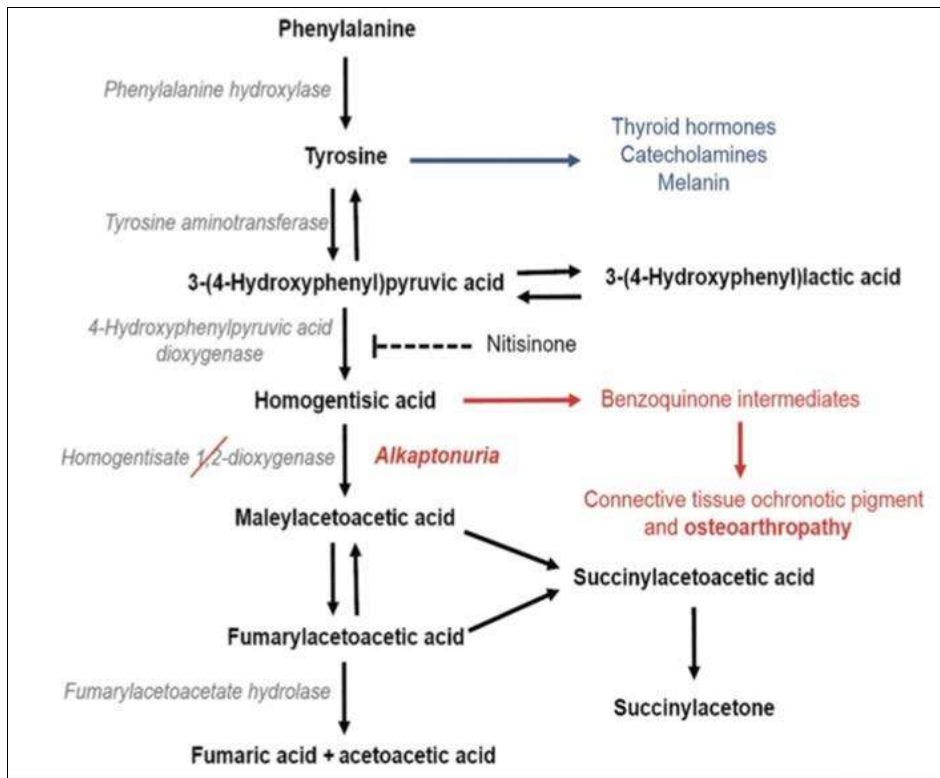


Fig 5: Metabolic pathway of phenylalanine and tyrosine metabolism concerning its defect in AKU and treatment with Nitisinone

Conclusion

In the present study of this case, careful attention of parents provided the key for early diagnosis of disease. This was beneficial in the early initiation of therapy and thereby preventing expected potential complications. This study concludes that creating awareness regarding AKU among consanguineous couples could reduce the future incidence of the disease.

Acknowledgment

The authors thank the management and Department of Pediatrics and Biochemistry, NRI medical college, and Hospital for providing all the necessary facilities to carry out this work.

Conflict of interest

None

Parent consent

Obtained and filed

References

1. Goldsmith L. Disorders of Metabolism. In: Fitzpatrick T, Arthur E, Wolff K, Frank A, editors. *Dermatology in General Medicine*. 3rd Ed. New York: McGraw-Hill Book Co. 1987, 1642-6.
2. Parikh A, Khubchandani RP, Bharucha BA, Kumta NB, Pandya MB, Naik G. Alkaptonuria-a series of seven cases. *J Assoc Physicians India*. 1988;36:565-6.
3. Nafees M, Muzzam M. Alkaptonuria: an inborn error of amino acid metabolism. *Annals*. 2008;14:68-71.
4. Phornphutkul C, Introne WJ, Perry MB, Bernardini I, Murphey MD, Fitzpatrick DL, *et al*. Natural history of alkaptonuria. *New England Journal of Medicine*. 2002;347(26):2111-21. <http://dx.doi.org/10.1056/NEJMoa021736>

PMid: 12501223

5. La Du BN. Alkaptonuria. In: Scriver CR, Beaudet AL, Sly WS, *et al*. *The Metabolic and Molecular Bases of Inherited Disease*. New York: McGraw-Hill. 2001, 2109-23. <http://dx.doi.org/10.1006/rwgn.2001.0025>
6. Iraj RDS. Metabolic diseases. In: Kliegman B, ed. *Nelson textbook of pediatrics*, 16th ed. Philadelphia, WB Saunders. 2000, 349.
7. Mueller RFD, Young ID. *Emery's elements of medical genetics*, 10th ed. Edinburgh, Churchill Livingstone. 1998, 155.
8. Connor JM, Ferguson-Smith M. *Essential medical genetics*, 5th ed. Oxford, Blackwell Scientific, 1997.
9. Intron WJ, O'Brien KJ, Ghal WA. Nitisinone use in hereditary tyrosinemia and alkaptonuria. In: Thoene JG, ed. *Small molecule therapy for genetic disease*. New York: Cambridge University Press. 2010, 114-30.