

Needle Cricothyroidotomy

Decision, Process, Management

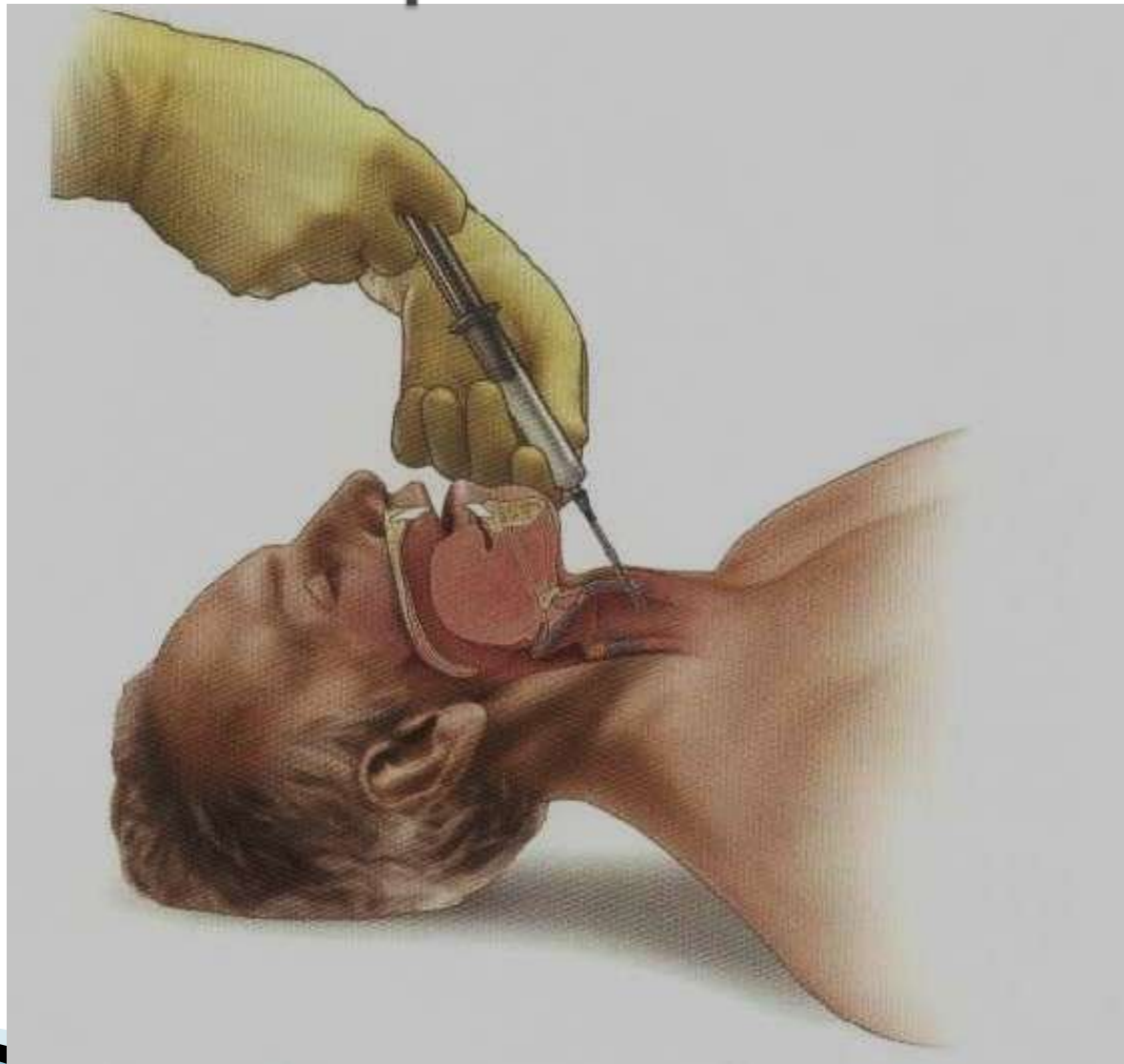


What is it...?

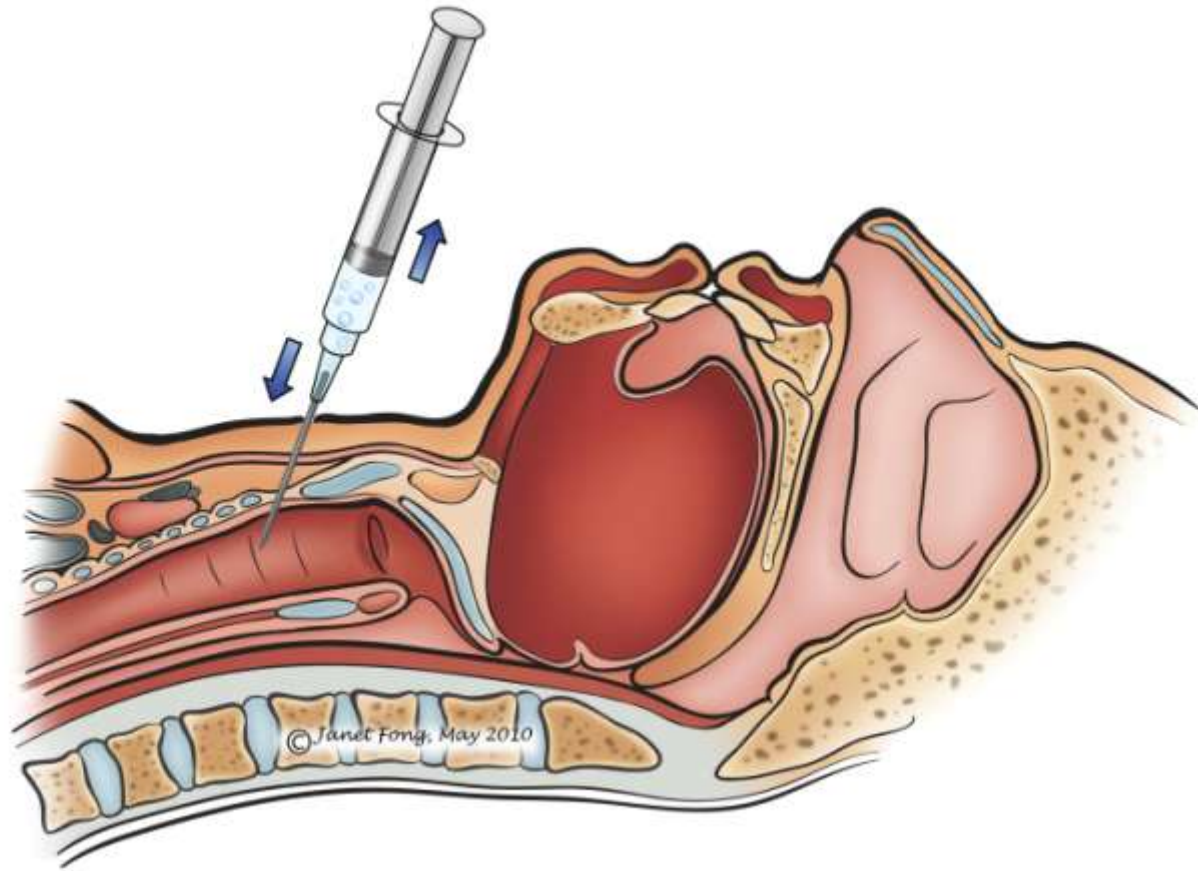
- ▶ Needle cricothyroidotomy involves passing an over-the-needle catheter through the cricothyroid membrane.
- ▶ This procedure provides a temporary secure airway to oxygenate and ventilate a patient in severe respiratory distress when ... other, less invasive methods have failed or are not likely to be successful.

“CAN’T INTUBATE; CAN’T VENTILATE”

Technique visualized



Another visual



Once inserted then what...?

- ▶ The delivery of oxygen to the lungs through this over-the-needle catheter now in place is achieved using a **high-pressure gas source** which is a form of conventional ventilation called...

Percutaneous Transtracheal Ventilation

P T V



PTV

- ▶ PTV uses a high pressure gas source that attaches to the inserted catheter via an improvised device.
- ▶ There is no standard ventilation device for PTV
(more on this later)


*And most of the expired air is assumed to come out the mouth & nose
(somewhat essential)

Not Surgical Cric....!

- ▶ Surgical cricothyroidotomy involves making an incision, with a scalpel, in the CT membrane and...
passing an ETT or Tracheostomy tube through the incision and into the trachea.
- ▶ There is **NO CUTTING** for needle Cric...!

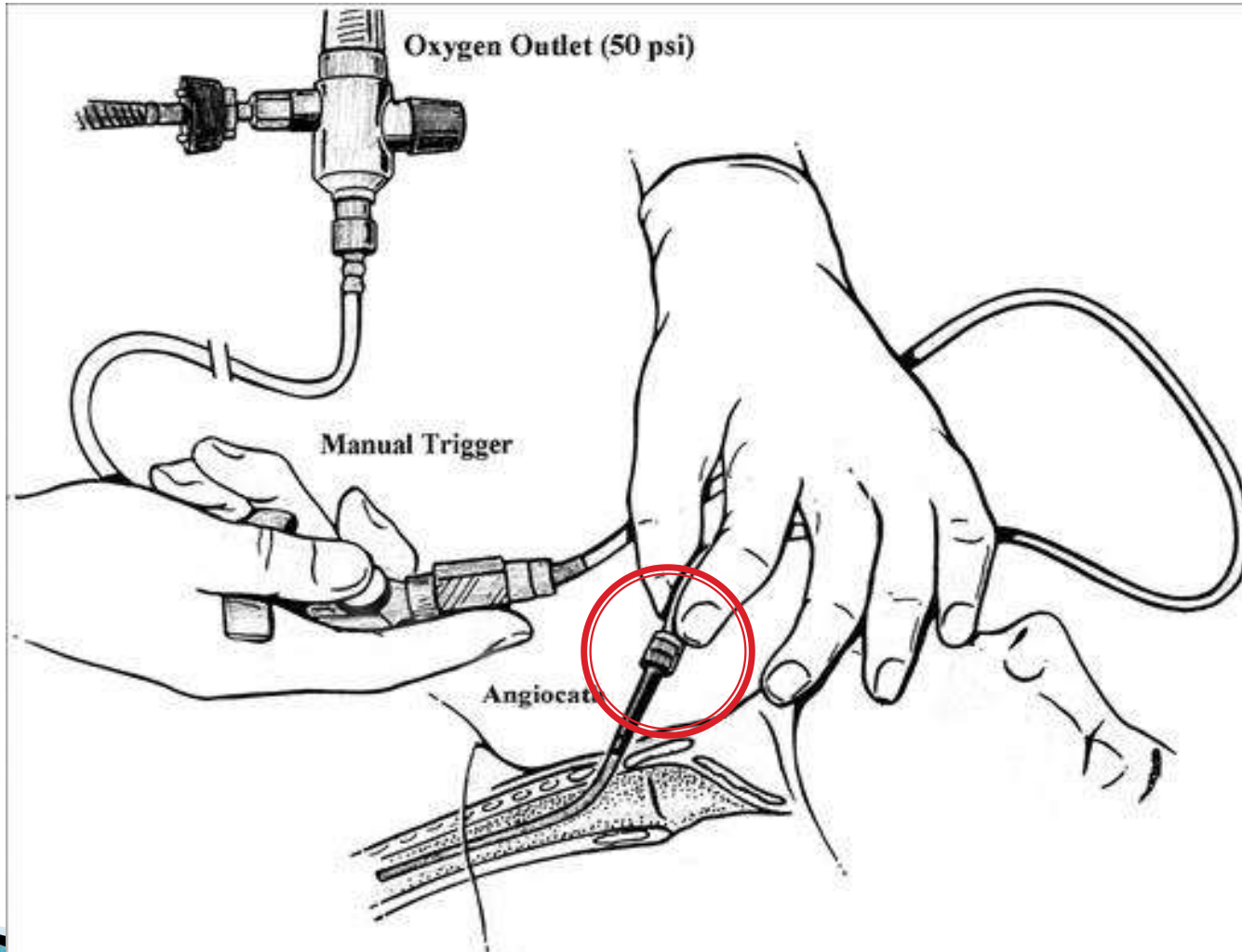
An example of PTV system

(just one example!)




Needle Cricothyroidotomy with PTV attached

(note the red circle)




Any Age...?


- ▶ Any age is indicated
 - ▶ It is considered preferable to surgical Cric. in infants and children up to 10 to 12 years because of the membranes small size and close proximity of vascularity.
 - ▶ 50 psi via 13 -16 gauge cath: Adults
 - ▶ 25 -35 psi via 16 -18 gauge cath: Peds
- 

Who gets this...?


- ▶ The primary indication is ...
 - ▶ **the inability to maintain the airway**
with non-invasive airway procedures.

 - ▶ Can't perform BVM (Can't ventilate)
 - ▶ Can't pass ETT (Can't Intubate)
 - ▶ Can't pass a rescue airway LMA
- 

Can't Ventilate Can't Intubate!

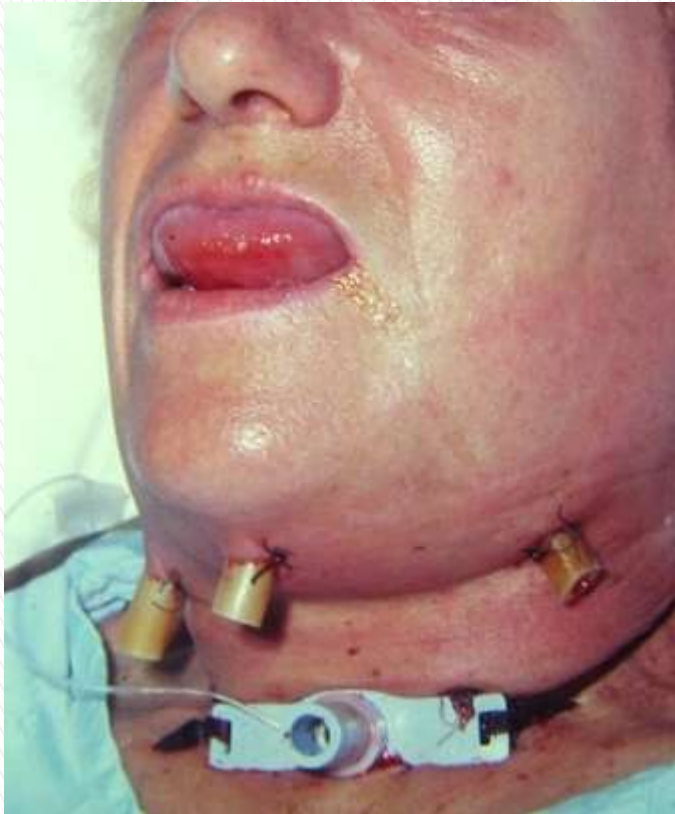- ▶ Examples:
 - ▶ Airway obstruction by uncontrolled bleeding into oral cavity and/or vomiting
 - ▶ Severe maxillofacial trauma; blunt or penetrating or associated mandible fracture
 - ▶ Laryngeal foreign body that cannot be removed expeditiously
- 

Can't Ventilate Can't Intubate!

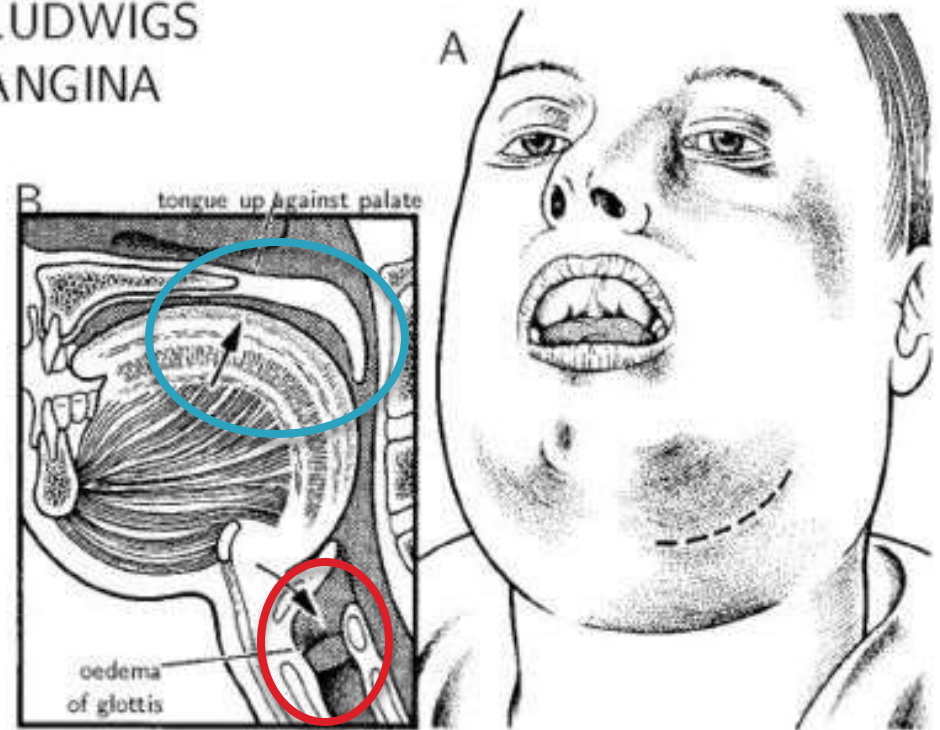
- ▶ Swelling/Edema of upper airway structures
 - ▶ ...from infection: epiglottitis; Ludwig's angina
 - ▶ ...allergic/immunologic: food allergy, angioedema (ACE inhibitor)
 - ▶ ...chemical/Thermal burns to upper airway
- 

Ludwigs Angina:

The danger of an abscessed tooth!




LUDWIGS
ANGINA



Notice the severely edematous tongue!

Vascularly engorged tongue
with
edematous glottic opening

Absolute Contraindication


- ▶ NC with PTV is absolutely contraindicated when....
 - ▶ The airway is maintainable through
non-invasive means
 - ▶ Can you Ventilate? (Are you oxygenating?)
 - ▶ Can you Intubate?
 - ▶ Is LMA an option?
- 

Absolute Contraindication

- ▶ Injury to Larynx with known damage to Cricoid cartilage
- ▶ Laryngeal fracture
- ▶ Tracheal rupture (a blow out–type hole)
 - Presence of subcutaneous emphysema/crepitus
- ▶ Tracheal transection with distal retraction into the mediastinum (This is Bad!)

Relative Contraindications

- ▶ Anterior neck swelling that obscures anatomical landmarks
 - ▶ Anatomic anomalies or distortion of larynx or trachea
 - ▶ Pt with a bleeding disorder

 - ▶ * in most instances...
 - ▶ the benefit that comes with securing the airway will...
 - ▶ outweigh the risk of performing the needle cric. procedure
- 

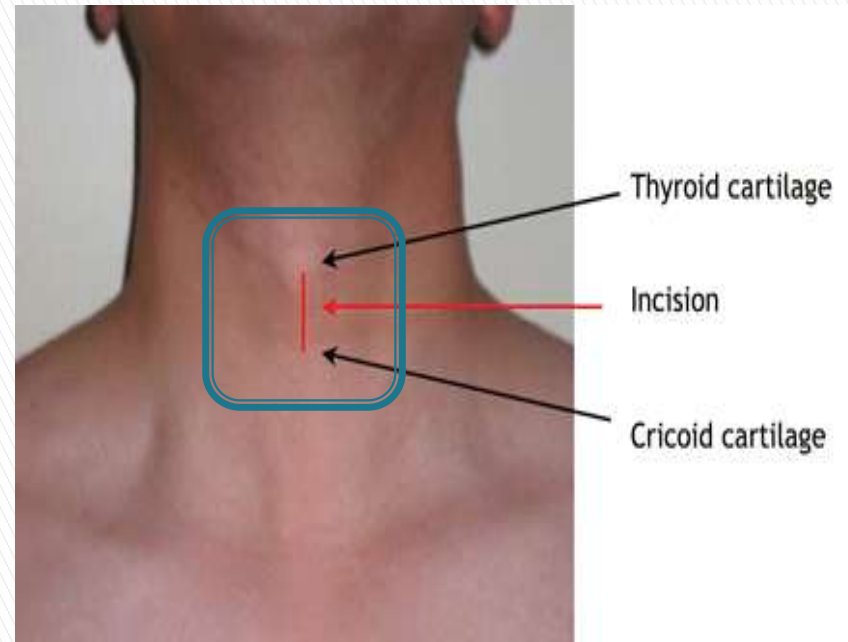
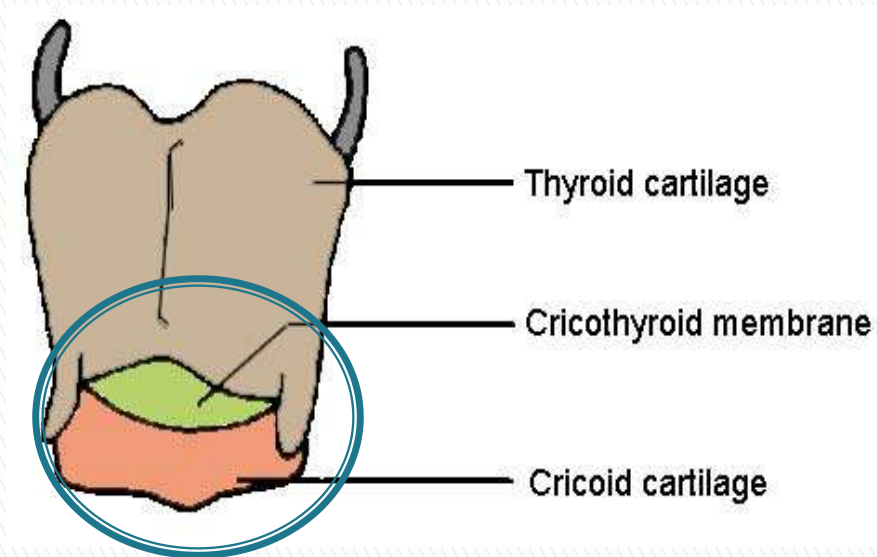
Precautions...

- ▶ **Complete upper airway obstruction**
- ▶ Egress or outflow of expired air via the mouth & nose is difficult in this instance.
- ▶ Risks massive distention of lungs with barotrauma and eventual death!
- ▶ If NC is placed then...
- ▶ **Larger catheter diameter helps**
- ▶ **Prolonged expiratory intervals**
- ▶ **Lower O2 flow rates....mitgates these risks**
(Watch closely for untoward chest expansion!)

PTV less efficient than ETI

- ▶ Concern for CO₂ retention,
NC with PTV is a temporary measure
- ▶ Less than 45 minutes!
- ▶ Hypercarbia worsens ICP!

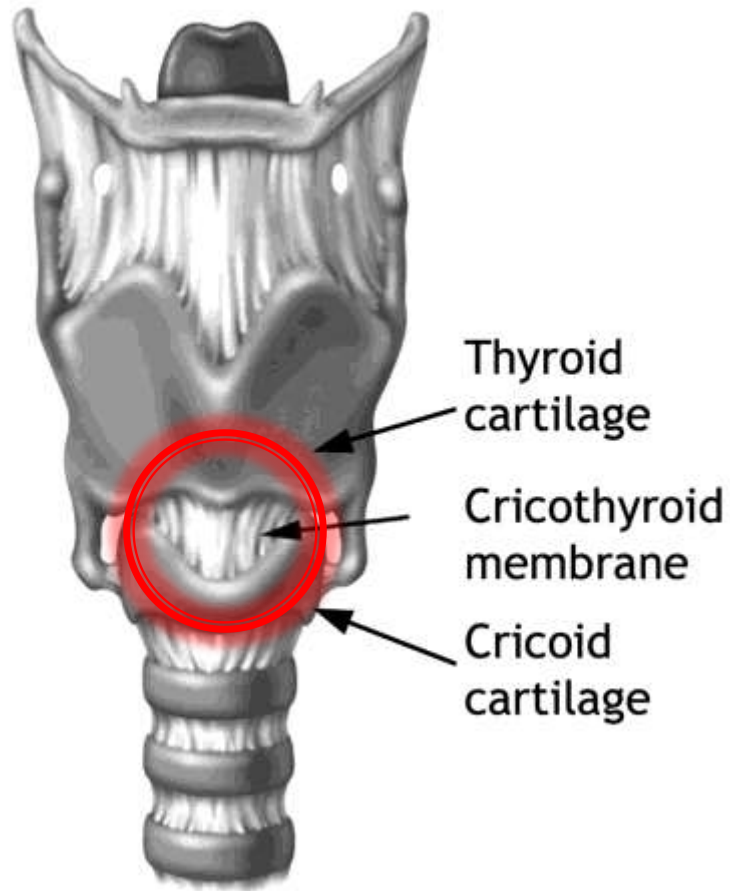
Lets appreciate the anatomy



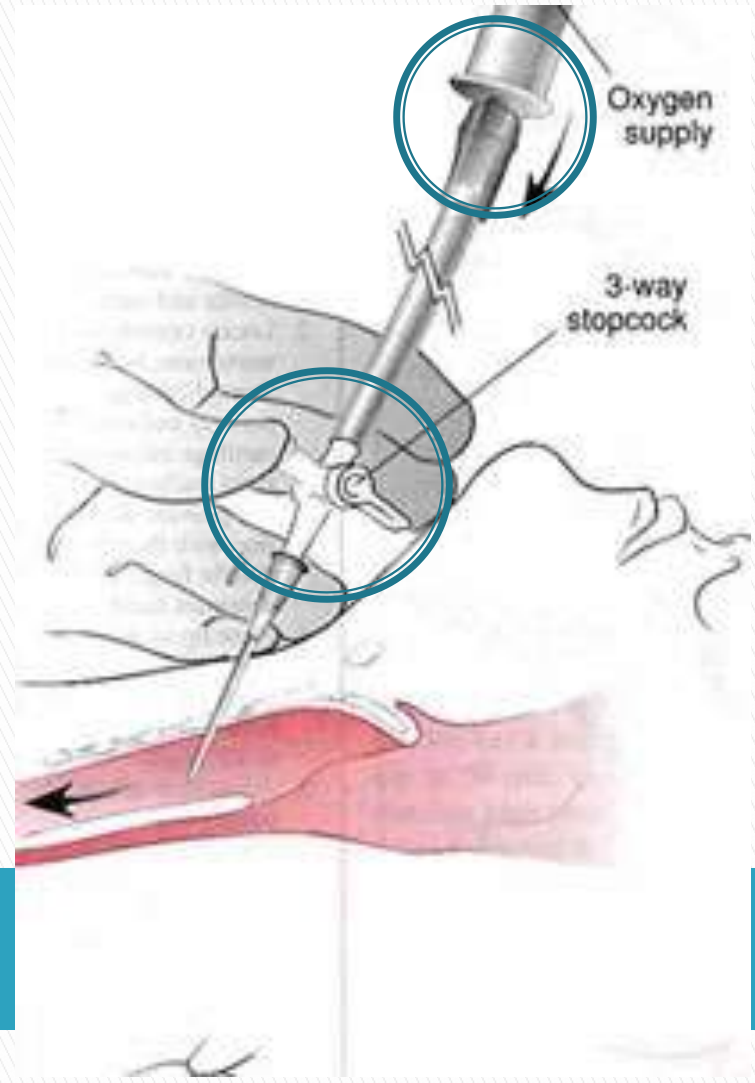
The prominence of the thyroid cartilage is the “Adams apple”

8–19 mm high & wide
under 2.3 mm of skin

CT Membrane: 8-19mm x 8-19mm



- ▶ Note the two areas of improvised attachments.
- ▶ At the top, O2 tubing has been cut to accommodate a pediatric ETT BV attachment
- ▶ Below a 3 way cog provides a pressure release valve
- ▶ Also; Luer-lock attachment at cath hub provides secure closure



BVM connector options

- ▶ Attach a 3ml Luer lock syringe with plunger removed to the cric catheter
- ▶ Place a 7.5mm ID ETT connector
- ▶ Attach the BVM
- ▶ Or...
- ▶ A 3mm ID ETT attached directly to the NC catheter.
- ▶ Or...
- ▶ A 2.5mm ID ETT connector attached to cut off IV tubing with Luer lock tip attached to NC cath.


Possible option...

The cut IV spike can also be attached directly to the BVM, however this configuration is more difficult to secure and stabilize.

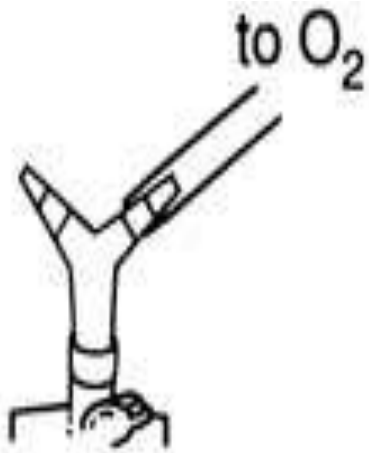


© 2011
CLIC-EM

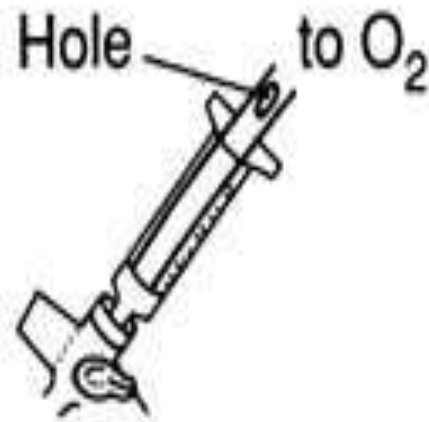
Oxygen tubing connector options

- ▶ Direct connection of tubing to catheter
 - ▶ Y-connector
 - ▶ 3 way stopcog to cath & O2 tubing
- 

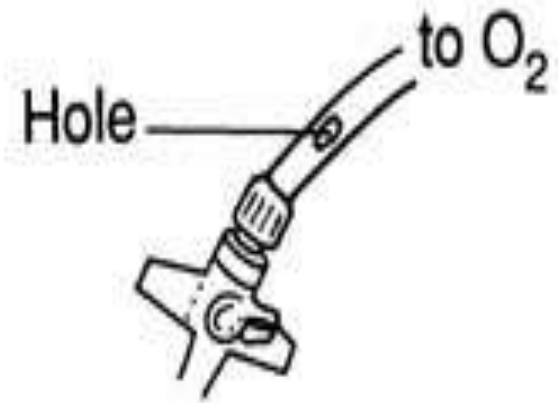
Adaptor Options



Y-connector

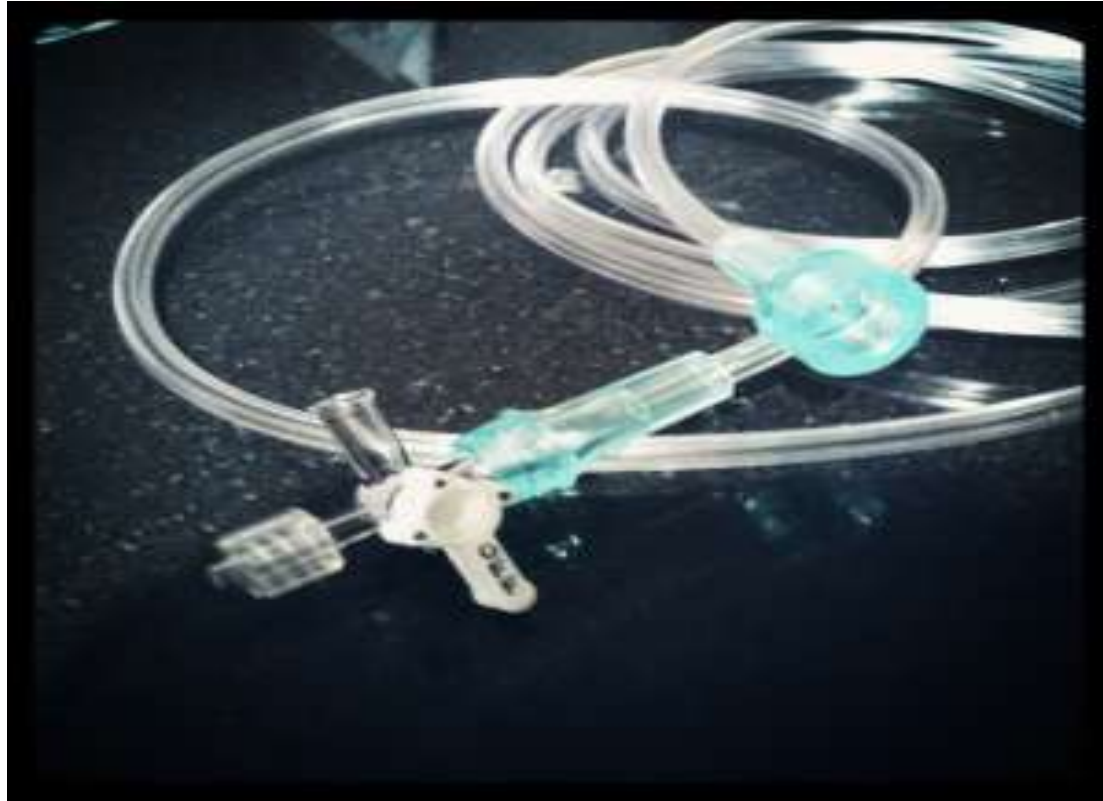

2 ml syringe



Intravenous
giving set

O2 tubing with 3-way cog




Procedure Overview

- ▶ Pt supine on stretcher with neck in extension.
- ▶ Palpate landmarks to locate CM widest expansion.
- ▶ Index/middle finger on laryngeal prominence
- ▶ Slide 2nd finger to cricoid cartilage
- ▶ Pre-oxygenate as possible
- ▶ Swab skin with antiseptic soln:
povidone iodine
- ▶ Of course full VS monitoring with ECG tracing
& ETCO₂ detection as feasible.

Procedure Overview

- ▶ Insert needle with universal precautions & sterile procedure.
- ▶ Over-the-needle catheter should be attached to 3–5 cc syringe with 1 cc of sterile saline.
- ▶ Angle needle 45° caudally or, inferiorly
- ▶ When needle in trachea, escaping air should cause H₂O in syringe to bubble.
- ▶ Advance catheter inward to hub as you would with IV access; remove syringe & needle
- ▶ Reattach a dry syringe to aspirate air for reconfirmation or proper placement.

- ▶ Secure cath with tape and dressing
 - ▶ Attach improvised air delivery system.
 - ▶ Interpose ETCO₂ in circuit to monitor exhale
 - ▶ Begin regular ventilation by intermittently opening and closing in-line valve, occluding side port of stopcog or y-connector, etc.
- 

I:E Ratios

- ▶ For most children...
- ▶ 1:4 to 1:5 with RR = 10 – 12/min
- ▶ For IICP...
- ▶ 1:2 to 1:3 with RR = 15 – 20/min

- ▶ Complete airway obstruction...
- ▶ 1:8 to 1:10 with RR = 5 –6/min
- ▶ To reduce risk of barotrauma
- ▶ Adjust ratios based on
capnography and clinical monitoring
- ▶ **Source:** [uptodateonline.com/needle cricothyroidotomy](http://uptodateonline.com/needle-cricothyroidotomy) 10–2013

Questions...

