

# Acquired Palmoplantar Keratoderma

Shaily Patel,<sup>1</sup> Matthew Zirwas<sup>2</sup> and Joseph C. English III<sup>1</sup>

1 Department of Dermatology, University of Pittsburgh, Pittsburgh, Pennsylvania, USA

2 Division of Dermatology, Ohio State University, Columbus, Ohio, USA

## Contents

Abstract .....	1
1. Keratoderma Climactericum .....	2
2. Chemically Associated Palmoplantar Keratoderma (PPK) .....	3
3. Malnutrition and PPK .....	4
4. Drug-Related PPK .....	5
5. Systemic Disease-Related PPK .....	6
6. PPK and Malignancy .....	6
7. PPK Due to Dermatoses .....	7
8. PPK Caused by Infectious Agents .....	8
9. Idiopathic Acquired PPK .....	8
10. Conclusion .....	9

## Abstract

Palmoplantar keratodermas (PPKs) are a diverse entity of disorders that are characterized by abnormal thickening of the skin on the palms and soles. Traditionally they have been classified as either hereditary or acquired and are distinguished from each other on the basis of mode of inheritance, presence of transgrediens (defined as contiguous extension of hyperkeratosis beyond the palmar and/or plantar skin), co-morbidities with other symptoms, and extent of epidermal involvement, namely diffuse, focal, and punctate. As the terms hyperkeratosis and keratoderma have been used interchangeably throughout the literature, we define acquired keratoderma as a non-hereditary, non-frictional hyperkeratosis of the palms and/or soles that involves  $\geq 50\%$  of the surface of involved acral areas and that may or may not be associated with clinical and histologic inflammation.

Given the numerous possible underlying causes for acquired PPKs, evaluation of patients presenting with acquired PPK can be a perplexing task. To facilitate such evaluations, this review categorizes the acquired PPKs as: keratoderma climactericum, drug related, malnutrition associated, chemically induced, systemic disease related, malignancy associated, dermatoses related, infectious, and idiopathic. In order to avoid the possibility of overlooking an underlying etiology and to eliminate excessive testing, we present an algorithm for assessing patients presenting with acquired PPK. The first step should include a comprehensive history and a physical examination, including a complete skin examination. If findings are consistent with a hereditary keratoderma, then a genetics consultation should be considered. Any findings suggestive of underlying conditions should be aggressively evaluated and treated. If no pertinent findings are identified after a history and a physical examination, laboratory and radiology studies should be undertaken in a systematic, logical fashion.

In terms of treatment, the most successful results occur when the underlying etiology is diagnosed and treated. If no such etiology is evident, then conservative treatment options include topical keratolytics (urea, salicylic acid, lactic acid), repeated physical debridement, topical retinoids, topical psoralen plus UVA, and topical corticosteroids. Etretinate and acitretin have also shown some success as alternative treatments in recalcitrant cases.

Palmoplantar keratodermas (PPKs) refer to a thickening of the skin of the palms and soles caused by excessive keratin.<sup>[1]</sup> They are a heterogeneous group of disorders that are classically grouped as either hereditary or acquired.<sup>[2,3]</sup> In addition, PPKs are classified in terms of epidermal involvement: diffuse, focal, and punctate.<sup>[3]</sup> The primary distinguishing factors that stratify hereditary and acquired groups of PPKs are age of onset, positive family history, and associated features. Hereditary PPKs tend to occur earlier, can be traced in family pedigrees, and may be associated with well described syndromes. Conversely, acquired PPKs occur later in life, without a positive family history, and tend to be attributable to an underlying etiology.<sup>[1-4]</sup> The hereditary PPKs have been reviewed extensively in the literature and in 1996 Stevens et al.<sup>[5]</sup> proposed a classification scheme for these disorders. More recently, in 2005, Itin and Fistol<sup>[6]</sup> classified the hereditary PPKs according to inheritance pattern and molecular basis. Unlike the hereditary PPKs, the acquired forms are less well characterized and described.<sup>[1-4]</sup> As such, there have been no previous comprehensive reviews of acquired PPKs.

Acquired PPKs have varying epidermal involvement patterns: diffuse, focal, and punctate. Diffuse PPK refers to uniform involvement of the palmoplantar surface, including the centripalmar skin and the instep. Focal PPK describes localized areas of hyperkeratosis, mainly over pressure points that may be oval (nummular) or linear (striate). Punctate PPK (papular or disseminated) consists of multiple scattered, discrete round lesions of tiny keratotic papules on the palms and soles not bearing a consistent relationship to pressure points.<sup>[3,4]</sup>

Histologically, hyperkeratosis refers to an increased thickness of the stratum corneum, and this is one of the cardinal histopathologic features of acquired keratodermas.<sup>[7]</sup> In general, acquired keratodermas are histologically nonspecific, with marked hyperkeratosis of the stratum corneum being the most reliable feature, along with variable presence of the following features: epidermal acanthosis, parakeratosis, hyperplasia of the stratum spinosum and granular layer, and perivascular infiltrate of chronic inflammatory cells.<sup>[7-12]</sup>

Throughout the literature, the terms hyperkeratosis and palmoplantar hyperkeratosis have been used synonymously with keratoderma.<sup>[1-107]</sup> As already noted, hyperkeratosis is a histologic feature of keratoderma, and it is also a clinical feature of keratodermas. The variable uses of the term hyperkeratosis throughout the literature on keratodermas makes it difficult to precisely distinguish true keratodermas from simple hyperkeratosis. For the purposes of clarity, in this review we define acquired keratoderma as a non-hereditary, non-frictional hyperkeratosis of the palms and/or soles that involves  $\geq 50\%$  of the surface of involved acral areas and that may or may not be associated with clinical and

histologic inflammation. Hyperkeratosis is used as a descriptive clinical and pathologic term, but not as a diagnosis, in this review.

In this article we review the literature, provide a systematic discussion on acquired PPKs, and present an algorithm for the evaluation of such patients. We searched the databases of PubMed, Scopus, Ovid, and Cochrane over the time period 1931 to 2006. Keywords included 'keratoderma,' 'hyperkeratosis,' 'palmoplantar keratoderma,' 'palmoplantar hyperkeratosis,' 'keratosis,' 'acrokeratosis,' 'acral keratoderma,' and 'keratoderma palmaris et plantaris.'

In the approach to the patient who presents with PPK, the first task is to ensure the condition is not secondary to a heritable cause. Once that has been determined, it then becomes necessary to explore the acquired causes that have been described to result in PPK. In order to facilitate this process, the following categories of PPK can be considered by the clinician: idiopathic, keratoderma climactericum, drug-related, malnutrition-associated, chemically induced, systemic disease-related, malignancy-associated, dermatoses-related, and infectious PPK (table I).<sup>[13-107]</sup> The remainder of this article discusses these categories and describes their various associated etiologies in depth. In addition, we present an algorithm (figure 1) to aid in recognition of the underlying etiology, thus ensuring appropriate management and treatment of the patient with PPK.

## 1. Keratoderma Climactericum

First described by Haxthausen<sup>[13]</sup> in 1934, keratoderma climactericum is sometimes referred to as Haxthausen disease. This entity appears in women of menopausal age with no personal or family history of skin diseases. A strong association with obesity and hypertension has been noted. Lesions are initially round or oval in shape and of varying size.<sup>[13]</sup> The keratotic lesions classically develop first on the plantar pressure points, with subsequent development of erythema, hyperkeratosis, and fissuring, making walking painful (figure 2).<sup>[3]</sup> The condition slowly extends and becomes confluent, but is rarely associated with pruritus.<sup>[3,13,14]</sup> Later in the course of the disease, hyperkeratosis can be seen starting in the central palmar region between the thenar and hypothenar eminences, and in some cases can become confluent on the palms as well.<sup>[3,14]</sup>

Microscopically, the lesions of keratoderma climactericum have been described as compact orthokeratotic hyperkeratosis of the epidermis together with hypergranulosis.<sup>[3,14]</sup> Although the exact mechanism of how this change occurs has not been well described, it has been proposed to be due to hormonal dysregulation.<sup>[15]</sup> Interestingly, Wathcel<sup>[16]</sup> reported palmar and plantar hyperkeratosis together with symptoms associated with menopause

**Table I.** Acquired causes of palmoplantar keratoderma

Category	Cause
Keratoderma climactericum	
Chemicals	Arsenic
	Chloracnegens
Malnutrition	
Drug related	Glucan
	Tegafur/fluorouracil
	Bleomycin
	Hydroxyurea (hydroxycarbamide)
	Lithium
	Verapamil
	Venlafaxine
	Quinacrine (mepacrine)
Systemic diseases	Hypothyroidism
	Myxedema
	Chronic lymphedema
	Circulatory disorders
Malignancy	Acrokeratosis paraneoplastica
	Tripe palms
	Esophageal cancer
	Lung cancer
	Breast cancer
	Bladder cancer
	Stomach cancer
	Colon cancer
	Skin cancer
	Myeloma
	Mycosis fungoides
Sézary syndrome	
Dermatoses	Psoriasis
	Keratoderma blennorrhagica
	Pityriasis rubra pilaris
	Atopic dermatitis
	Chronic hand dermatitis
	Lichen planus
	Lichen nitidus
	Lupus erythematosus
	Aquagenic
	Infectious causes
Syphilis	
Encrusted scabies	
Trichophytosis	
Leprosy	
Idiopathic	Tuberculosis

such as hot flushes, genital atrophy, osteoporosis, and loss of libido in three young women following bilateral oophorectomy. This author described complete resolution of hyperkeratosis with the administration of conjugated estrogens. In this study, the women were young and did not undergo natural menopause, as did

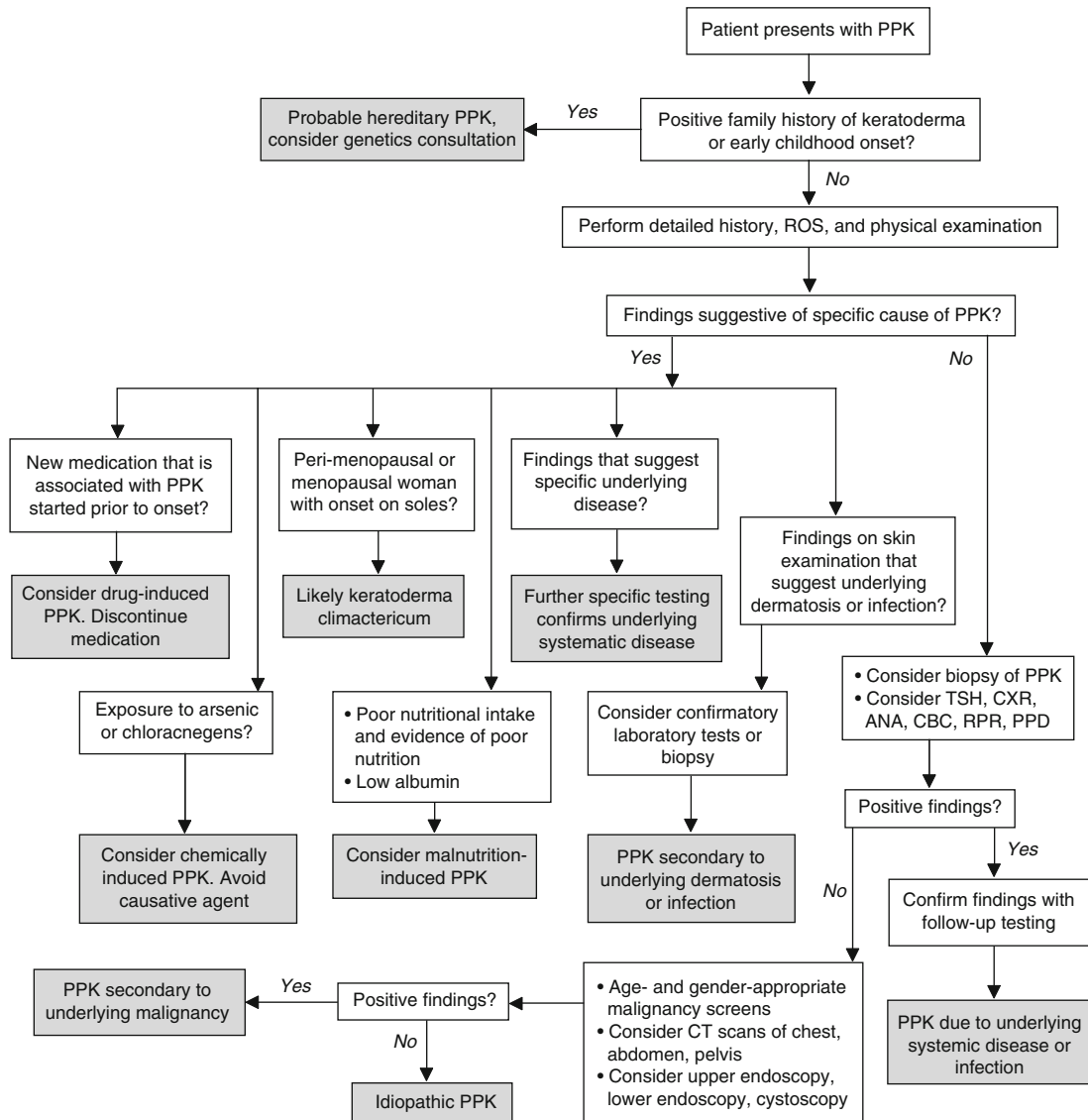
the women in subsequent studies. Deschamps et al.<sup>[14]</sup> reported ten cases of keratoderma climactericum and did not find an association with sex hormones, in particular estradiol, estrone, follicle-stimulating hormone, or luteinizing hormone. Other etiologies, including contact dermatitis, fungal infections, and altered vitamin A serum levels, were ruled out. Brincat et al.<sup>[17]</sup> and Shuster et al.<sup>[18]</sup> suggested that decreased collagen content in the skin, which has been shown to be influenced by sex hormones, may contribute to keratoderma climactericum. Successful treatment was observed with etretinate, which was associated with partial or total remission of keratoderma climactericum in all ten patients.<sup>[14]</sup> Finally, a later study described successful use of topical estrogen, devoid of systemic effects, in the treatment of keratoderma climactericum.<sup>[19]</sup> However, to date, a definitive pathogenic role for estrogens in keratoderma climactericum has not been established.

In summary, keratoderma climactericum is generally a clinical diagnosis, based on the age and sex of the patient and on typical clinical findings, including initial involvement of the feet, the presence of erythema and fissuring, and lack of transgrediens (defined as contiguous extension of hyperkeratosis beyond the palmar and/or plantar skin). Other diagnoses such as contact dermatitis and tinea must be ruled out. Histopathology is not specific, but a biopsy may be helpful in ruling out psoriasis. Given the success of etretinate, acitretin is the treatment of choice.

## 2. Chemically Associated Palmoplantar Keratoderma (PPK)

Exposure to certain chemicals, namely arsenic and chloracnegens, has been reported to present as PPK.<sup>[20,21]</sup> Sass et al.<sup>[20]</sup> described two cases of arsenic-induced PPK, one in a woman who presented with punctate PPK in whom histologic examination showed acanthosis of the epidermis with hyperkeratosis. A laboratory examination revealed a moderate anemia and leukopenia, along with high concentrations of arsenic in hair and nail samples, thus confirming the diagnosis. Another case was described in a 42-year-old man with punctate PPK that had appeared a few months prior to presentation; the patient was using Fowler's solution, which contains arsenic.<sup>[20,22]</sup> Acitretin used in conjunction with keratolytics stabilized the condition. In addition to keratoderma, major dermatologic signs of chronic arsenic toxicity include diffuse or spotted hypo- and/or hyperpigmentation, particularly of the abdomen.<sup>[23]</sup> Thus, in a patient who presents with PPK, a careful history should be obtained and arsenic-induced keratoderma should be considered in the differential diagnosis.

Poskitt et al.<sup>[21]</sup> described a man who presented with chloracne, thickening of his palms and soles, and sclerodactyly for approximately 1 year. The patient had been exposed to chloracnegens,



**Fig. 1.** Algorithm for the approach to a patient presenting with palmoplantar keratoderma (PPK). **ANA** = antinuclear antibody; **CBC** = complete blood count; **CXR** = chest x-ray; **PPD** = purified protein derivative; **ROS** = review of systems; **RPR** = rapid plasma reagin; **TSH** = thyroid-stimulating hormone.

which are halogenated aromatic compounds found in polyhalogenated naphthalenes, polyhalogenated bisphenyls, and contaminants of polychlorophenol compounds, especially herbicides and herbicide intermediates, in his home workshop.<sup>[24]</sup> Hyperkeratosis has been described following chloracnegen exposure; however, the above case report represents the first description of PPK associated with exposure to choracnegens. Resolution of symptoms typically occurs 4–6 months after the last known exposure to the offending chemical, but cases have been reported in which symptoms persisted for 15–30 years.<sup>[21]</sup> In addition, dioxin, which is one of the most potent chloracnegens, has also been linked to chloracne with an acquired punctate PPK.<sup>[25]</sup>

### 3. Malnutrition and PPK

In a paper by Lee et al.,<sup>[26]</sup> skin damage secondary to malnutrition was described by a physician inmate of a concentration camp in northeast China. Most inmates were 18- to 70-year-old Chinese men whose diets consisted of corn and green vegetables with minimal animal protein. All 5000 inmates with protein energy malnutrition and vitamin deficiency developed dry, calloused palms and soles. Thin, pyramidal pieces of epidermis peeled up, but did not detach, contributing to the pain and roughness. The palmar lesions were more severe on the fingertips, hypothenar, and thenar eminences, while the plantar lesions had fissuring and thickening primarily in weight-bearing areas, especially over the heel and the distal end of the first metatarsal bone. Injections of

thiamine 50mg would initiate healing; however, multiple nutrients, such as nutritional support and multivitamins, were more effective for the palms and soles. The authors concluded that chronic mechanical injury combined with malnutrition was the primary cause of PPK with associated fissures in these patients.

#### 4. Drug-Related PPK

Numerous drugs have been reported to cause PPK, including glucan, tegafur, lithium, venlafaxine, and quinacrine (mepacrine). Chemotherapeutic agents, namely bleomycin and hydroxyurea (hydroxycarbamide), together with quinacrine have been reported to result in a hyperkeratosis and possible keratoderma. However, it is unclear if the hyperkeratosis described can be considered an acquired PPK as the involved area may vary in patients.<sup>[27-41]</sup>

Glucan-induced keratoderma of the palms and soles was described in 6 of 20 patients with AIDS who were receiving infusions of soluble glucan.<sup>[27]</sup> Glucan is a  $\beta$ -1,3 polyglucose oligosaccharide derived from the inner cell walls of yeast that was used as an immunostimulant for patients with AIDS. Clinically, patients developed symptoms such as pruritus, erythema, pain, and discomfort. However, all patients also eventually developed diffuse hyperkeratosis of the palms and/or soles weeks to months after initiation of glucan infusions. Improvement in the condition was noted as early as 2 weeks after discontinuation of glucan therapy and the PPK eventually resolved in all patients. Although the pathogenesis of glucan-induced keratoderma is unknown, it is believed that glucan may regulate epidermal differentiation, thereby promoting epidermal hyperkeratosis.<sup>[28]</sup>

Tegafur is a fluoropyrimidine analog of fluorouracil used in the treatment of gastrointestinal neoplasms. Tegafur was reported to be the cause of PPK secondary to chronic acral erythema with subsequent resolution upon discontinuation of therapy.<sup>[29]</sup> In addition, PPK has been described in patients with acral erythema after repeated courses of continuous infusions of fluorouracil. The author concluded that in cases of acral erythema, if the causative agent is not discontinued, the cutaneous reaction may progress to keratoderma.<sup>[29]</sup>

Lithium has been reported to cause numerous cutaneous adverse effects, including acneiform eruptions, pruritus, maculopapular eruptions, folliculitis, pretibial ulcerations, alopecia, exacerbation of psoriasis, and keratoderma.<sup>[3,30]</sup> One case of PPK, ichthyosis, and euthyroid goiter has also been described.<sup>[31]</sup>

The most common mucocutaneous adverse effect of venlafaxine, a commonly prescribed antidepressant of the serotonin-noradrenaline reuptake inhibitor class, is xerostomia. Dalle et al.<sup>[32]</sup> reported the case of a man presenting with 6 months of PPK who had started taking venlafaxine 10 months prior to presenta-

tion. No other exposures were noted and biopsies revealed hyperkeratosis and parakeratosis. Upon withdrawal of venlafaxine, the palm and sole hyperkeratoses resolved over 4–5 weeks without any other therapy.

Bleomycin and hydroxyurea are chemotherapeutic agents that have been associated with a number of adverse effects. Bleomycin has been reported to cause hyperkeratosis of the hands and nails, together with erythema, edema, and hyperpigmentation.<sup>[33,34]</sup> In adults receiving prolonged hydroxyurea therapy, adverse effects involving the skin and nails have been reported to occur.<sup>[35]</sup> Skin changes included palmar and plantar hyperkeratosis, leg ulcers, dermatomyositis-like changes, atrophy, lichen planus, and localized or generalized hyperpigmentation.<sup>[36,37]</sup> It has been proposed that regenerative repair may be abnormal in some individuals, resulting in patchy hyperkeratosis and hyperpigmentation following treatment with hydroxyurea.<sup>[38]</sup>

Use of other medications such as verapamil, a calcium channel antagonist, and quinacrine, an antimalarial, has been reported to result in hyperkeratosis. However, determination that use of these drugs is causing PPK should depend upon consideration of the involved surface area of the palmar and/or plantar surfaces in the affected patient. Verapamil has been implicated in the etiology of palmoplantar hyperkeratosis together with other cutaneous adverse reactions including pruritus and rash.<sup>[39]</sup> Quinacrine has also been reported to result in inflammatory skin reactions, including

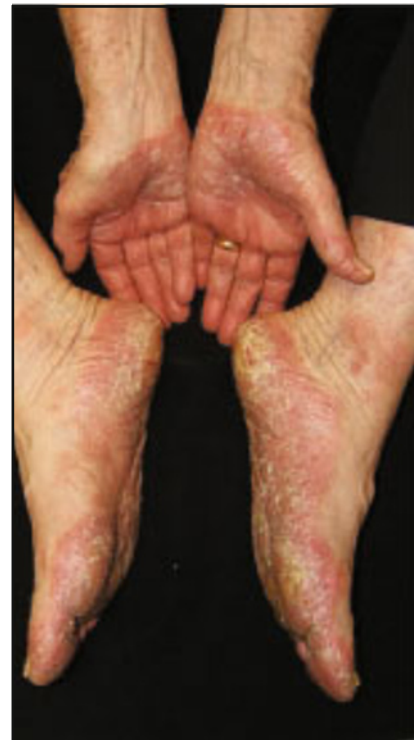

Fig. 2. Keratoderma climactericum.

eczematous eruptions and lichenoid exfoliative reactions, which subsequently have caused keratoderma together with cutaneous atrophy and pigmentary changes.<sup>[40,41]</sup>

Thus, drug-induced PPK should be considered and patients should be questioned about any new medications and the time frame during which symptoms appeared; this will enable the clinician to determine the likelihood that drugs may have induced PPK. However, the diagnosis can be clinched only when the findings resolve following discontinuation of the suspected medication.

### 5. Systemic Disease-Related PPK

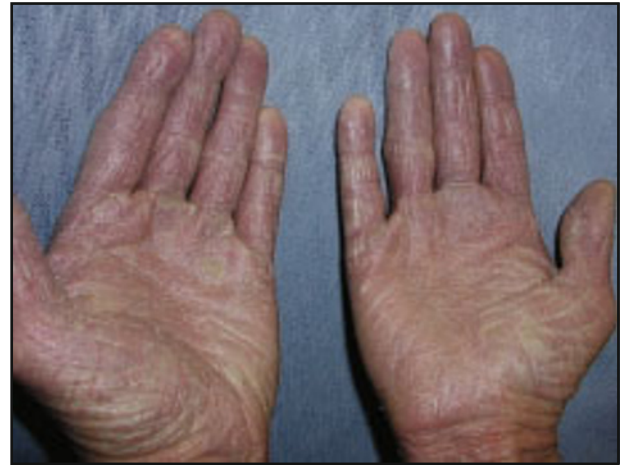A number of systemic disorders, including hypothyroidism, myxedema, chronic lymphedema, and other circulatory disorders, have been noted to be associated with PPK.<sup>[3,42-47]</sup>

Hypothyroidism is a rare cause of acquired PPK that is reversible with thyroid hormone replacement.<sup>[42-45]</sup> Myxedema has also been associated with PPK, as first reported by Shaw et al.<sup>[43]</sup> Distinctive features of the keratoderma in these cases included marked severity, sometimes verrucous in nature, with diffuse plantar involvement and more limited involvement of the palms. However, there was a striking lack of response to topical corticosteroids and keratolytics, together with a rapid response to thyroid hormone replacement.<sup>[3,42-46]</sup>

Chronic lymphedema and other circulatory disorders have been reported in association with acquired PPKs. In chronic lymphedema, the skin becomes diffusely thickened and develops a velvety papillomatous surface. This classically occurs in filariasis, but may develop from lymphedema of any etiology.<sup>[3]</sup> Hyperkeratosis in association with lymphedema has been reported to improve after treatment with etretinate.<sup>[47]</sup> Other circulatory disorders, including acrocyanosis and livedo reticularis, have been reported in association with keratoderma.<sup>[3]</sup>

### 6. PPK and Malignancy

Isolated nonspecific keratoderma has been reported as a paraneoplastic marker for internal malignancy, and can also present as a clinically unique paraneoplastic type of keratoderma called tripe palms.<sup>[3,48-76]</sup> Acquired PPK has been noted to be associated with esophageal, lung, bronchial, breast, urinary bladder, gastric, colon, and skin cancer.<sup>[48-56]</sup> In addition, there has been of a report of a patient with diffuse planar xanthomatosis, myeloma, and acquired PPK, which indicates a possible relationship between paraproteinemia and keratoderma.<sup>[57]</sup> Sézary syndrome (figure 3) is commonly associated with palmoplantar hyperkeratosis, although non-



**Fig. 3.** Sézary syndrome.

Sézary mycosis fungoides has also been associated with, and can even present as, PPK.<sup>[58-60]</sup>

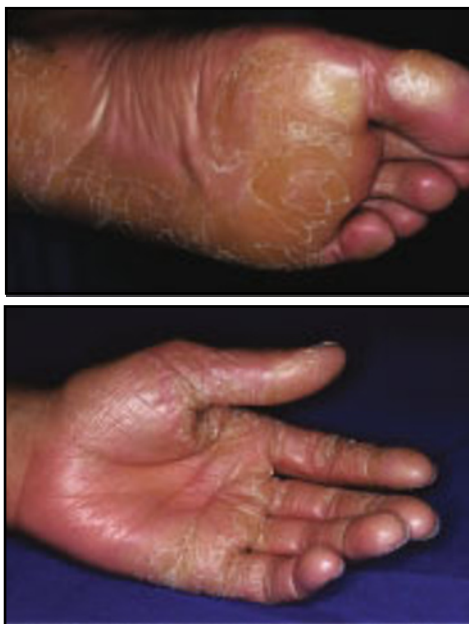In most paraneoplastic cases, the hyperkeratosis shows a cobblestone pattern with disruption of the dermatoglyphic palmar skin markings.<sup>[49]</sup> This is in contrast to hereditary diffuse hyperkeratosis, described as tylosis by Howel Evans et al.,<sup>[61]</sup> which is associated with esophageal cancer. Improvement in keratoderma following radiation therapy or surgical resection has confirmed the paraneoplastic nature of some cases of keratoderma.<sup>[54]</sup> Thus, development of acquired keratoderma should prompt consideration of a malignancy evaluation if no alternative etiology is identified.<sup>[50,53]</sup>

Acrokeratosis paraneoplastica, also known as Bazex syndrome, is associated with acquired PPK in the context of internal malignancy.<sup>[62-67]</sup> Bazex and Griffiths<sup>[62]</sup> first described the syndrome, which primarily affects men aged >40 years and is mainly associated with neoplasia of the upper aerodigestive tract. There have also been reports in the European literature of acrokeratosis paraneoplastica in patients with prostate carcinoma, primary squamous cell carcinoma of the leg, adenocarcinoma of the stomach, and squamous cell carcinoma of the vulvar region.<sup>[65,66]</sup> Three stages of the disorder have been described. The eruption starts as erythema and psoriasiform scaling on the fingers and toes, which spreads to the helices and nasal bridge, leading to violaceous erythema and pityriasiform scaling. Next, the eruption spreads to the palms and soles, producing keratoderma with a violaceous color, and giving the skin an edematous appearance with a honeycomb pattern. Finally, if the neoplasm has not been treated, the rash extends to the legs, knees, thighs, arms, and scalp. Histologically, there is mild acanthosis and hyperkeratosis with scattered parakeratotic foci. As Bazex syndrome can lead to painful paronychia and fissured keratoderma, etretinate may be used with some success in this setting. Symptomatic treatment occasionally

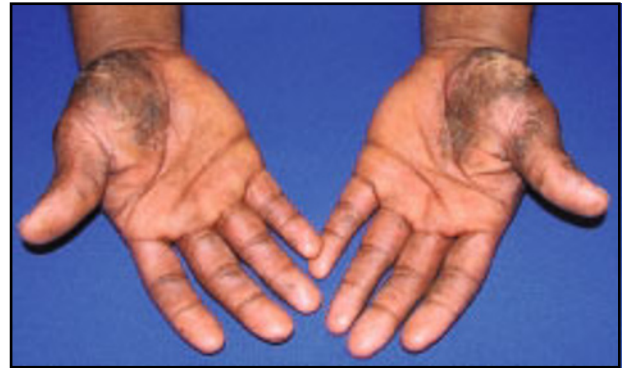results in improvement of the skin lesions, but removal of the tumor is the definitive treatment. The rash may reappear if the tumor recurs.<sup>[62-67]</sup>

Tripe palms was a term first introduced by Clarke<sup>[68]</sup> and later popularized by Breathnach and Wells<sup>[69]</sup> to denote a cutaneous paraneoplastic syndrome. The term refers to a distinctive form of palmar keratoderma with a thickened, moss-like or velvety texture characterized by exaggerated dermatoglyphics of the palmar surface of the hands and fingers. These skin findings are thought to resemble the lining of a cow stomach, which is called tripe.<sup>[70-72]</sup> Tripe palms have been reported to occur with or without acanthosis nigricans. An underlying malignancy is found in >90% of cases, regardless of the presence or absence of acanthosis nigricans.<sup>[72]</sup> Carcinomas of the lung and stomach are the most frequently observed neoplasms in patients with tripe palms; however, neoplasms of the brain, bladder, cervix, kidney, ovary, uterus, prostate, colon, gallbladder, pancreas, breast, tongue, larynx, skin (melanoma), and lymphatic system (non-Hodgkin lymphoma) have also been reported.<sup>[70-77]</sup> In nearly 75% of cases, tripe palms were diagnosed concurrently with or prior to the associated malignancy.<sup>[71]</sup> The findings typically improve, but may not resolve completely, following treatment of the underlying neoplasm.

As noted above, treatment of any identified underlying neoplasm is the treatment of choice for paraneoplastic keratodermas. In addition, etretinate treatment has been reported to be effective in the treatment of PPK in patients with widespread metastases, and acitretin could therefore be considered in recalcitrant cases or



**Fig. 4.** Pityriasis rubra pilaris.



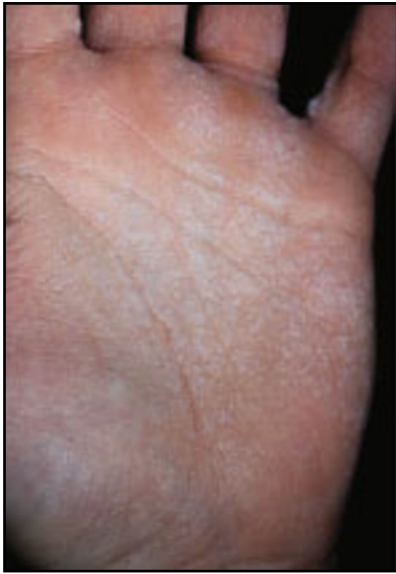**Fig. 5.** Acquired keratoderma caused by chronic cutaneous lupus erythematosus.

in cases in which the underlying neoplasm cannot be eradicated.<sup>[78,79,107]</sup>

## 7. PPK Due to Dermatoses

Numerous reactive and inflammatory dermatoses, including psoriasis, keratoderma blennorrhagica, pityriasis rubra pilaris, eczema, chronic hand dermatitis, lichen planus, lichen nitidus, lupus erythematosus, and aquagenic keratoderma, have been reported to cause palmar and/or plantar keratodermas.<sup>[1-3,80-86]</sup> In psoriasis, hyperkeratosis can be both diffuse and central. Findings such as nail pitting, depressed plaques on the sides of the fingers, involvement of the knuckles, and presence of typical plaques, together with biopsy results, may aid in making the correct diagnosis.<sup>[3,80-83]</sup> Reiter disease can present as keratoderma blennorrhagica in some cases, which appears as compact heaped-up lesions that resemble nail heads. Pityriasis rubra pilaris can present as thickening of the palms and soles with even, yellow hyperkeratosis, often described as having a 'carnuba wax' appearance (figure 4).<sup>[1-4]</sup> Chronic hand dermatitis can be difficult to distinguish from isolated PPK.<sup>[1-3]</sup> However, a history of exacerbating factors (i.e. work) and the presence of pruritus may suggest an eczematous etiology of PPK.<sup>[3]</sup> Lichen planus may present as a typical keratoderma with erythema and scale or as punctate keratoses with a warty texture and yellow hue, while lichen nitidus has presented with nail dystrophy and palmoplantar hyperkeratosis in one case.<sup>[1-3,84]</sup> Chronic cutaneous lupus erythematosus may present predominantly with palmar lesions and may be dry and atrophic or hypertrophic (figure 5).<sup>[3,85]</sup>

Finally, aquagenic PPK, first described by English and McCollough<sup>[86]</sup> in 1996, is a keratoderma characterized by burning and edema limited to the hands and feet after brief immersion in water. It was first reported in two sisters and was termed transient-reactive papulotranslucent acrokeratoderma because it resembled hereditary papulotranslucent acrokeratoderma. Onwukwe et al.<sup>[87]</sup>



**Fig. 6.** Aquagenic keratoderma.

first described this hereditary condition manifesting with persistent yellowish-white translucent papules and plaques that appear during puberty and are associated with fine-textured scalp hair and an atopic diathesis. Unlike hereditary papulotranslucent acrokeratoderma, acquired aquagenic PPK is transient, is not associated with fine scalp hair and atopic diathesis, and tends to respond to topical therapeutic interventions.<sup>[88]</sup> More than ten cases of aquagenic PPK have been reported in the literature, primarily involving younger females aged 9–33 years; however, most recently (in 2006), this condition has also been reported to occur in young males.<sup>[89,90]</sup> The keratoderma is characterized as transient, recurrent, bilateral and symmetric, mildly symptomatic, with translucent-to-whitish papules with central puncta (figure 6). The eruption disappears spontaneously within minutes to hours after drying of the palms.<sup>[86-95]</sup> The condition has also been associated with cystic fibrosis, and has been described in patients with the delta F508 mutation.<sup>[96,97]</sup> As such, cystic fibrosis should be considered in patients with aquagenic keratoderma, and patients with cystic fibrosis should be asked about symptoms of this condition. Avoiding water exposure in acral surfaces, aluminum chloride hexahydrate, and barrier agents containing petrolatum have been useful treatments.<sup>[86-101]</sup>

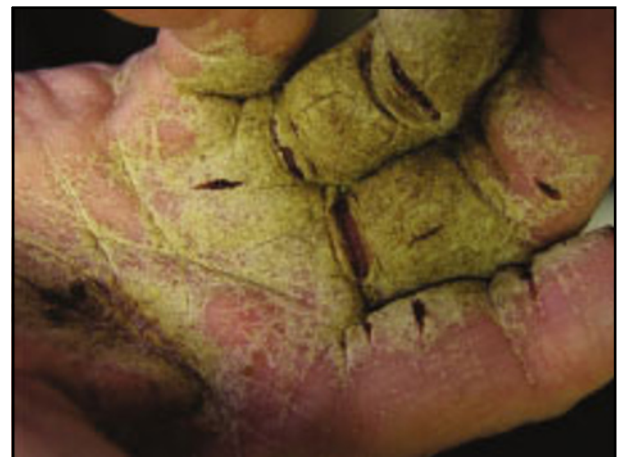## 8. PPK Caused by Infectious Agents

Infectious causes that may present as an acquired PPK include human papilloma virus, syphilis, encrusted scabies (figure 7), trichophytosis, leprosy, and tuberculosis.<sup>[1-3,103,104]</sup> Human papilloma virus infection, especially in the immunocompromised host, can appear as confluent verrucous masses on the palms and soles

that mimic PPK. In syphilis, secondary lesions classically involve the palms and soles and may manifest as either diffuse or focal hyperkeratosis. In encrusted scabies, lesions may begin as ordinary scabies but progress to become markedly hyperkeratotic and/or crusted on palmar surfaces.<sup>[2,3]</sup> Trichophytosis may also develop into prominent hyperkeratosis, primarily affecting the palms and soles.<sup>[2,3]</sup> Leprosy, because it affects peripheral nerves, can cause hand and feet contracture and may manifest as hyperkeratotic lesions and diffuse palmoplantar thickening.<sup>[2]</sup> Lastly, tuberculosis, especially miliary tuberculosis, has been described as presenting with palmar and plantar lesions with notable hyperkeratosis.<sup>[103,104]</sup>

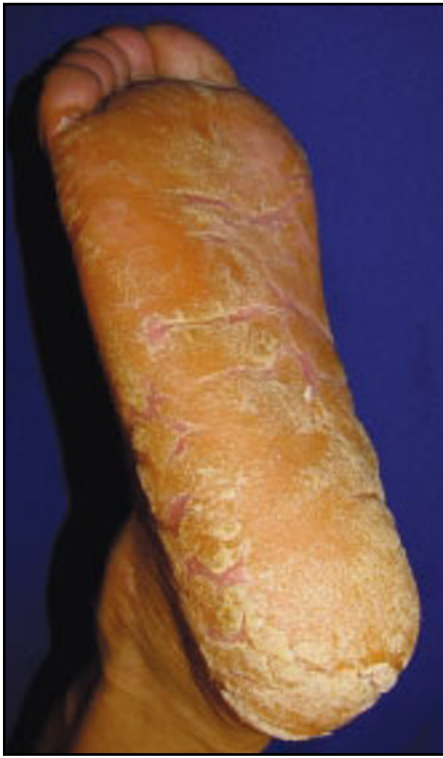## 9. Idiopathic Acquired PPK

Idiopathic acquired PPK should be reserved as a diagnosis of exclusion, when all other etiologies have been investigated and ruled out. They may present in any of the characteristic distributions, including diffuse, focal, and punctate. Idiopathic filiform parakeratotic PPK was described in a patient with no familial dermatologic conditions who developed thickening of his palms and soles over a 10-year period.<sup>[105]</sup> On examination, the patient had discrete filiform keratotic seed-like plugs on the volar surfaces of his palms and soles. Parakeratotic plugs were present on biopsy; however, the clinical and histologic features did not correlate with other forms of hereditary punctate keratoderma. The patient later developed bronchial carcinoma 10 years after the initial keratoderma development, so it remains unknown whether the keratoderma was idiopathic or a premalignant marker. It should be noted that palmoplantar filiform parakeratotic hyperkeratosis associated with digestive adenocarcinoma has also been reported.<sup>[106]</sup> Therefore, the diagnosis of idiopathic acquired PPK should be reserved for cases in which another cause cannot be determined (figure 8).



**Fig. 7.** Encrusted scabies.





**Fig. 8.** Idiopathic acquired palmoplantar keratoderma in a patient with no family history of keratoderma and no evidence of malignancy to date.

## 10. Conclusion

Acquired PPKs have been associated with a wide array of underlying etiologies, making the work-up of these patients challenging. The first step in the evaluation of these patients is to perform a complete skin examination and a comprehensive history and physical examination. Any findings that suggest underlying conditions should be aggressively evaluated and treated. If no pertinent findings are identified in the history and physical examination, laboratory and radiology studies should be undertaken in a systematic, logical fashion. This approach should reduce the likelihood of overlooking an underlying etiology and should minimize unnecessary, excessive tests. To this end, we present an algorithm for the assessment of patients presenting with acquired PPK (figure 1).

Generally, the most successful treatment strategy is to identify and treat the underlying etiology leading to PPK, as noted in sections 1–9. If no underlying etiology is found, conservative treatment options include topical keratolytics (urea, salicylic acid, lactic acid), repeated physical debridement, topical retinoids, topical psoralen plus UVA, and topical corticosteroids. In cases where the above measures fail, or as initial therapy in severe cases, acitretin is an effective alternative.

## Acknowledgment

No sources of funding were used to assist in the preparation of this review. The authors have no conflicts of interest that are directly relevant to the content of this review.

## References

1. Arnold Jr HL, Odom RB, James WD. *Andrews' diseases of the skin: clinical dermatology*. 8th ed. Philadelphia (PA): WB Saunders, 1990
2. Freedberg IM, Eisen AK, Wolff K, et al. *Fitzpatrick's dermatology in general medicine*. 6th ed. New York: McGraw-Hill, 2003
3. Champion RH, Burton JL, Burns DA, et al. *Rook, Wilkinson, Ebling textbook of dermatology*. 7th ed. Malden (MA): Blackwell Science Ltd, 2004: 34, 79-107
4. Bologna JL, Jorizzo JL, Rapini RP. *Dermatology*. New York: Mosby, 2003: 809-10
5. Stevens HP, Kelsell DP, Bryant SP, et al. Linkage of an American pedigree with palmoplantar keratoderma and malignancy (palmoplantar ectodermal dysplasia type III) to 17q24: literature survey and proposed updated classification of the keratodermas. *Arch Dermatol* 1996; 132: 640-51
6. Itin PH, Fistol SK. Palmoplantar keratodermas. *Clin Dermatol* 2005; 23: 15-22
7. Farmer ER, Hood AF. *Pathology of the skin*. 2nd ed. New York: McGraw-Hill, 1990: 143, 653-4
8. Weedon D. *Skin pathology*. 2nd ed. New York: Churchill Livingstone, 2002
9. McKee PH. *Pathology of the skin*. 2nd ed. Chicago (IL): Mosby-Wolfe, 1996
10. McCarthy L. *Histopathology of skin diseases*. St. Louis (MO): CV Mosby Company, 1931: 36-7, 96-8, 118-9
11. Elder D, Elenitsas R, Jaworsky, et al. *Lever's histopathology of the skin*. 8th ed. Philadelphia (PA): Lippincott-Raven, 1997
12. Barnhill RL, Busam KJ, Crowson AN, et al. *Textbook of dermatopathology*. New York: McGraw Hill, 1998: 287-8, 499
13. Haxthausen H. Keratoderma climactericum. *Br J Dermatol* 1934; 46: 161-7
14. Deschamps P, Leroy D, Pedailles S, et al. Keratoderma climactericum (Haxthausen's disease): clinical signs, laboratory findings and etretinate treatment in 10 patients. *Dermatologica* 1986; 172: 258-62
15. Lynch FW. Keratoderma climactericum (Haxthausen). *Arch Derm* 1943; 48: 270-81
16. Wathcel TJ. Plantar and palmar hyperkeratosis in young castrated women. *Int J Dermatol* 1981; 20: 270-1
17. Brincat M, Moniz CJ, Studd JW, et al. Long term effects of the menopause and sex hormones on skin thickness. *Br J Obstet Gynaecol* 1985; 92: 256-9
18. Shuster S, Black MM, McVitie E. The influence of age and sex on skin thickness, skin collagen and density. *Br J Dermatol* 1975; 93: 639-43
19. Zultak M, Bedeau C, Blanc D. Keratoderma climactericum treatment with topical estrogen. *Dermatologica* 1988; 176: 151-2
20. Sass U, Grosshans E, Simonart JM. Chronic arsenicism: criminal poisoning or drug-intoxication? *Dermatology* 1993; 186: 303-5
21. Poskitt LB, Duffill MB, Rademaker MR. Chloracne, palmoplantar keratoderma and localized scleroderma in a weed sprayer. *Clin Exp Dermatol* 1994; 19: 264-7
22. Shannon RS, Strayer DS. Arsenic induced skin toxicity. *Hum Toxicol* 1989; 8: 99-104
23. Rahman MM, Chowdhury UK, Mukherjee SC, et al. Chronic arsenic toxicity in Bangladesh and West Bengal, India: a review and commentary. *J Toxicol Clin Toxicol* 2001; 39 (7): 683-700
24. Tindall JP. Chloracne and chloracnogens. *J Am Acad Dermatol* 1985; 13: 539-58
25. Geusau A, Jurecka W, Nahavandi H, et al. Punctate keratoderma-like lesions on the palms and soles in a patient with chloracne: a new clinical manifestation of dioxin intoxication? *Br J Dermatol* 2000; 143 (5): 1067-71
26. Lee BY, Hogan DJ, Ursine S, et al. Personal observation of skin disorders in malnutrition. *Clin Dermatol* 2006; 24: 222-7
27. Duvic M, Reisman M, Finley V, et al. Glucan-induced keratoderma in acquired immunodeficiency syndrome. *Arch Dermatol* 1987; 123: 751-6
28. Albersheim P, Darvill AG. Oligosaccharins. *Sci Am* 1985; 253: 58-64
29. Jucgla A, Sais G, Navarro M, et al. Palmoplantar keratoderma secondary to chronic acral erythema due to tegafur. *Arch Dermatol* 1995; 131 (3): 364-5

30. Lambert D, Beer F, Gisselman R, et al. Cutaneous lesions due to lithium therapy. *Ann Dermatol Venereol* 1982; 109 (1): 19-24
31. Reiffers J, Dick P. Cutaneous side effects of treatment with lithium. *Dermatologica* 1977; 155 (3): 155-63
32. Dalle S, Becuwe C, Balme B, et al. Venlafaxine-associated psoriasiform palmoplantar keratoderma and subungual hyperkeratosis. *Br J Dermatol* 2006; 154: 999-1000
33. Tsuji T, Sawabe M. Hyperpigmentation in striae distensae after bleomycin treatment. *J Am Acad Dermatol* 1993; 3: 503-5
34. Blum RH, Carter SK, Agre K. A clinical review of bleomycin: a new antineoplastic agent. *Cancer* 1973; 31: 903-13
35. Branski EE, Ware RE, Prose NS, et al. Skin and nail changes in children with sickle cell anemia receiving hydroxyurea therapy. *J Am Acad Dermatol* 2001; 44: 859-61
36. Kennedy BJ, Smith LR, Goltz RW. Skin changes secondary to hydroxyurea therapy. *Arch Dermatol* 1975; 111: 183-7
37. Chaine B, Neonato MG, Girot R, et al. Cutaneous adverse reactions to hydroxyurea in patients with sickle cell disease. *Arch Dermatol* 2001; 137: 467-70
38. Burns DA, Sarkany I, Gaylarde P. Effects of hydroxyurea therapy on normal skin: a case report. *Clin Exp Dermatol* 1980; 5: 447-9
39. Major P. Verapamil as a cause of palmar hyperkeratosis. *Tidsskr Nor Laegeforen* 1983; 103: 2061
40. Bauer F. Quinacrine hydrochloride drug eruption (tropical lichenoid dermatitis). *J Am Acad Dermatol* 1981; 4: 239-48
41. Bauer F. Sequelae of Atabrine® dermatitis in Australian ex-servicemen. *Aust J Dermatol* 1962; 6: 311-9
42. Miller JJ, Roling D, Spiers E, et al. Palmoplantar keratoderma associated with hypothyroidism. *Br J Dermatol* 1998; 139: 741-2
43. Shaw WM, Mason EH, Kaltz EG. Hypothyroidism, liver damage and vitamin A deficiency as factors in hyperkeratosis. *Arch Dermatol Syph* 1952; 66: 197-203
44. Good JM, Neill SM, Rowland Payne CME, et al. Keratoderma of myxoedema. *Clin Exp Dermatol* 1988; 13: 339-41
45. Hodak E, David M, Feuerman EJ. Palmoplantar keratoderma in association with myxedema. *Acta Derm Venereol* 1986; 66: 354-7
46. Tan OT, Sarkany I. Severe palmar keratoderma in myxoedema. *Clin Exp Dermatol* 1977; 2: 287-8
47. Zouboulis CC, Biczko S, Gollnick H, et al. Elephantiasis nostras verrucosa: beneficial effect of oral tretinoin therapy. *Br J Dermatol* 1992; 127: 411-6
48. Parnell DD, Johnson SA. Tylosis palmaris et plantaris: its occurrence with internal malignancy. *Arch Dermatol* 1969; 100: 7-9
49. Millard LG, Gould DJ. Hyperkeratosis of the palms and soles associated with internal malignancy and elevated levels of immunoreactive human growth hormone. *Clin Exp Dermatol* 1976; 1: 363-8
50. Powell F, Mackey JP. Bronchial carcinoma and hyperkeratosis palmaris et plantaris. *Postgrad Med J* 1981; 57: 57-9
51. Cuzick J, Harris R, Mortimer PS. Palmar keratoses and cancers of the bladder and lung. *Lancet* 1984; I: 530-3
52. Murata Y, Kumano K, Tani M, et al. Acquired diffuse keratoderma of the palms and soles with bronchial carcinoma: report of a case and review of the literature. *Arch Dermatol* 1988; 124: 497-8
53. Kerdel FA, MacDonald DM. Palmo-plantar keratoderma associated with carcinoma of the bronchus. *Acta Dermato Venereol* 1982; 62 (2): 178-80
54. Khanna SK, Agnone FA, Leibowitz AI, et al. Nonfamilial diffuse palmoplantar keratoderma associated with bronchial carcinoma. *J Am Acad Dermatol* 1993; 28: 295-7
55. Murata I, Ogami Y, Nagai Y, et al. Carcinoma of the stomach with hyperkeratosis palmaris et plantaris and acanthosis of the esophagus. *Am J Gastroenterol* 1998; 93 (3): 449-51
56. Abadir R, Zurowski S. Case report: squamous cell carcinoma of the skin in both palms, axillary node, donor skin graft site and both soles: associated hyperkeratosis and porokeratosis. *Br J Radiol* 1994; 67: 507-10
57. Smith CH, Barker JN, Hay RJ. Diffuse plane xanthomatosis and acquired palmoplantar keratoderma in association with myeloma. *Br J Dermatol* 1995; 132: 286-9
58. Tomsick RS. Hyperkeratosis in mycosis fungoides. *Cutis* 1982; 29: 621-3
59. Taswell HF, Winkelman RK. Sézary syndrome: a malignant reticulocytic erythroderma. *JAMA* 1961; 177: 465-72
60. Fleischmajer R, Eisenberg S. Sézary's reticulosis: its relationship with neoplasias of the lymphoreticular system. *Arch Dermatol* 1964; 89: 9-19
61. Howel Evans W, McConnell RB, Clarke CA, et al. Carcinoma of the oesophagus with keratosis palmaris et plantaris (tylosis). *Q J Med* 1958; 27: 413-29
62. Bazex A, Griffiths A. Acrokeratosis paraneoplastica: a new cutaneous marker of malignancy. *Br J Dermatol* 1980; 102: 301-6
63. Pecora AL, Landsman L, Imgrund SP, et al. Acrokeratosis paraneoplastica (Bazex' syndrome). *Arch Dermatol* 1983; 119: 820-6
64. Jacobsen FK, Abildtrup N, Laursen SO, et al. Acrokeratosis paraneoplastica (Bazex' syndrome). *Ach Dermatol* 1984; 120: 502-4
65. Obasi OE, Garg SK. Bazex paraneoplastic acrokeratosis in prostate carcinoma. *Br J Dermatol* 1987; 117: 647-51
66. Hara M, Hunayama M, Aiba S, et al. Acrokeratosis paraneoplastica (Bazex syndrome) associated with primary cutaneous squamous cell carcinoma of the lower leg, vitiligo and alopecia areata. *Br J Dermatol* 1995; 133: 121-4
67. Martin RW, Cornitius TG, Naylor MF, et al. Bazex's syndrome in a woman with pulmonary adenocarcinoma. *Arch Dermatol* 1989; 125: 847-8
68. Clarke J. Malignant acanthosis nigricans. *Clin Exp Dermatol* 1977; 2: 167-70
69. Breathnach SM, Wells GC. Acanthosis palmaris: tripe palms: a distinctive pattern of palmar keratoderma frequently associated with internal malignancy. *Clin Exp Dermatol* 1980; 5: 181-9
70. Lo WL, Wong CK. Tripe palms: a significant cutaneous sign of internal malignancy. *Dermatology* 1992; 185: 151-3
71. Cohen PR, Kurzrock R. Malignancy associated tripe palms. *J Am Acad Dermatol* 1992; 27 (2): 271-2
72. Cohen PR, Grossman ME, Almeida L, et al. Tripe palms and malignancy. *J Clin Oncol* 1989; 7 (5): 669-78
73. Cohen PR, Grossman ME, Silvers DN, et al. Tripe palms and cancer. *Clin Dermatol* 1993; 11: 165-73
74. Patel A, Teixeira F, Redington AE. Palmoplantar keratoderma (tripe palms) associated with primary pulmonary adenocarcinoma. *Thorax* 2005; 60: 976
75. Pentenero M, Carozzo M, Pagano M, et al. Oral acanthosis nigricans, tripe palms and sign of Leser-Trélat in a patient with gastric adenocarcinoma. *Int J Dermatol* 2004; 43: 530-2
76. Kebria MM, Belinson J, Kim R, et al. Malignant acanthosis nigricans, tripe palms and the sign of Leser-Trélat, a hint to the diagnosis of early stage ovarian cancer: a case report and review of the literature. *Gynecol Oncol* 2006; 101: 353-5
77. McGinness J, Greer K. Malignant acanthosis nigricans and tripe palms associated with pancreatic adenocarcinoma. *Cutis* 2006; 78 (1): 37-40
78. Berardesca E, del Forno C, Vignini M. Usefulness of tretinoin treatment in paraneoplastic palmoplantar hyperkeratosis [letter]. *Br J Dermatol* 1987; 117 (1): 132
79. Marks R, Finlay AY, Holt PJA. Severe disorders of keratinization: effects of treatment with Tigason (tretinoin). *Br J Dermatol* 1981; 104: 667-73
80. Kumar B, Kaur I, Thami GP. Plantar psoriasis: clinical correlation of lesion pattern to weight bearing. *Acta Derm Venereol* 1995; 75: 157-8
81. Rai R, Saraswat A, Kaur I, et al. Marginal acrokeratoderma and psoriasis: is there an association? *Int J Dermatol* 2000; 39: 936-9
82. Farber EM, Nall L. Nonpustular palmoplantar psoriasis. *Cutis* 1992; 50: 407-10
83. Kumar B, Saraswat A, Inderjeet K. Palmoplantar lesions in psoriasis: A study of 3065 patients. *Acta Derm Venereol* 2002; 82: 192-5
84. Munro CS, Cox NH, Marks JM, et al. Lichen nitidus presenting as palmoplantar hyperkeratosis and nail dystrophy. *Clin Exp Dermatol* 1993; 18: 381-3
85. Ashinoff R, Werth VP, Franks AG. Resistant discoid lupus erythematosus of palms and soles: successful treatment with azathioprine. *J Am Acad Dermatol* 1988; 19: 961-5
86. English JC, McCollough ML. Transient reactive papulotranslucent acrokeratoderma. *J Am Acad Dermatol* 1996; 34: 686-7
87. Onwukwe MF, Mihm Jr MC, Toda K. Hereditary papulotranslucent acrokeratoderma: a new variant of familial punctate keratoderma? *Arch Dermatol* 1973; 108: 108-10
88. Yan AC, Aasi SZ, Alms WJ, et al. Aquagenic palmoplantar keratoderma. *J Am Acad Dermatol* 2001; 44: 696-9
89. Neri I, Bianchi F, Patrizi A. Transient aquagenic palmar hyperwrinkling: the first instance reported in a young boy. *Pediatr Dermatol* 2006; 23 (1): 39-42

90. Baldwin BT, Prakash A, Fenske NA, et al. Aquagenic syringeal acrokeratoderma: report of a case with histologic findings. *J Am Acad Dermatol* 2006; 54 (5): 899-902
91. Lowes MA, Khaira GS, Holt D. Transient reactive papulotranslucent acrokeratoderma associated with cystic fibrosis. *Aust J Dermatol* 2000; 41: 172-4
92. MacCormack MA, Wiss K, Malhotra R. Aquagenic syringeal acrokeratoderma: report of two teenage cases. *J Am Acad Dermatol* 2001; 45: 124-6
93. Itin PH, Lautenschlager S. Aquagenic syringeal acrokeratoderma (transient reactive papulotranslucent acrokeratoderma). *Dermatology* 2002; 204: 8-11
94. Betlloch I, Vergara G, Albares MP, et al. Aquagenic keratoderma. *J Eur Acad Dermatol Venereol* 2003; 17: 306-7
95. Schmults C, Sidhu G, Urbaneck W. Aquagenic syringeal acrokeratoderma. *Dermatol Online J* 2003; 9: 27
96. Johns MK. Skin wrinkling in cystic fibrosis. *Med Biol Illustr* 1975; 25: 205-10
97. Katz KA, Yan AC, Turner ML. Aquagenic wrinkling of the palms in patients with cystic fibrosis homozygous for the delta F508 CFTR mutation. *Arch Dermatol* 2005; 141 (5): 621-4
98. Carder KR, Weston WL. Rofecoxib-induced instant aquagenic wrinkling of the palms. *Pediatr Dermatol* 2002; 19: 353-5
99. Yalcin B, Artuz F, Toy GG, et al. Acquired aquagenic papulotranslucent acrokeratoderma. *J Eur Acad Dermatol Venereol* 2005; 19 (5): 654-6
100. Heymann WR. Hereditary papulotranslucent acrokeratoderma. *Cutis* 1998; 61: 29-30
101. Wilder-Smith EP, Chow A. Water immersion wrinkling is due to vasoconstriction. *Muscle Nerve* 2003; 27: 307-11
102. Mikhail GR, Babel D. Trichophyton rubrum infection and keratoderma palmaris et plantaris. *Arch Derm* 1981; 117 (11): 753-4
103. Premalatha S, Augustine SM, Yesudian P, et al. Punctate palmoplantar keratosis acuminata: an unusual form of tuberculid. *Int J Dermatol* 1982; 21: 470-1
104. Mehlmauer MA. Keratotic papules and nodules and hyperkeratosis of palms and soles in patients with tuberculosis and AIDS-related complex. *J Am Acad Dermatol* 1990; 23: 381-5
105. Herman PS. Punctate porokeratotic keratoderma. *Dermatologica* 1973; 147: 206-13
106. Rault S, Salmon Ehr V, Cambie MP, et al. Palmoplantar filiform parakeratotic hyperkeratosis and digestive adenocarcinoma. *Ann Dermatol Venereol* 1997; 124 (10): 707-9
107. Wishart JM. Bazex paraneoplastic acrokeratosis: a case report and response to Tigason. *Br J Dermatol* 1986; 115: 595-9

---

Correspondence and offprints: Dr *Joseph C. English, III*, Department of Dermatology, University of Pittsburgh, 190 Lothrop Street, Suite 145 Lothrop Hall, Pittsburgh, PA 15213, USA.  
E-mail: englishjc@upmc.edu