



## Tungiasis and myiasis

Tania F. Cestari, MD<sup>a,\*</sup>, Simone Pessato, MD<sup>a</sup>, Marcia Ramos-e-Silva, MD<sup>b</sup>

<sup>a</sup>Department of Dermatology, Hospital Clinicas Porto Alegre, R Ramiro Barcellos 2350, Zone 13, Porto Alegre RS, 90035-003, Brazil

<sup>b</sup>Department of Dermatology, School of Medicine, University of Rio de Janeiro, Rio de Janeiro, Brazil

**Abstract** Tungiasis and myiasis are common ectoparasitic infestations that occur in developing countries in the tropics, particularly where poverty and poor standards of basic hygiene exist. The growth in international travel to and from these regions has led to an increase in the presentation of these conditions in nonendemic countries. Despite recent progress in the treatment and prevention of tungiasis and myiasis, diagnosis can present a challenge to those unfamiliar with these conditions, especially when they present in nonendemic countries. Tungiasis is caused by the penetration of the female sand flea, *Tunga penetrans*, into the epidermis of the host. Myiasis is a parasitic infection of the skin and mucous membranes in which the larvae of Diptera insects penetrate healthy or altered skin depending on the species. Infestations are usually self-limited and present few complications. Social neglect and inadequate health behavior in economically depressed urban neighborhoods, however, may lead to secondary infections and complications.

© 2007 Elsevier Inc. All rights reserved.

### Introduction

Dermatologic manifestations are among the most common complaints of travelers visiting tropical reserves, and the increase of international travel with the growth of the ecotourism industry has led to a marked rise in the reported incidence of parasitic infestations that were formerly restrained to specific regions.<sup>1</sup> Such diagnoses should be considered whenever the history includes venture into potentially endemic regions.<sup>2-5</sup>

### Tungiasis

#### Definition

Tungiasis is an ectoparasitic disease caused by the penetration of the female sand flea, *Tunga penetrans*, into the epidermis of the host. It is known by several popular

designations, including *chigoe flea*, *jigger flea*, *pico*, *chique*, *piroque*, *nigua* (Mexico, Caribbean islands, Peru), *pique* (Argentina), *bicho dos pés*, *pulga de porco*, *pulga da areia* (Brazil), *moukardan* (Sudan), *puce chique*, *ogri eye*, *kuti*, *suthi-pique*, *sikka*, *chica*, and *piqui* (South America).<sup>6-8</sup>

#### Epidemiology

The sand flea *T penetrans* is one of the few parasites that has spread from the western to the eastern hemisphere.<sup>8,9</sup> This ectoparasite originally existed only on the American continent and came to Angola with the sand carried by travelers from Brazil. Within a few decades, it spread from Angola to sub-Saharan Africa, East Africa, and Madagascar. Today, tungiasis is endemic in many countries in Latin America (from Mexico to northern Argentina), in the Caribbean islands, and in sub-Saharan Africa.<sup>8,9</sup> Prevalence rates in human populations range from 21% to 83%, the higher rates being reported in some communities of Brazil, Nigeria, and Trinidad and Tobago.<sup>10-13</sup>

\* Corresponding author. Fax: +55 51 33462773.  
 E-mail address: tcestari@terra.com.br (T.F. Cestari).

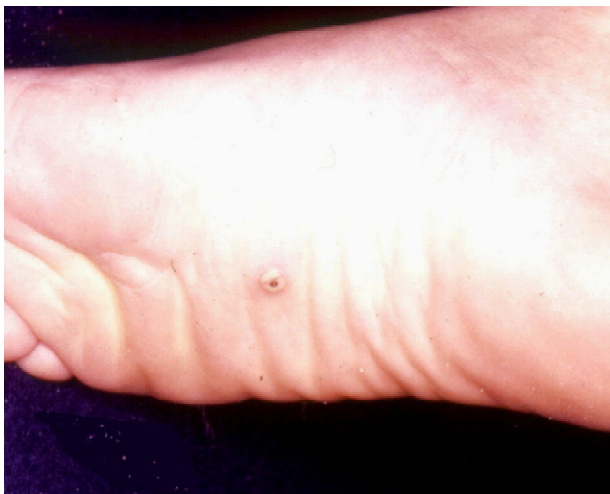In nonendemic areas, tungiasis is rare and usually appears on travelers returning from endemic areas. It has been documented in numerous countries, mainly in Europe, because of tourism to tropical and subtropical regions.<sup>6,14-17</sup> There are isolated reports of infection acquired in non-endemic countries, most likely by fleas that were imported and completed their free-living life cycle at sites such as sandy beaches on the Mediterranean Coast.<sup>8,18</sup>

Tungiasis is typically a disease of adults. Considering the thinness of their stratum corneum and epidermis, children ought to be more susceptible; however, this ectoparasitosis is rarely reported in children living in non-endemic regions.<sup>14,19</sup>

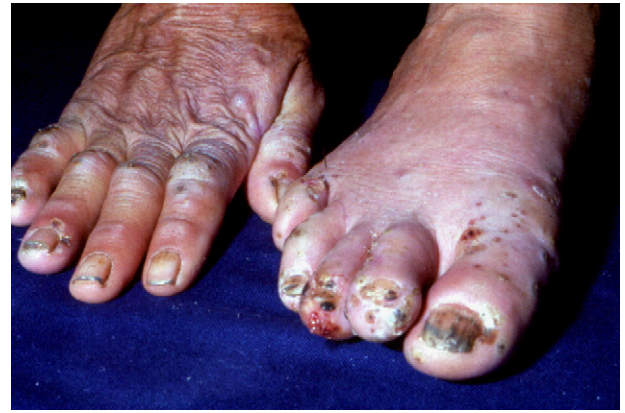## Etiology

*T penetrans* is the smallest flea, measuring around 1 mm in length, and is the only species of the genus that affect humans. On soft skin, the parasite moves at a speed of up to 1 cm/s and it is also able to jump vertically to a height of about 20 cm.<sup>20</sup> It thrives best in warm sandy soils, especially near pigsties, stables, and other animal housing. Male and female *T penetrans* are bloodsuckers, but the male leaves its host after feeding, whereas the female burrows into soft skin regions of the body. Here, it remains for up to 5 weeks, during which it matures, produces, and releases eggs, before finally dying.<sup>20</sup> Besides humans, various animals (all domestic or wild mammals) may act as hosts for *T penetrans*.<sup>8,10,21</sup> Investigating the animal reservoirs and the prevalence of the tungiasis in the human population, Heulkelbach et al<sup>10</sup> found that dogs, cats, and rats (but not mice) harbor *T penetrans* at prevalence rates comparable with those of humans in Brazil.

Tungiasis occurs in underdeveloped communities in the rural hinterland, in secluded fishing villages along the coast, and in the slums of urban centers. The seasonal variation of



**Fig. 1** Tungiasis—isolated lesion on the lateral feet that corresponds to the parasite's maximum growing stage and that is presented as a white nodule with a central opening.



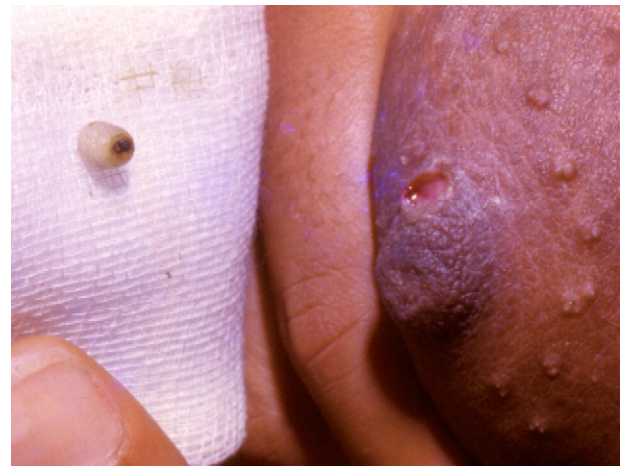**Fig. 2** Tungiasis—massive infestation of hand and feet in a cattle handler. (Courtesy: Dermatology Service, Santa Casa de Misericórdia, Porto Alegre, Brazil).

tungiasis in endemic communities shows a peak incidence between August and September, which corresponds to the peak of the dry season in the tropical southern hemisphere.<sup>9,18</sup>

## Clinical manifestations

Areas of soft skin, such as the space between toes, under toenails, and along the medial border of the feet, are the favored sites for flea embedding (Figs. 1-3). Occasionally, genital and perianal regions, thighs, hands, and other areas may be affected, especially in cases where there is extensive disease.<sup>7,13,17,19-21</sup>

The female flea burrows into the skin of its host, starting a complex 5-stage sequence of structural and morphological changes. The cycle is accompanied by different degrees of inflammatory reaction, known as the *Fortaleza classification*.<sup>22,23</sup> The first stage corresponds to the penetration of the gravid flea, achieved at an angle of 45° to 90° and taking 30 minutes to 7 hours to be completed (average of 3 hours). During this period, the second and third abdominal segment



**Fig. 3** Tungiasis—ectopic tungiasis occurring in the breast and the removed parasite. (Courtesy: Dermatology Service, Santa Casa de Misericórdia, Porto Alegre, Brazil).

of the parasite separate toward the cephalic direction. The penetration is perceived by the host as a mild stink, and clinically manifested as a tiny reddish spot. After 1 or 2 days, the abdominal segment enlarges and the parasite is visible as an itchy painful nodule with a central black dot, surrounded by an erythematous inflammatory area (beginning hypertrophy or second phase). The third stage starts 4 days after penetration and corresponds to the maximum growth of the parasite (white halo phase). The lesion resembles a white pearl with a central opening from which the enlarged flea eliminates feces and eggs. A painful foreign body sensation is commonly perceived by the host.<sup>24</sup> The fourth stage begins 3 to 4 weeks after the penetration and corresponds to the involution phase, characterized by a dark crust containing the parasite remains. The lesions may be numerous and close-set like a honeycomb. Secondary infection is frequently present. The last stage (fifth stage) corresponds to the residual scar.

### Treatment and control

Tungiasis is usually a self-limited condition with few complications consequent to the infestation. In economically depressed urban neighborhoods, however, poor housing conditions and inadequate healthcare lead to a high transmission potential, resulting in high parasite loads and secondary complications.<sup>24,25</sup> Typical complications of extensive tungiasis are atrophy or loss of nails, toe deformations, difficulty in walking and gripping, and lymphadenopathy.<sup>22,24</sup> Secondary infection is very common in tungiasis. Early antibiotic treatment is indicated as the spread of pathogenic bacteria that may lead to abscess formation, lymphangitis, sepsis, tissue necrosis or gangrene, erysipelas, or even contamination by agents causing deep mycosis.<sup>12,25</sup> Clinical and epidemiological evidence suggests that in populations with low vaccination coverage, untreated tungiasis is a risk factor for tetanus.<sup>25,26</sup>

Standard therapy for tungiasis consists of surgical extraction of the embedded parasite under sterile condition, followed by appropriate care of the resulting wound.<sup>8,15,24</sup> Topical application of kerosene, plant extracts, chlorophenothane, chloroform, 4% formaldehyde solution, turpentine, and yellow mercury oxide has been used, but without any controlled study.<sup>7,9</sup> Chemotherapeutic approaches to attempt to kill embedded fleas without mechanical extraction include administration of oral niridazole,<sup>27</sup> thiabendazole,<sup>28</sup> and ivermectin,<sup>29</sup> none of them completely effective.

Superinfection of the lesions may lead to pustule formation, suppuration, and ulceration.<sup>25</sup> In these cases, oral antibiotics should be prescribed and appropriate local care administered. Tetanus prophylaxis is recommended, especially for those individuals living in endemic areas.

Prevention of tungiasis is achieved by paving of public areas and house floors, and by implementing basic hygiene measures. Animals living close to humans should also be treated using insecticidal compounds, such as collars, sprays, shampoos, or topical products.<sup>10,13</sup> The early and

late stages of the flea may be eliminated by spraying environmental insecticide on sandy areas, beaches, and close to animal housing facilities.<sup>9,10</sup> Biologic repellents, composed by coconut and jojoba oils (Zanzarin), may be recommended.<sup>30</sup> Sanitary disposal of domestic garbage, proper vector control, housing of animals, wearing of protective shoes, and periodic self-examination in endemic areas are also mandatory.

## Myiasis

### Definition

Myiasis is a parasitic infection of the skin and mucous membranes determined by the larvae of Diptera insects. Many species of Diptera may cause larval infection in humans. Disease determined by those insects may be classified according to their localization, the tissue or organ that is involved, the larval or vector feeding behavior, and entomology.

### Etiology

Myiasis may be categorized as cutaneous, subcutaneous, or cavitory, according to localization of the embedded larvae. The most widely used classification scheme, however, divides myiasis into 3 types, according to the causative agent and pathogenic behavior: (i) primary (or obligatory), (ii) facultative, and (iii) accidental.<sup>31,32</sup>

In the primary myiasis, the larva is an obligatory parasite that invades and completes its development inside healthy tissue of the host. It comprises *migratory myiasis*, caused by larvae belonging to the genera *Gasterophilus* and *Hypoderma*, parasites of cattle and horses; and *furunculoid* or *furuncular myiasis*, which has as the main causal agents *Dermatobia hominis*, *Callitroga americana* (*Cochliomyia hominivorax*), *Cordylobia anthropophaga*, and *Oestrus ovis*.<sup>32,33</sup> During the biologic cycle of *Dermatobia* spp, the females lay their eggs on the abdomen of blood-sucking hemophagous insects, especially mosquitoes. When the carrier insect feeds, warmth stimulates the attached eggs to hatch, producing larvae that penetrate the bite puncture site or the intact skin of the host. Once embedded within the human host, the larvae undergo a metamorphosis that may take 7 to 15 weeks to completion. Once mature, the end-stage larvae extricate itself from the host and pupates on the ground (Fig. 4).<sup>31,34,35</sup> *C. anthropophaga* (tumbu fly) deposits its eggs on moist clothes, on blankets, or on the sand where larvae can survive for up to 15 days without feeding. Once in contact with the host, however, it penetrates its tegument, completing the life cycle.<sup>36</sup>

In the secondary myiasis, the female fly is attracted to and lays its eggs directly on inadequately cared-for open ulcers or wounded skin and/or mucosa. Eggs are laid at the edge of ulcers from where the second-stage larvae penetrates living tissues, feeding on necrotic debris or decom-

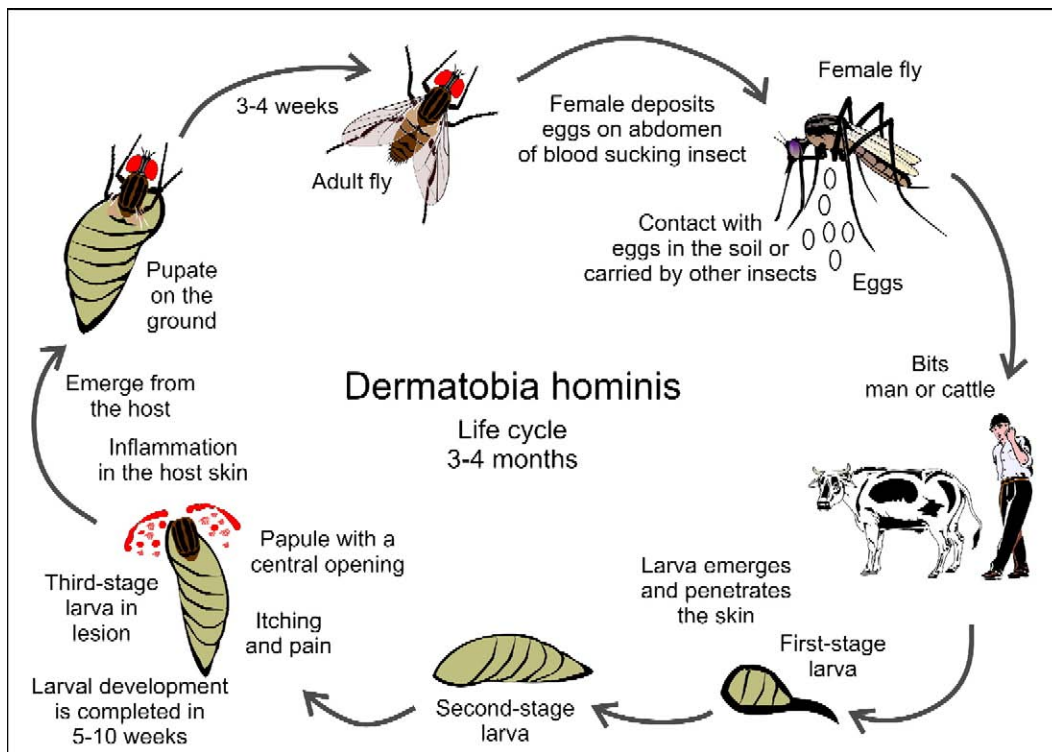


Fig. 4 Life cycle of *D hominis*.

posing flesh.<sup>32,37,38</sup> Sometimes, maggots penetrate natural cavities and even the navel of infants. *Calliphora* spp, *Musca* spp, and *Lucilia sarcophagidae* flies most frequently determine this type of infection.

The ingestion of *Sarcophaga*-contaminated food or drink may also cause accidental intestinal myiasis.<sup>32,33</sup>

### Epidemiology

Myiasis is more prevalent in humid tropical and subtropical regions where many species of flies are natural inhabitants. *D hominis*, a human bot fly found at the edge of tropical forests in Central and South America, causes primary or furunculoid myiasis. The infection is frequently observed in regions located between latitudes 25° and 32° south.<sup>31,39</sup> In the Caribbean islands, it has only been reported in Trinidad but is endemic at the southeast area of Mexico.<sup>34</sup> The main reservoirs of this infection are rodents and larger mammals. Cattle, horses, and pigs are the most frequent hosts in rural areas and perpetuate the infestation, humans being accidental hosts.<sup>32,33</sup> Furunculoid myiasis is common in children, especially in those living in rural and endemic areas. Frequent entomological inoculation by blood-sucking insects, poor hygiene, culinary habits, religious rites, mental or psychiatric disturbance, diabetes, and immune depression predispose to myiasis.<sup>33</sup> Reported incidence rates are increasing among individuals from nonendemic countries who have traveled to tropical destinations or practice outdoor activities.<sup>34,40,41</sup>

Tumbu fly is endemic in South Africa, but isolated cases have been reported in Europe in returning travelers and even in persons who acquired the parasite after contact with contaminated clothing or objects.<sup>32,42</sup>

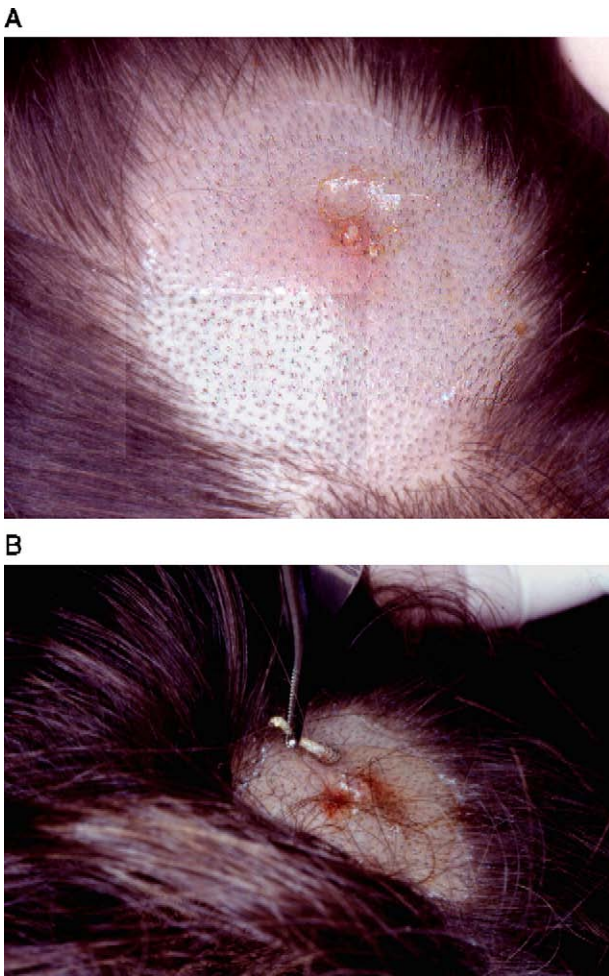
Secondary myiasis is usually caused by *Callitroga* spp, *Cochliomyia macellaria*, or *Lucilia* spp. It is widely reported and usually develops as a result of inadequate care of tumoral or ulcerated lesions.<sup>33,38</sup>

### Clinical aspects

Clinical manifestations of myiasis are variable depending upon the causative agent, the pathophysiology, and the affected site.<sup>33</sup> It has been described in almost all parts of the body, including the gastrointestinal tract, tracheopulmonary tree, urinary tracts,<sup>43,44</sup> eyes,<sup>45</sup> genitalia,<sup>46-48</sup> and breasts.<sup>42,49</sup> Infestation caused by *D hominis*, however, clearly predominates on the exposed areas of the skin, whereas the larvae of *C anthropophaga* are more likely to affect the trunk, buttocks, and thighs.<sup>33,40,50</sup>

Single inflammatory edematous nodules characterize the furunculoid myiasis. The boillike lesions usually present an apical orifice that exude a serous secretion when squeezed (Fig. 5A and B).<sup>34</sup> An intermittent slight movement and occasional bubbling may be noted from the lesional orifice.

Symptoms are variable. Sporadic itching, irritation, and pain are caused by activity and biting of the larva and/or the chemical irritation produced by its fomites. Lesions are more common on the scalp and exposed areas, but larvae



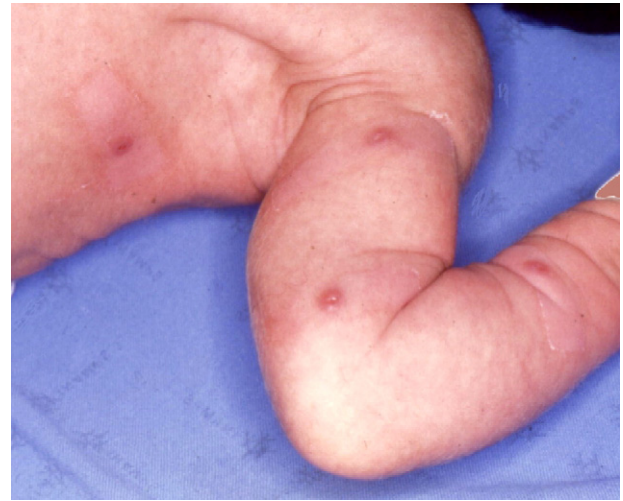**Fig. 5** A, Furunculoid myiasis—nodular inflammatory lesion in the scalp showing the central opening. B, Furunculoid myiasis—the same patient after removing the larva, with its anchoring spines in concentric circles.

can penetrate clothes and, therefore, may affect any part of the body. Complications include secondary infection leading to abscess formation and cellulitis.

Myiasis may occur at any age. Cases of neonatal fatal cerebral myiasis, caused by the penetration of larva through the fibrous portion of the fontanel, have been reported (Fig. 6).<sup>51</sup>

The diagnosis of cutaneous myiasis should be considered when examining a furuncular lesion in individuals who have visited endemic regions. Diagnosis is usually straightforward when the patient presents with typical symptoms. Myiasis, however, can mimic other inflammatory skin disorders such as furunculosis, sebaceous cysts, and tumor.<sup>49,52,53</sup> Doppler ultrasound may be useful to confirm the diagnosis in cases where there is doubt, and it is reported to be 100% sensitive even for lesions that are small or deeply located.<sup>34</sup>

Larvae that feed on organic decaying matter and “accidentally” infect preexisting ulcers, tumors, and necrotic or infected lesions are said to cause cavitary or secondary myiasis (Fig. 7). Maggots are usually noticed by virtue of



**Fig. 6** Furunculoid myiasis—multiple infection by *D hominis* larvae in a 28-day-old neonate.

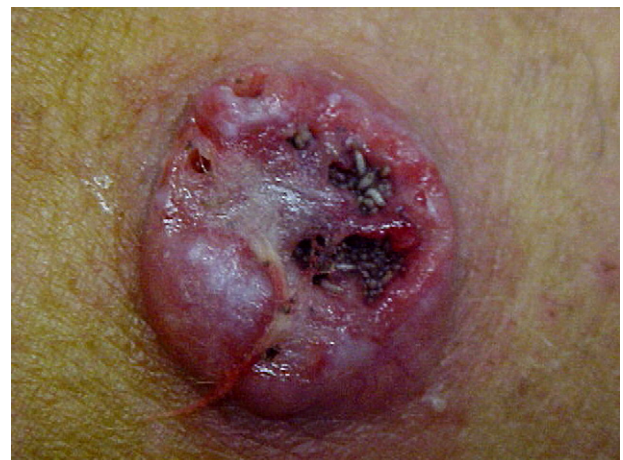their movement, bad odor, and discharge. Larvae uncommonly adhere to and enter natural cavities such as the nose, ears, eyes, mouth, and anus.<sup>32,38</sup> Symptoms of nasal myiasis include epistaxis and a local burning sensation. Rarely, complications such as meningitis, sinusitis, and pharyngitis ensue. Ocular myiasis may affect the conjunctiva and eyelids or even compromise deeper structures of the orbit.<sup>45,54</sup> Auricular and vaginal myiasis is also well reported.<sup>32,46</sup>

Larvae migrating to the gastrointestinal will frequently mimic the symptoms of intestinal parasites, whereas migration of larvae into the bladder via the urethra may mimic urinary tract infection.<sup>33</sup>

## Treatment

### Primary or furunculoid myiasis

The simplest form of treatment is to occlude the larval respiratory orifice using an occlusive agent. Commonly used substances include liquid paraffin, petrolatum, wax, resins, glue, adhesive tape, nail polish, chewing gum, and



**Fig. 7** Cavitary myiasis—epidermoid carcinoma with areas of hyperplasia and ulceration invaded by numerous maggots.

even strips of pork fat.<sup>31,34,55</sup> Occlusion of the respiratory apparatus will cause the larva to emerge for oxygen. It can then be easily removed with a pair of tweezers using slight lateral compression. Chloroform, ether, lidocaine, or pilocarpine can be instilled into the tunnel to paralyze the larva to facilitate the removal.<sup>56-59</sup> Surgical removal, using a cruciate incision, may be necessary if there is a high larval load or when requested by the patient.<sup>31,35,60</sup>

### Secondary or cavitatory myiasis

Treatment of secondary or cavitatory myiasis is directed at removing the larvae—a painful and cumbersome task, particularly when deep-seated larvae are firmly embedded in smaller cavities. Ether, chloroform, and rapid passes of liquid nitrogen can be used topically to facilitate the removal of superficial maggots.<sup>37</sup> Topical or oral ivermectin is a safe and effective option that has been successfully used to treat lesions that are located in difficult-to-reach sites.<sup>31,61-63</sup>

### References

- Steffen R, Rickenbach M, Wilhelm U, Helminger A, Schar M. Health problems after travel to developing countries. *J Infect Dis* 1987; 1156:84-91.
- Caumes E, Carriere J, Guernonprez G, Bricaire F, Danis M, Gentilini M. Dermatoses associated with travel to tropical countries: a prospective study of the diagnosis and management of 269 patients presenting to a tropical disease unit. *Clin Infect Dis* 1995;20:542-8.
- Frieling U, Nashed D, Metz D. Cutaneous myiasis: a vacation souvenir. *Hautarzt* 1999;50:203-7.
- Desruelles F, Delaunay P, Marty P, et al. Myiasis caused by *Dermatobia hominis* after an organized tour to Amazonia. *Presse Med* 1999;28:2223-5.
- Wilson ME, Chen LH. Dermatologic infectious diseases in international travelers. *Curr Infect Dis Rep* 2004;6:54-62.
- Grunwald MH, Shai A, Mosovich B, Avinoach I. Tungiasis. *Australas J Dermatol* 2000;41:46-7.
- Shatin H, Canizares O. Dermatoses caused by arthropods. In: Canizares O, Harman RRM, editors. *Clinical tropical dermatology*. Oxford (UK): Blackwell Scientific Publications; 1992. p. 392-4.
- Heukelbach J. Tungiasis. *Orphanet Encyclopedia*. Sep 2004. <http://www.orpha.net/data/patho/GB/uk-Tungiasis.pdf> [last access Nov 21 2005].
- Heukelbach J, Oliveira FAZ, Hesse G, Feldmeier H. Tungiasis: a neglected health problem of poor communities. *Trop Med Int Health* 2001;6:267-72.
- Heukelbach J, Costa AML, Wilcke T, Mencke N, Feldmeier H. The animal reservoir of *Tunga penetrans* in severely affected communities of north-east Brazil. *Med Vet Entomol* 2004;18:329-35.
- Ejezie GC. The parasitic diseases of school children in Lagos State, Nigeria. *Acta Trop* 1981;38:79-84.
- Chadee DD. Distribution patterns of *Tunga penetrans* within a community in Trinidad, West Indies. *J Trop Med Hyg* 1994;97:167-70.
- Heukelbach J, Mencke N, Feldmeier H. Cutaneous larva migrans and tungiasis: the challenge to control zoonotic ectoparasitosis associated with poverty. *Trop Med Int Health* 2002;7:907-10.
- Fein H, Naseem S, Witte DP, Garcia VF, Lucky A, Staat MA. Tungiasis in North America: a report of 2 cases in internationally adopted children. *J Pediatr* 2001;139:744-6.
- Brane S, Adams B, Bazemore A. Tungiasis in the returning traveler. *J Am Acad Dermatol* 2005;52:1105-6.
- Sanusi D, Brown E, Shepard T, Grafton W. Tungiasis: report of one case and review of the 14 reported cases in the United States. *J Am Acad Dermatol* 1989;20:941-4.
- Veraldi S, Carrera C, Schianchi R. Tungiasis has reached Europe. *Dermatology* 2000;201:382.
- Heukelbach J, Wilcke T, Harms G, Feldmeier H. Seasonal variation of tungiasis in an endemic community. *Am J Trop Med Hyg* 2005; 72:145-9.
- Gelmetti C, Carrera C, Veraldi S. Tungiasis in a 3-year-old child. *Pediatr Dermatol* 2000;17:293-5.
- Heukelbach J, Wilcke T, Eisele M, Feldmeier H. Ectopic localization of tungiasis. *Am J Trop Med Hyg* 2002;67:214-6.
- Raimundo WC, Almeida AB, Barbosa-Silva SC, Amorim M, Ribeiro PC, Serra-Freire NM. The pattern of tungiasis in Araruama Township, state of Rio de Janeiro, Brazil. *Mem Inst Oswaldo Cruz* 2003;98:31-6.
- Eisele M, Heukelbach J, Marck EV, et al. Investigations on the biology, epidemiology, pathology and control of *Tunga penetrans* in Brazil: I. Natural history of tungiasis in man. *Parasitol Res* 2003;90:87-99.
- Feldmeier H, Heukelbach J, Eisele M, Ribeiro R, Hams G, Mehlhorn H. Investigations on the biology, epidemiology, pathology and control of *Tunga penetrans* in Brazil: cytokine levels in peripheral blood of infected humans. *Parasitol Res* 2003;91:298-303.
- Feldmeier H, Eisele M, Van Marck E, Mehlhorn H, Ribeiro R, Heukelbach J. Investigations on the biology, epidemiology, pathology and control of *Tunga penetrans* in Brazil: clinical and histopathology. *Parasitol Res* 2004;94:275-82.
- Feldmeier H, Heukelbach J, Eisele M, Souza AQ, Barbosa LMM, Carvalho CBM. Bacterial superinfection in human tungiasis. *Trop Med Int Health* 2002;7:559-64.
- Feldmeier H, Eisele M, Saboia-Moura RC, Heukelbach J. Severe tungiasis in underprivileged communities: case series from Brazil. *Emerg Infect Dis* 2003;9:949-55.
- Ade-Serrano MA, Olomolehin OG, Adewunmi A. Treatment of human tungiasis with niridazole (Ambilhar): a double blind placebo-controlled trial. *Ann Trop Med Parasitol* 1982;76:89-92.
- Cardoso A. Generalized tungiasis treated with thiabendazole. *Arch Dermatol* 1981;117:127.
- Heukelbach J, Frank S, Feldmeier H. Therapy of tungiasis: a double randomized controlled trial with oral ivermectin. *Mem Inst Oswaldo Cruz* 2004;99:873-6.
- Schwalfenberg S, Witt LH, Kehr JD, Feldmeier H, Heukelbach J. Prevention of tungiasis using a biological repellent: a small case series. *Ann Trop Med Parasitol* 2004;98:89-94.
- Maier H, Honigsmann H. Furuncular myiasis caused by *Dermatobia hominis*, the human botfly. *J Am Acad Dermatol* 2004;50(2 Suppl): S26-S30.
- Burns DA. Diseases caused by arthropods and other noxious animals. In: Burns T, Breathnach S, Cox N, Griffiths C, editors. *Rook's textbook of dermatology*. 7th ed. Oxford: Blackwell Science Ltd; 2004. p. 33.8-11.
- Canizares O. Myiasis and leeches. In: Canizares O, Harman R, editors. *Clinical tropical dermatology*. 2nd ed. Oxford: Blackwell Scientific Publications; 1992. p. 404-12.
- Quintanilla-Cedillo MR, León-Ureña H, Contreras-Ruiz J, Arenas R. The value of Doppler ultrasound in diagnosis in 25 cases of furunculoid myiasis. *Int J Dermatol* 2005;44:34-7.
- Gordon PM, Hepburn NC, Williams AE, Bunney MH. Cutaneous myiasis due to *Dermatobia hominis*: a report of six cases. *Br J Dermatol* 1995;132:811-4.
- van Hal SJM, Hudson BJ, Wong DA. Furuncular myiasis after contact with clothing (when washing clothes can be infectious). *Clin Infect Dis* 2004;39:1552-3.
- Spigel GT. Opportunistic cutaneous myiasis. *Arch Dermatol* 1988;124:1014-5.
- Sherman R. Wound myiasis in urban and suburban United States. *Arch Intern Med* 2000;160:2004-14.

39. Veraldi S, Gorani A, Suss L, Tadini G. Cutaneous myiasis caused by *Dermatobia hominis*. *Pediatr Dermatol* 1998;15:116-8.
40. Siraj DS, Luczkovich J. Nodular skin lesion in a returning traveler. *J Travel Med* 2005;12:229-31.
41. Jelinek T, Nothdurft HD, Rieder N, Loscher T. Cutaneous myiasis: review of 13 cases in travelers returning from tropical countries. *Int J Dermatol* 1995;34:624-6.
42. Adisa CA, Mbanaso A. Furuncular myiasis of the breast caused by the larvae of the Tumbu fly (*Cordylobia anthropophaga*). *BMC Surg* 2004;4:1-4.
43. Cornet M, Florent M, Lefebvre A, et al. Tracheopulmonary myiasis caused by a mature third-instar *Cuterebra* larva: case report and review. *J Clin Microbiol* 2003;41:5810-2.
44. Garrison RD. Human tracheopulmonary myiasis. *J Clin Microbiol* 2004;42:3378.
45. De Tarso P, Pierre-Filho P, Minguini N, Pierre LM, Pierre AM. Use of ivermectin in the treatment of orbital myiasis caused by *Cochliomyia hominivorax*. *Scand J Infect Dis* 2004;36:503-5.
46. Martinez CAR, Romani G, Priolli DG, Campos AA, Carneiro VPP, Dalbem CAG. Miiase vulvar: relato de caso. *Rev Bras Ginecol Obstet* 2003;25:291-5.
47. Mirande LM, Landolfi JM, Pedermonete LH, Pepe CM. Furunculoid myiasis caused by *Dermatobia hominis*. *Med Cutan Ibero Lat Am* 1976;4:421-5.
48. Rodriguez G, Raschid M. Human scrotal myiasis (bot fly): a case of self-diagnosis. *J Urol* 2001;166:1397-8.
49. Kahn DG. Myiasis secondary to *Dermatobia hominis* (human botfly) presenting as a long-standing breast mass. *Arch Pathol Lab Med* 1999;123:829-31.
50. Baily GG, Moody AH. Cutaneous myiasis caused by larvae of *Cordylobia anthropophaga* acquired in Europe. *BMJ* 1985;290:1473-4.
51. Rossi MA, Zucoloto S. Fatal cerebral myiasis caused by the tropical warble fly. *Dermatobia hominis*. *Am J Trop Med Hyg* 1973;22:267-9.
52. Gewirtzman A, Rabinovitz H. Botfly infestation (myiasis) masquerading as furunculosis. *Cutis* 1999;63:71-2.
53. Schembre DB, Spillert CR, Khan MY, Lazaro EJ. *Dermatobia hominis* myiasis masquerading as an infected sebaceous cyst. *Can J Surg* 1990;33:145-6.
54. Bangsgaard R, Holst B, Krogh E, Heegaard S. Palpebral myiasis in a Danish traveler caused by the human bot fly (*Dermatobia hominis*). *Acta Ophthalmol Scand* 2000;78:487-9.
55. Brewer TF, Wilson ME, Gonzalez E, Felsenstein D. Bacon therapy and furuncular myiasis. *JAMA* 1993;270:2087-8.
56. Nunzi E, Rongioletti F, Rebora A. Removal of *Dermatobia hominis* larvae. *Arch Dermatol* 1986;122:140.
57. Li Loong PT, Lui H, Buck HW. Cutaneous myiasis: a simple and effective technique for extraction of *Dermatobia hominis* larvae. *Int J Dermatol* 1992;31:657-9.
58. Boggild AK, Keystone JS, Kain KC. Furuncular myiasis: a simple and rapid method for extraction of intact *Dermatobia hominis* larvae. *Clin Infect Dis* 2002;35:336-8.
59. Richards KA, Brieva J. Myiasis in a pregnant woman and an effective, sterile method of surgical extraction. *Dermatol Surg* 2000;26:955-7.
60. Lane RP, Lovell CR, Griffiths WAD, Sonnex TS. Human cutaneous myiasis: a review and report of three cases due to *Dermatobia hominis*. *Clin Exp Dermatol* 1987;12:40-5.
61. Victoria J, Trujillo R, Barreto M. Myiasis: a successful treatment with topical ivermectin. *Int J Dermatol* 1999;38:142-4.
62. Ribeiro FAQ, Pereira CS, Alves A, Marcon MA. Tratamento da miiase humana cavitária com ivermetina oral. *Rev Bras Otorrinol* 2001;67:755-61.
63. Shinohara EH, Martini MZ, Oliveira Neto HG, Takahashi A. Oral myiasis treated with ivermectin: case report. *Braz Dent J* 2004;15:79-81.