

Frequency of Apical and Laminal /s/ in Normal and Post-glossectomy Patients

Maureen Stone^{*}, Susan Rizk^{*}, Jonghye Woo^{*}, Emi Z. Murano[^], Hegang Chen[#], Jerry L. Prince⁺^{*}University of Maryland School of Dentistry, [^]Johns Hopkins Hospital, [#]University of MarylandSchool of Medicine, ⁺Johns Hopkins University

Author Note

Maureen Stone, Department of Neural and Pain Sciences; Orthodontics, University of Maryland School of Dentistry

Susan Rizk, Department of Neural and Pain Sciences; Orthodontics, University of Maryland School of Dentistry

Jonghye Woo, Department of Neural and Pain Sciences; Orthodontics, University of Maryland School of Dentistry

Emi Z. Murano, Johns Hopkins University School of Medicine, O-HNS

Hegang Chen, University of Maryland School of Medicine, Epidemiology

Jerry L. Prince, Department of Electrical and Computer Engineering, Johns Hopkins University

This research was supported in part by NIH grant R01 CA133015.

Correspondence concerning this article should be addressed to Maureen Stone, University of Maryland School of Dentistry, Department of Neural and Pain Sciences, 650 W. Baltimore St., Baltimore, MD 21201

Contact: mstone@umaryland.edu

Abstract

American English can be produced with two types of /s/: apical or laminal. These productions differ in that the apical gesture requires independent tongue tip elevation and the laminal does not. Post-glossectomy speakers, who have lost a unilateral section in the tongue body along the outer edge, lose innervation to the tongue tip. We hypothesize that post-glossectomy patients, even those with a preserved tongue tip, will be more likely to use laminal tongue shapes due to reduced control of the tongue tip. This study examines /s/-type, palate height and related parameters in 24 controls and 13 patients with lateral resections using cine-MRI and dental casts. Results on this dataset show that palate height affects choice of /s/ in controls, but not in patients. Patients tend to use laminal /s/.

Keywords: glossectomy, speech, tongue, apical, laminal

FREQUENCY OF APICAL AND LAMINAL /S/

Frequency of Apical and Laminal /s/ in Normal and Post-glossectomy Patients

The production of speech is highly dependent on tongue deformation, as changes in vocal tract shape are caused primarily by movement of the tongue. Speakers who have had tongue cancer surgery (glossectomy), which removes part of the tongue, develop adapted motion patterns to produce phonemes that are acoustically optimized (Mosier, Wen-Ching, Behin, Lee, & Baredes, 2005). Thus, this patient group provides a testing ground to study successful adaptations of tongue motor control during speech.

Post-surgery, small tumors of the tongue are typically closed primarily (sutured shut) while large tumors receive a 'flap'. The flap is composed of soft tissue, usually taken from the radial forearm, which replaces the resected tissue. Mid-sized tumors can be closed in either manner and it is the surgeon's choice. Although flap reconstruction makes additional tissue available to manipulate the bolus, prevent retention of food below the tongue, and reach high tongue positions for speech, it is not without disadvantages. The flap is not innervated and adds extra weight, which fatigues the tongue (McConnel et al., 1998). Hence, there is disagreement among surgeons regarding whether a flap is the better closure procedure for midsize (T2) tumors, which are 2-4 cm in the longest dimension (Chuanjun, 2002; Hsiao, 2002; Logemann, 1993).

One of the more difficult sounds for glossectomy speakers is the /s/ (Imai & Ichi, 1992). This sound requires precise placement of the tongue and jaw to produce a narrow constriction in the alveolar region of the palate and direct the airstream toward the incisors; slight errors are acoustically and perceptually salient. Interestingly, the normally spoken /s/ can be produced using at least two different gestures. The apical /s/ uses the tongue tip to contact the alveolar ridge; the laminal /s/ uses the tongue blade (Dart, 1990). Both gestures are quite prevalent among normal speakers and there is no known determinant for a speaker's use of one versus the

FREQUENCY OF APICAL AND LAMINAL /S/

other. For glossectomy patients, however, tongue tip control may be impaired, so that laminal /s/ may be easier to produce. The present study examines patients whose resection is in the lateral tongue margin, that is, on one side of the tongue, and midway between the anterior and posterior tongue. In all patients the tip has been preserved. However, innervation to the tip is damaged, because the resection cuts many of the nerves that flow into it. It is the goal of this study to determine if glossectomy patients differ from controls in the /s/ type produced, and whether closure procedure plays a role. In addition, however, palate height and width may affect a speaker's choice of /s/ type. Therefore, this study also considers the effects of these other variables on /s/ type for patients and controls.

Materials and Methods

Subjects and Speech Material

This study examined 22 control subjects (10 male, 12 female; mean age 38) and 15 post-glossectomy subjects (8 male, 7 female; mean age 46). All subjects had normal hearing acuity, speech reception threshold, and word recognition tests. Participants were required to have first molars and nearly complete dentition. The subjects were native speakers of English, typically from the North Eastern US, and none had an extreme accent.

The patients had undergone a partial glossectomy procedure at the University of Maryland Hospital or Johns Hopkins Hospital as treatment for squamous cell carcinoma of the tongue at least 8 months prior to the study. At least one side of the lengthwise tongue was preserved during the surgery. Ten patients had small tumors (T1N0M0 < 2cm in largest dimension) and five had moderate ones (T2N0M0 2-4cm in largest dimension). Two T2s had

FREQUENCY OF APICAL AND LAMINAL /S/

radial forearm free flaps (RFFF). The rest had primary closures, that is, they were sutured closed. In all cases, the tongue tip was preserved.

Sentence Intelligibility Tests were available for 12 of the 15 patients and scored by a naïve listener. Intelligibility scores were 97-100% except for one subject, who scored 91%. She was a T1 with a primary closure, who also had a palatal torus and missing teeth, which may have contributed to the score.

The speech task, “a souk,” was studied for several reasons. The task can be repeated in less than 1 second, which is within the limits of our MRI recording system. The first MRI frame is a schwa, which uses a fairly neutral tongue position, from which it moves into the /s/. The word uses very little jaw motion, so tongue deformation is the main component of the /s/ motion.

Instruments and Data Collection

Cine-MRI recordings were made during the speech task. A 3.0 T Siemens Tim Trio with 8 channel head and neck coil were used. The recording parameters were: 26 time-frames per second; in-plane resolution of 1.875 mm; slice thickness of 6 mm. To ensure good image quality and spatial resolution, the scanning protocol used in this MRI data collection required 5 repetitions of the task to be summed during recording to create a single midsagittal movie. Acoustic recording was done in the MRI using a noise-cancellation fiber optic microphone (OptoAcoustics Ltd, Israel). The audio recordings were used solely to corroborate timing of the phonemes and frames of interest.

Pre-MRI training was given to each subject. Each MR image is a combination of 5 repetitions, so the speaker’s ability to repeat the utterance precisely is critical to image quality. Therefore, subjects repeated the speech task in the MRI scanner using a metronome. Prior to the

FREQUENCY OF APICAL AND LAMINAL /S/

MRI scan subjects were trained for about 15 minutes to speak the task to the metronome beats they would later hear in the scanner. The experimenter stopped the training when her perception of the subject's repetitions indicated accurate timing had occurred for several minutes. This method was designed by Masaki and colleagues (Masaki et al., 1999). A dental impression was made of each subject's palate for direct measurement of height and width. Five subjects did not have dental casts and were included only in the MRI analyses: three pre-dated this protocol, one had a torus and missing molars, and one had a defective cast.

Data Analysis

From the dental casts, palate width was measured using calipers and palate height using an attached depth gauge. Palate width was defined as the distance between the mid-palatal aspect of the maxillary first molars at the gingival level. Palate height was measured by resting the calipers on the cusps of the maxillary first molars and lowering the depth gauge to the palatal vault. If a torus was present, the depth gauge was lowered to the surface of the torus. However the subject with the torus was missing several molars on both sides and depth measures could not be reliably made. The palatal heights of the first molars from the gingival margin to the cusp tips were then measured. Palatal height was calculated by subtracting the height of the molars from the palatal height including the molars. The average of two measurements was taken. The median height of 14 mm was used to categorize subjects as high palate (>14 mm depth) or low palate (\leq 14 mm depth). This value is the rough average of the mean palatal heights for adult males (14.9 mm) and females (12.7mm) measured by Shapiro, et al., (1963), and also is the average palate height for our data set.

FREQUENCY OF APICAL AND LAMINAL /s/

From the MR images /s/ was categorized as apical or laminal (Figure 1) based on the criteria of Dart (1991). This categorization and all measurements were made on the /s/ time-frame with the first palate contact to minimize coarticulatory effects of the following /u/. A custom Matlab Program (Mathworks, Natick, MA), was used to select the frames of interest in the cine-MRI movies. It also measured the tongue-to-palate distance (T-P distance) at the velopalatal junction. See white lines in Figure 1.

Results

No significant difference was found between the control and glossectomy patient groups in palate height ($p=0.2619$) or palate width ($p=0.1846$).

/s/ Type

Apical /s/ was less frequent for patients than controls. Four of the 15 patients used apical /s/, whereas 12 of the 22 controls used it ($p = 0.0686$, Fisher's Exact Table Test). Five patients did not have palate casts: 3 apical and 2 laminal. For remaining subjects, the consideration of palate height produced a striking effect. Table 1 shows a preference for apical /s/ in low palate controls but not high palate controls. Of the patients with a dental cast, only one used an apical /s/; he was a T1 with a primary closure and a high palate.

Tongue-Palate Distance

Results showed a significantly larger T-P distance for the control group than the patient group [ANOVA, GLM, /s/-onset: $F=4.65$, $p<0.04$]. Table 2 shows detailed values for the two groups relative to palate height and /s/ type. Considering just the patient group, T-P distance

FREQUENCY OF APICAL AND LAMINAL /s/

was examined as a function of tumor size (T1, T2) and closure procedure (primary, flap). In the primary closure patients, the nine T1's had an average T-P distance of 10.02 mm whereas the four T2's had distances of 8.76 mm. There were two patients with flap closures (Flap-1, Flap-2). Flap-1 was a T1 with a high palate, Flap-2 was a T2 with low palate; both had laminal /s/. Flap-1 had a T-P distance of 9.0 mm, whereas Flap-2 had a T-P distance of 9.6 mm.

Discussion

Although the number of subjects is fairly small in this study, a trend for group differences is apparent. The glossectomy patients, but not the controls, preferred laminal /s/ (45% of controls and 73% of patients). In addition, palate height and /s/-type were related for controls, but not patients. For high palates, 63% of controls and 75% of patients used laminal /s/. But for low palates, 28% of controls and 100% of patients used laminal /s/. While high-palate controls tended to use either /s/ type, low-palate controls tended to use apical /s/. This suggests that it may be more challenging to execute a laminal /s/ with a low palate in the context of glossectomy.

The rare usage of apical /s/ in patients is consistent with the proposition that tongue tip elevation is difficult for these patients, probably due to reduced control. Even when the tongue tip is preserved in a lateral glossectomy, the surgery removes intermediate sections of muscle, resulting in discontinuous fibers and reduced or absent sensori-motor innervation in the distal end of the fiber. Motion of the tip-plus-blade may be easier than elevation of the tip alone.

To produce /s/ the lateral margins of the tongue must contact the lateral palate and teeth in order to funnel a narrow jet of air onto the incisors, which creates the characteristic sibilant noise pattern. A tongue groove is typically seen in low front vowels, where the genioglossus anterior pulls the anterior tongue down. In high tongue positions, the groove is diminished or

FREQUENCY OF APICAL AND LAMINAL /S/

eliminated (Stone and Lundberg, 1996). During /s/, however, the upward pressure of the lateral tongue braces it against the palate so that the genioglossus anterior can lower the midline without lowering the tongue. The lower the midline, the deeper the groove; the amount of midline lowering is what the T-P distance measures.

The relationship between /s/ type and palate height for controls was interesting. For the high-palate controls, there was virtually no difference (0.4 mm) in T-P distance between apical and laminal /s/. In low-palate controls, however, T-P distance was 3.0 mm smaller on average for apical /s/. These findings indicate a difference in tongue shape for the two /s/'s. A shallower groove at the velopalatal juncture occurs in the apical /s/. Although only one word was studied here, it is likely that the following /u/, which used a high tongue body, maximized tongue body height and minimized T-P distance in all subjects. For the one patient with apical /s/, T-P distance was not remarkable (10.2 mm).

Tongue-palate distance at the velopalatal juncture was significantly larger for controls than patients (Table 2), consistent with a deeper groove for the controls. The patients also differed from each other in groove depth, though no statistics were performed due to the small sample size. The two flap patients used a laminal /s/, as did all but one of the primary closure patients. Although the flap patients had different palate heights, this variable did not have a significant effect on the patient data and was not considered. For primary closure patients, T1's had a deeper groove than T2's, whereas the two flap patients had shallower grooves than the controls and deeper grooves than the T2's. It may be that the flap patients had better control of the midline, or that the flap distanced the tongue more from the palate, or a combination. In any case the flap patients had a greater T-P distance than the more severe patients. However, a larger sample size of patients, especially T2's and those with flap closures, is necessary to determine if

FREQUENCY OF APICAL AND LAMINAL /S/

there is a true difference in T-P distances between closure types or tumor sizes, and what the implications of this might be.

Patient difficulties with /s/ production are multifactorial but subtle modifications in motor control strategies appear to compensate for these losses. Due to the severing of small branches of the CN XII, independent elevation of the tongue tip is difficult. Patients may adapt by using laminal /s/, which does not independently elevate the tongue tip. Due to the tongue's reduced mass, tongue body elevation might also have been compromised. However, the small T-P distances measured at midline in the velar region suggest that elevation of the tongue body was successfully accomplished and a smaller than normal groove created by the patients. Normal tongue body elevation is understandable since the surgical resections are in the oral, not the pharyngeal tongue, and may not impact control of tongue body elevation. The loss of tongue mass in the anterior tongue may be compensated elsewhere, such as by greater larynx elevation and forward positioning. Due to unilateral resection, creation of bilateral tongue-palate contact is challenging. This is a midsagittal dataset and cannot address lateral tongue contact, but the perception data suggest adequate tongue function. Due to unilateral resected muscles, the tongue groove is diminished. Patients adapt by using a shallower groove.

Deleted: is

Conclusions

Control speakers with high-palates use either /s/ type, apical or laminal. However, controls with low-palates had a moderate preference for apical /s/. This was not seen in glossectomy speakers who preferred laminal /s/ irrespective of palate height.

References

FREQUENCY OF APICAL AND LAMINAL /S/

Chuanjun, C., Zhiyuan, Z., Shaopu, G., Xinquan, J., and Zhihong, Z. (2002) Speech after partial glossectomy: a comparison between reconstruction and non-reconstruction patients. *J Oral Maxillofac Surgery*, 60(4):404-7.

Dart, Sarah (1991). "Articulatory and Acoustic Properties of Apical and Laminal Articulations" *UCLA Working Papers in Phonetics* no. 79.

Hsiao, H.T., Leu, Y.S., and Lin, C.C. (2002) Primary closure versus radial forearm flap reconstruction after hemiglossectomy: functional assessment of swallowing and speech. *Ann Plast Surgery*, 49(6):612-6.

Imai, S., and Michi, K.I. (1992) Articulatory function after resection of the tongue and floor of the mouth: Palatometric and perceptual evaluation. *Journal of Speech and Hearing Research*, 35(1):68-78.

Logemann, J.A., Pauloski, B.R., Rademaker, A.W., McConnel, F.M., Heiser, M.A., Cardinale, S., Shedd, D., Stein, D., Beery, Q., and Johnson, J. (1993) Speech and swallow function after tonsil/base of tongue resection with primary closure. *J Speech Hear Res*, 36(5):918-26.

Masaki, S., Tiede, M., Honda, K., Shimada, Y., Fujimoto, I., Nakamura, Y., and Ninomiya, N. (1999) "MRI-based speech production study using a synchronized sampling method." *J Acoust Soc Jpn*, 20, 375-379.

McConnel, F.M., Pauloski, B.R., Logemann, J.A., Rademaker, A.W., Colangelo, L., Shedd, D., Carroll, W., Lewin, J., and Johnson, J. (1998) Functional results of primary closure vs flaps in oropharyngeal reconstruction: a prospective study of speech and swallowing. *Arch Otolaryngol Head Neck Surgery*, 124(6):625-30.

FREQUENCY OF APICAL AND LAMINAL /S/

- Mosier, K., Wen-Ching, L., Behin, B., Lee, C., and Baredes, S. (2005) Cortical Adaptation Following Partial Glossectomy With Primary Closure: Implications for Reconstruction of the Oral Tongue. *Annals of Otology, Rhinology & Laryngology*, 114(9): 681-7.
- Shapiro, BL, Redman, RS, and Gorlin, RJ, (1963) Measurement of normal and reportedly Malformed Palatal Vaults. I. Normal Adult Measurements. *J. Dent. Res.* 42(4):1039-1042.
- Stone, M. and Lundberg, A. (1996) Three-dimensional tongue surface shapes of English consonants and vowels. *J. Acoust. Soc. Am*, 99:3728-37.

| Palate Height | Controls | | Patients | |
|---------------|----------|---------|----------|---------|
| | Apical | Laminal | Apical | Laminal |
| Low Palate | 8 | 3 | 0 | 6 |
| High Palate | 4 | 7 | 1 | 3 |
| Total | 12 | 10 | 1 | 9 |

| | Low Palate | | | | High Palate | | | |
|--------------|-----------------|---------------|----------|---------------|-----------------|-----------------|-----------|---------------|
| | Controls | | Patients | | Controls | | Patients | |
| | Apical | Laminal | Apical | Laminal | Apical | Laminal | Apical x1 | Laminal |
| T-P distance | 10.28 (2.49) | 13.2 (1.2) | None | 9.5 (1.67) | 11.55 (3.22) | 11.14 (2.21) | 10.2 (0) | 9.2 (1.25) |

FREQUENCY OF APICAL AND LAMINAL /S/

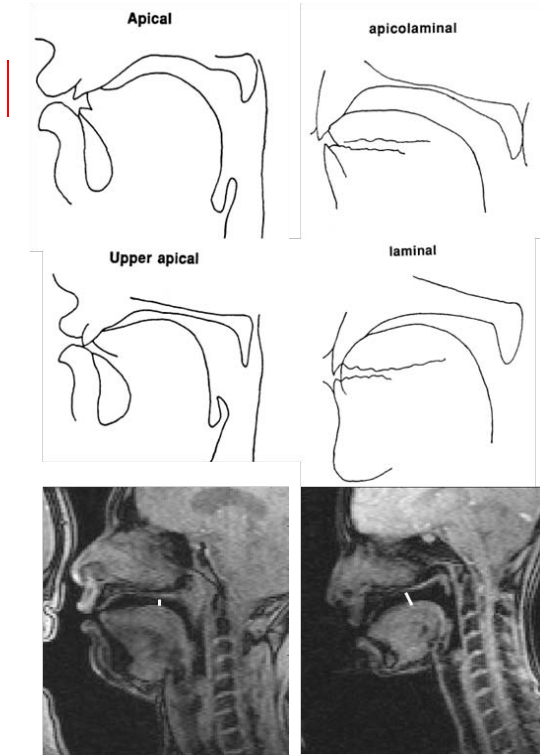


Figure 1: Designation of /s/ as apical (left) or laminal (right). Top two rows indicate apical and laminal tongue shapes (from Dart 1991). Bottom row shows examples from the data and white lines indicate location of T-P Distance measurement.