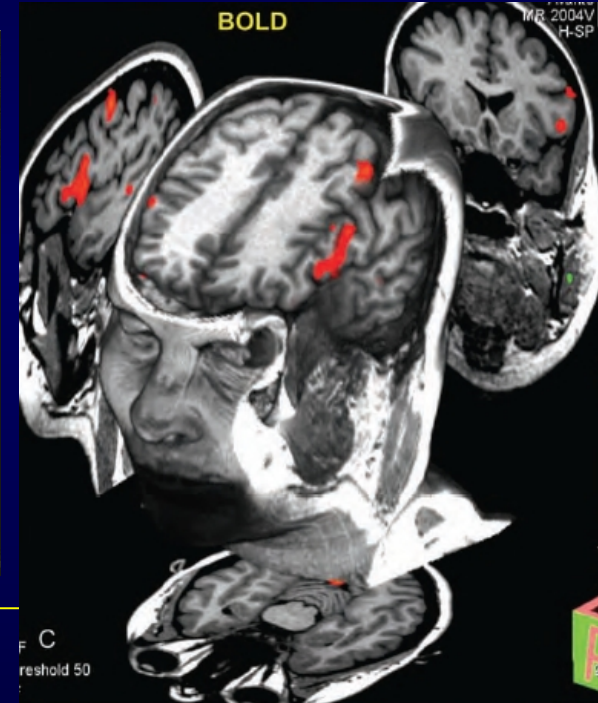
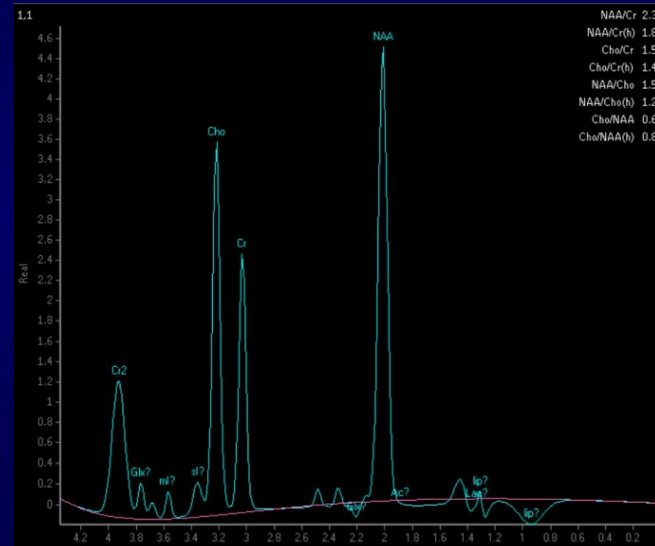
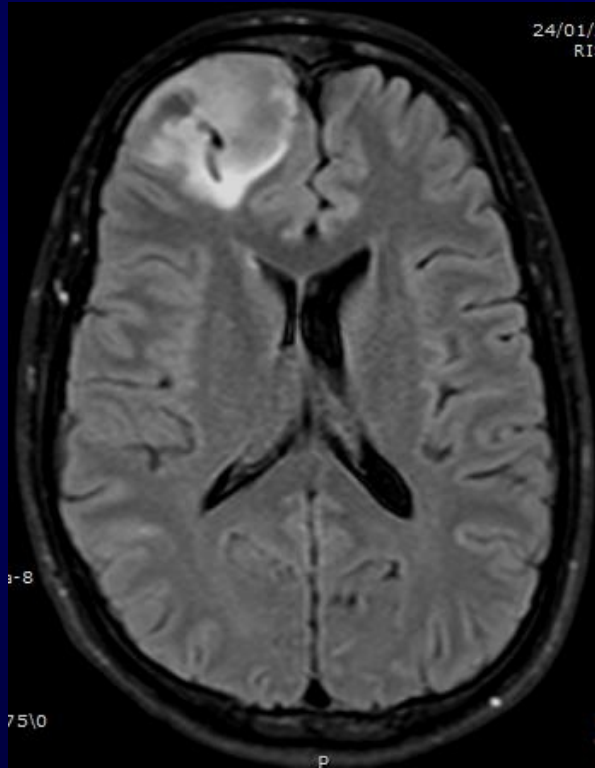


NEUROIMAGEN EN EL DIAGNÓSTICO DE LOS TUMORES GLIALES



Dr Juan S Martínez San Millán
Sección de Neuro-Radiología
Servicio de Radiodiagnóstico
Hospital Ramón y Cajal
Madrid

Definitivamente, lo más bonito que le pueden decir a uno hoy en día **NO** es “Te Quiero”, sino “ESE TUMOR QUE TIENE USTED NO ES MALIGNO”.

Woody Allen

En el encéfalo es simplemente **MEJOR** que te digan “ESE TUMOR QUE TIENE USTED ES DE BAJO GRADO”.

NEOFORMACIONES DEL ENCÉFALO

- **CLASIFICACIÓN**

- PRIMARIAS

- GLIALES

- NO GLIALES

- DEPÓSITOS SECUNDARIOS

NEOFORMACIONES PRIMARIAS DEL ENCÉFALO

- **NATURALEZA**

- 2/3 de los tumores del encéfalo son **PRIMARIOS**
- El 50% de los tumores primarios del encéfalo son **GLIOMAS**
- El 70-75% de los gliomas son **ASTROCITOMAS**
- Más del 75% de los astrocitomas son **ANAPLÁSICOS ó GLIOBLASTOMAS**
- La mitad de los astrocitomas son **GLIOBLASTOMAS**

NEOFORMACIONES PRIMARIAS DEL ENCÉFALO

- **MALIGNIDAD BIOLÓGICA**

- RAPIDEZ DE CRECIMIENTO
- NECROSIS TUMORAL
- HEMORRAGIA
- EXTENSIÓN LOCAL
- DISEMINACIÓN
 - ARACNOIDEA
 - LINFÁTICA
 - HEMATÓGENA

- **MALIGNIDAD HISTOLÓGICA**

- ATIPIA CELULAR
- MITOSIS
- INFILTRACIÓN TISULAR
 - EDEMA-PLUS
 - MULTIFOCALIDAD
- NECROSIS
- CAMBIOS VASCULARES
 - ANGIOGÉNESIS
 - BHE PERMEABLE

NEOFORMACIONES PRIMARIAS DEL ENCÉFALO

- **GRADACIÓN TUMORAL**
 - AP
 - RADIOLÓGICA
- **GRADOS**
 - BAJO
 - INTERMEDIO
 - ALTO

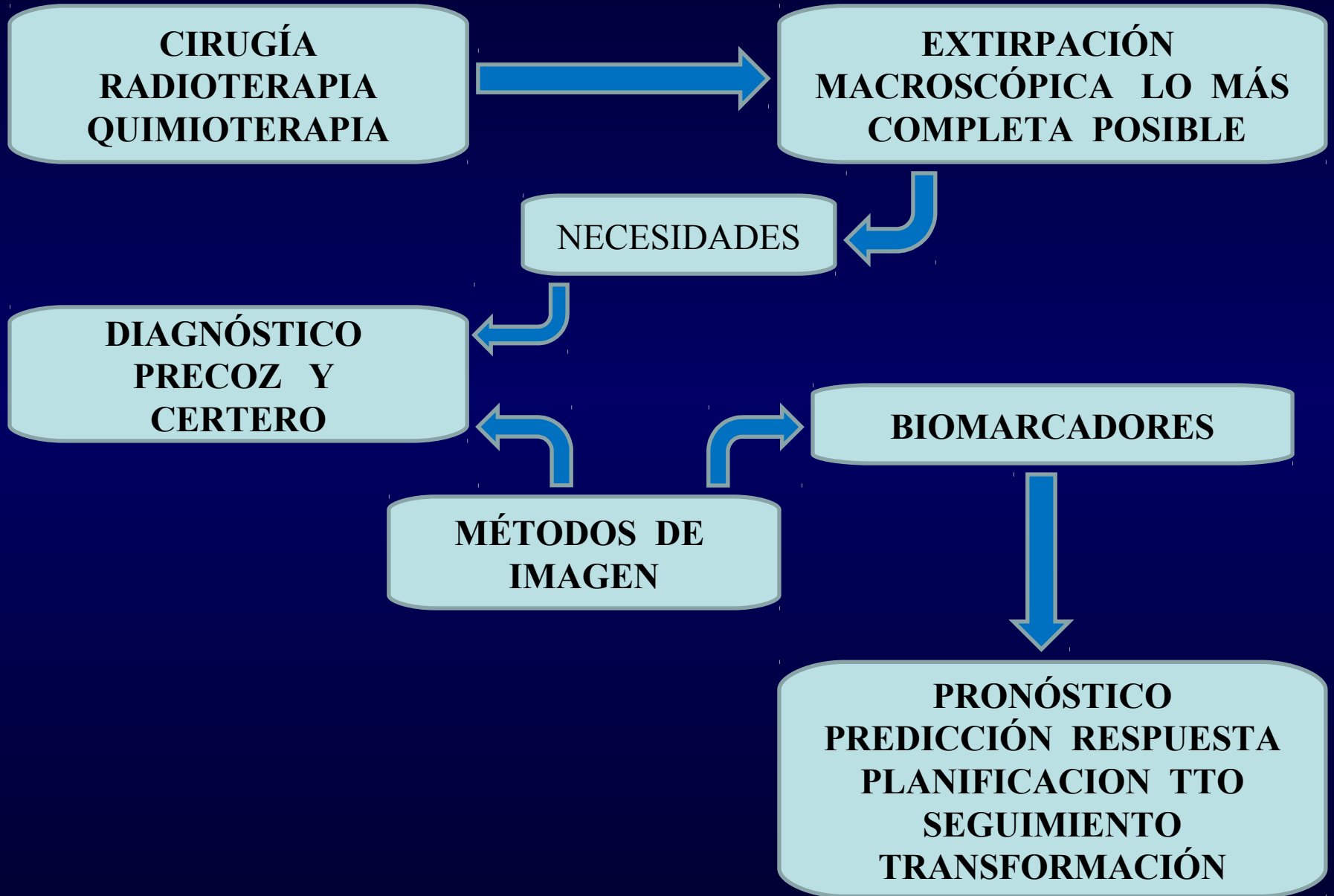
- **VEHÍCULOS CLÁSICOS**
 - NECROSIS
 - HEMORRAGIA
 - REALCE
 - PRESENTE / AUSENTE
 - TIPO
 - VASCULARIZACIÓN

AP: GOLD-STANDARD

- **VARIABILIDAD INTERPERSONAL**
- **LUGAR DE ELECCIÓN DE BIOPSIA**
- **LUGAR DE REALIZACIÓN DE LA BIOPSIA**
- **TOMA DE BIOPSIA: PROCESO AGRESIVO POCAS VECES REPETIBLE**

LA INFORMACIÓN
OBTENIDA PUEDE
RESULTAR MUY
ALEATORIA

TRATAMIENTO



PAPEL INICIAL DE LOS MÉTODOS DE IMAGEN

MÉTODOS

TC

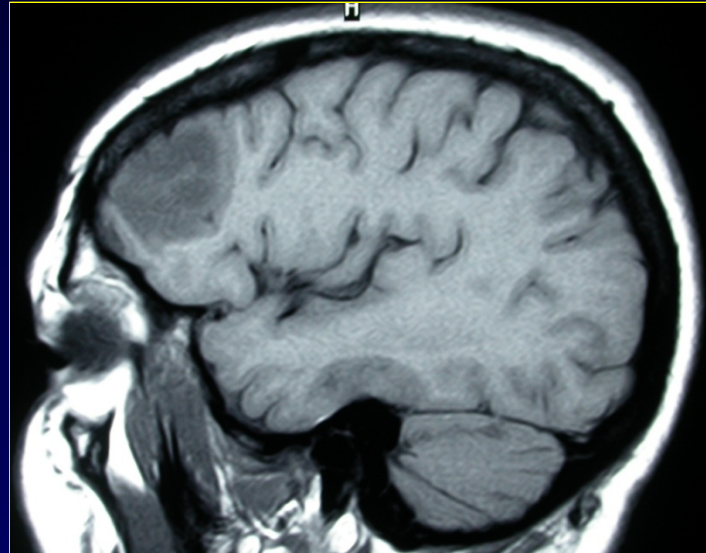
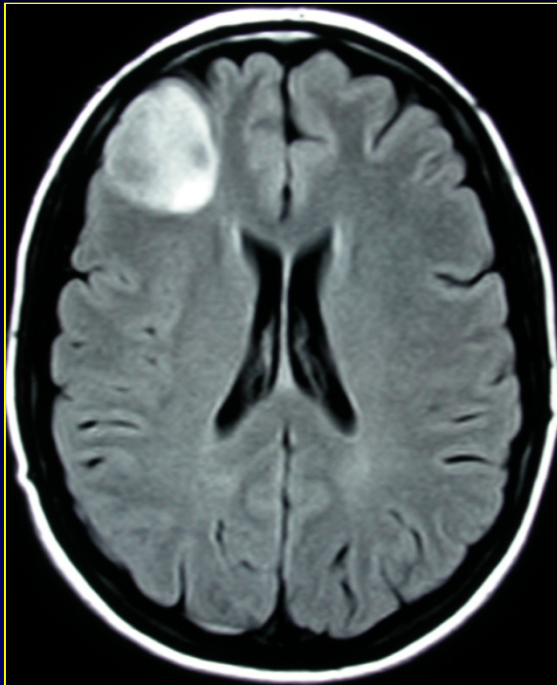
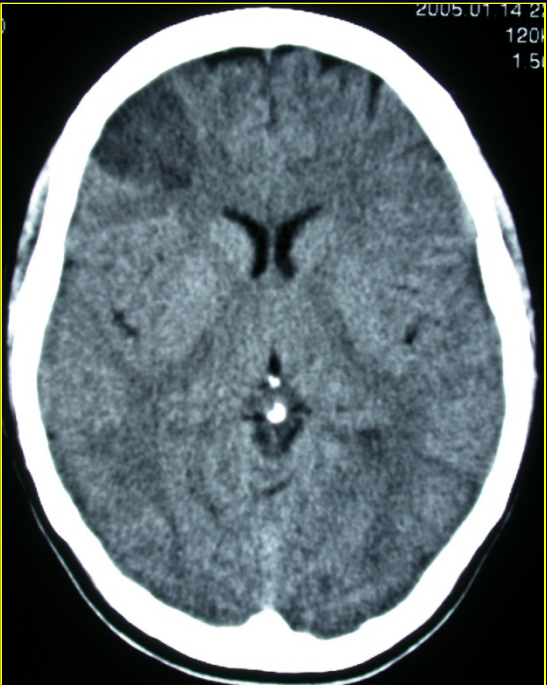
RM

RM CONVENCIONAL

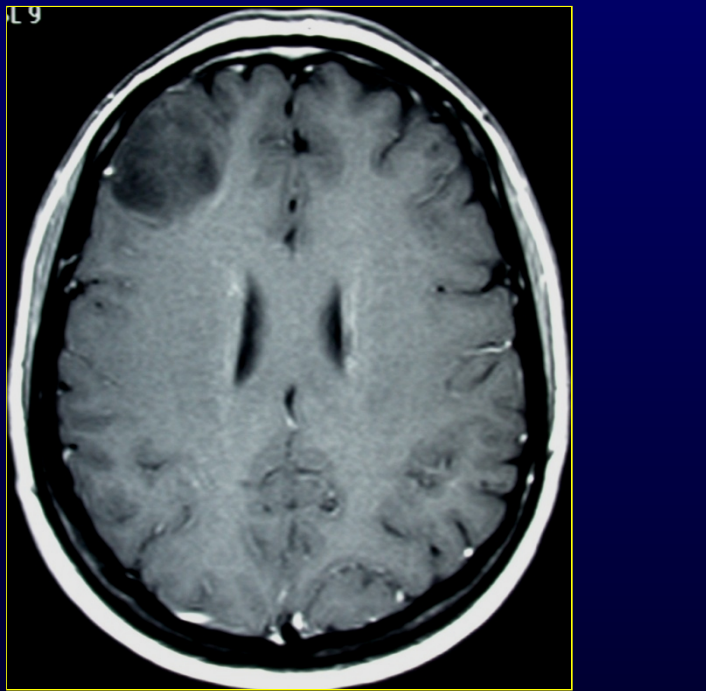
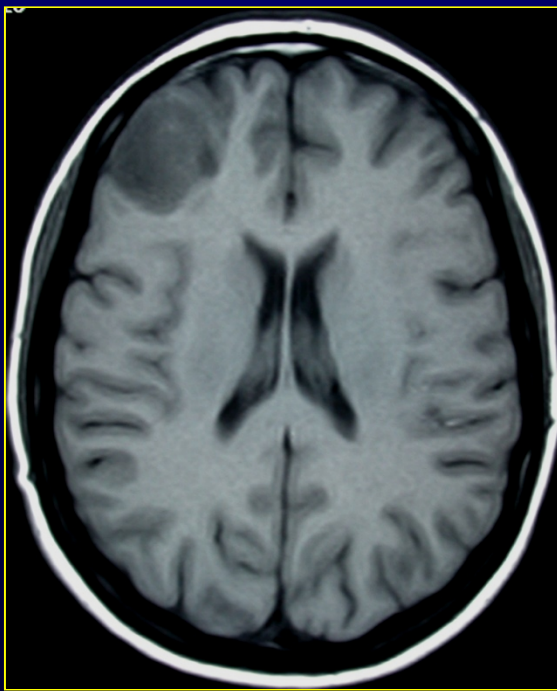
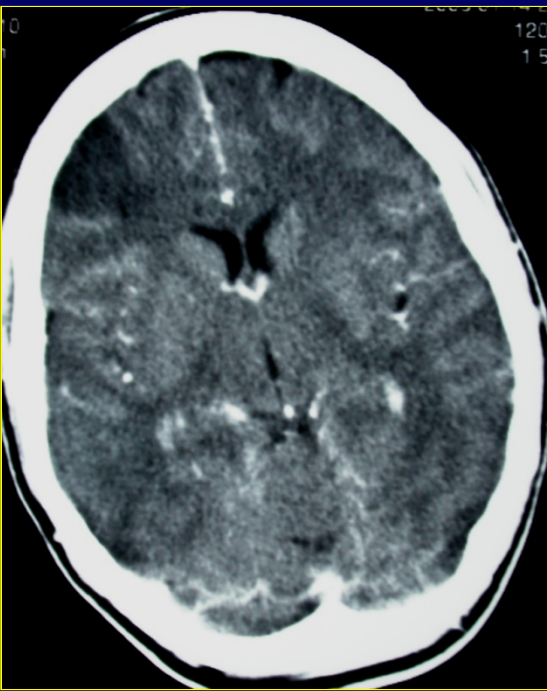
- DIAGNÓSTICO DIFERENCIAL
- DIAGNÓSTICO
- GRADO
- EXTENSIÓN
- LUGAR DE BIOPSIA
- CONTROL EVOLUTIVO

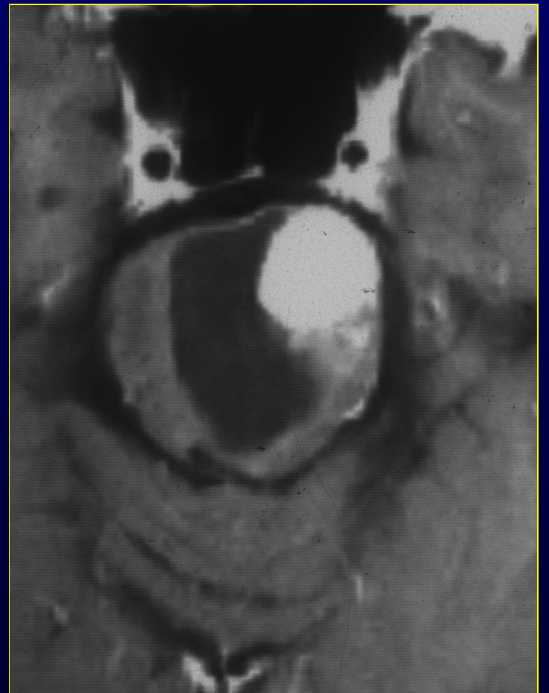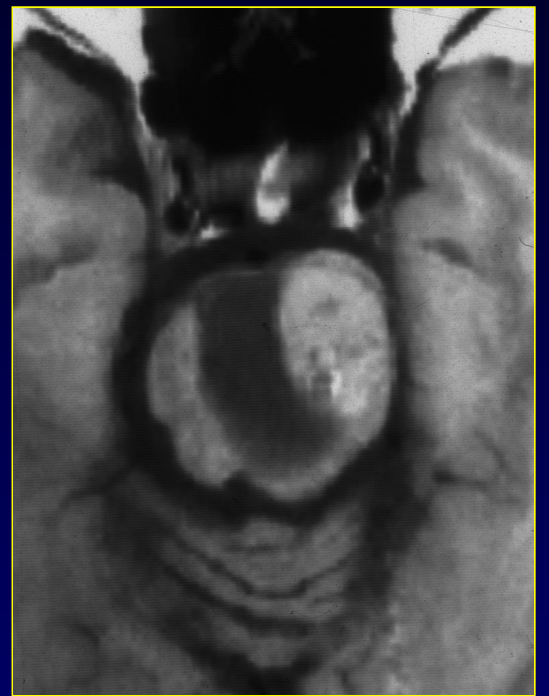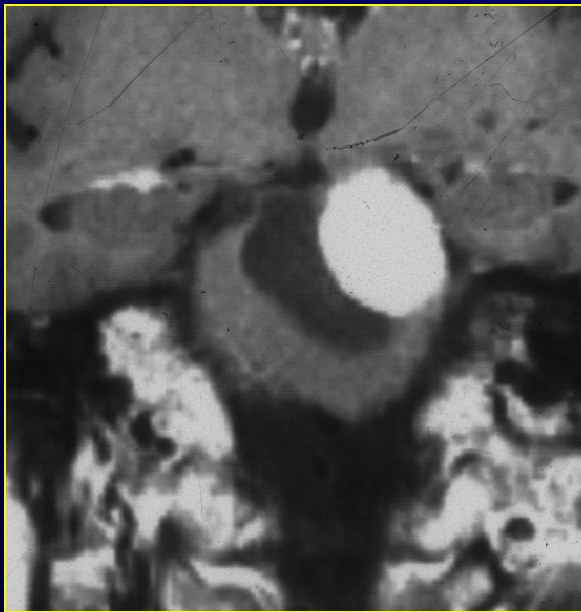
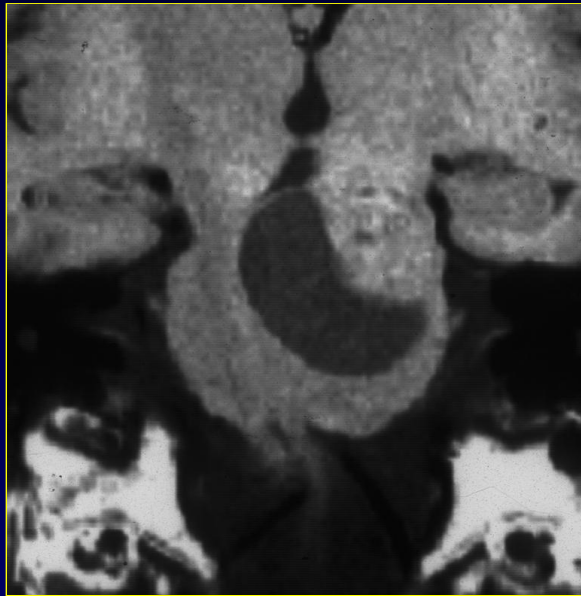
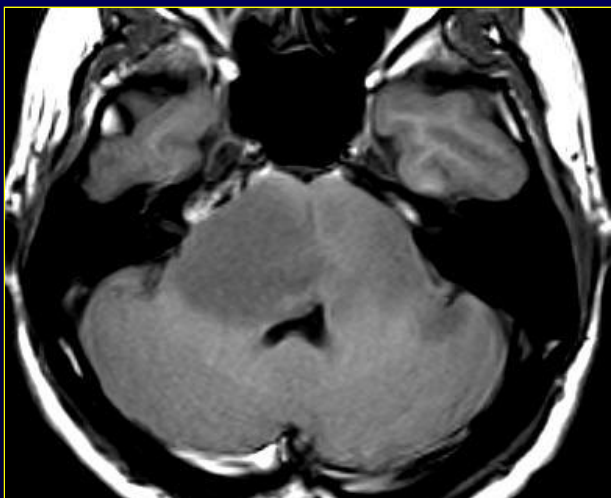
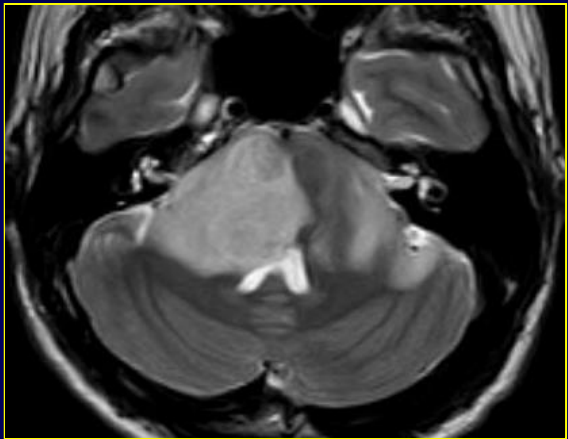
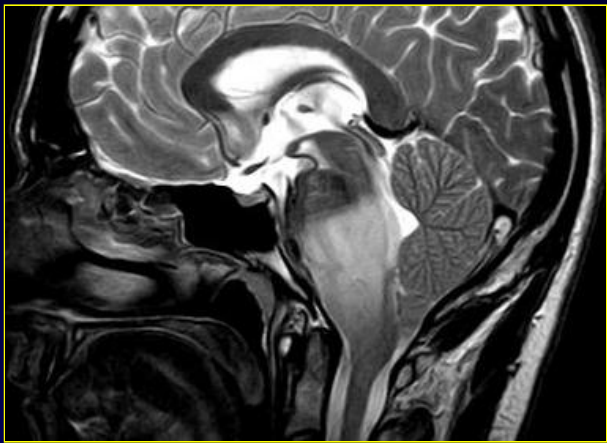PAPEL INNEGABLE E
INNEGOCIABLE DE LOS
CONTRASTES

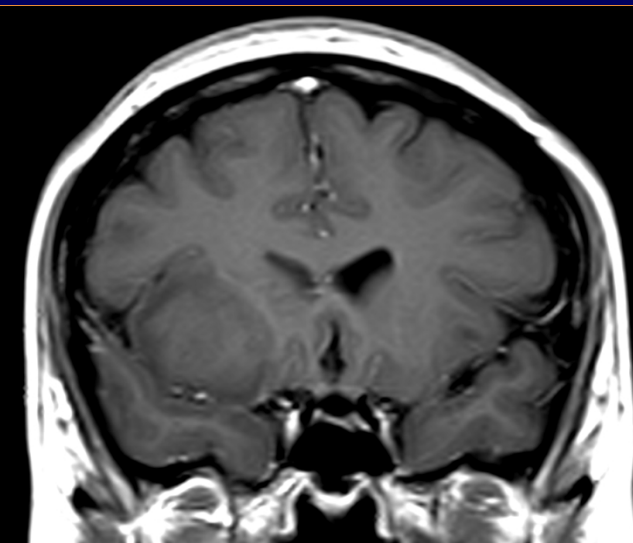
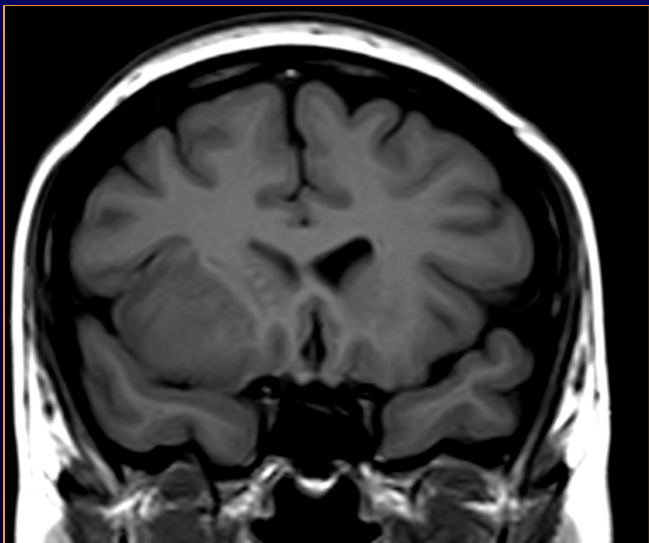
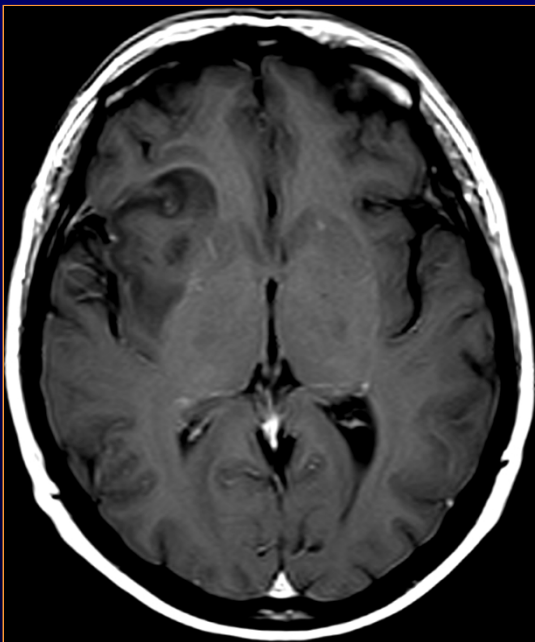
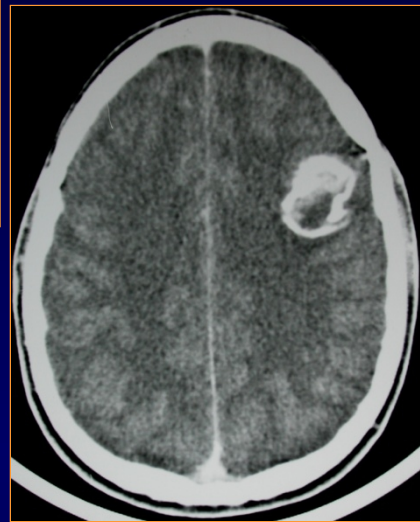
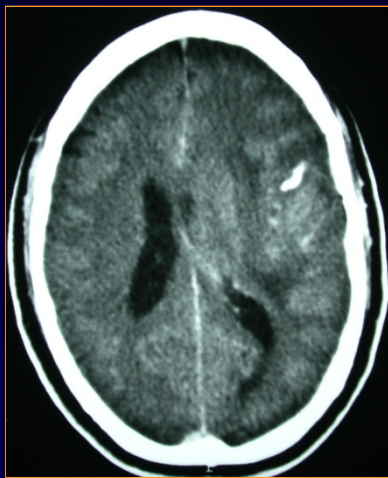
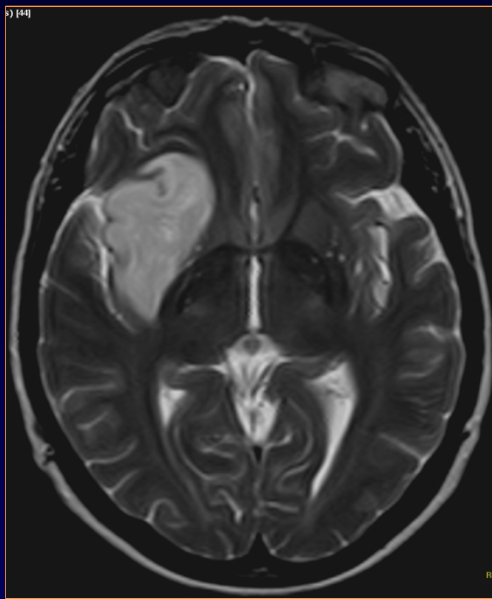
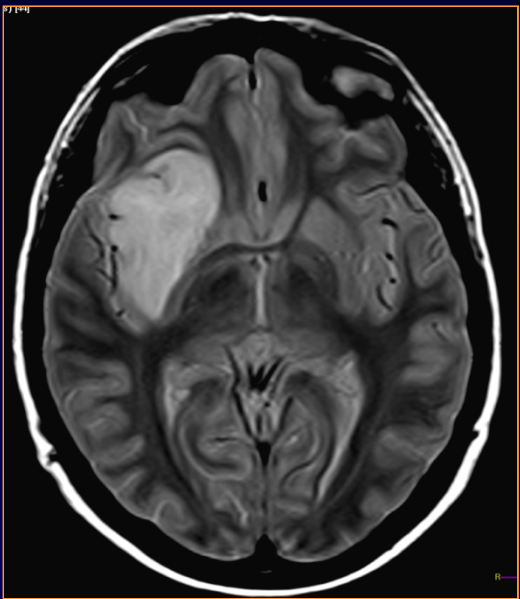
2005 01 14 21
120
1.5

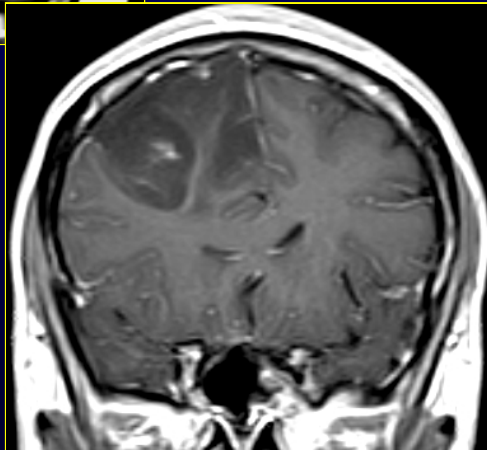
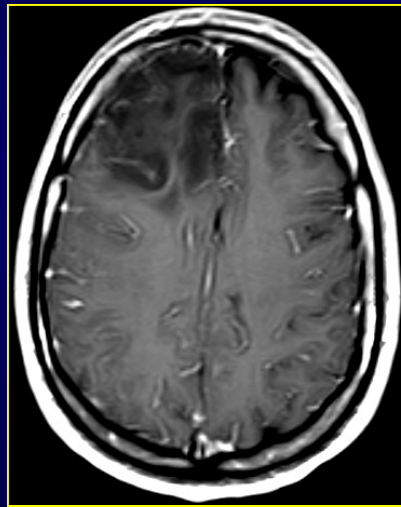
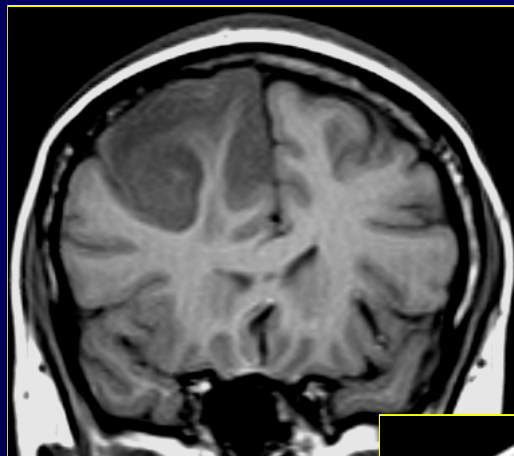
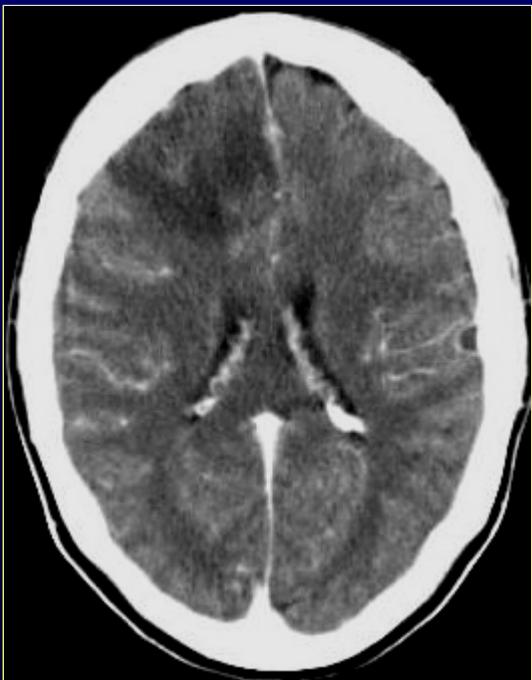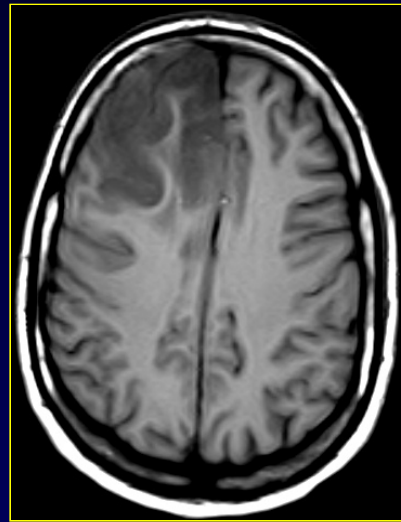
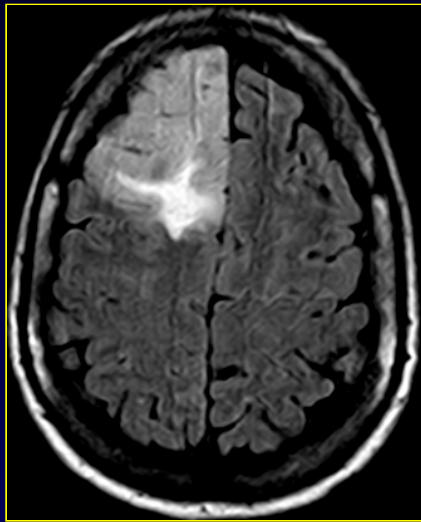
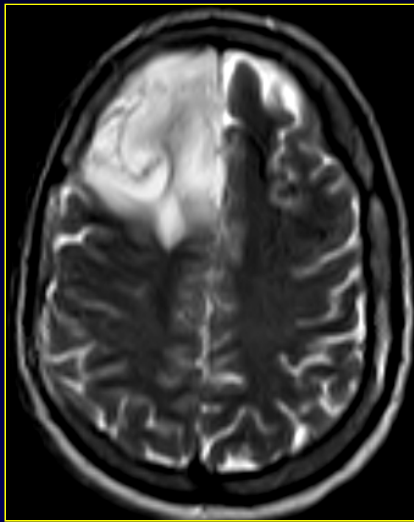

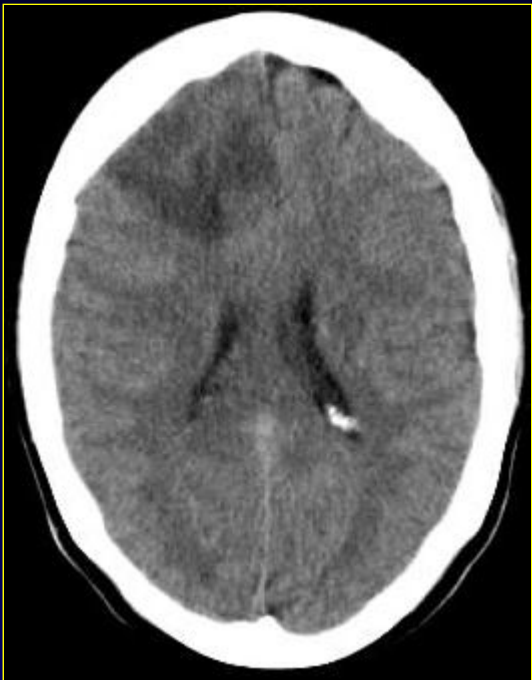
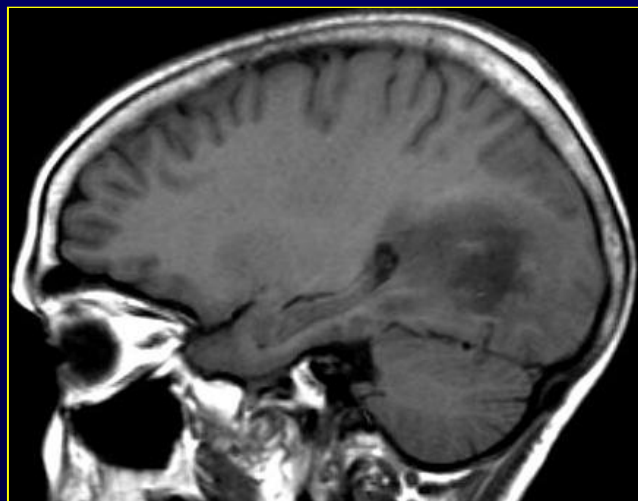
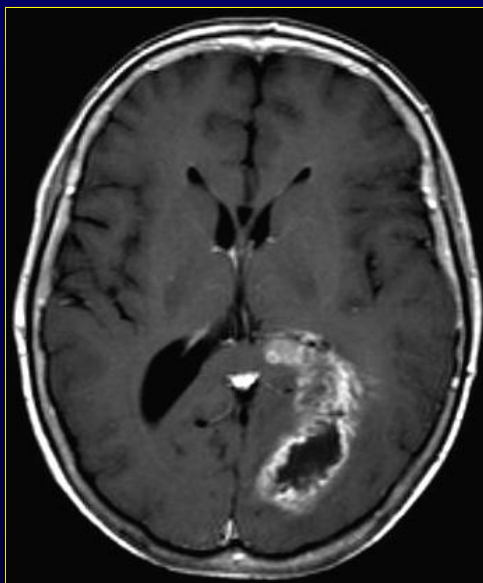
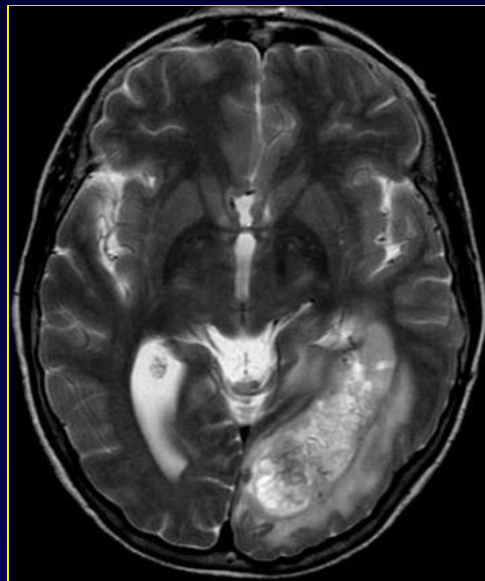
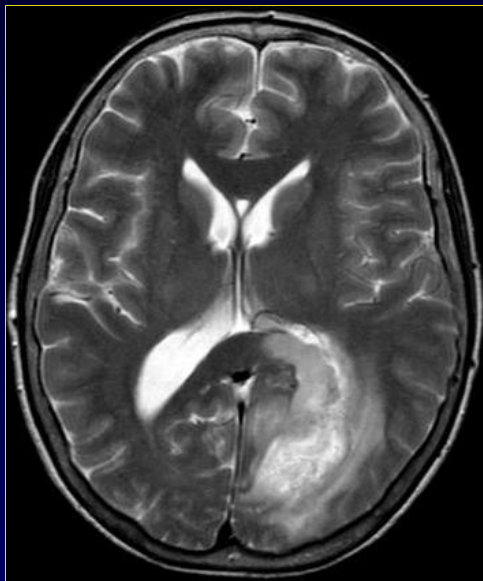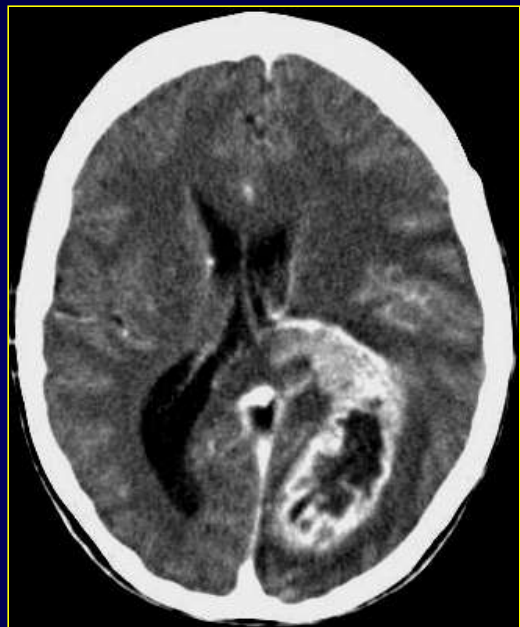120
1.5

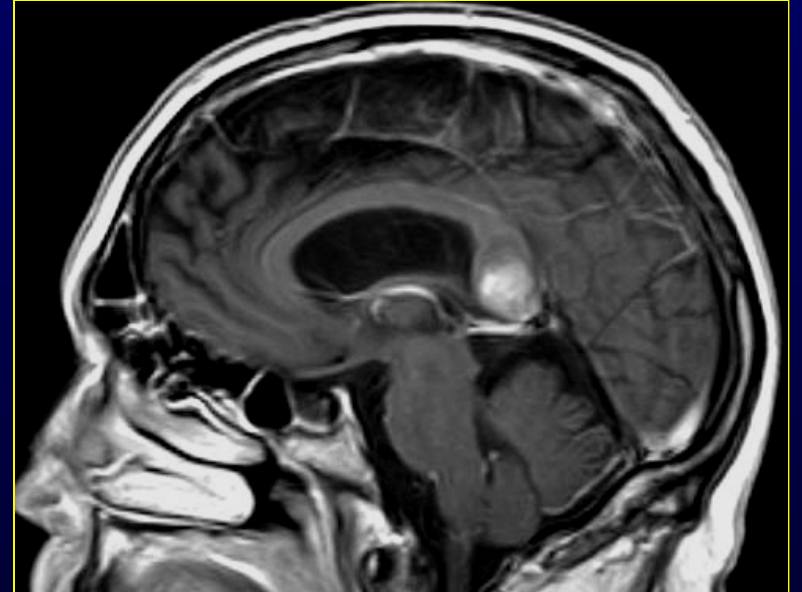
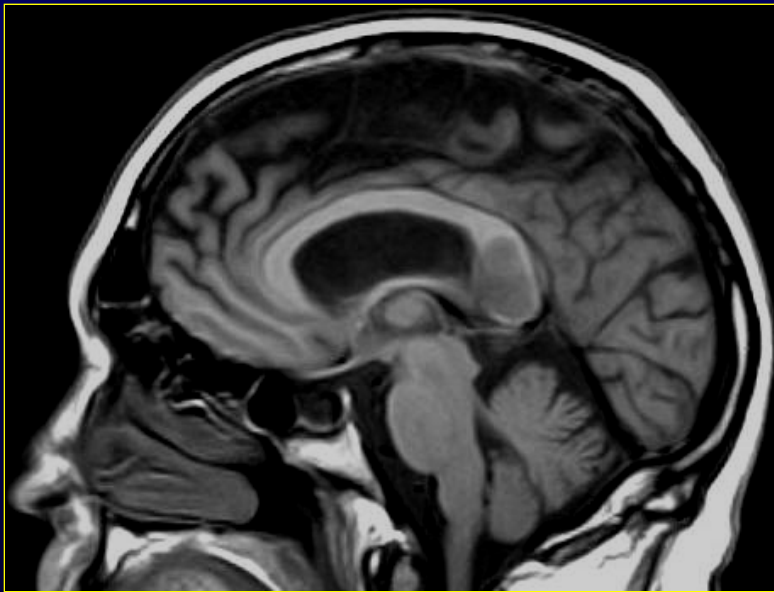
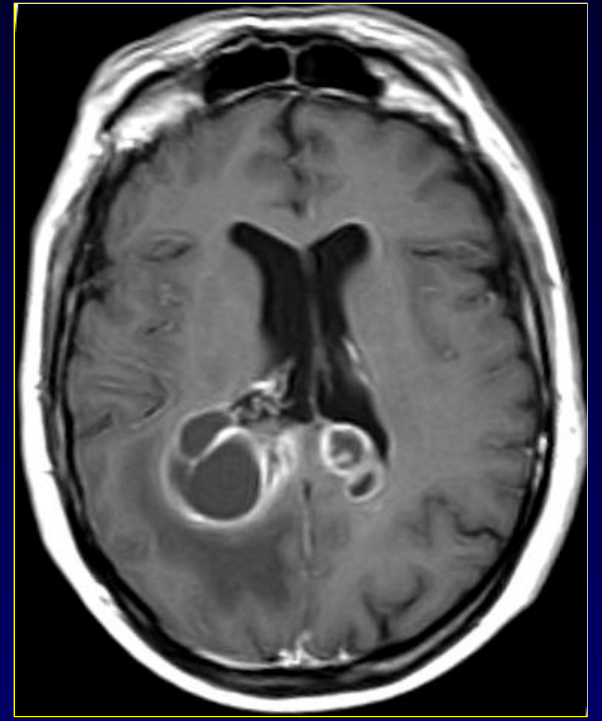
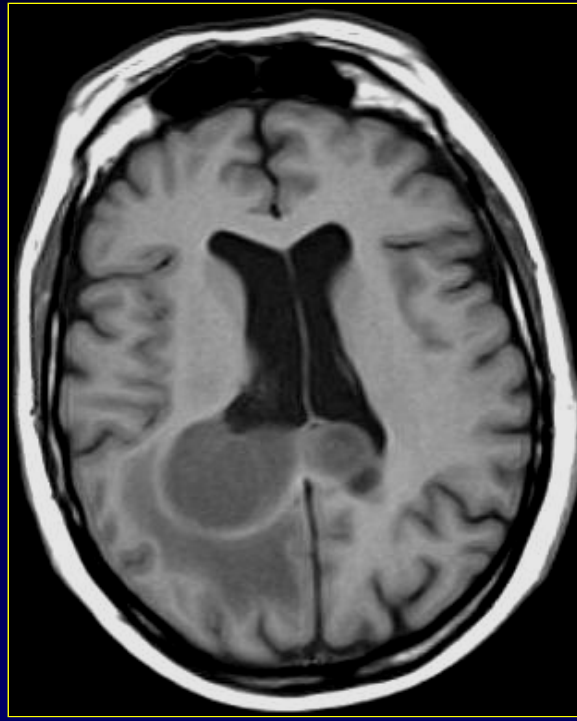
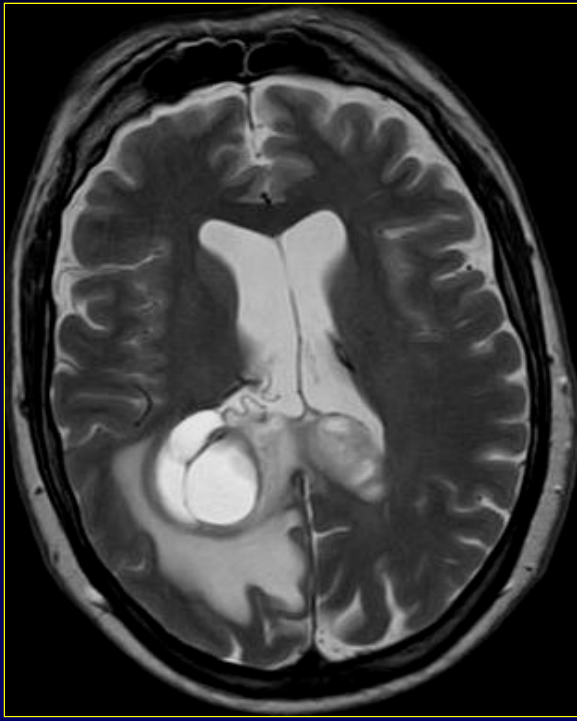










EXTENSIÓN DE LAS NEOFORMACIONES PRIMARIAS DEL ENCÉFALO

- **EXTENSIÓN TUMORAL (I)**

- A LO LARGO DE LOS TRACTOS DE SB

- FIBRAS EN U
- FIBRAS ARCUATAS
- CUERPO CALLOSO
- CORONA RADIATA
- VÍA PIRAMIDAL
- COMISURA ANTERIOR
- FÓRNICES
- OTROS

- **EXTENSIÓN TUMORAL (II)**

- A LO LARGO DE SUPERFICIES

- PIAL
- EPENDIMARIA

- MENÍNGEA

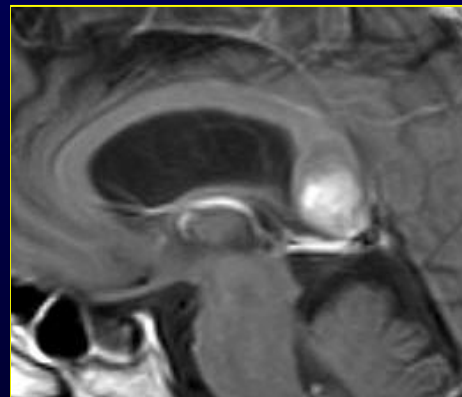
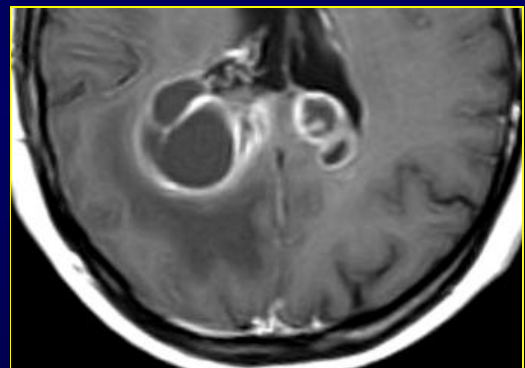
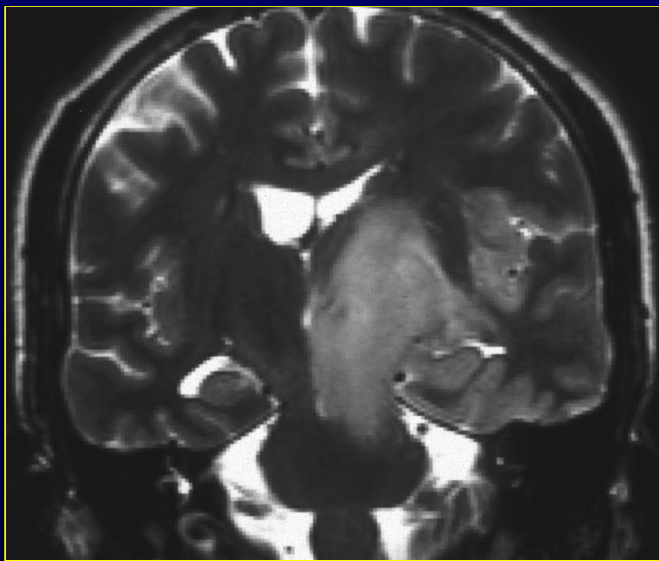
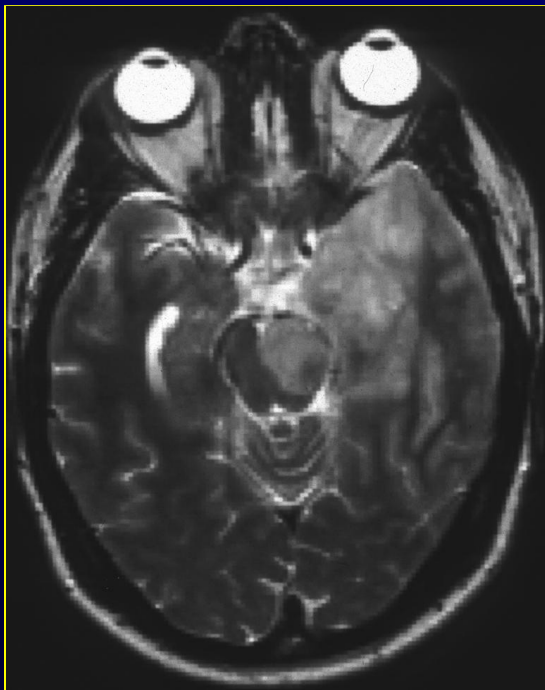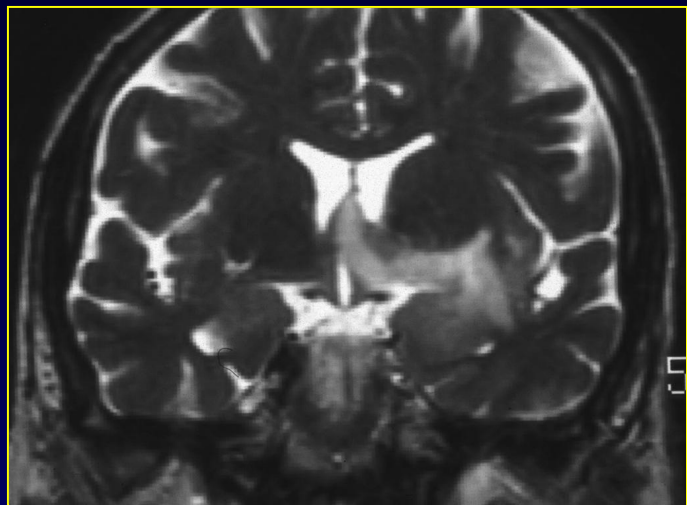
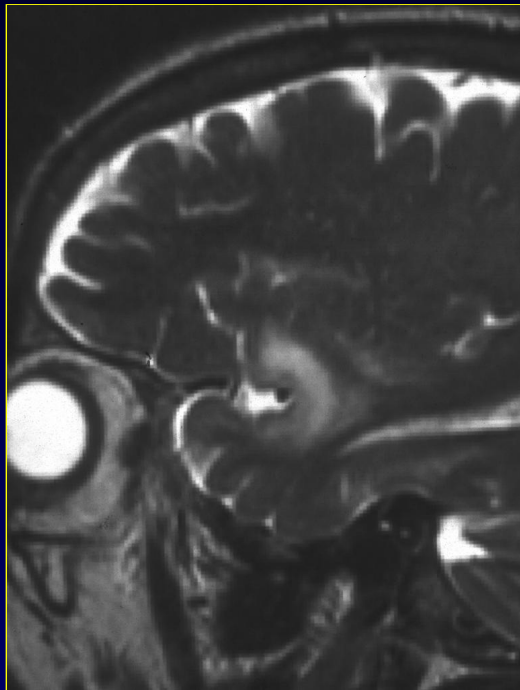
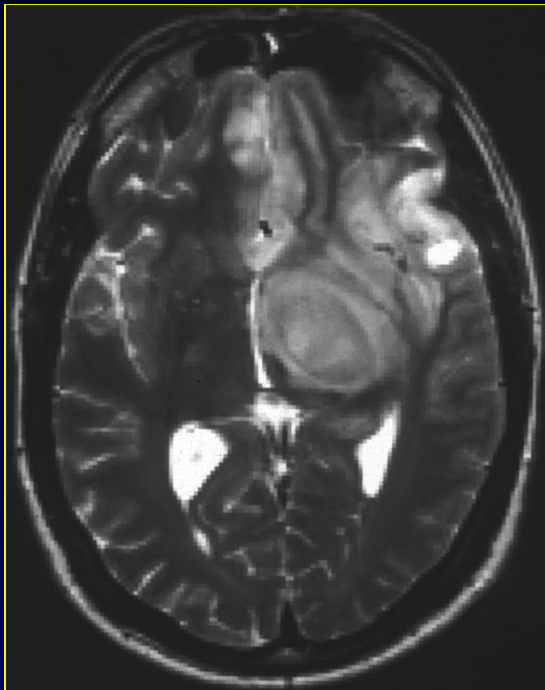- INFILTRACIÓN DURAL y ÓSEA
- SIEMBRA ARACNOIDEA

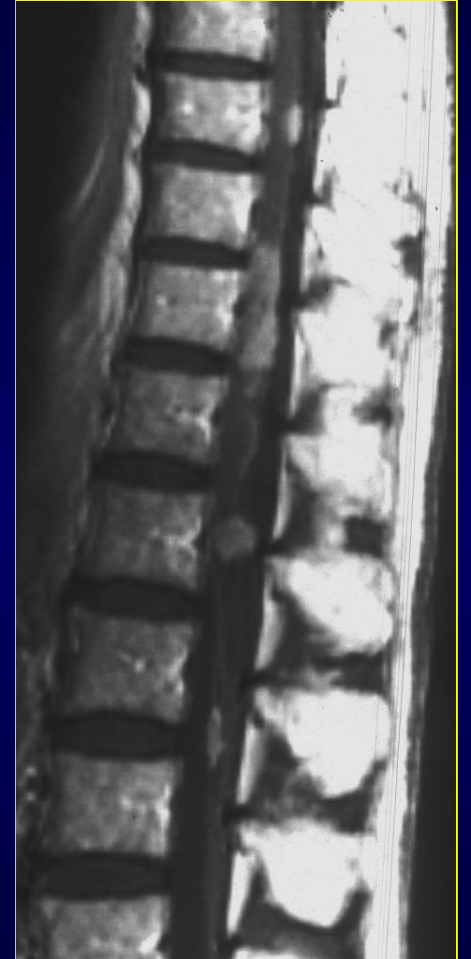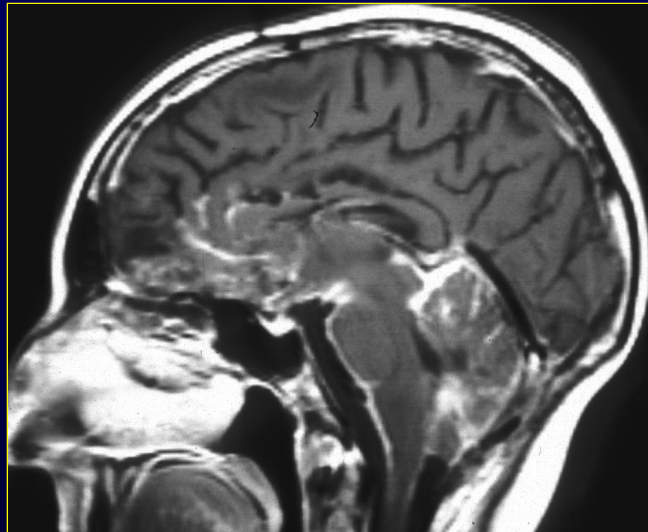
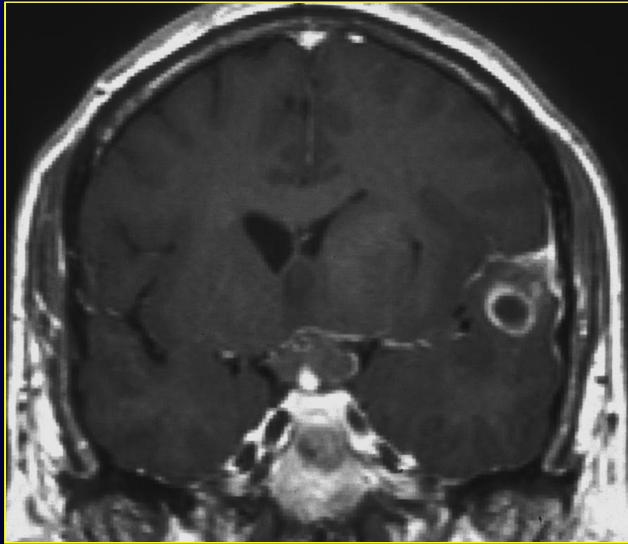
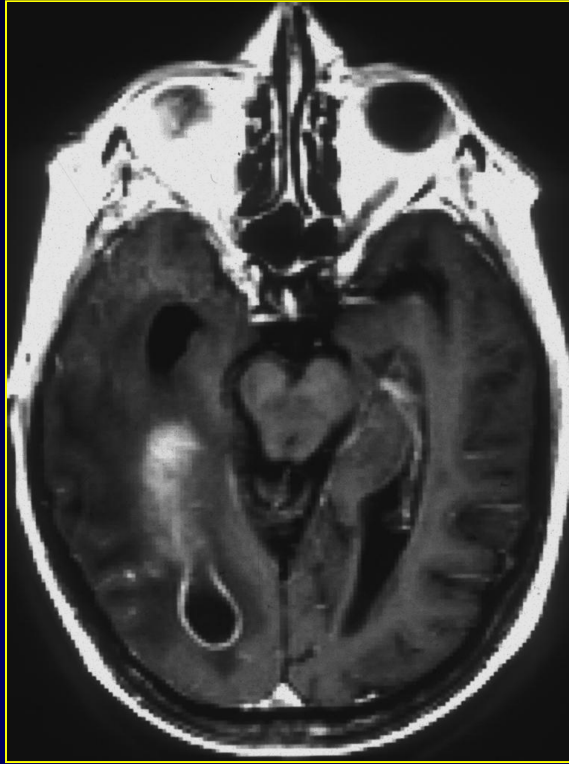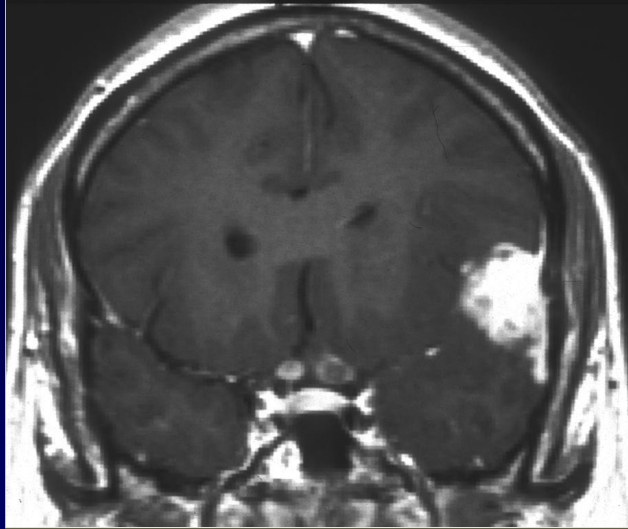
- LINFÁTICA

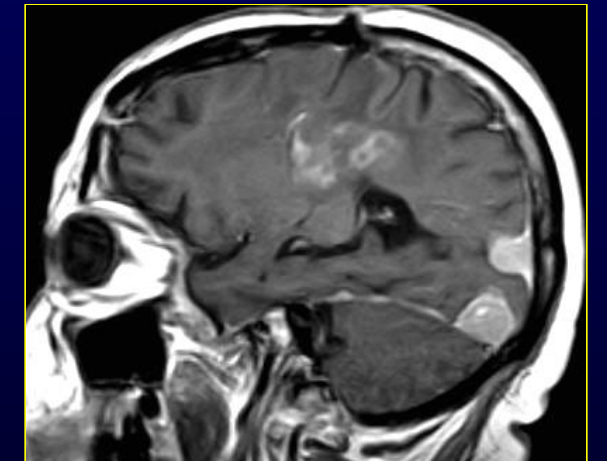
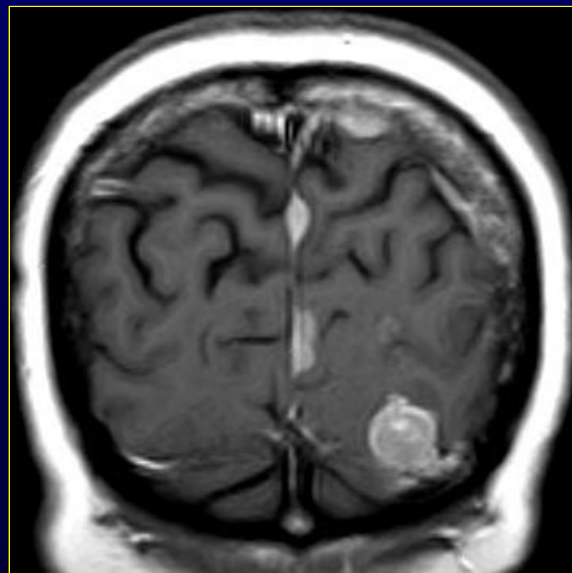
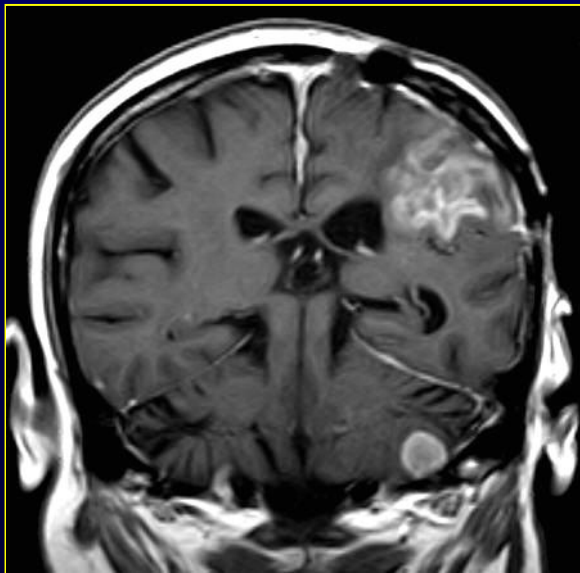
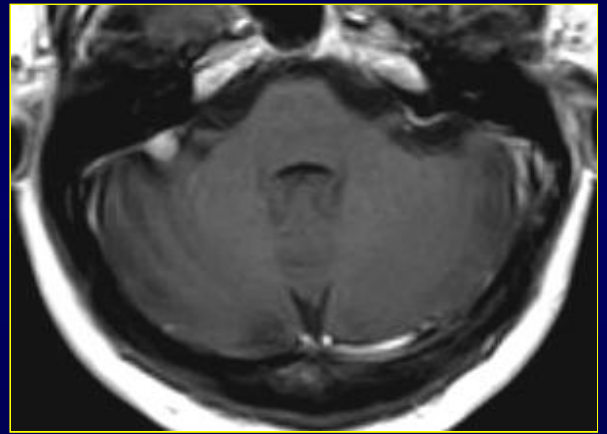
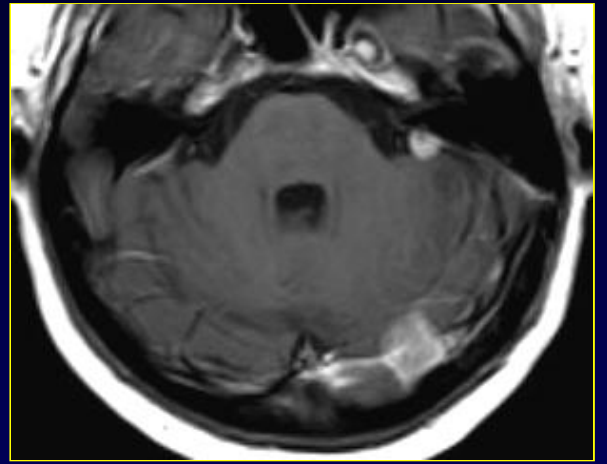
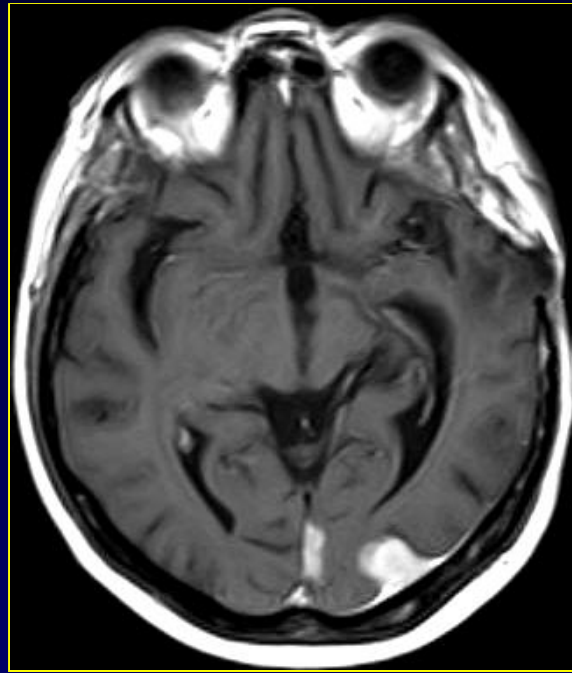
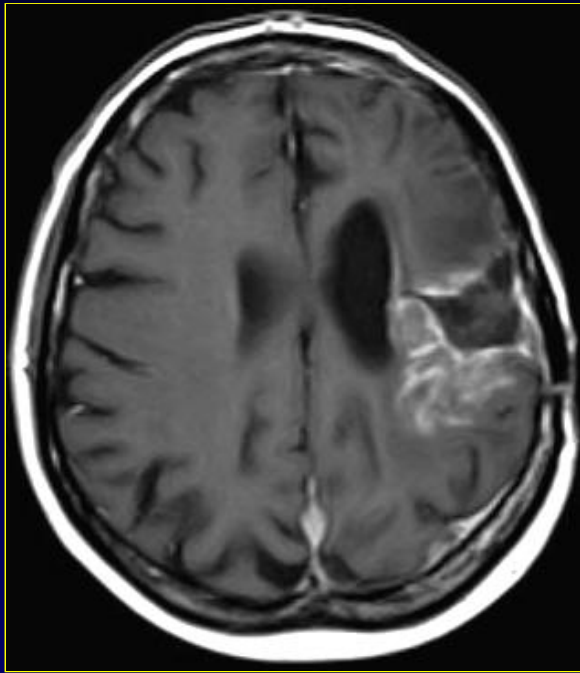
- TUMORES OPERADOS

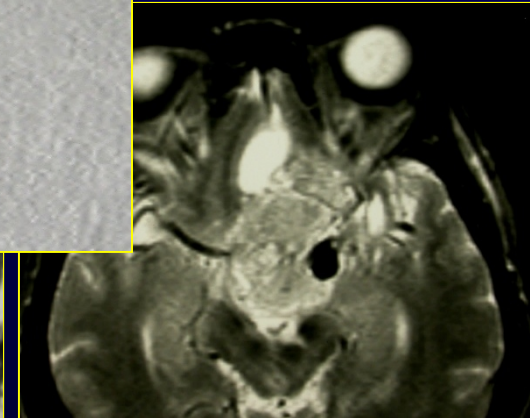
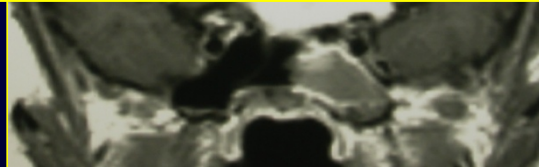
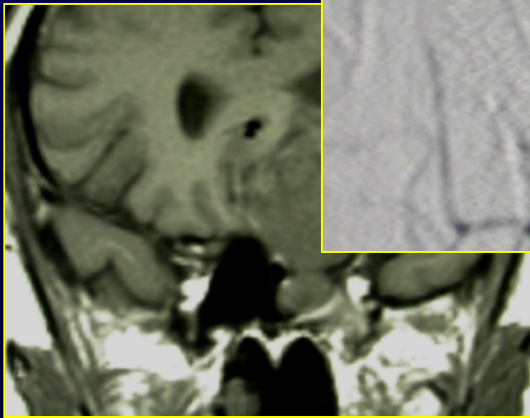
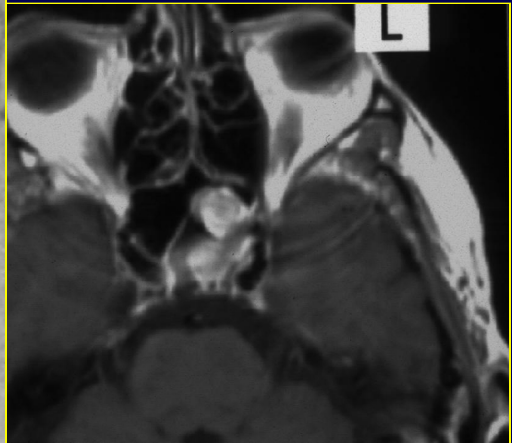
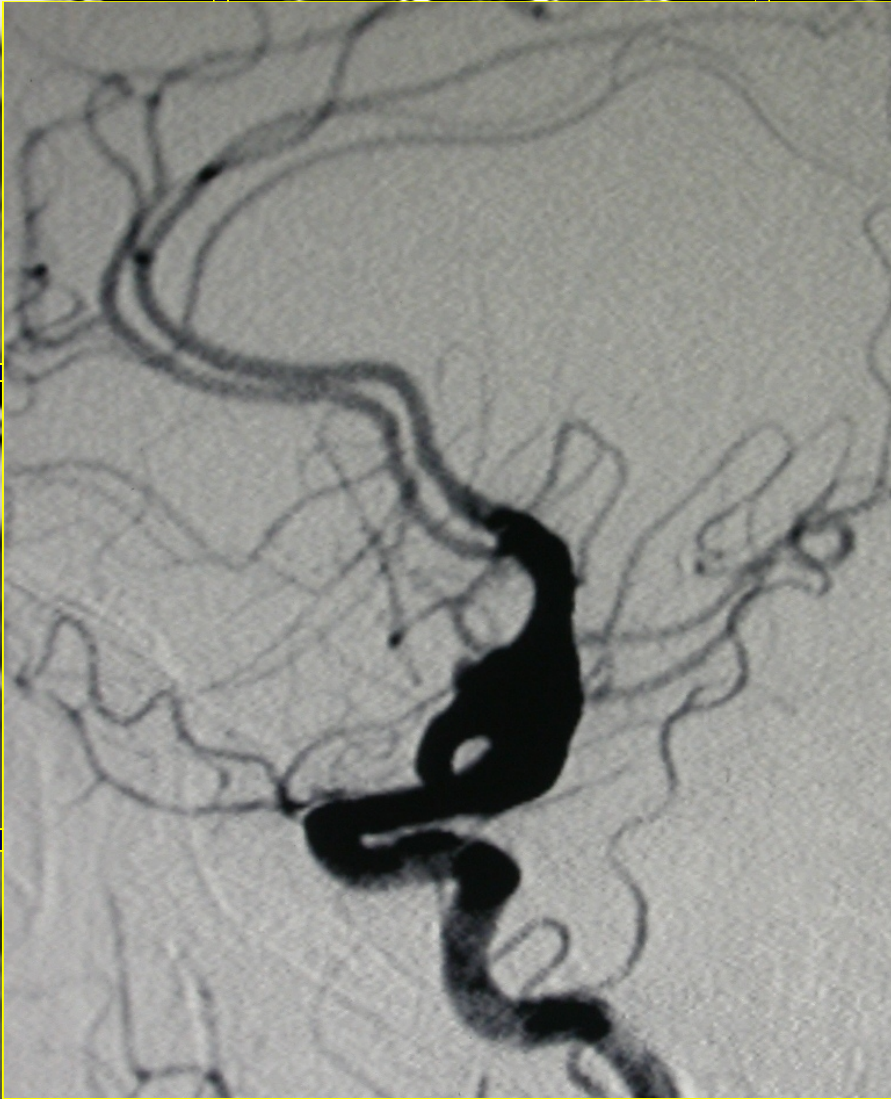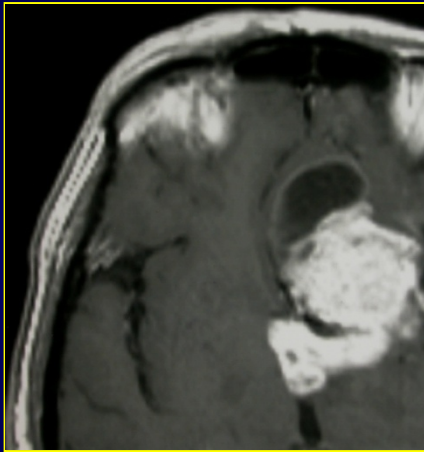
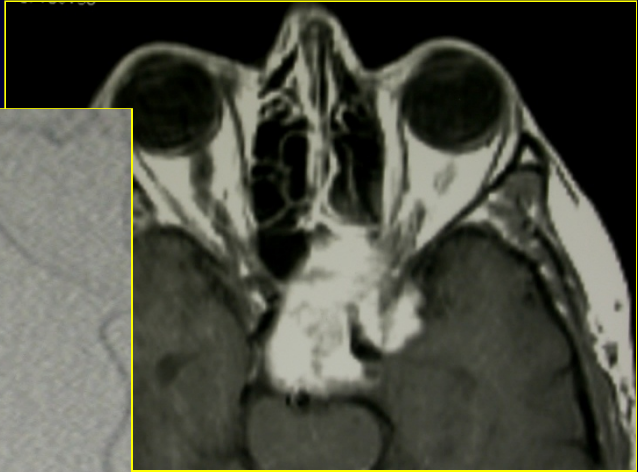
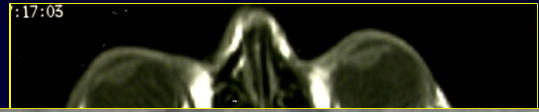
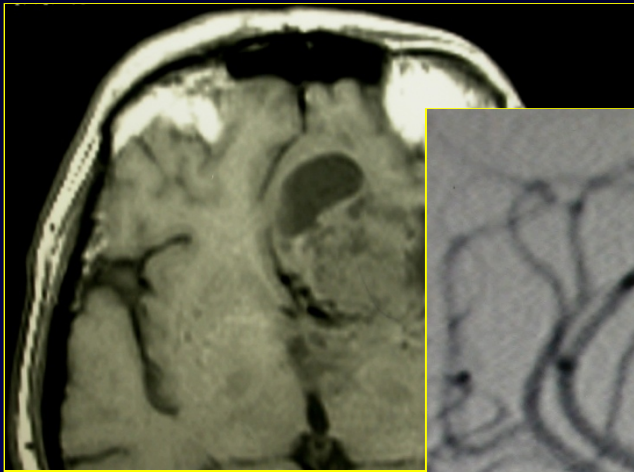
- HEMATÓGENA

- PNET / EMBRIONARIOS
- OPERADOS









PAPEL DE LAS TÉCNICAS AVANZADAS EN NEUROIMAGEN

• PAPEL CONVENCIONAL

- DIAGNÓSTICO
- TIPO
- GRADO
- EXTENSIÓN
- LUGAR DE BIOPSIA
- CONTROL EVOLUTIVO

• TÉCNICAS AVANZADAS

- DIFUSIÓN
- PERFUSIÓN
- TENSOR DE DIFUSIÓN / TRACTOGRAFÍA
- RM FUNCIONAL
- ESPECTROSCOPIA
- TÉCNICAS HÍBRIDAS
 - PET-TAC
 - PET-RM

**“NADA DEBE SER TEMIDO, SOLO
COMPRENDIDO”**

Marie Curie

TÉCNICAS AVANZADAS DE IMAGEN

- **DIFUSIÓN (DwI)**
 - CELULARIDAD
 - ESTRUCTURA INTERNA
 - HOMOGENEIDAD
 - HETEROGENEIDAD
 - AGRESIVIZACIÓN
- **PERFUSIÓN (PwI)**
 - ↑ CBV - GRADO
 - ANGIOGÉNESIS
 - RECURRENCIAS
 - AGRESIVIZACIÓN
- **ESPECTROSCOPIA**
 - ↑ Cho
 - ↓ NAA
 - ↑ Lactato y lípidos
 - Creatina variable
- **PERMEABILIDAD BHE**

- **RMF**
- **TRACTOGRAFÍA**
- **NEURONAVEGACIÓN**
- **RM INTRAOPERATORIA**

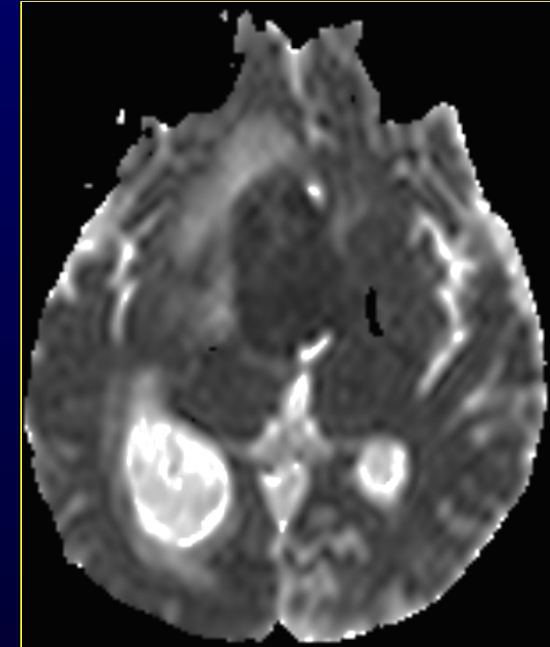
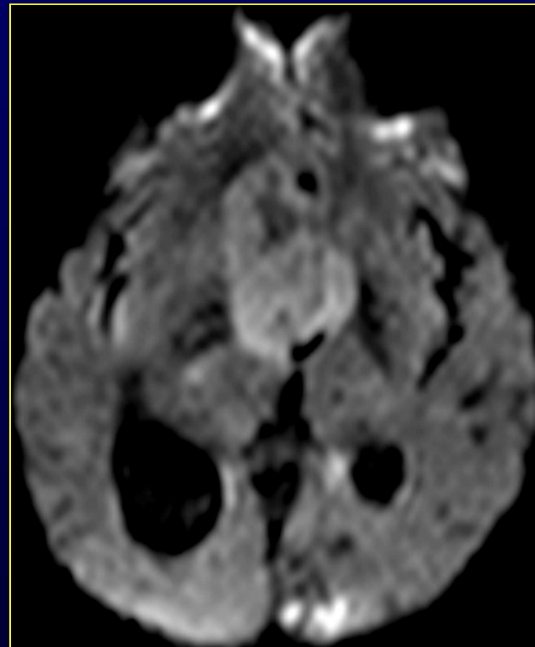
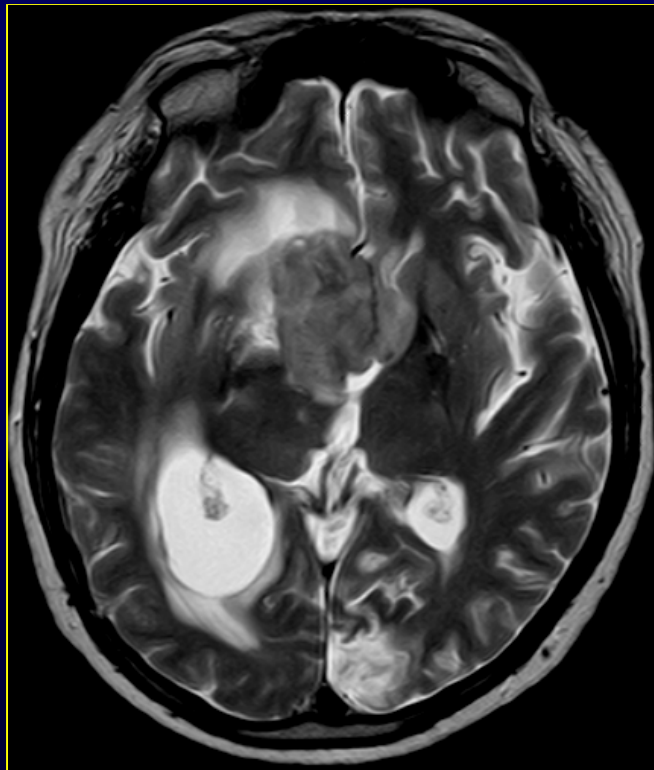
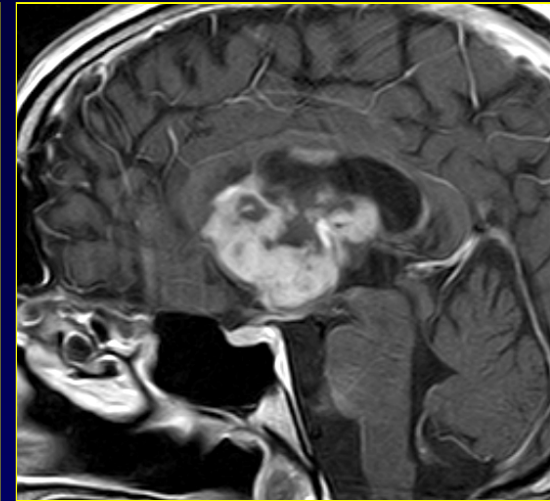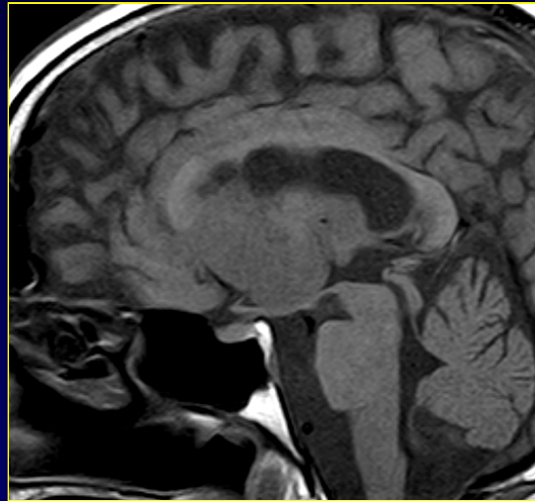
PLANIFICACIÓN
QUIRÚRGICA

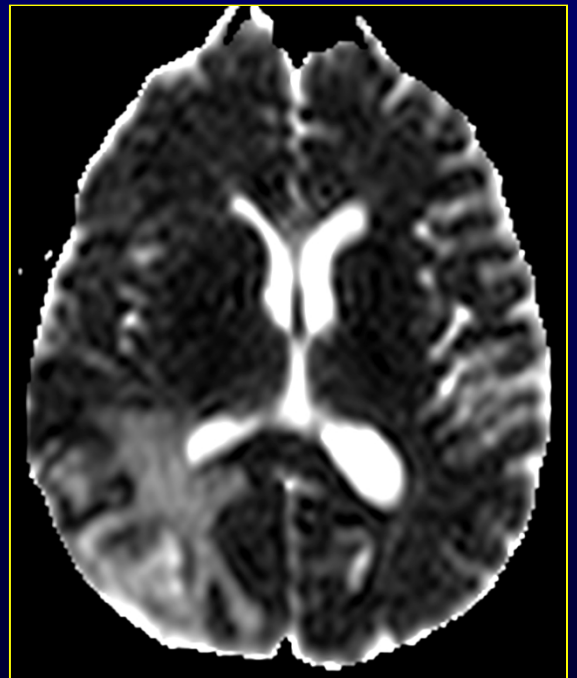
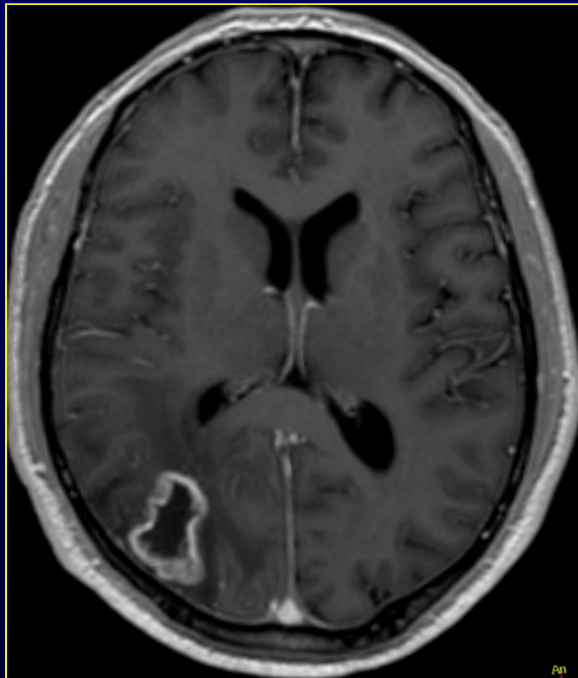
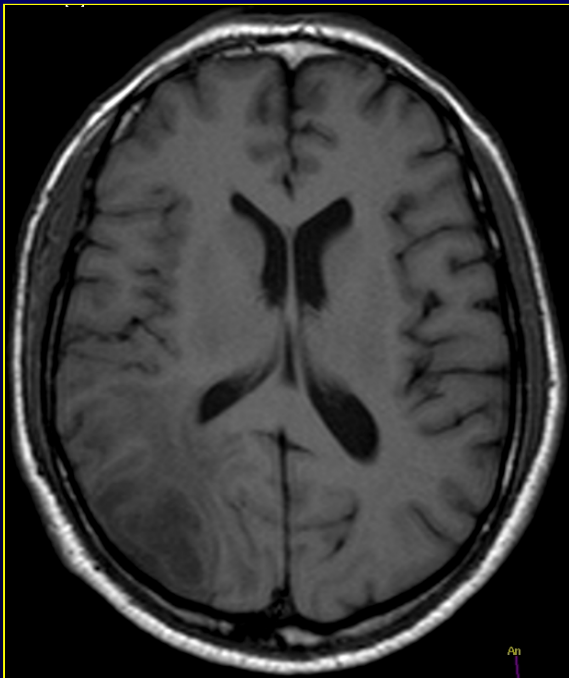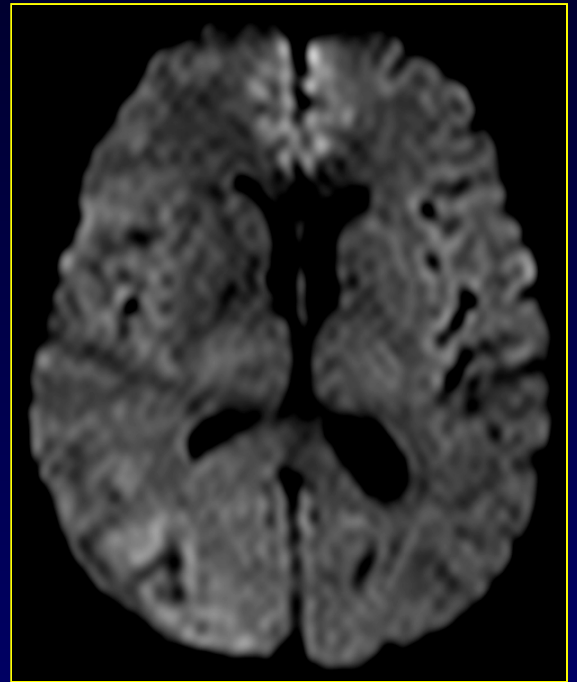
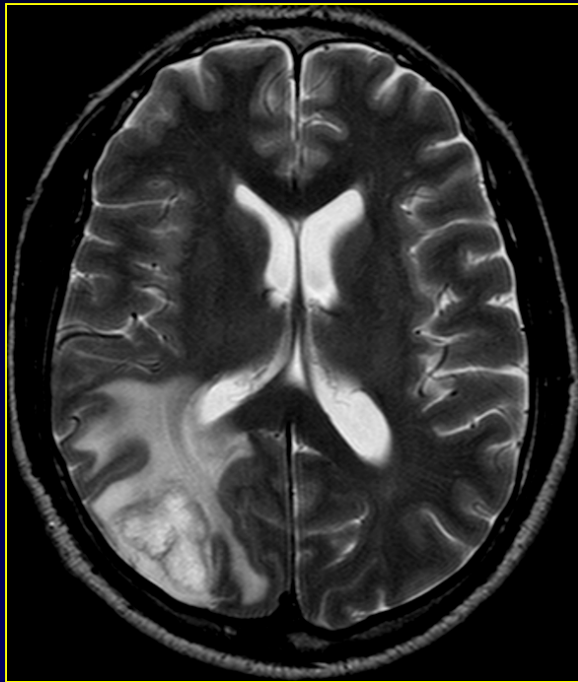
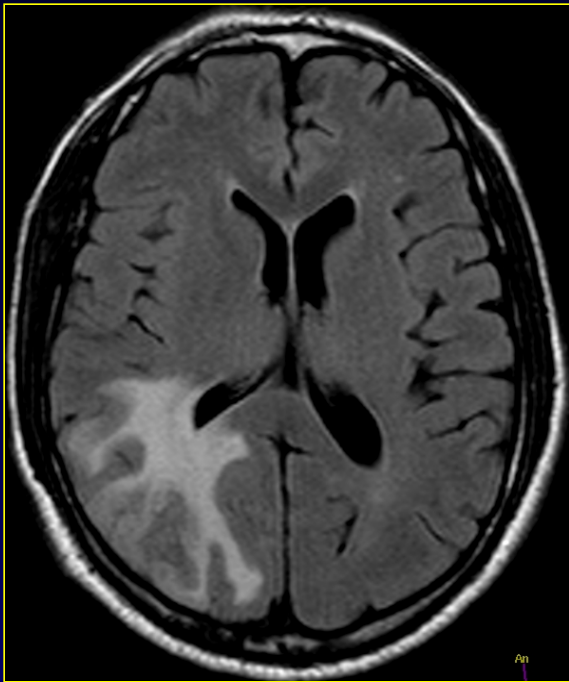
UTILIDAD DE LAS TÉCNICAS AVANZADAS DE RM

- NATURALEZA TUMORAL vs NO TUMORAL
- PRIMARIO vs SECUNDARIO
- GLIAL vs NO GLIAL
- GRADO
- EXTENSIÓN
- SELECCIÓN DEL MEJOR LUGAR DE BIOPSIA
- PREDICCIÓN DE RESPUESTA AL TRATAMIENTO
- PRONÓSTICO
- PLANIFICACIÓN DEL TRATAMIENTO
 - CIRUGÍA
 - RADIOTERAPIA
- MONITORIZACIÓN DE RESPUESTA AL TRATAMIENTO
- AGRESIVIZACIÓN

DIFUSIÓN

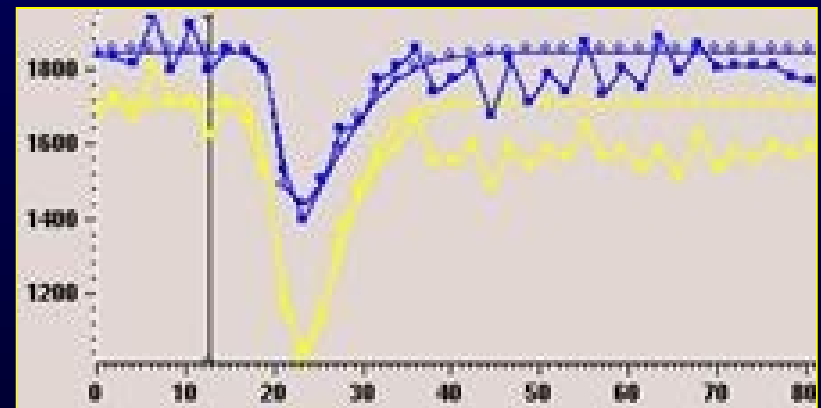
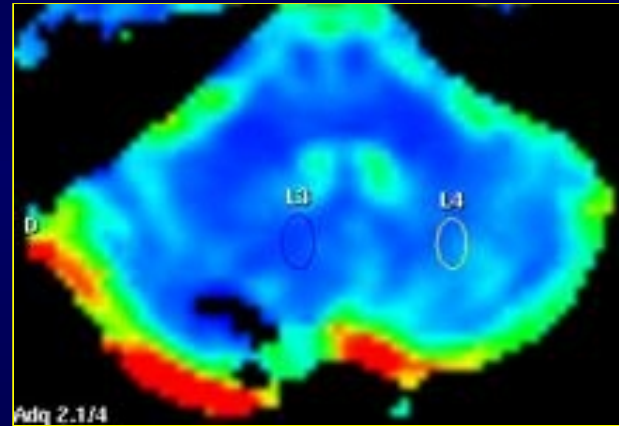
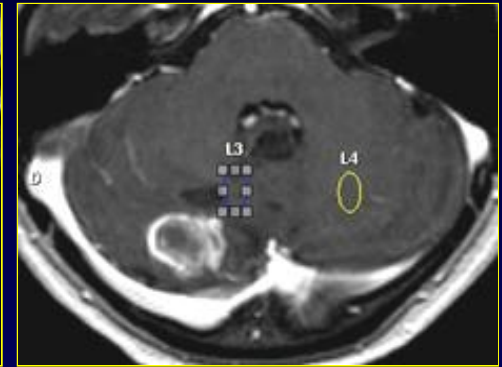
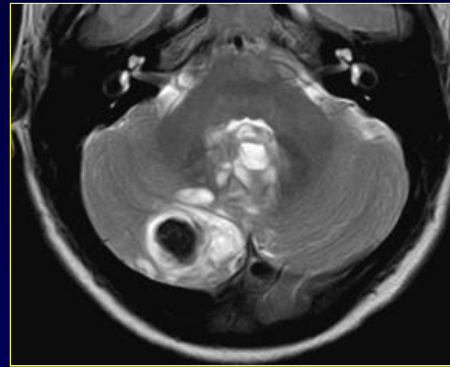- **T GLIAL vs NO GLIAL**
 - CELULARIDAD
 - GLIAL vs NO GLIAL
 - GRADO
 - TRANSFORMACIÓN



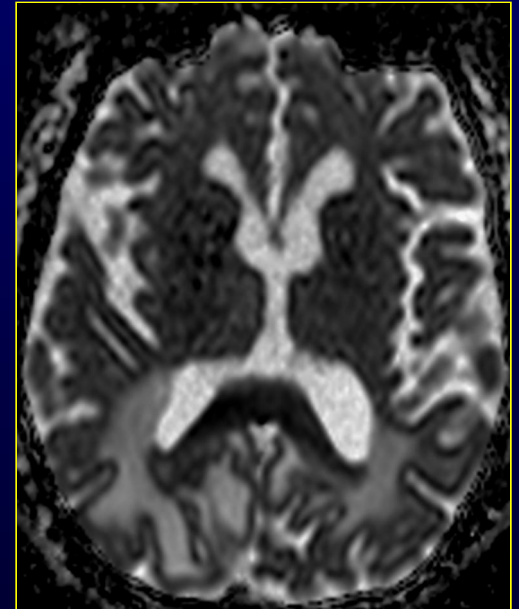
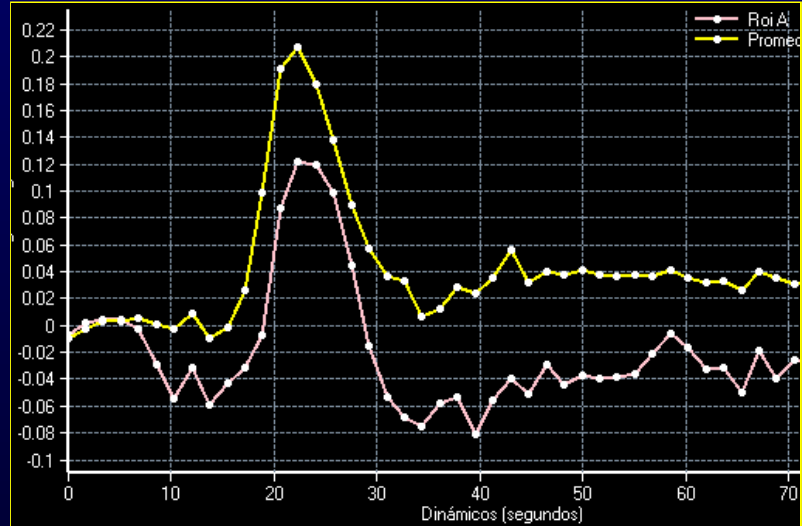
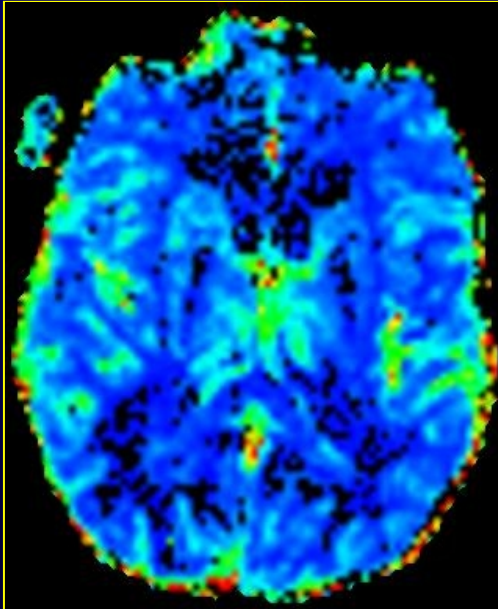
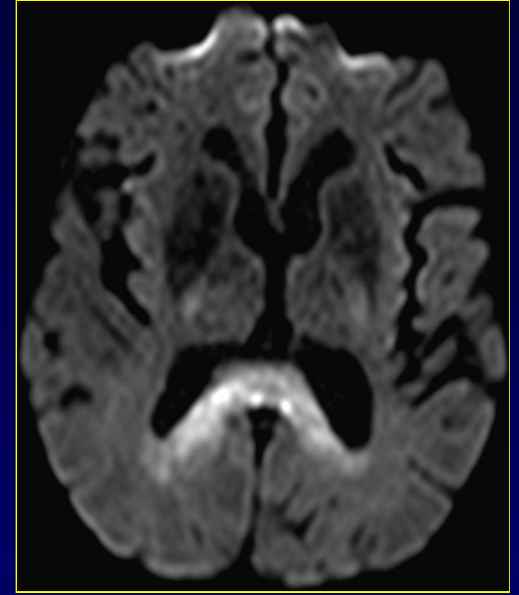
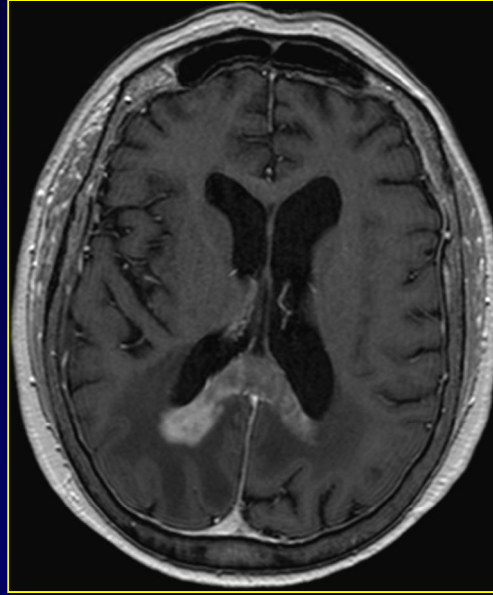
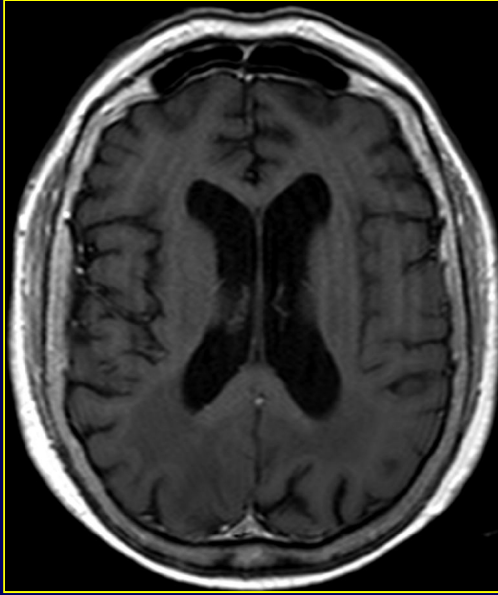


PERFUSIÓN

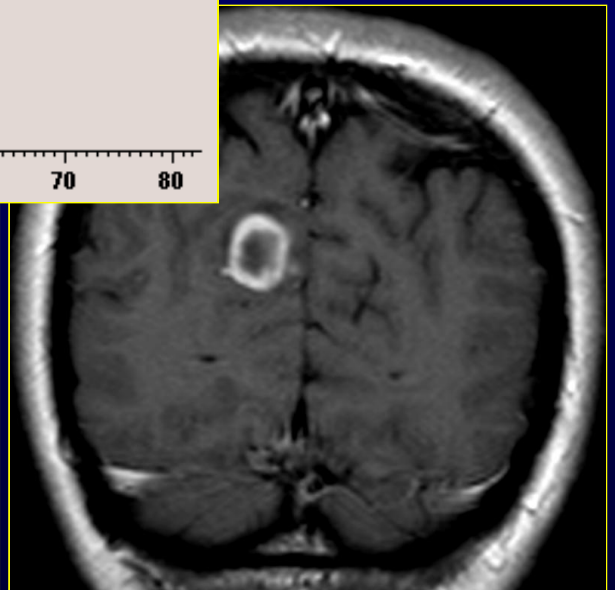
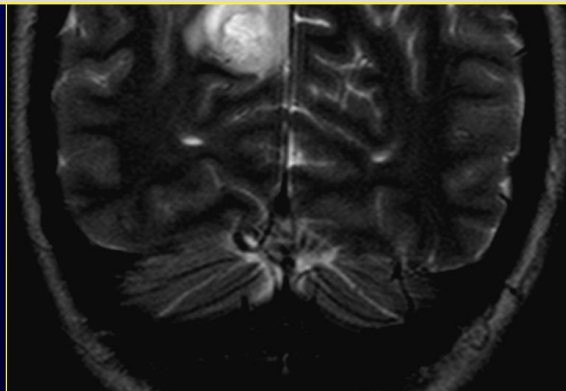
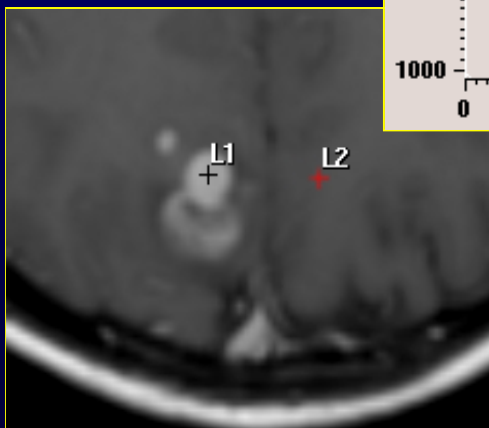
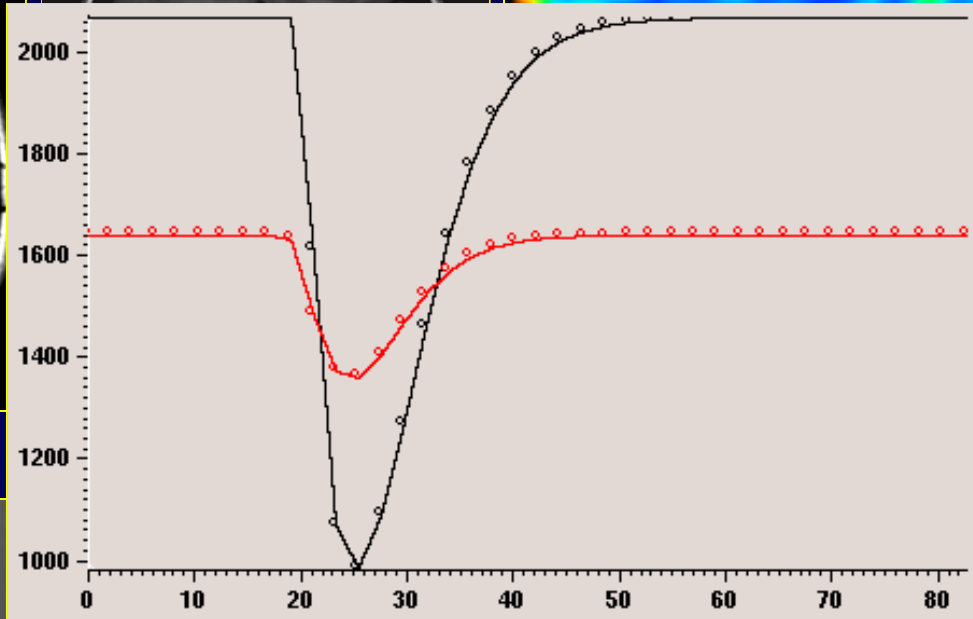
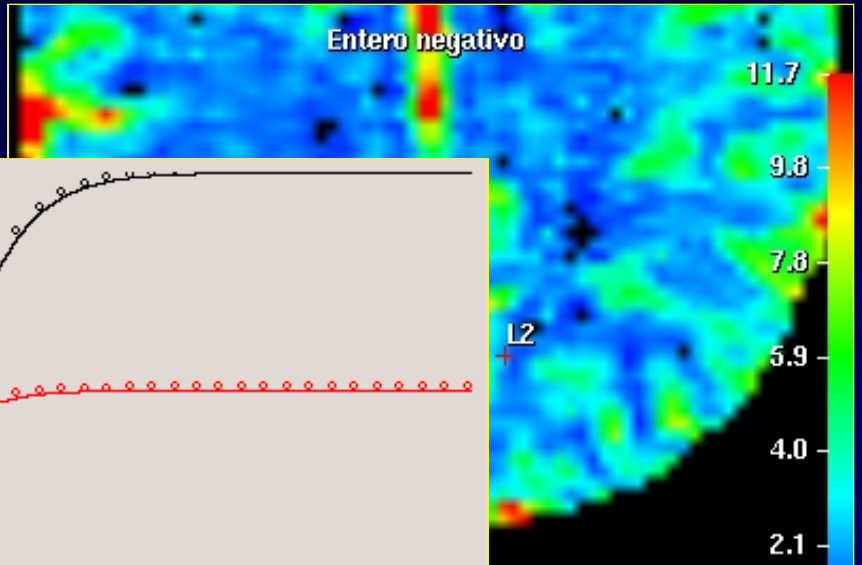
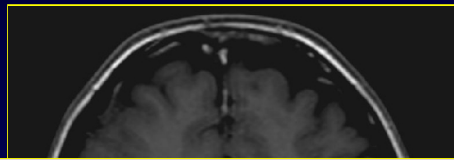
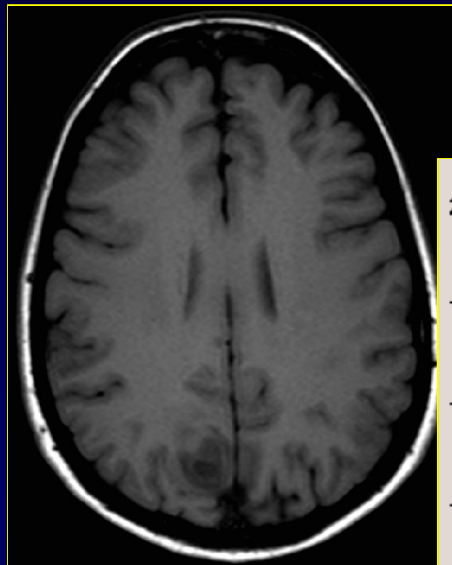
- **PRIMARIO vs OTROS**
 - ANGIOGÉNESIS
 - TUMORES Y TEJIDOS NORMALES: MICROVASCULARIZACIÓN MUY DISTINTA
 - CBV DISTINTO EN:
 - ABSCESOS
 - LINFOMA
 - METASTASIS
 - TUMORES PRIMARIOS
 - BAJO GRADO
 - ALTO GRADO
 - ANÁLISIS DE:
 - ÁREAS SÓLIDAS
 - EDEMA PERILESIONAL
 - ÁREA CONTRALATERAL



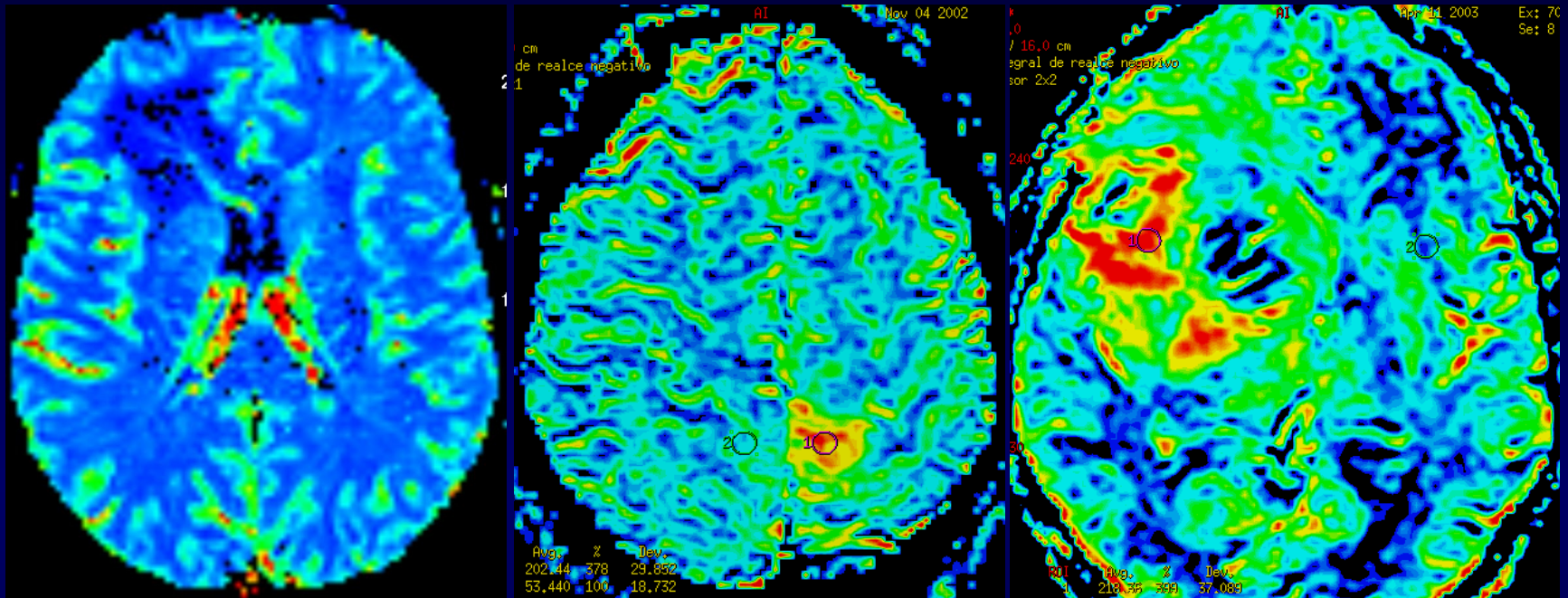
PERFUSIÓN



PERFUSIÓN



GLIOMA BAJO GRADO vs ALTO GRADO

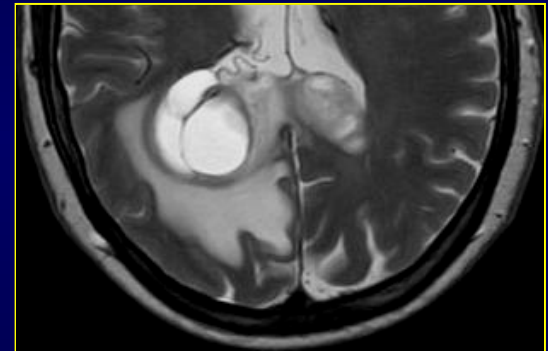


- EL **CBV** ES MAYOR EN LOS TUMORES DE ALTO GRADO QUE EN LOS DE BAJO GRADO.
- **CBV** EN TX GRADO IV > GRADO III > GRADO II
- EL **CBV** ES MUY SENSIBLE Y ESPECÍFICO PARA EL DIAGNÓSTICO DE LOS TUMORES CEREBRALES Y PARA DIFERENCIAR ENTRE LOS DE ALTO Y BAJO GRADO

AP: NUEVOS CONCEPTOS

- **CONCEPTO CLÁSICO: “EDEMA-PLUS”**

- EDEMA + TUMOR
- CAUSA VARIACIÓN ENTRE OBSERVADORES
- MÁRGENES MUY POCO CONCRETOS
- RECURRENCIA TUMORAL
 - MARGEN Q_x
 - A DISTANCIA
 - REMOTA



- **NOVEDAD: ANGIOGÉNESIS**

- FORMACIÓN DE NEOCAPILARES DESDE VASOS PREEXISTENTES
 - COMPONENTE ESENCIAL DE LA PROGRESIÓN
 - FACILITA LA EXTENSIÓN TUMORAL

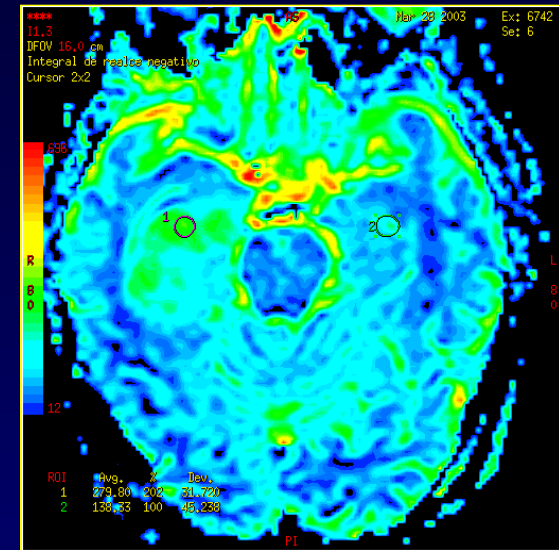
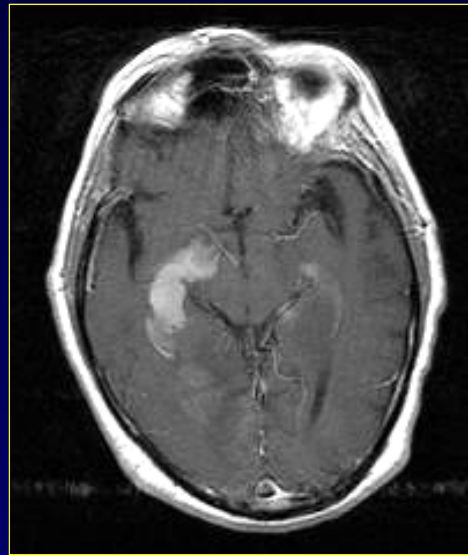
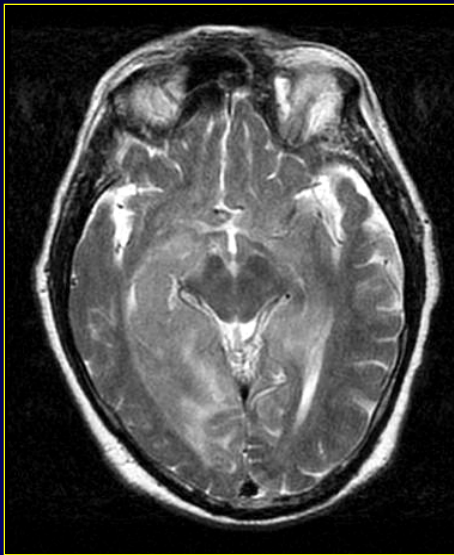
SOLUCIONES

- **BIOMARCADORES APROPIADOS**
 - NINGUNO 100% CERTERO
- **UTILIDAD**
 - DETERMINACIÓN DE LA EXTENSIÓN REAL DEL TUMOR
 - ACTIVIDAD
 - CRECIMIENTO

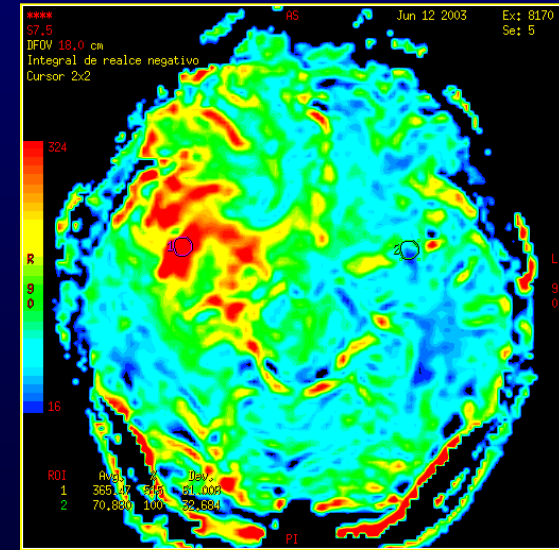
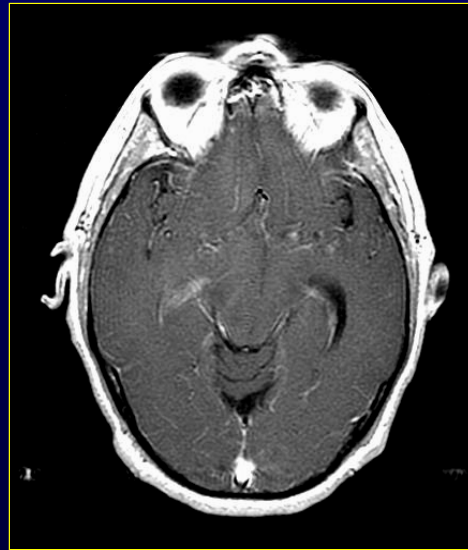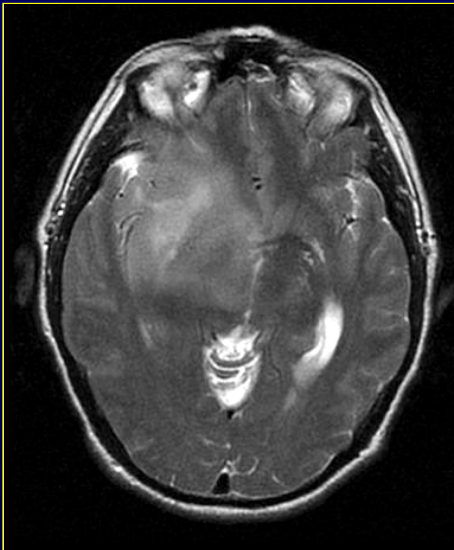
RM / TC
CONVENCIONAL + CIV
DWI
TDI
PWI
PERMEABILIDAD BHE
MRS

GLIOMA BAJO GRADO vs ALTO GRADO

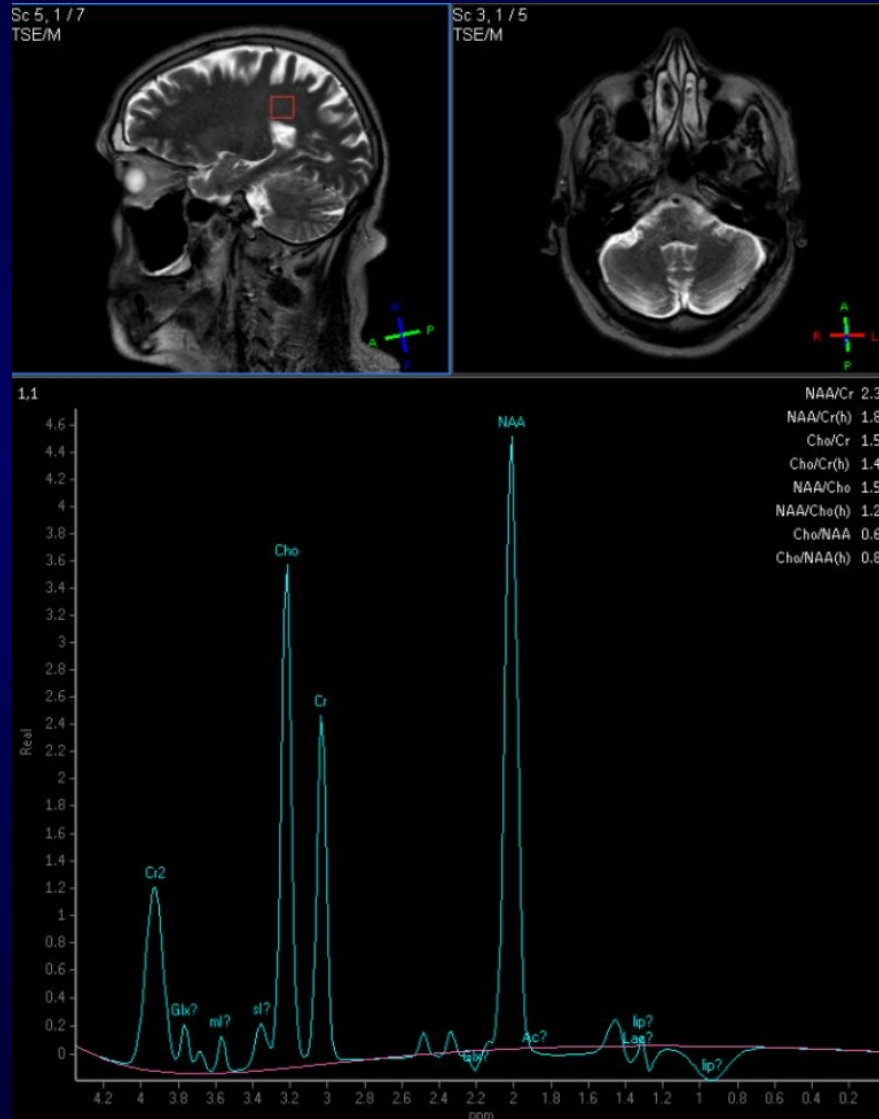
ANAPLÁSICO



GLBMF

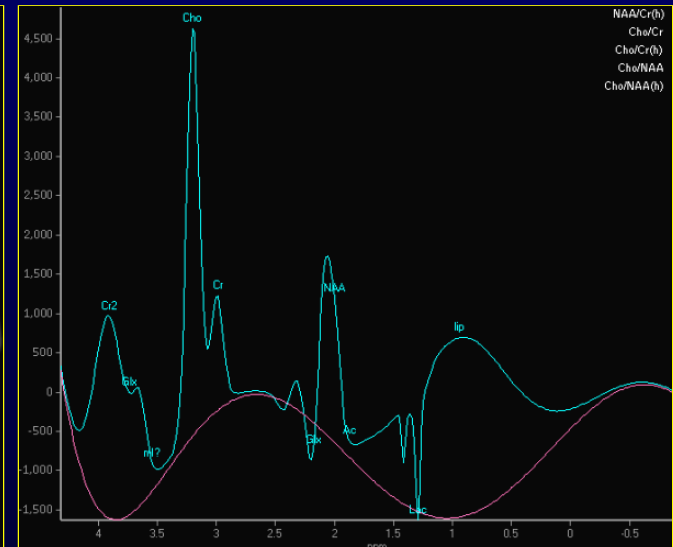
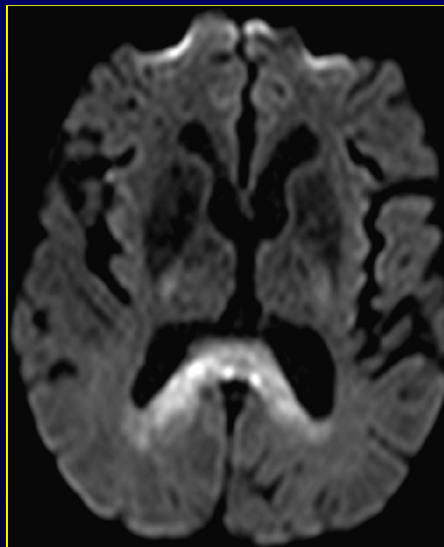
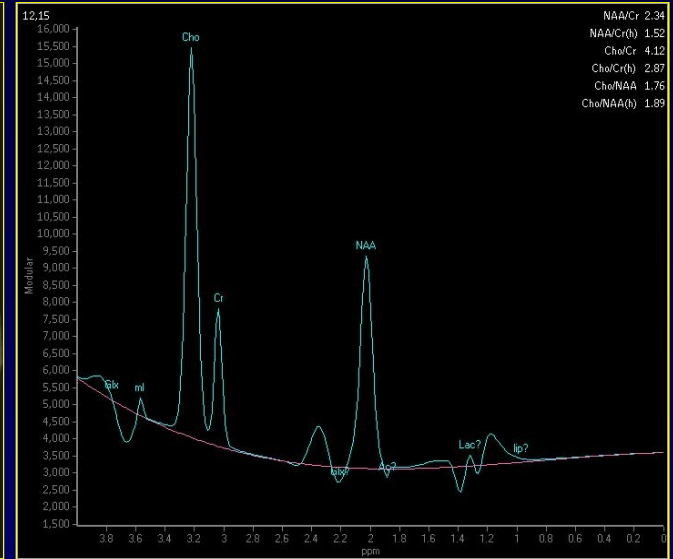
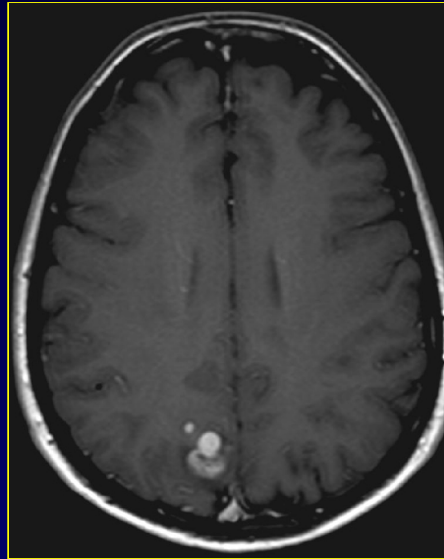


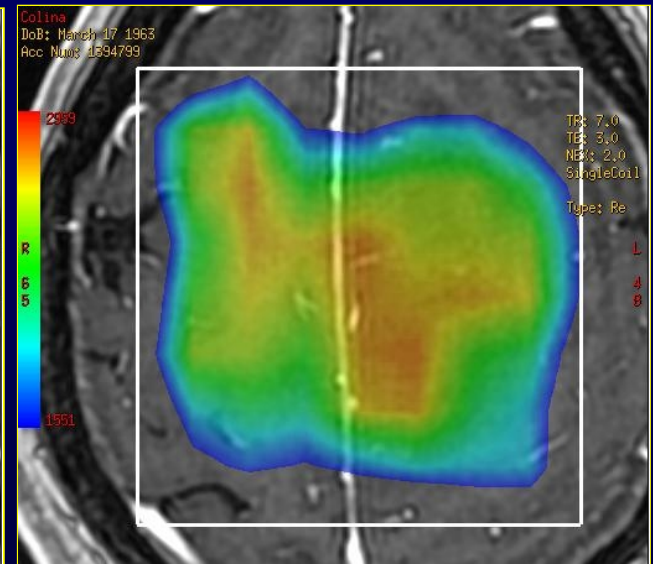
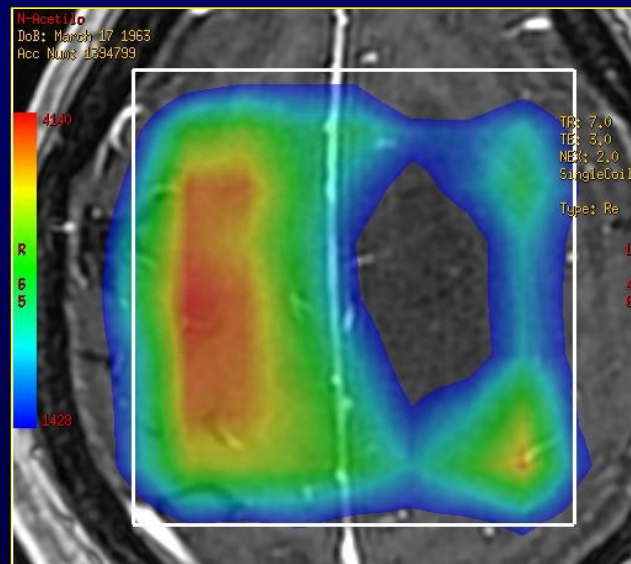
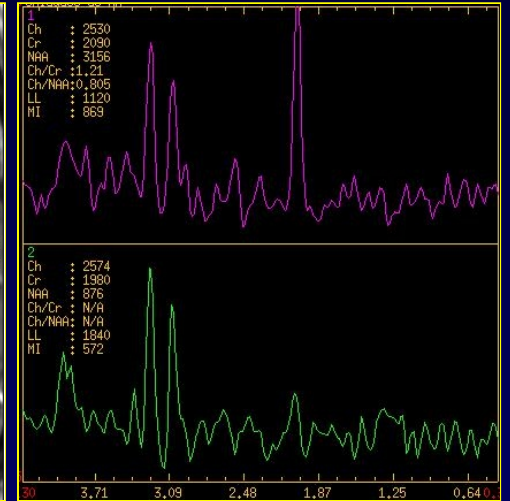
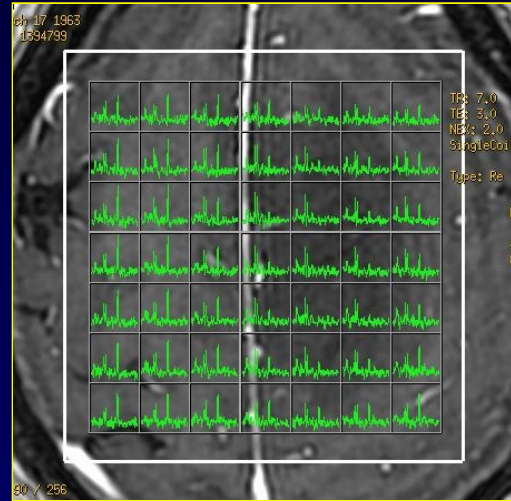
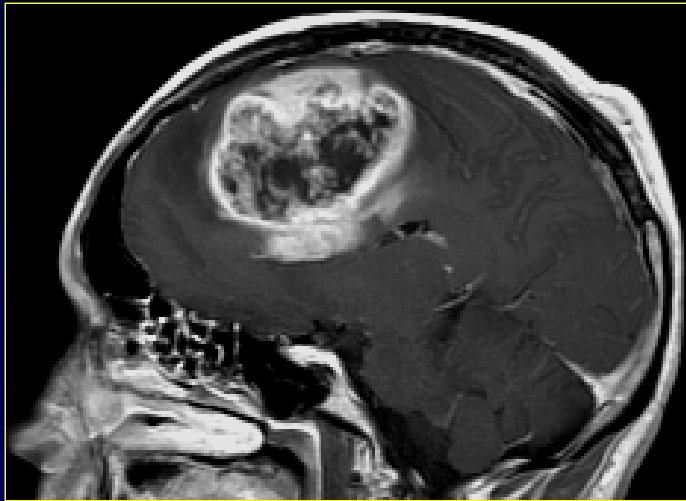
OTROS



OTROS

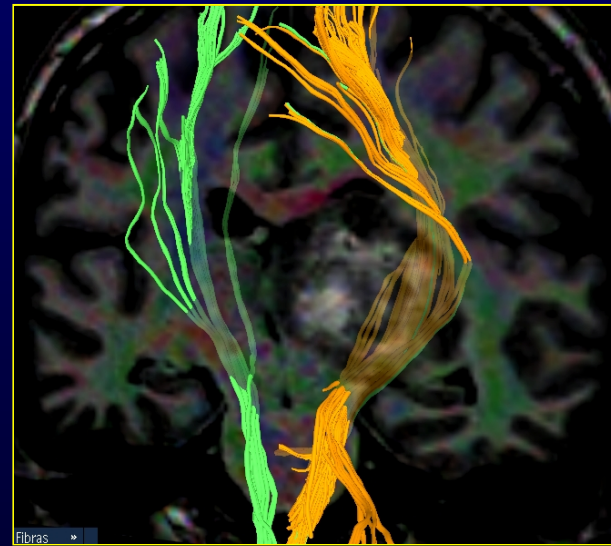
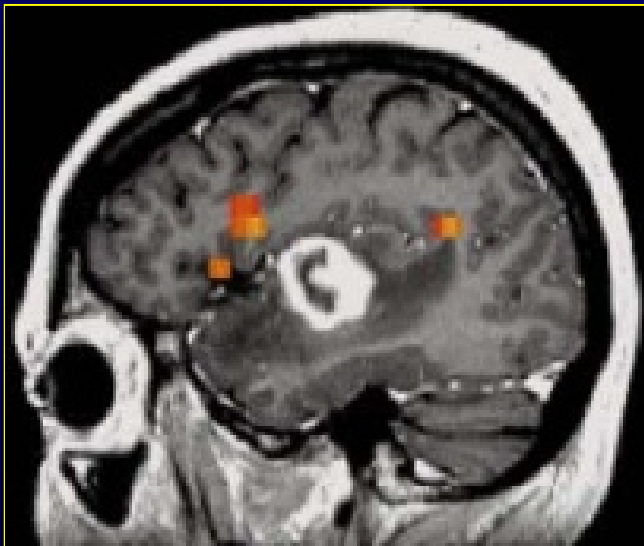
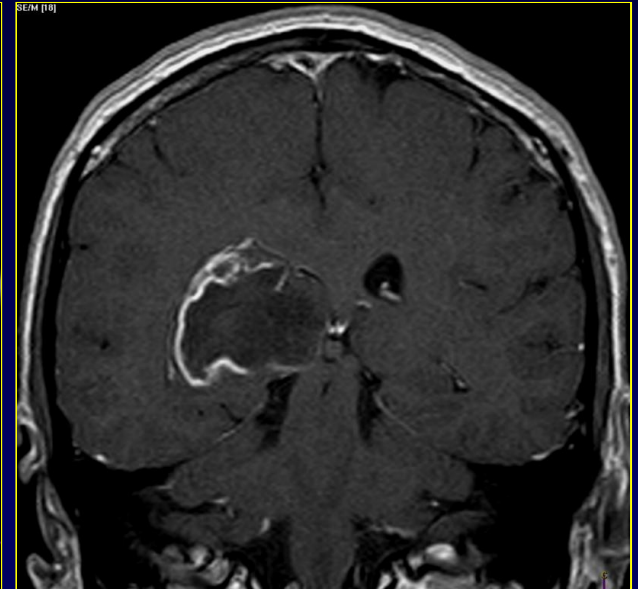
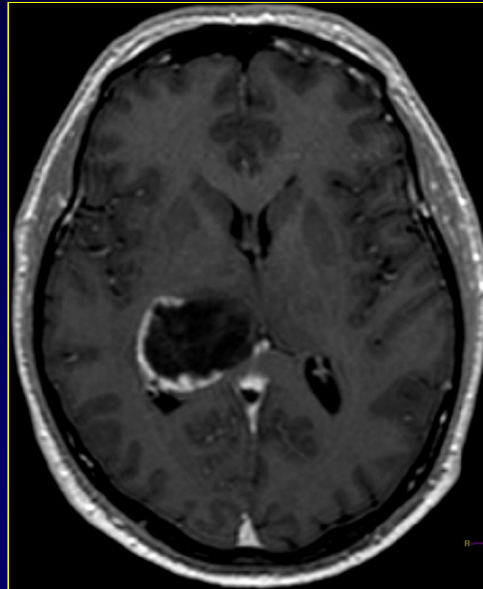
- **MRS**
 - UNI / MULTIVOXEL
 - DD (+/-)
- **ANÁLISIS**
 - ÁREAS SÓLIDAS
 - EDEMA – PLUS





PLANIFICACIÓN QUIRÚRGICA

RMF
TRACTOGRAFÍA
NEURONAVEGACIÓN
RM INTRAOPERATORIA



Todos somos muy
ignorantes, pero no todos
ignoramos las mismas
cosas.

Albert Einstein

Medicina Basada en
la Experiencia

Medicina Basada en
la Evidencia

Medicina Basada en
la Obediencia

