

## Frontal Fibrosing Alopecia

Susan Mehboob Holmes\*

Department of Dermatology, Alan Lyell Centre for Dermatology, Glasgow, UK

\*Corresponding author: Susan Mehboob Holmes, Department of Dermatology, Alan Lyell Centre for Dermatology, Glasgow, UK, Tel: 00491744721103; E-mail: mehboobhaque906@gmail.com

Received date: January 17, 2017; Accepted date: February 21, 2017; Published date: February 28, 2017

Copyright: © 2017 Holmes SM. This is an open-access article distributed under the terms of the Creative Commons Attribution License, which permits unrestricted use, distribution, and reproduction in any medium, provided the original author and source are credited.

### Abstract

Frontal fibrosing alopecia, described simply over two decades in the past, has come to be probably the most normally noticeable causes of scarring phalacroasis at several skilled hair clinics. Regarded a medical variant of lichen planopilaris (LPP), its uncommon components and associations that distinguish it from LPP. Despite the fact that largely affecting post-menopausal ladies, a small however growing number of guys and premenopausal ladies are affected. The spectrum of the ailment has accelerated from involvement of the frontal hairline and eyebrows, to potentially affecting the whole hairline, facial and body hair. Genetic and environmental motives were implicated however the aetiology remains uncertain. A range of cures had been used in management of the, however medical trials are required to set up effectiveness.

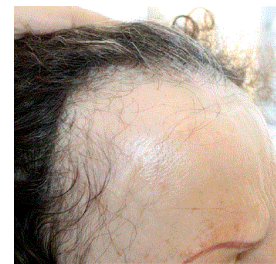**Keywords:** Frontal fibrosing alopecia; Lichen planopilaris

### Introduction

Frontal fibrosing baldness (FFA) was initially delineated in 1994 by Kossard as a fresh style of scarring baldness [1]. Clinically, the vesicle aspects regarded capable lichen planopilaris (LPP) nonetheless, the pattern of the sickness used to be distinctive from average LPP in a couple of approaches [2]. To begin with, these affected were solely postmenopausal females. Secondly, the resulting in a wonderful pattern of alopecia touching the frontal hairline, related to loss of eyebrows. Histologically, the findings are indistinguishable from LPP, with reduction in follicle numbers, perifollicular pathology, perifollicular bodily fluid infiltrate and cyst interface eczema [2]. On account that this 1st description, FFA has been the topic of quite eighty papers. The clinical spectrum of the sickness has also elevated. As good as eyebrows, eyelashes could also be lost [2,3] and involvement of facial vellus hairs will overtimes end in tiny flesh colored facial papules [4-6]. Limb and flexural hair are on the whole affected, more commonly without a related signs or rash [7,8]. The condition now not solely influences postmenopausal females as a small however growing number of instances had been suggested in premenopausal females and in guys [9]. There could also be differing ethnic susceptibility: FFA is most traditionally recorded in Caucasian females, being suggested much less normally in black ladies [10,11] and rarely in Asians [12,13]. Nevertheless, it has been steered that in black sufferers, FFA is under-famous as it most of the time co-grants with traction alopecia [10,11].

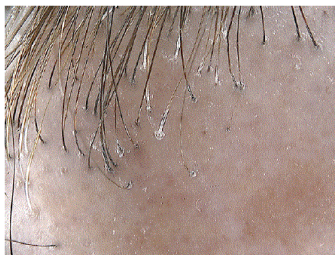The scientific and histologic similarities between FFA and LPP endorse that FFA could be a scientific variant of LPP [2]. Like LPP, [14] an accelerated association between FFA and disease, exceptionally thyroid, has been illustrious [3,15] but, there square measure variety of areas within which FFA seems to fluctuate from classical LPP. First of all, FFA influences predominantly females: in two tremendous circumstances sequence, male to feminine (M:F) ratio ranged from 1:289 to 1:31, whereas in LPP, M:F has been calculable at between 1:1.8 to 1:49 [16]. Lichen planus moving alternative websites (cutaneous, nail, mucosal) is seen additional usually in association with LPP (28–

50%) [17,18] than with FFA (1.6–9.9%) [3,9,15] lack of facial and hair concomitant with LPP is suggested in 7-10% (Figure 1) [16,18].



**Figure 1:** Frontal fibrosing alopecia.

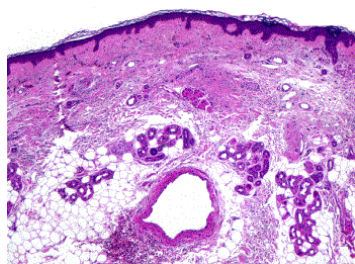
In FFA, lack of eyebrows has been said in round 80% of cases [2,4,9,15] and may just every now and then precede loss of hairline. [3,15] lack of eyelashes is distinctive [2,3,9] and has been related to more severe disorder [9], loss of hair conjointly happens, moving each limb and flexural hair. Loss of hair from limbs has been documented in round 20-25% of sufferers in massive case sequence [3,9,15] but affected seventy seven% of patients in a smaller case series and was once tested histologically. Unlike ordinary LPP, loss of hair from eyebrows and body in FFA is clinically mostly non-inflammatory [7]. Classical diffuse LPP somewhere else on the scalp has been stated in organization with FFA in one sixteenth percent [2,3,9,15]. Whereas scalp LPP is especially a complaint of terminal pigmented hairs, it's been suggested that in FFA, vellus and intermediate hairs square measure affected preferentially, [8,19] though this has not been confirmed in an added gain information of [7] ironically, most terminal pigmented hairs on the scalp square measure unaffected in FFA, with handiest these on the hairline involved. Symptoms also will be less frequent in FFA [3,9,19] (3-55%) than in LPP (60-70%) [18]. However this has not been validated in all case sequence (Figure 2) [15,20].



**Figure 2:** Affected scalp with alopecia.

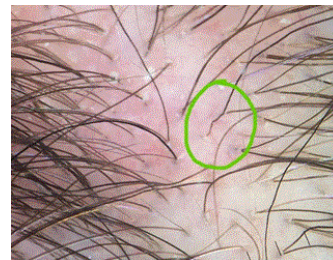Currently, there is not any epidemiological information on the incidence or incidence of FFA in the basic populace. Nevertheless, most papers released over latest years advise that the incidence of FFA could also be growing [3,4,9,15,21]. Diagrams from my possess hair hospital in Glasgow, UK show that the numbers of recent circumstances of FFA have increased vastly over the last 16 years, each in terms of absolute number and as a percent of the whole number of latest circumstances obvious yearly.

It must be borne in mind that there are talents sources of bias inherent in this form of knowledge: for example, when a brand new situation is described, it is possible that the number of recorded instances will expand as attention of the situation increases amongst clinical practitioners. However, as FFA progresses slowly and could also be asymptomatic, the recognized circumstances may characterize simplest the "tip of the iceberg". Most likely, in a percentage of instances, hair loss is unrecognized by sufferers and also the identification is formed once patients attend with another medical specialty condition (Figures 3 and 4) [3,22]. Given these observations, there could also be prodigious interest within the aetiologies of FFA and therefore the manner this may justify why we tend to be apparently seeing increasing numbers of instances.



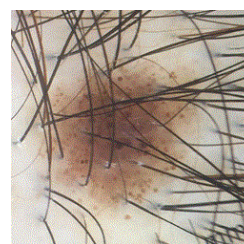**Figure 3:** Depression of the frontal veins.

On account that the primary case studies of FFA affecting siblings, [23-25] there had been an increasing quantity of studies of familial cases [26,27], suggesting a potential genetic predisposition and reviews are a foot to envision dead set establish genes which can be related to FFA. Nonetheless, genetic susceptibility on my own would no longer give an explanation for the apparent expand in FFA incidence.



**Figure 4:** Pili torti (twisting of hairs) can occur for a variety of reasons. In someone with itching, burning or pain in the scalp, one must consider the possibility of a scarring alopecia.

It has been planned that clusters of affected cases at intervals families could indicate not solely genetic susceptibleness however viable environmental triggers [26] Karnik et al. [28] released experimental proof that tested a possible position for peroxisome proliferator activated receptor-gamma (PPAR-gamma) in pathologic process of LPP. They established that PPAR-gamma, a transcription issue that belongs to the nuclear receptor tremendous-gene worshipped ones, is needed for preservation of cyst stem cells and valid that mice with PPAR-gamma deleted from cyst stem cells developed a scarring phalacrosis. In scalp biopsies from patients with LPP, it had been found that PPAR-gamma was down-regulated in hair follicles. The authors postulated a possible perform for xenobiotic metabolism as AN environmental set out for LPP, by means that of the aryl organic compound receptor (AhR). Environmental toxins resembling dioxin-like provides, prompt AhR that is known to suppress PPAR-gamma [28]. The position of PPAR-gamma and AhR in FFA stay to be elucidated (Figure 5) [26].



**Figure 5:** Dark colored moles on the scalp need to be carefully examined. Skin cancers, such as melanomas can occur. The regular appearance of this mole confirms it is not a cancer. The brown globules are uniform in size and color and somewhat symmetrically located throughout the lesion.

The possible position of environmental factors in FFA is supported through alternative observations. In our cohort of FFA sufferers, we have a tendency to determine a statistically massive organization (0.001) between FFA and wealth, as measured by the Carstairs Index, when put next with age and gender matched sufferers attending the hair clinic with alternative causes of phalacrosis, and with age and gender matched ladies within the basic population. This discovering was once supported via the statement that the identical cohort have been vastly much less more likely to be smokers (p=0.01), when compared with the final populace [3]. A review of 355 Spanish patients [9] showed 87% were non-smokers nevertheless, this used to be no

longer significantly one of a kind from the final population. While it appears unlikely that wealth in and of itself is primary within the pathological process of FFA, this might be a surrogate marker for associate degree as however unidentified likelihood component related to wealth. Curiously, during a cohort people sufferers with FFA, affected females are hugely further a lot of probably to possess earned the simplest attainable academic degree (US cooperative FFA study cluster, Elise Olsen chairman, unpublished information).

The development of FFA/LPP following hair transplant or cosmetic surgical procedure [29] extra helps the perform of environmental triggers within the pathologic process of FFA/LPP. One possible clarification that has been planned to provide a proof for this discovering implies that the immunological disorder surroundings that often surrounds hair follicles ("immune privilege") is disturbed by using inflammatory mediators motivated as a consequence of cutaneous surgical procedure, main to lack of follicle immune privilege and growing hair follicle susceptibility to inflammatory attack [29], additional reviews inspecting the position of environmental retailers in FFA are currently being undertaken.

As FFA used to be first represented solely moving biological time girls, it's been postulated that FFA is also due to hormonal alterations on the time of the menopause [9,19]. Nonetheless, no hormonal abnormalities had been recognized in FFA sufferers [2,19] and hormonal alterations by myself would no longer explain the obvious increasing incidence of the condition, nor the cases of FFA springing up in biological time girls and in guys. The statement of FFA poignant transplanted so hairs in an exceedingly man with FFA concomitant with virgin birth phalacrois [30], suggests that follicle sex hormone condition won't be needed for pathologic process of FFA. However, the possible position of hormones within the pathologic process of FFA has been supported via the observations that 5-alpha-reductase inhibitors (5ARIs) will stabilize [9,19,21] and strengthen FFA9 [31,32]. Hair regrowth in an exceedingly scarring phalacrois within which destruction of hair follicles could be a cardinal histopathological characteristic [2,7] is a perplexing phenomenon. Nonetheless, individual expertise and documented instances have established improvement in brow progress in some FFA patients handled with topical calcineurin inhibitors [33]. During a similar fashion, regrowth of hair in apparently scarred areas of scalp in chronic circular autoimmune disease (CDLE) and different scarring alopecias is sometimes found [34,35]. There were a number of sporadic case studies of development in FFA with 5ARIs, which have incorporated photographic graphics [31,32], the biggest released overview of FFA instances urged that of 111 patients handled with 5ARIs, 47% stabilized and fifty three% extended [9]. additional clarification of these results nonetheless, indicated that scientific growth at the hairline was once minimal and response to antiandrogens used to be more everyday if concomitant androgenetic alopecia used to be present, although not completely so [36] stabilization of FFA with treatment is usually recommended, it's predominant to be conscious that spontaneous stabilization of FFA will can arise.[4] Given the most likely sluggish progress of FFA, extended periods of commentary could be required to verify real stabilization. Certainly, randomized managed trials, utilising purpose measurements of sickness, are required to examine the role of remedies for FFA.

## Conclusion

In abstract, the incidence of FFA, initial represented solely 20 years within the past, seems to be growing. Clinically and histologically, it

seems to be a variant of LPP. The identification of familial circumstances suggests a genetic susceptibleness however additionally raises the chance of environmental triggers. Irregular controlled trials are needed to verify the outcomes of therapies and epidemiological experiences must be regarded to affirm the incidence and prevalence of FFA inside the populace.

## References

- Kossard S (1994) Postmenopausal frontal fibrosing alopecia. Scarring alopecia in a pattern distribution. *Arch Dermatol* 130: 770-774.
- Kossard S, Lee MS, Wilkinson B (1997) Postmenopausal frontal fibrosing alopecia: a frontal variant of lichen planopilaris. *J Am Acad Dermatol* 36: 59-66.
- MacDonald A, Clark C, Holmes S (2012) Frontal fibrosing alopecia: A review of 60 cases. *J Am Acad Dermatol* 67: 955-961.
- Tan KT, Messenger AG (2009) Frontal fibrosing alopecia: Clinical presentations and prognosis. *Br J Dermatol* 160: 75-79.
- Abbas O, Chedraoui A, Ghosn S (2007) Frontal fibrosing alopecia presenting with components of Piccardi-Lassueur-Graham-Little syndrome. *J Am Acad Dermatol* 57(Suppl 2): S15-18.
- Donati A, Molina L, Doche I, Valente NS, Romiti R (2011) Facial papules in frontal fibrosing alopecia: Evidence of vellus follicle involvement. *Arch Dermatol* 147: 1424-1427.
- Chew AL, Bashir SJ, Wain EM, Fenton DA, Stefanato CM (2010) Expanding the spectrum of frontal fibrosing alopecia: A unifying concept. *J Am Acad Dermatol* 63: 653-660.
- Miteva M, Camacho I, Romanelli P, Tosti A (2010) Acute hair loss on the limbs in frontal fibrosing alopecia: A clinicopathological study of two cases. *Br J Dermatol* 163: 426-428.
- Vañó-Galván S, Molina-Ruiz AM, Serrano-Falcón C, Arias-Santiago S, Rodrigues-Barata AR, et al. (2014) Frontal fibrosing alopecia: A multicenter review of 355 patients. *J Am Acad Dermatol* 70: 670-678.
- Miteva M, Whiting D, Harries M, Bernardes A, Tosti A (2012) Frontal fibrosing alopecia in black patients. *Br J Dermatol* 167: 208-210.
- Dlova NC, Jordaan HF, Skenjane A, Khoza N, Tosti A (2013) Frontal fibrosing alopecia: A clinical review of 20 black patients from South Africa. *Br J Dermatol* 169: 939-941.
- Sato M, Saga K, Takahashi H (2008) Postmenopausal frontal fibrosing alopecia in a Japanese woman with Sjögren's syndrome. *J Dermatol* 35: 729-731.
- Inui S, Nakajima T, Shono F, Itami S (2008) Dermoscopic findings in frontal fibrosing alopecia: Report of four cases. *Int J Dermatol* 47: 796-799.
- Atanaskova Mesinkovska N, Brankov N, Piliang M, Kyei A, Bergfeld WF2 (2014) Association of lichen planopilaris with thyroid disease: A retrospective case-control study. *J Am Acad Dermatol* 70: 889-892.
- Banka N, Mubki T, Bunagan MJ, McElwee K, Shapiro J (2014) Frontal fibrosing alopecia: A retrospective clinical review of 62 patients with treatment outcome and long-term follow-up. *Int J Dermatol* 53: 1324-1330.
- Meinhard J, Stroux A, Lünemann L, Vogt A, Blume-Peytavi U (2014) Lichen planopilaris: Epidemiology and prevalence of subtypes - a retrospective analysis in 104 patients. *J Dtsch Dermatol Ges* 12: 229-235, 229-36.
- Mehregan DA, Van Hale HM, Muller SA (1992) Lichen planopilaris: Clinical and pathologic study of forty-five patients. *J Am Acad Dermatol* 27: 935-942.
- Cevasco NC, Bergfeld WF, Remzi BK (2007) A case-series of 29 patients with lichen planopilaris: The Cleveland Clinic Foundation experience on evaluation, diagnosis and treatment. *J Am Acad Dermatol* 57: 47-53.
- Tosti A, Piraccini BM, Iorizzo M, Misciali C (2005) Frontal fibrosing alopecia in postmenopausal women. *J Am Acad Dermatol* 52: 55-60.
- Samrao A, Chew AL, Price V (2010) Frontal fibrosing alopecia: A clinical review of 36 patients. *Br J Dermatol* 163: 1296-1300.

21. Ladizinski B, Bazakas A, Selim MA, Olsen EA (2013) Frontal fibrosing alopecia: A retrospective review of 19 patients seen at Duke University. *J Am Acad Dermatol* 68: 749-755.
22. Poblet E, Jiménez F, Pascual A, Piqué E (2006) Frontal fibrosing alopecia versus lichen planopilaris: A clinicopathological study. *Int J Dermatol* 45: 375-380.
23. Roche M, Walsh MY, Armstrong DKB (2008) Frontal fibrosing alopecia occurrence in male and female siblings. *J Am Acad Dermatol* 58(Suppl 2): AB81.
24. Junqueira Ribeiro Pereira AF, Vincenzi C, Tosti A (2010) Frontal fibrosing alopecia in two sisters. *Br J Dermatol* 162: 1154-1155.
25. Miteva M, Aber C, Torres F, Tosti A (2011) Frontal fibrosing alopecia occurring on scalp vitiligo: Report of four cases. *Br J Dermatol* 165: 445-447.
26. Dlova N, Goh CL, Tosti A (2013) Familial frontal fibrosing alopecia. *Br J Dermatol* 168: 220-222.
27. Tziotzios C, Fenton DA, Stefanato CM, McGrath JA (2015) Familial frontal fibrosing alopecia. *J Am Acad Dermatol* 73: e37.
28. Karnik P, Tekeste Z, McCormick TS, Gilliam AC, Price VH, et al. (2009) Hair follicle stem cell-specific PPAR gamma deletion causes scarring alopecia. *J Invest Dermatol* 129: 1243-1257.
29. Chiang YZ, Tosti A, Chaudhry IH, Lyne L, Farjo B, et al. (2012) Lichen planopilaris following hair transplantation and face-lift surgery. *Br J Dermatol* 166: 666-370.
30. Kossard S, Shiell RC (2005) Frontal fibrosing alopecia developing after hair transplantation for androgenetic alopecia. *Int J Dermatol* 44: 321-323.
31. Georgala S, Katoulis AC, Befon A, Danopoulou I, Georgala C (2009) Treatment of postmenopausal frontal fibrosing alopecia with oral dutasteride. *J Am Acad Dermatol* 61: 157-158.
32. Donovan JC (2015) Finasteride-mediated hair regrowth and reversal of atrophy in a patient with frontal fibrosing alopecia. *JAAD Case Rep* 1: 353-355.
33. Katoulis A, Georgala, Bozi E, Papadavid E, Kalogeromitros D, et al. (2009) Frontal fibrosing alopecia: treatment with oral dutasteride and topical pimecrolimus. *J Eur Acad Dermatol Venereol* 23: 580-582.
34. Hamilton T, Otberg N, Wu WY, Martinka M, Shapiro J (2009) Successful hair re-growth with multimodal treatment of early cicatricial alopecia in discoid lupus erythematosus. *Acta Derm Venereol* 89: 417-418.
35. Bianchi L, Paro Vidolin A, Piemonte P, Carboni I, Chimenti S (2001) Graham Little-Piccardi-Lassueur syndrome: Effective treatment with cyclosporin A. *Clin Exp Dermatol* 26: 518-520.
36. Vaño-Galván S, Arias-Santiago S, Camacho F (2014) Reply to 'frontal fibrosing alopecia'. *J Am Acad Dermatol* 71: 594-595.