
CASE REPORT

Inferior Ophthalmic Vein Varix Complicated by Acute Thrombosis

SF Low, YL Lee

Department of Radiology, Universiti Kebangsaan Malaysia Medical Centre, Kuala Lumpur, Malaysia

ABSTRACT

Orbital venous varix is an uncommon venous malformation of the orbit, divided into primary and secondary types. Orbital varix most commonly involves the superior ophthalmic vein and is rarely complicated by thrombosis. We report a case of inferior ophthalmic vein varix complicated by acute thrombosis, who presented with acute visual loss and proptosis. Lateral cantholysis was performed and high-dose steroid was given to relieve the patient's symptoms. The thrombus of the orbital varix gradually regressed in 1 month and completely resolved in 6 months.

Key Words: Diplopia; Orbit; Thrombosis; Valsalva maneuver; Varicose veins

中文摘要

急性血栓所致的眼下靜脈曲張

劉淑芬、李依玲

眼眶靜脈曲張是一種罕見的眼眶靜脈畸形，分為原發性和繼發性兩種。眼眶靜脈曲張一般累及眼上靜脈，很少併發血栓。本文報告一宗眼下靜脈曲張併發急性血栓的病例。患者以急性視力喪失伴眼球突出就診。為患者進行外側眦切開術，並給予高劑量類固醇以緩解症狀。眼眶靜脈曲張的血栓在一個月內逐步消退，直至六個月時內完全消失。

INTRODUCTION

Orbital venous varix (OVV) is an uncommon venous malformation of the orbit. It is divided into primary and secondary types.¹ Primary OVV is idiopathic and congenital in origin. It is attributed to congenital weakness of the venous wall leading to proliferation of the veins and massive dilatation of the valveless orbital vein. Secondary OVV refers to a dilated orbital vein due to trauma or increased blood flow that develops into an intraorbital or intracranial vascular malformation.¹ Classical symptoms manifest in second or third decades

of life, and affect both genders equally.² It is known that OVV most commonly arises in the superior ophthalmic vein (SOV); involvement of the inferior ophthalmic vein (IOV) is rare,² whilst acute thrombosis and haemorrhage are occasional complications.³⁻⁵ A unique case of inferior ophthalmic vein varix (IOVV) with acute thrombosis is presented herein.

CASE REPORT

A 50-year-old Chinese man with a background history of poorly controlled hypertension presented with

*Correspondence: Dr Soo-fin Low, Department of Radiology, Universiti Kebangsaan Malaysia Medical Centre, Jalan Yaacob Latif, Bandar Tun Razak, 56000 Cheras, Kuala Lumpur, Malaysia.
Tel: (603) 9145 6439; Fax: (603) 9145 6682; Email: soofinlow@gmail.com*

Submitted: 24 Sep 2012; Accepted: 19 Dec 2012.

sudden-onset right-sided severe headache for 3 days, associated with vomiting, right proptosis, and sudden deterioration of vision in right eye. He had experienced a right thalamic haemorrhage 9 months earlier from which he had recovered completely. Urgent plain computed tomography (CT) of the brain was ordered and excluded intracranial haemorrhage. However, there was a lobulated hyperdense lesion in the right retro-orbital region at the inferior aspect of the orbit, mainly involving the intraconal space. It measured 2.0 x 1.3 cm. The lesion appeared to be in continuity with a tortuous and dilated dense vessel (Figure 1). This finding raised the suspicion of a vascular lesion.

After admission to the ophthalmology ward, further questioning revealed that he experienced intermittent proptosis of his right eye for 3 months, induced by straining, but which resolved spontaneously. The right eye examination revealed an injected conjunctiva with chemosis and mild proptosis. Vision in the right eye was markedly reduced, which was limited to recognition of hand motion only. When the swinging light test was performed for consensual response of the pupils when moving the light source from right eye to left eye, a normal pupillary reflex with constriction was noted. However, paradoxical dilation of the right pupil was noted when the light source moved from left eye to right eye. The response showed a reduced afferent impulses received by the right eye, suggesting relative afferent pupillary defect of the right eye. Such finding suggested a pre-chiasmal lesion. Double vision and limited extra-ocular muscle (EOM) movement were also present. During his admission, his intra-orbital pressure was normal (16 mm Hg). Exophthalmometry confirmed the presence of right eye proptosis. In view of the acute threat to vision, on the day of admission, emergency orbital decompression was performed via a lateral cantholysis. Incising and disinserting the lateral canthal tendon to reduce the intra-orbital pressure was a simple procedure. Direct surgery on the retro-orbital lesion was not undertaken. Following the procedure, the patient was treated with anti-glaucoma eye drops (timolol maleate 0.5%, brinzolamide 1%, latanoprost 0.005%) and intravenous methylprednisolone.

Magnetic resonance imaging (MRI) of the orbit and brain was performed the day after cantholysis. The right retro-orbital lesion was isointense on T1-weighted and mixed hypointense to hyperintense on T2-weighted images. On post-gadolinium study, the lesion was enhancing, with multiple round and tubular

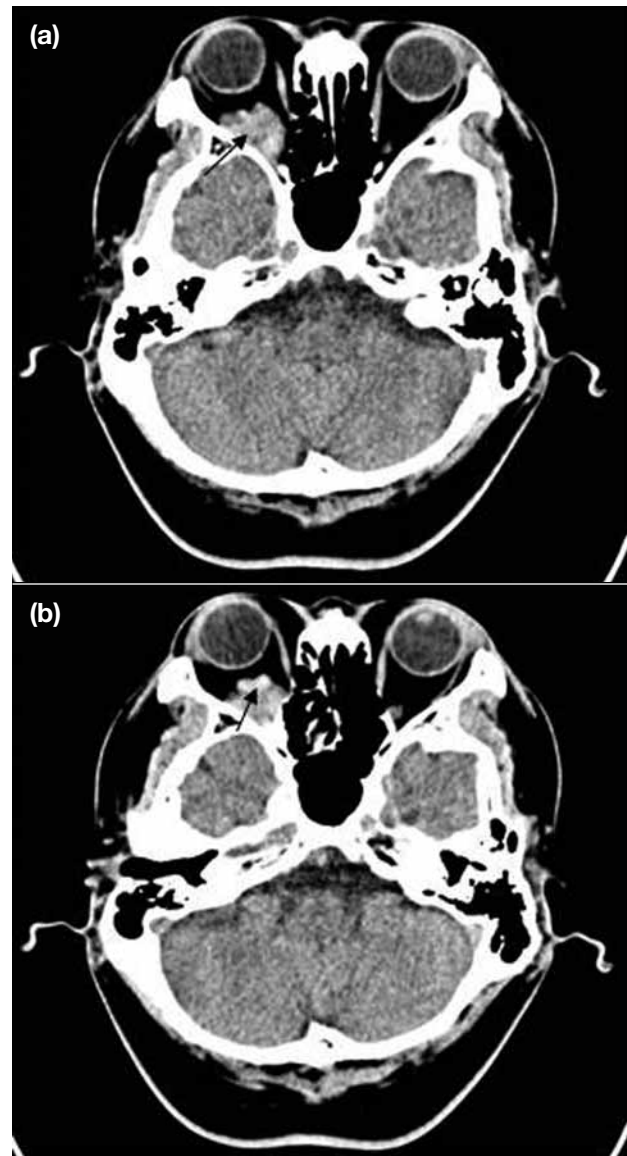


Figure 1. (a) Axial plain computed tomography of the brain shows a hyperdense right retro-orbital lesion with well-defined lobulated margin (arrow) and mild right eye proptosis. (b) A dense and tortuous tubular structure (arrow) is seen at the inferior aspect of the lesion suspicious of a vascular lesion.

filling defects within (Figure 2). The lesion exhibited a mass effect and displaced the optic nerve superiorly. There was no intracranial or intraorbital arteriovenous malformation. The right ophthalmic artery, SOV and cavernous sinus appeared normal. The MRI findings of the right retro-orbital lesion suggested IOVV with acute thrombosis; ultrasound of the orbit with Valsalva manoeuvre was performed but not conclusive of such a diagnosis. It only showed a non-specific right retro-orbital mass.

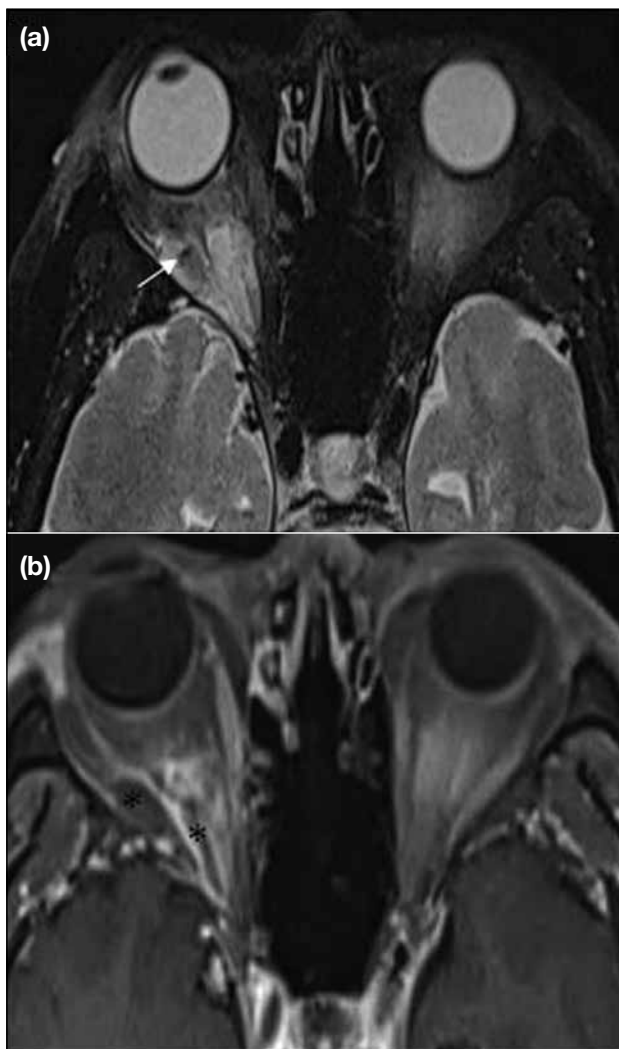


Figure 2. (a) Magnetic resonance imaging T2-weighted fat-suppressed image shows hyperintense right retro-orbital lesion with hypointense signal within (arrow). No serpiginous signal void within the lesion suggests arteriovenous malformation. (b) Post-gadolinium T1-weighted fat-suppressed image shows enhancement of the lesion with tubular filling defects (asterisk) within, consistent with thrombosis of the orbital varix.

CT of the orbit with and without Valsalva manoeuvre was performed 4 days later. At this point of time, the patient had about 30 to 40% improvement of his vision. As venous thrombus might mask the distensibility of the orbital varix, the patient was placed in a prone position during the scan. The CT scan was performed in two phases, namely plain CT at rest, and contrast-enhanced CT with Valsalva manoeuvre. At rest, the lesion was smaller in size than the image during admission, consistent with treatment response. On contrast-enhanced CT with Valsalva manoeuvre, the lesion

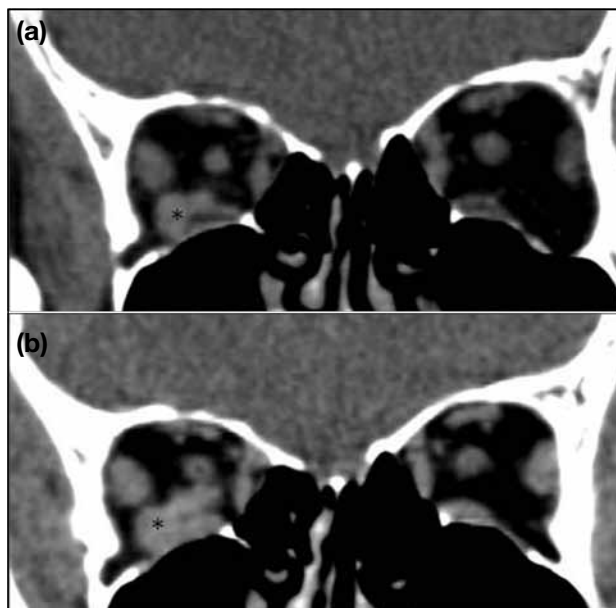


Figure 3. (a) Coronal-reformatted computed tomography of the orbit. Plain study at rest demonstrates the right retro-orbital lesion (asterisk) which is smaller in size 4 days following emergency lateral cantholysis of the right eye. (b) Contrast-enhanced study with Valsalva manoeuvre shows enlargement of the lesion (asterisk) with minimal enhancement.

became larger with mild homogeneous enhancement (Figure 3). The IOV was dense, distended and non-enhancing, consistent with presence of thrombus within. The diagnosis of right IOVV with acute thrombosis therefore became credible if not convincing.

The patient was well during follow-up, and the right proptosis gradually resolved. His right eye vision improved markedly, though he still experienced intermittent mild diplopia. Follow-up CT orbit after 1 month showed the thrombus was significantly smaller.

DISCUSSION

OVV typically presents with intermittent proptosis, is induced by changes in cephalic venous pressure, and thus, is also known as stress proptosis. Coughing, bending over, and Valsalva manoeuvre potentially cause reversible expansion of an OVV.¹ OVVs most commonly involve the SOV and sudden thrombosis is an uncommon finding. A thrombosed OVV compresses the optic nerve and EOMs, causing visual impairment and diplopia, as in the present case. Venous stasis in the OVV predisposes to thrombus formation. There were only two reported cases of IOVV with acute thrombosis.^{5,6} In the present case, a middle-aged patient

with an atypically located OVV and acute thrombosis lead to a diagnostic dilemma.

An OVV with and without thrombosis has different imaging features. Without thrombosis it exhibits classic imaging findings, with distensibility readily demonstrable on CT, MRI, and colour Doppler imaging (CDI) during Valsalva manoeuvre or internal jugular vein compression.^{5,7} A thrombosed OVV shows variable enhancement and distensibility, and can be completely non-enhancing and non-distensible in the acute phase due to lack of recanalisation of the thrombosed vein; later on, enhancement and distensibility depends on the degree of recanalisation. As a tool to assess OVVs, increasingly CDI is being used, as it is non-invasive and radiation-free. Ozden and Erkan⁸ recommended that CDI could be used as the initial screening test in cases of suspected orbital varix. However, a thrombosed OVV appears as a non-specific hypoechoic retro-orbital mass. In addition, using ultrasound it is easy to demonstrate the SOV but difficult to assess the IOV.⁹

On MRI, OVVs are hypointense to hyperintense on T1-weighted and hyperintense on T2-weighted images. Usually they enhance intensely after contrast administration, but are hypointense in both T1-weighted and T2-weighted sequences after acute thrombosis. OVVs are associated with non-contiguous intracranial vascular malformations in approximately 10% of cases and therefore patients should be investigated appropriately.¹⁰

To assess the distensibility of an OVV, the Valsalva manoeuvre is easy to perform during CT due to the short scanning time. An OVV may show hyperdensity on plain CT but filling defects or lack of enhancement in the context of thrombosis. Calcified phleboliths are pathognomonic if present.¹¹ CT is also valuable to detect bone anomalies (orbital wall defect or thinning) related to OVVs.

Treatment of orbital varices should be as conservative as possible.^{6,7} Surgery is reserved for patients with frequent thrombotic episodes, intractable pain, severe proptosis, and compressive optic neuropathy.^{4,6} Thrombosis of the orbital varix poses the danger of blindness, warranting an orbital decompression via a subciliary approach.¹² In most cases, symptoms resolve spontaneously due to recanalisation or resorption of thrombosis.^{5,6} Other treatment options include embolisation such as sclerotherapy. Laser therapy can also be used, especially

when surgery is contraindicated.¹³

The differential diagnosis of a retro-orbital mass in a middle-aged subject includes metastasis, lymphoma, orbital pseudotumour, cavernous haemangioma and arteriovenous malformation, of which the latter two conditions resemble thrombosed OVVs most closely. Arteriovenous malformations of the orbit are rare and usually fed by ophthalmic artery branches, and imaging typically shows a feeding artery, nidus and enlarged draining vein, which was not seen in our patient. Although an orbital arteriovenous malformation can present with proptosis and visual loss, the classical presentations entail periorbital swelling, dilated retinal veins and epibulbar vessels, none of which were present in our patient.¹⁴

Cavernous haemangioma is the most common vascular lesion in adulthood. It is slow growing and results in progressive proptosis rather than acute or intermittent events as with OVVs. Cavernous haemangioma is an intracranial lesion and most often located lateral to the optic nerve. On CT, it is typically well-circumscribed, round or ovoid, homogeneously hypodense on plain study and gradually filling up of contrast in contrast study.¹⁵

Orbital pseudotumour was less likely in our patient due to clear retro-orbital fat and the clinical presentation with painless proptosis. With orbital lymphomas and orbital metastasis, homogeneous or variable enhancement of the lesion is expected. However, the lesion should not result in dilatation of the IOV. If the lesion occupies the orbital apex, it can lead to orbital venous congestion, but the SOV (the major vein draining the orbit) rather than the IOV will be congested.

In conclusion, IOVV complicated with acute thrombosis is a rare condition. It mimics an orbital mass leading to a diagnostic challenge, especially in middle age. CT, MRI, and CDI may not show characteristic findings due to thrombus within the varix, but play an important role in the diagnosis and follow-up of thrombosed vessels, albeit with limitations. Imaging is also essential to exclude secondary causes of OVV. Treatment should be directed at treating the identifiable cause of secondary OVV. For primary thrombosed OVV, treatment should be conservative due to the tendency for recanalisation and reabsorption of the thrombus. Surgical treatment for removal of IOVV and thrombosis is a high-risk procedure. A high index of suspicion is required to

make the diagnosis and avoid unnecessary surgery.

ACKNOWLEDGEMENT

Appreciation to our department's Research Officer, Ms Farizwana Ridzwan for her help and skills in formatting and editing the report.

REFERENCES

1. Lloyd GA, Wright JE, Morgan G. Venous malformations in the orbit. *Br J Ophthalmol*. 1971;55:505-16. [cross ref](#)
2. Rubin PA, Remulla HD. Orbital venous anomalies demonstrated by spiral computed tomography. *Ophthalmology*. 1997;104:1463-70. [cross ref](#)
3. Lieb WE, Merton DA, Shields JA, Cohen SM, Mitchell DD, Goldberg BB. Colour Doppler imaging in the demonstration of an orbital varix. *Br J Ophthalmol*. 1990;74:305-8. [cross ref](#)
4. Rivas JJ, Lobato RD, Cordobés F, Barcena A, Millán JM. Intermittent exophthalmos studied with computerized tomography. Report of two cases. *J Neurosurg*. 1982;57:290-4. [cross ref](#)
5. Yalaz M, Hacıyakupoğlu G, Aksungur E, Isigüzel I. Inferior ophthalmic vein varix and thrombosis. *Orbit*. 1996;15:81-4. [cross ref](#)
6. Bullock JD, Goldberg SH, Connelly PJ. Orbital varix thrombosis. *Ophthalmology*. 1990;97:251-6. [cross ref](#)
7. Winter J, Centeno RS, Bentson JR. Maneuver to aid diagnosis of orbital varix by computed tomography. *AJNR Am J Neuroradiol*. 1982;3:39-40.
8. Ozden SU, Ercan K. Orbital varix: CT and MRI findings. *Eur J Radiol Extra*. 2010;75:e51-3. [cross ref](#)
9. Berges O. Colour Doppler flow imaging of the orbital veins. *Acta Ophthalmol Suppl*. 1992;204:55-8.
10. Katz SE, Rootman J, Vangveeravong S, Graeb D. Combined venous lymphatic malformations of the orbit (so-called lymphangiomas). Association with noncontiguous intracranial vascular anomalies. *Ophthalmology*. 1998;105:176-84. [cross ref](#)
11. Aviv RI, Miskiel K. Orbital imaging: part 2. Intraorbital pathology. *Clin Radiol*. 2005;60:288-307. [cross ref](#)
12. Gómez Oliveira G, Lorenzo Franco F, Rodríguez G, López Cedrún JL, Martínez A. Acute thrombosis of an orbital varix. A case report. *Rev Esp Cirug Oral y Maxilofac*. 2007;29:405-9.
13. Bagazgoitia L, Boixeda P, Lopez-Caballero C, Beà S, Santiago JL, Jaén P. Venous malformation of the eyelid treated with pulsed-dye-1064-nm neodymium yttrium aluminum garnet sequential laser: an effective and safe treatment. *Ophthal Plast Reconstr Surg*. 2008;24:488-90. [cross ref](#)
14. Vu BL, Harris GJ. Orbital vascular lesions. *Ophthalmol Clin North Am*. 2000;13:609-31. [cross ref](#)
15. Ansari SA, Mafee MF. Orbital cavernous hemangioma: role of imaging. *Neuroimaging Clin N Am*. 2005;15:137-58. [cross ref](#)