

PHARYNGO-TYMPANIC TUBE

[Eustachian Tube/Auditory Tube]

Presented by :- Dr. Sushma Tomar
Associate Professor
Department of Anatomy

28-5-2020

Introduction

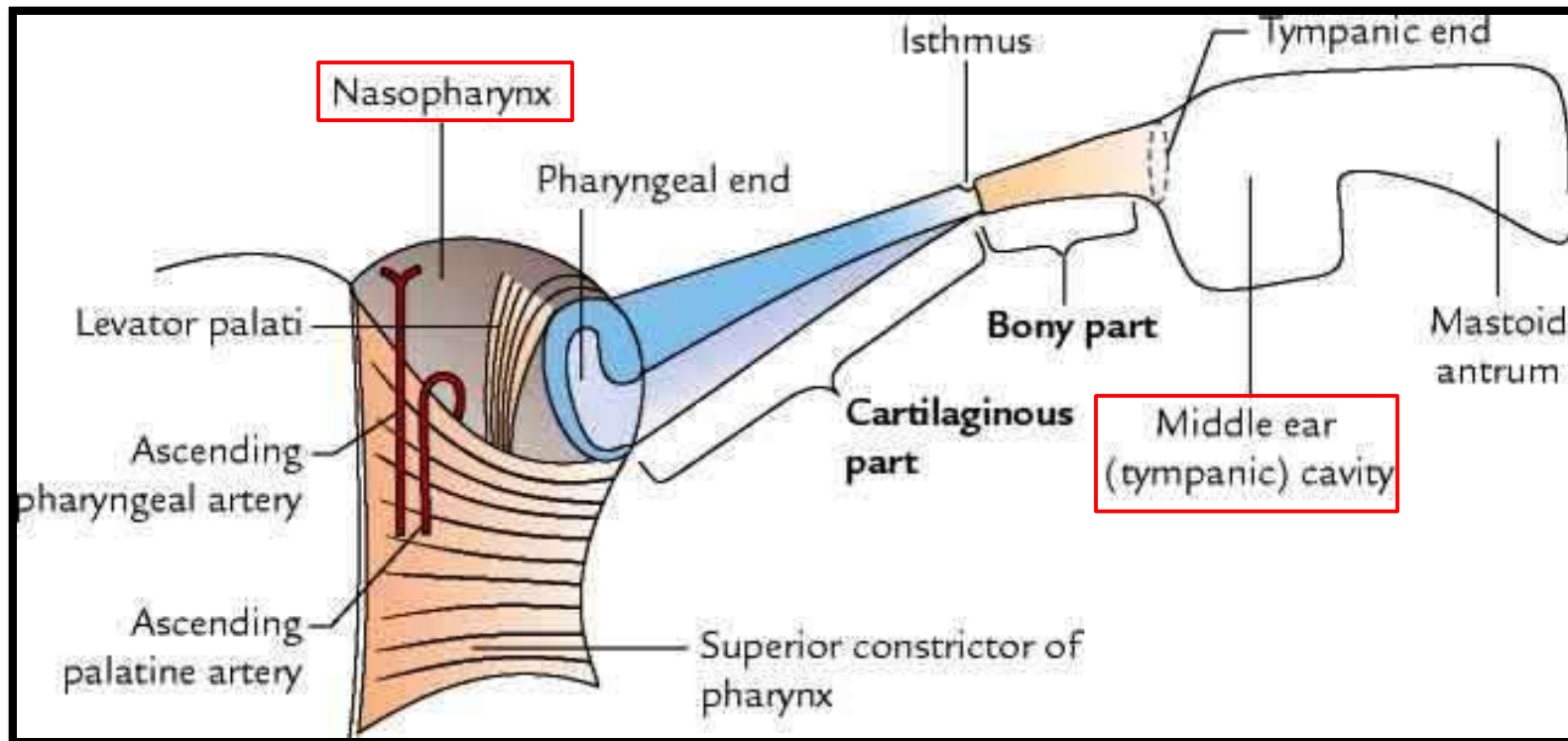
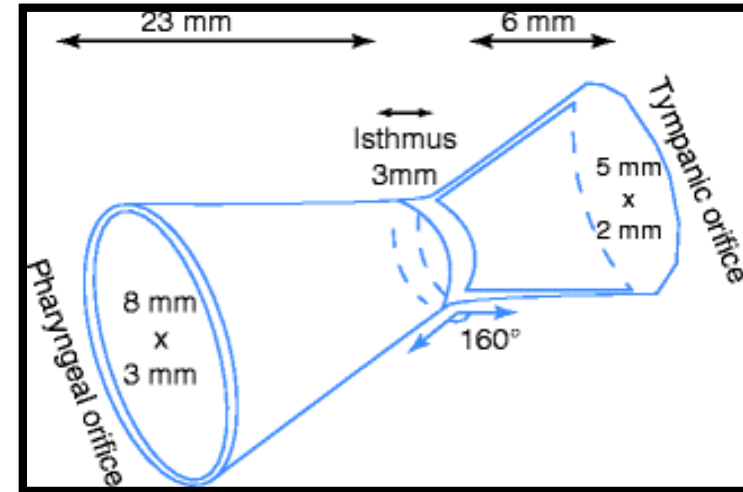
- An **osseo-cartilaginous** tube.
- Connects the nasopharynx with the tympanic cavity.
- Maintains the equilibrium of air pressure on either side of tympanic membrane.

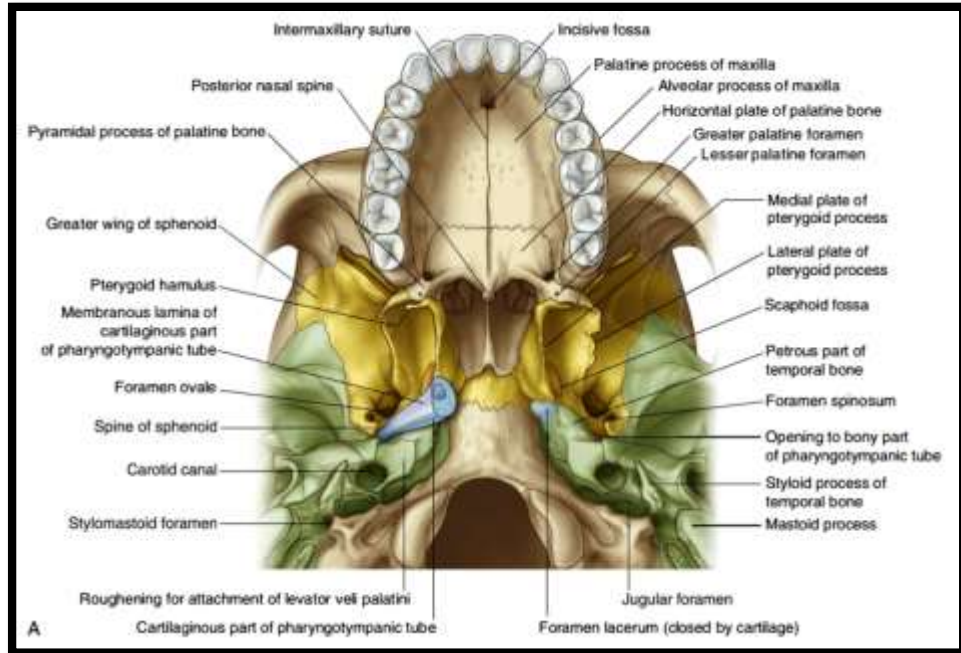
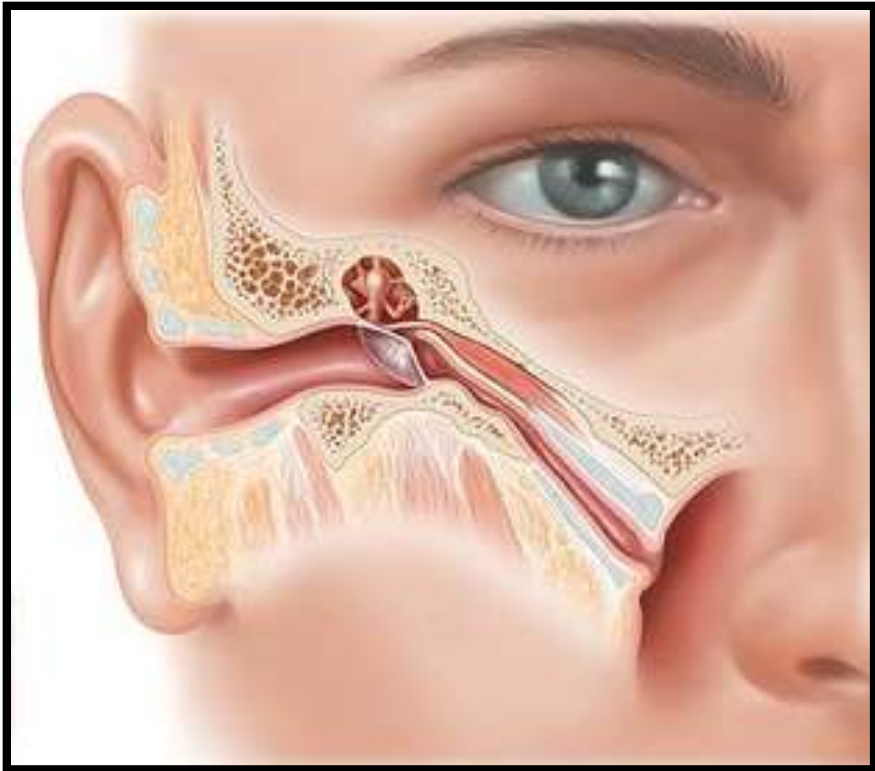
Length-

- ~36 mm

Direction (from tympanic end)-

- **Downwards, Forwards** and **Medially**.





Parts

❖ 2 parts:

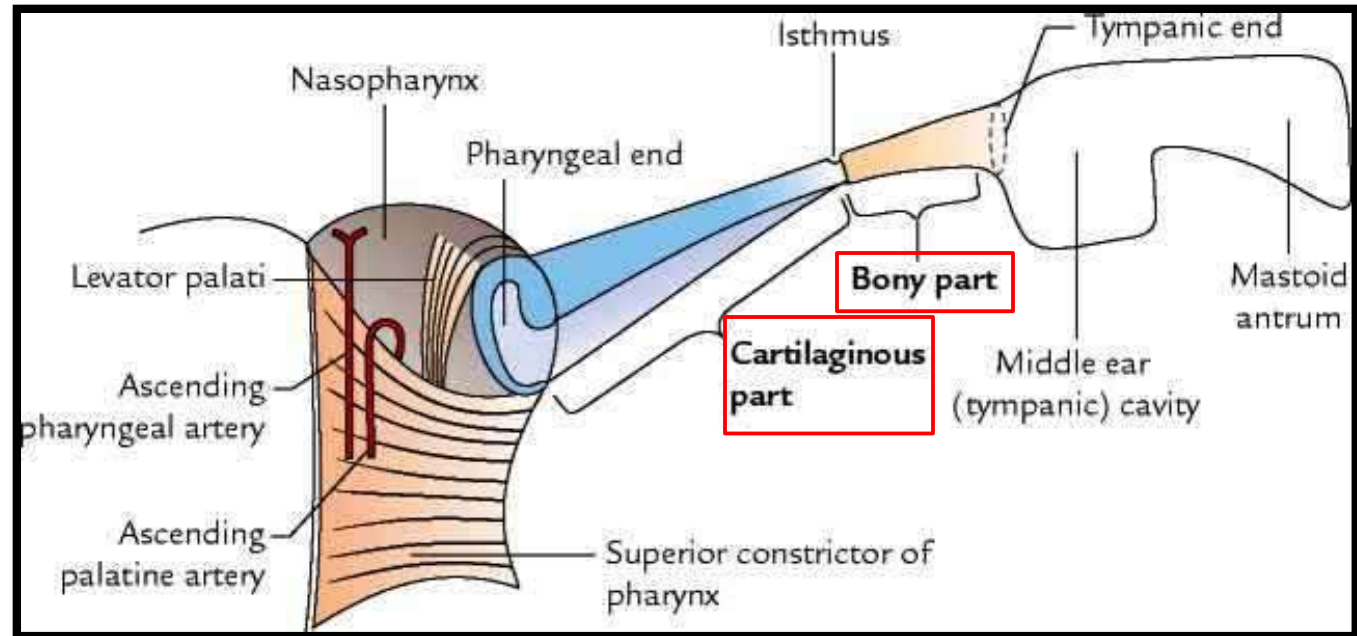
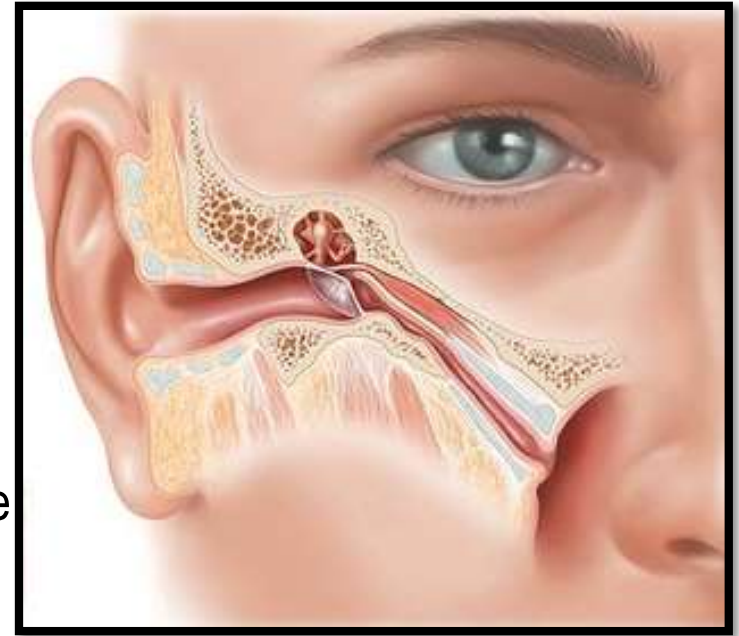- *Bony (Osseous) part.*
- *Cartilaginous part.*

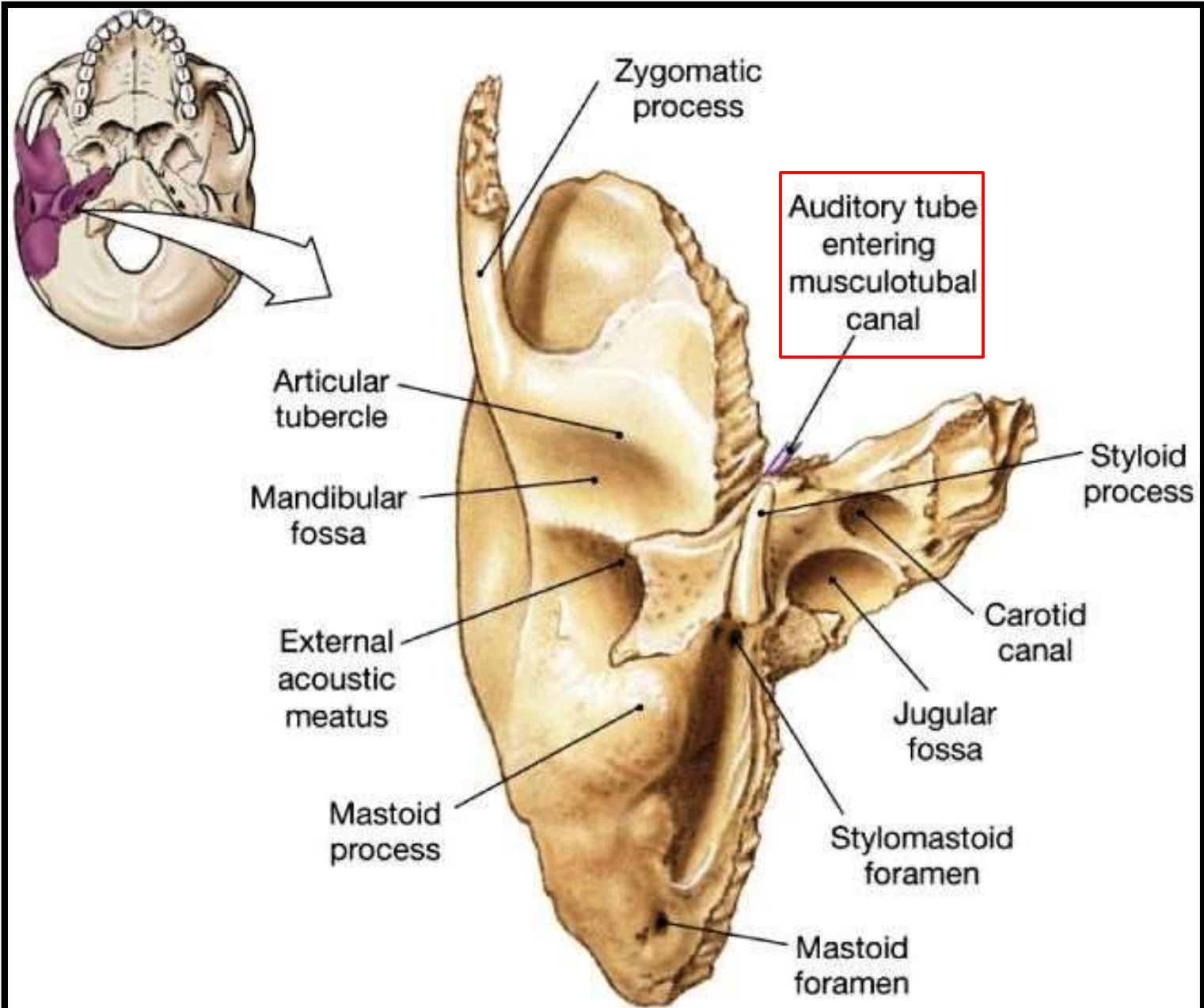
Bony (Osseous) part-

- **Posterolateral** part.

Length- ~12mm (1/3rd of total length).

- Lies between tympanic and petrous part of temporal bone
- Opens into anterior wall of middle ear cavity (tympanic cavity)
- **Tympanic end** is small.





(c) Right temporal bone, inferior view

Prominence of lateral semicircular canal

Prominence of facial canal

Tegmen tympani

Left ear: TM removed

Promontory

Roof

Tensor tympani muscle

Aditus to mastoid antrum

Ant wall

Pharyngotympanic tube

Oval window

Post wall

Medial wall

Pyramidal eminence

Lesser petrosal nerve

Branch from internal carotid plexus

Chorda tympani nerve

Sympathetic plexus

Internal carotid artery

Floor

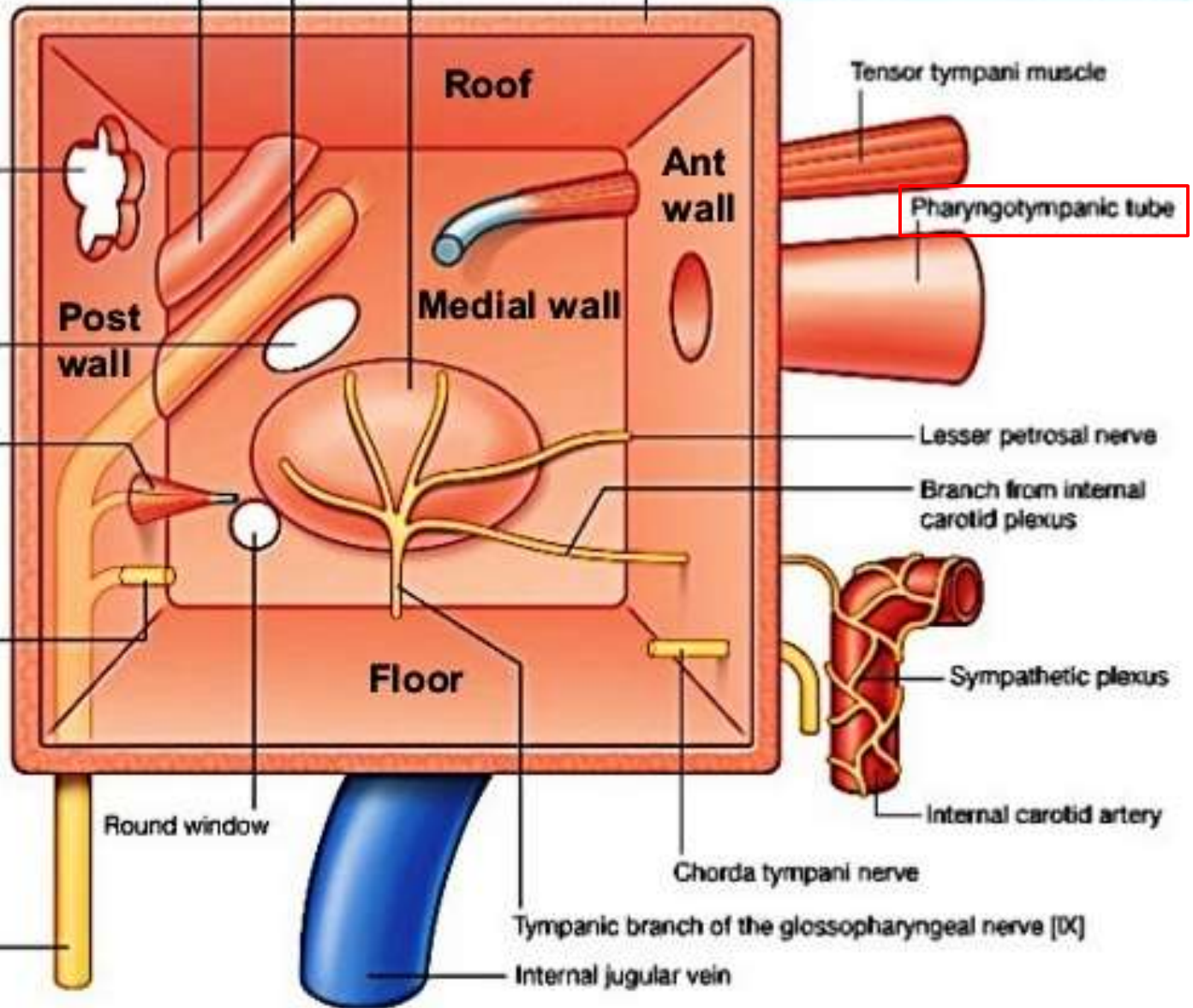
Round window

Chorda tympani nerve

Tympanic branch of the glossopharyngeal nerve [IX]

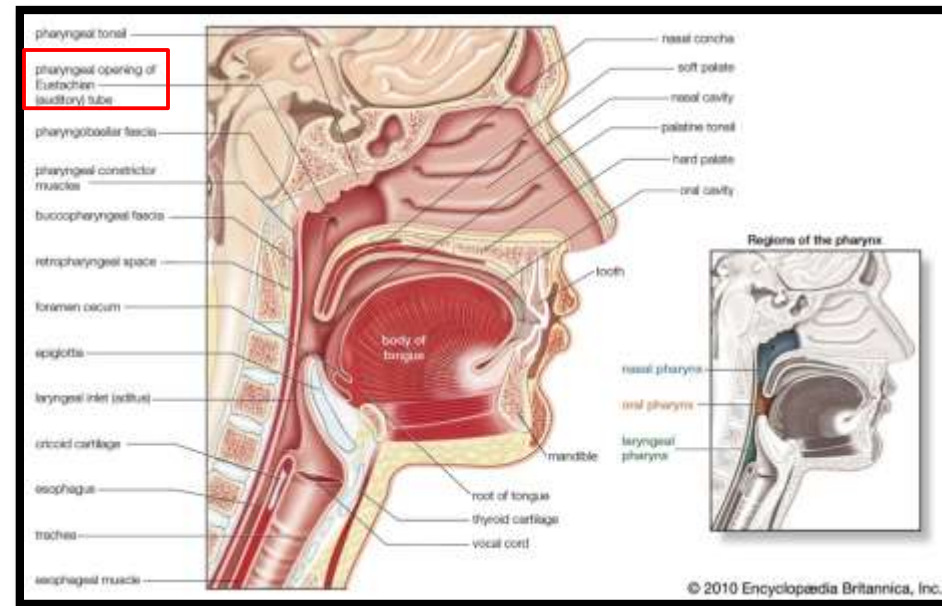
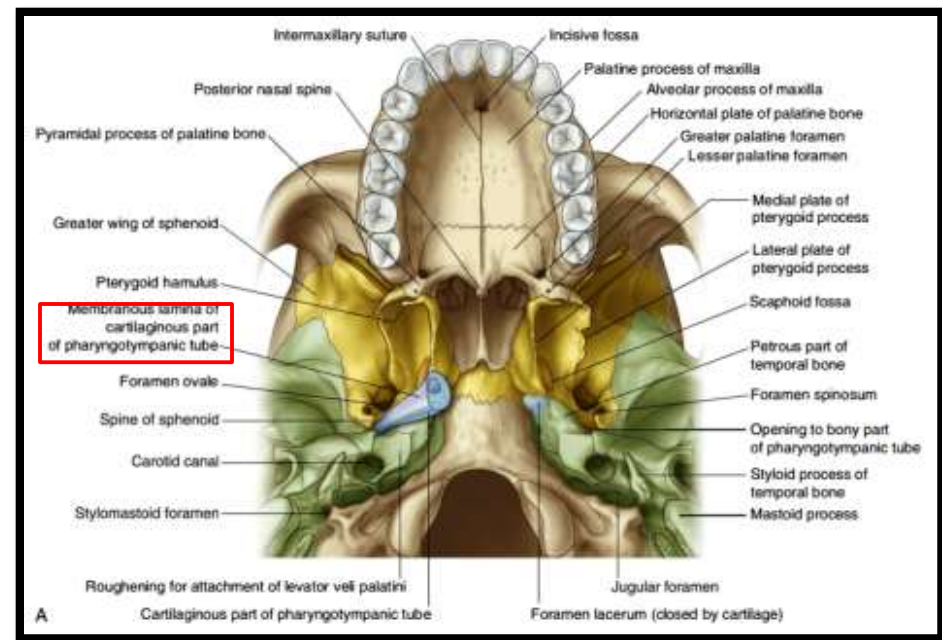
Facial nerve [VII]

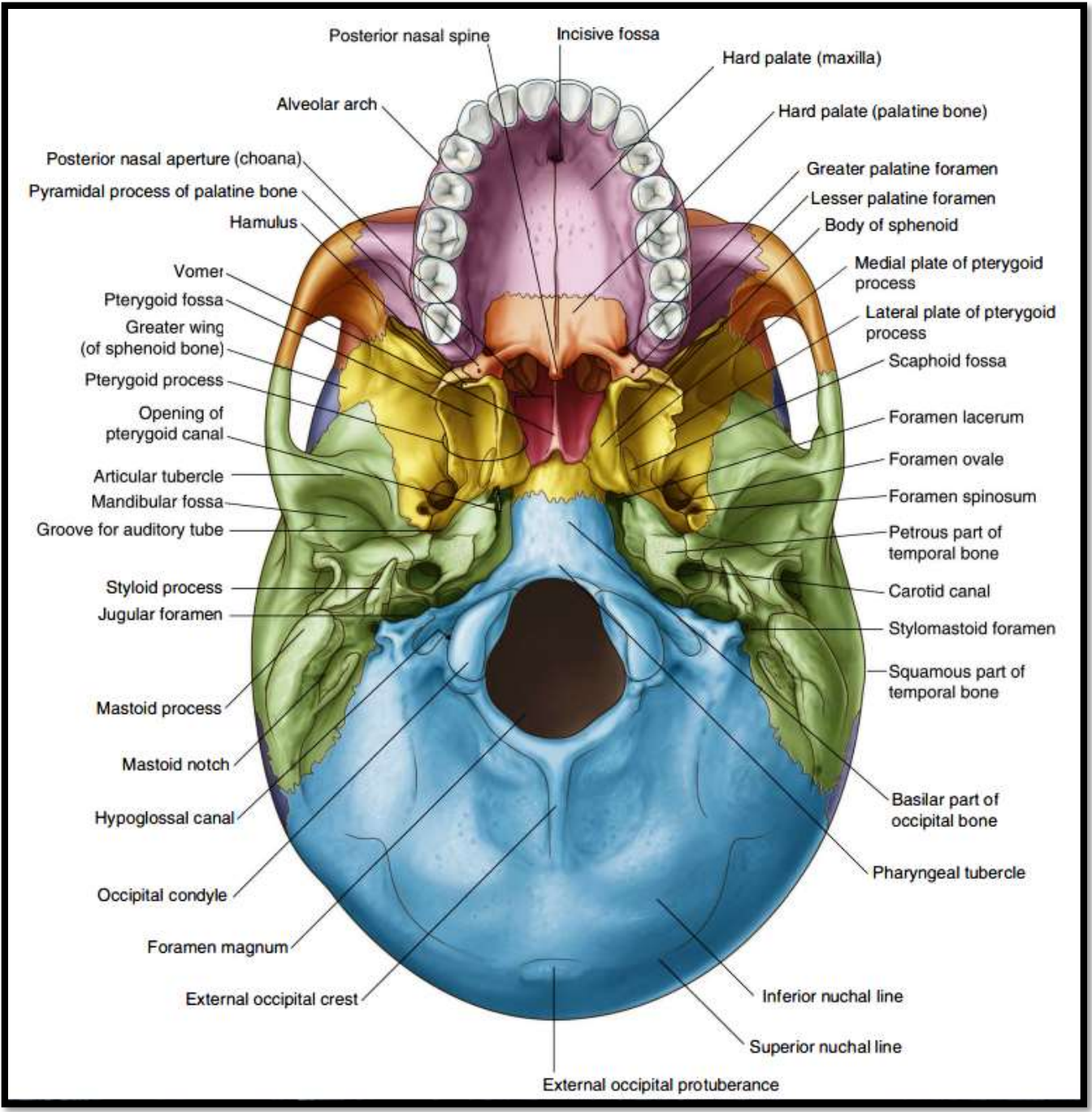
Internal jugular vein



Cartilaginous Part

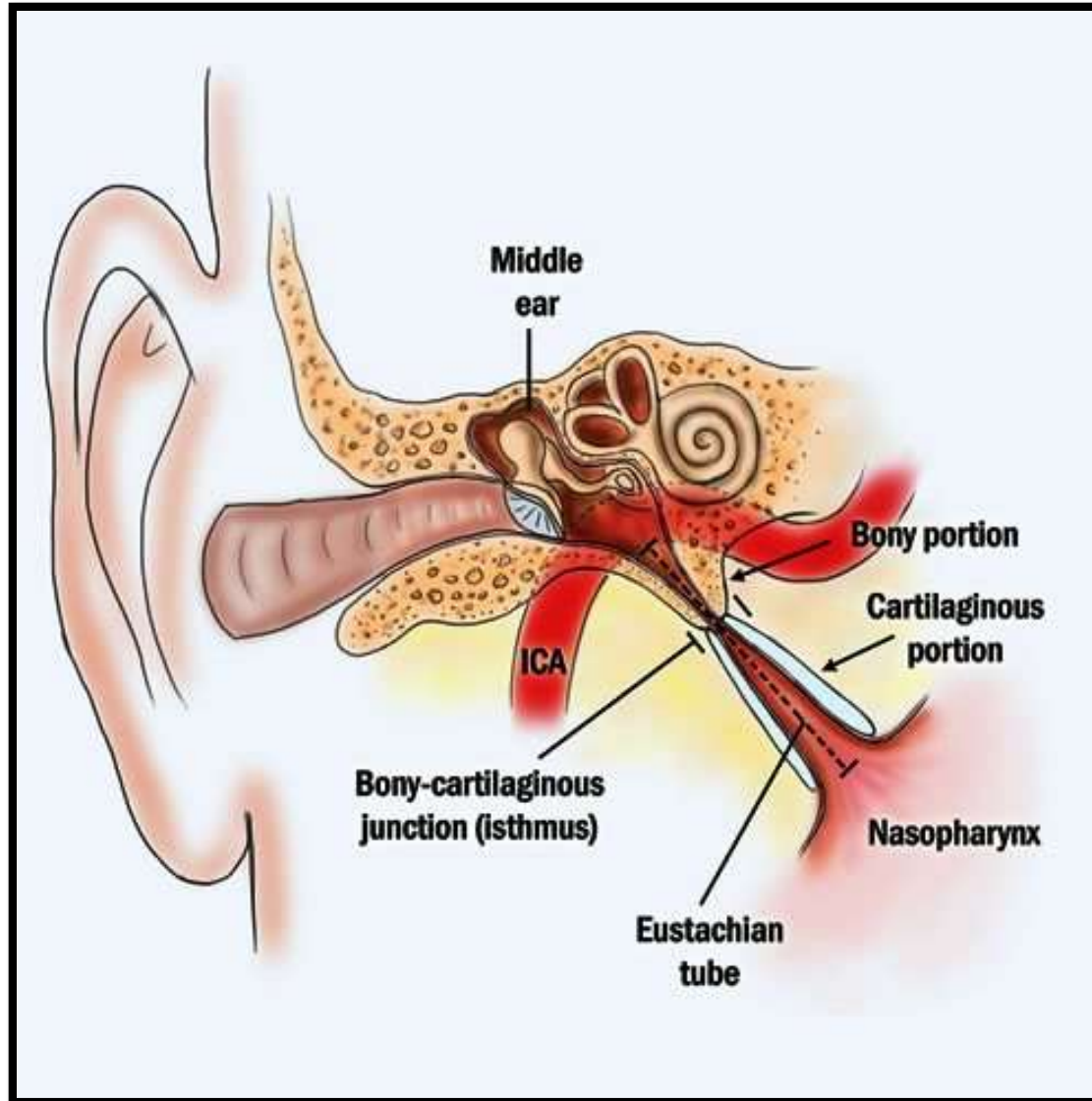
- **Anteromedial** part.
- Length- **~24mm** (2/3rd of total length).
- Lies between petrous part of temporal bone and posterior border of greater wing of sphenoid bone.
- Opens into lateral wall of nasopharynx.
- **Pharyngeal end** is in the form of a vertical slit, and it is the **widest part** of the tube.
- Medial wall, roof and upper part of lateral wall of cartilaginous part is formed by elastic cartilage.
- Rest of the lateral wall is formed by fibrous membrane.





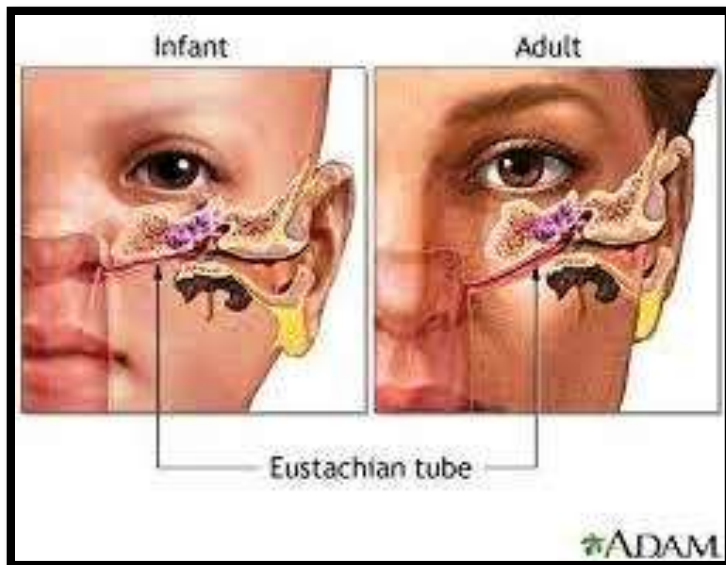
Parts contd...

- Both parts meet at isthmus (narrowest part).



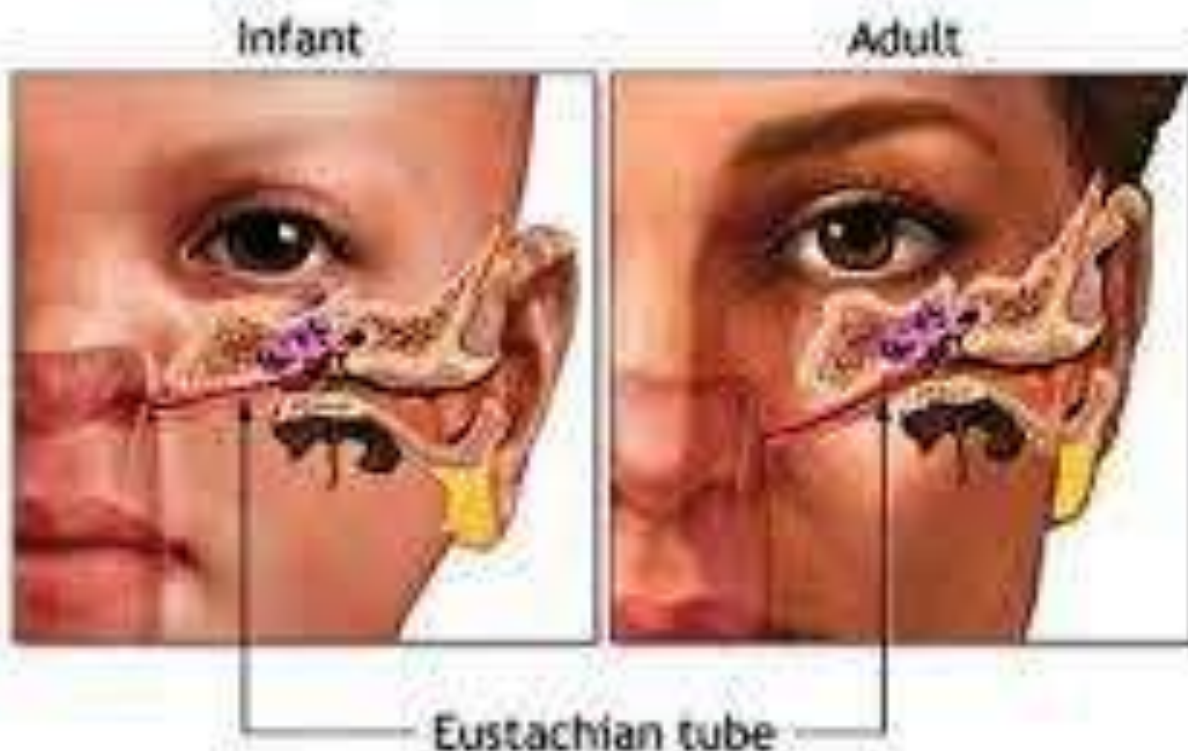Differences between the Eustachian Tube of an Infant and an Adult

Parameter	Infant	Adult
Length	18 mm	36 mm
Direction	More or less horizontal (makes an angle of 10° with horizontal plane)	Oblique, directed downwards, forwards and medially from tympanic end (makes an angle of 45° with horizontal plane)
Angulation of Isthmus	No angulation	Angulation present



Applied Aspects

❖ Middle ear infections are more common in infants and young children than in adults, since the eustachian tube is shorter, wider and more horizontal and infections from nasopharynx can easily reach the middle ear.



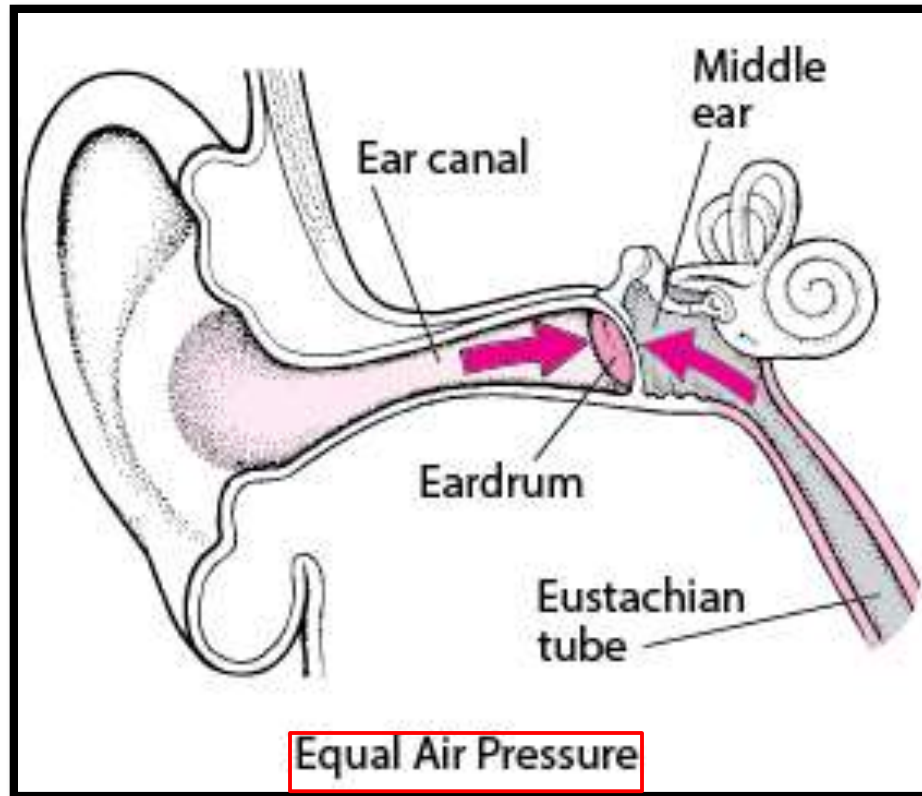
ADAM

Figure.1: Comparison of Eustachian tubes of adult and child. The Eustachian tube of the human child is shorter, narrower, and more horizontal than that of the adult human.

Neil K. Kaneshiro, MD, MHA, Clinical Assistant Professor of Paediatrics, University of Washington School of Medicine. Last reviewed on 5/16/2012.

Functions of Eustachian Tube

- At rest, Eustachian tube remains closed.
- Eustachian tube is reflexly opened during swallowing, yawning and sneezing.
- It maintains equilibrium of air pressure on either side of tympanic membrane.
- It protects the middle ear by preventing the transmission of high air pressure from nasopharynx to middle ear.
- Movement of cilia present in epithelium of tube, clears the secretions from middle ear.



Applied Aspects

Blockage of Eustachian Tube- (blockage may be due to inflammation of tubal tonsil)

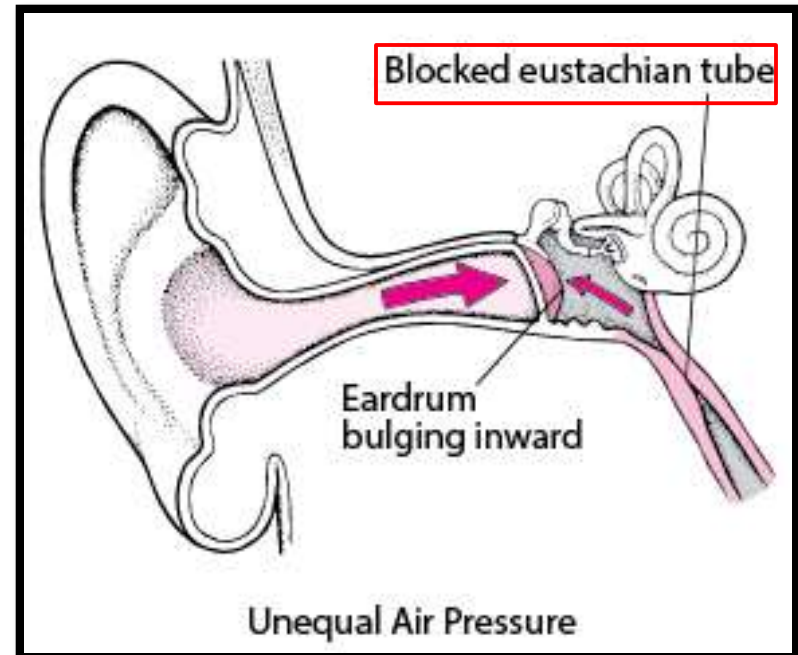
- Residual air in middle ear is absorbed into the blood vessels of its mucous membrane.
- Air pressure falls in tympanic cavity.
- Tympanic membrane retracts (bulges towards middle ear cavity).

Clinical Features-

- Hearing disturbance.
- Severe headache.

Treatment-

Periodic introduction of air within the middle ear by Eustachian catheter.



THANK YOU

