

---

---

# PHOTOREFRACTIVE KERATECTOMY IN REFRACTIVE ACCOMMODATIVE ESOTROPIA

KAMIL BILGIHAN, FIKRET AKATA, MERAL OR and BERATI HASANREISOĞLU  
*Ankara, Turkey*

## SUMMARY

Photorefractive keratectomy (PRK) was performed on a 19-year-old man with hyperopic astigmatism and refractive accommodative esotropia. The patient was orthophoric while wearing spectacles, but had an esotropia of 30 prism dioptres at near and distance vision without spectacles. The best corrected visual acuity of the right eye was 20/50 and of the left eye was 20/20. The excessive accommodative convergence of the patient was eliminated by correcting the hyperopic refractive error by performing PRK, and the patient became orthophoric after the treatment.

An uncorrected hyperopia forces the patient to exert excessive accommodation to clear the retinal image, thus evoking excessive convergence. If the motor fusion of the patient is inadequate the esodeviation becomes manifest. Full correction of the hyperopic refractive error, determined by cycloplegic refraction, is required for the treatment of refractive accommodative esotropia.<sup>1</sup>

Photorefractive keratectomy (PRK) is a new technique for reshaping the anterior corneal surface, and the principle of the hyperopic correction is to steepen the anterior corneal surface.<sup>2,3</sup> We corrected the hyperopic refractive error by PRK in a patient with refractive accommodative esotropia. The patient became orthophoric after the treatment.

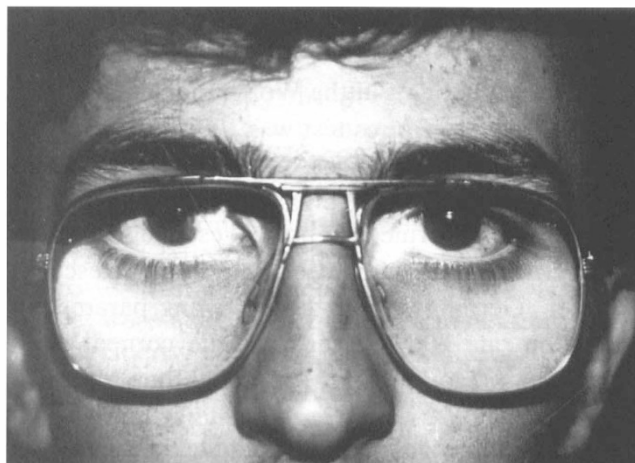
## CASE REPORT

A 19-year-old man with bilateral hyperopic astigmatism and refractive accommodative esotropia was referred to our clinic for PRK.

Uncorrected visual acuity was 20/200 in the right eye, 40/200 in the left eye. After full correction of the hypermetropic error, which was determined by cycloplegic refraction, the visual acuity of the right eye increased to 20/50 with +7.0 + 1.0 @90 correction

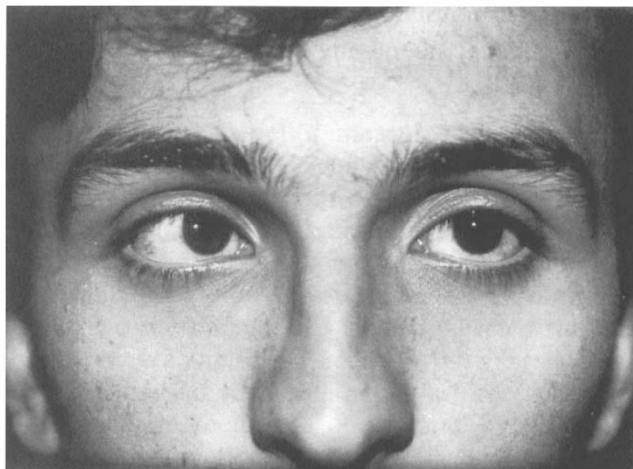From: Department of Ophthalmology, Gazi University Medical Faculty, Ankara, Turkey.

Correspondence to: Kamil Bilgihan, MD, Gunes sok. 3/11, Kavaklıdere/06690, Ankara, Turkey. Fax: +90 312 212 57 94.

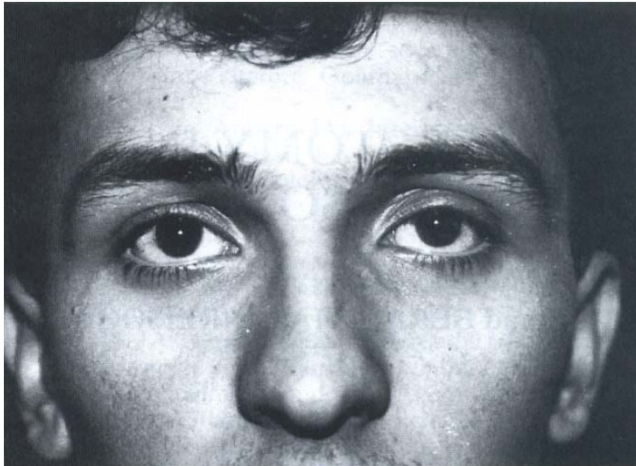


**Fig. 1.** *The patient is orthophoric with spectacles.*

and visual acuity of the left eye was found to be 20/20 with +5.0 + 1.0@90 correction. The refraction of the patient had not changed over 3 years. The patient was orthophoric while wearing spectacles but had an esotropia of 30 prism dioptres in the amblyopic right eye at near and distance vision without spectacles (Figs. 1,2).



**Fig. 2.** *Esotropia in the right eye, without spectacles.*



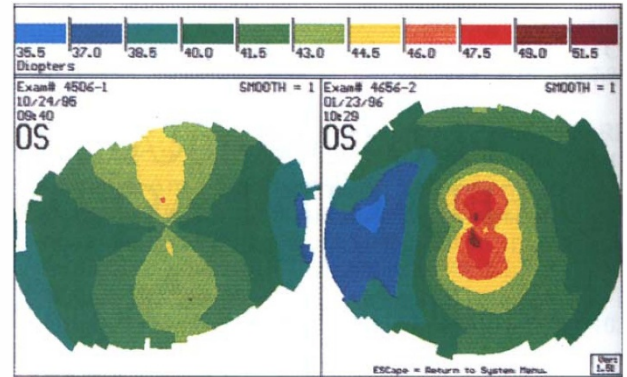
**Fig. 3.** The patient became orthophoric after PRK.

He saw three lights in the Worth four-dot test, and the result of the Titmus test was 120 seconds of arc. The slit lamp microscopic examination and the fundus examination of the patient were normal.

PRK was performed on both eyes using a 193 nm argon fluoride excimer laser (MEL 60, Aesculap, Meditec, Germany) with the following parameters: repetition rate 20 Hz; fluence at the corneal plane 220 mJ/cm<sup>2</sup>; ablation zone 7 mm. Photoablation was performed with the aid of a hyperopic mask.

Post-operative treatment included topical antibiotics and therapeutic contact lens until epithelium resurfacing. After complete re-epithelialisation the patient used 0.1% fluoromethalone seven times daily for the first and second month, five times daily for the third month.

After the correction of hyperopia with the excimer laser the patient became orthophoric at near and distance vision (Fig. 3). Uncorrected visual acuity was 20/50 in the right eye and 20/20 in the left eye in the fourth month and videokeratography showed central corneal steepening due to hyperopic photoablation (Fig. 4).



**Fig. 4.** (a) Corneal topography of the left eye before PRK. (b) Corneal topography of the same eye after the correction of hyperopic astigmatism by photoablation.

## DISCUSSION

It is believed that PRK is an efficient and relatively safe procedure for correcting hyperopia up to +7.5 dioptres.<sup>2</sup> Patient selection is very important and patients should be at least 18 years old and have had stable refraction for more than 1 year. As this procedure is not applied under general anaesthesia on a routine basis, cooperation depending on the age of the patient is very important in hyperopic PRK, because the main problem is decentralisation, which leads to the loss of best corrected visual acuity.<sup>3</sup>

To our knowledge this is the first reported case of refractive accommodative esotropia cured with the help of PRK. The indications of this rather new technique are still evolving.

Key words: Photorefractive keratectomy, Refractive accommodative esotropia.

## REFERENCES

1. Von Noorden GK. Binocular vision and ocular motility, 4th ed. St Louis: CV Mosby, 1990:289-91.
2. Dausch D, Klein R, Schröder E. Excimer laser photorefractive keratectomy for hyperopia. *Refract Corneal Surg* 1993;9:20-8.
3. Anshütz T. Laser correction of hyperopia and presbyopia. *Int Ophthalmol Clin* 1994;34:107-37.