

## Family- Monocercomonadidae

Organism posses 3-5 anterior flagella with recurrent flagella usually free

### Genus - Monocercomonas

- Pyriform body, 3 anterior flagella, a trailing flagellum but no undulating membrane
- Axostyle rod like protrude from posterior end

*Monocercomonas ruminantium* occur at rumen of cattle *M. gallinarum* in the caecum of chicken, non-pathogenic

### Genus - *Histomonas*

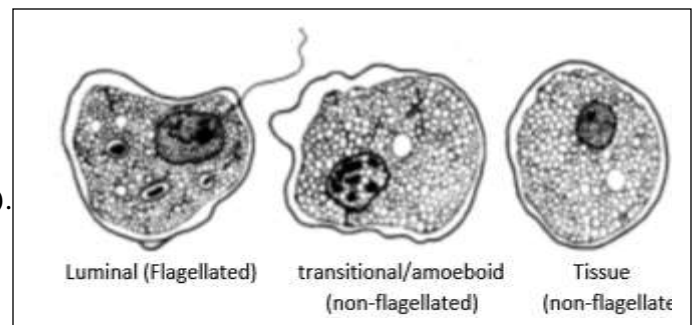
Organism are amoeboid with single nucleus, single flagellum arise from basal granule, close to nucleus.

### *Histomonas meleagridis*

The protozoan *Histomonas meleagridis* infects a wide range of gallinaceous birds and causes histomoniosis (blackhead disease) or infectious enterohepatitis. Chickens are typically asymptomatic carriers, but mortality in turkeys is commonly 80% -100%. Clinical signs include drooping head and wings, prolonged standing, closed eyes, ruffled feathers, emaciation, and sulfur-colored droppings. Diagnosis is based on pathognomonic ulceration of the ceaca and necrotic lesions in the liver. There are no vaccines.

### Etiology of Histomoniosis in Poultry

*Histomonas meleagridis*, an anaerobic protozoan parasite of the order Trichomonadida, is the causative agent of histomoniosis (blackhead disease). It can exist in flagellated (8–15  $\mu\text{m}$  in diameter) and amoeboid (8–30  $\mu\text{m}$  in diameter) forms.

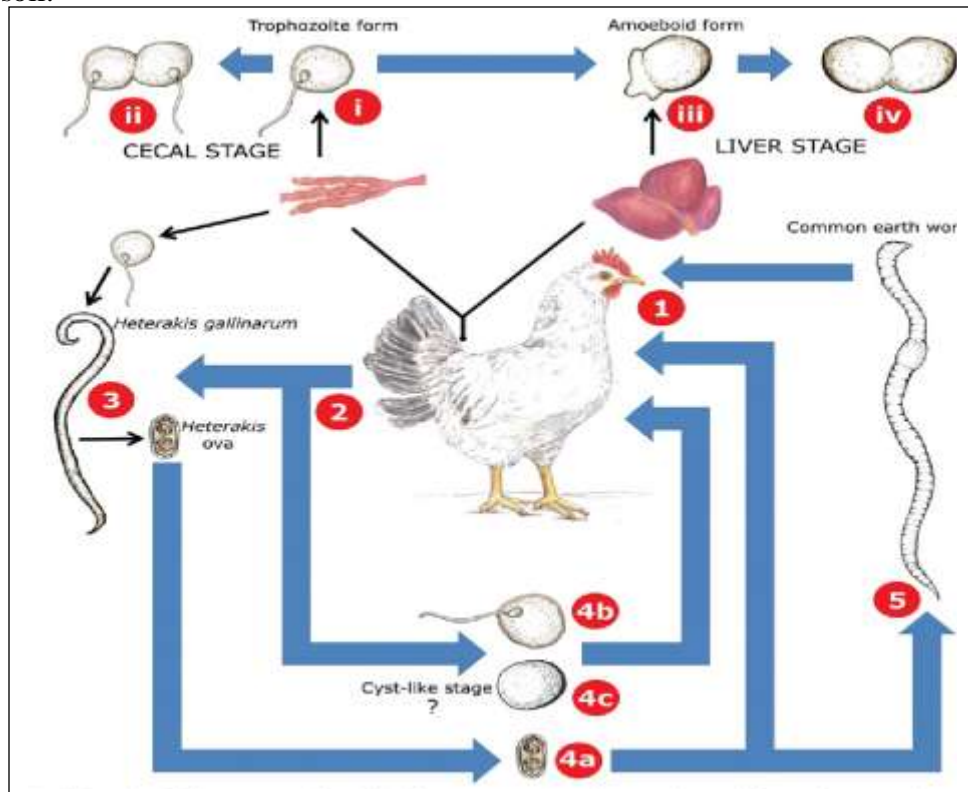


*H.meleagridis* is primarily transmitted in the egg of the cecal nematode, *Heterakis gallinarum*. Chickens and other gallinaceous birds act as a reservoir for *H gallinarum*. Nematode eggs infected with *H meleagridis* remain viable in the environment for years. Three species of earthworms can act as paratenic hosts for *H gallinarum* larvae containing *H meleagridis*. Chickens and turkeys that consume these earthworms can become infected with both *H gallinarum* and *H meleagridis*. In turkeys, transmission by direct cloacal contact with infected birds or via fresh droppings results in *H meleagridis* quickly spreading throughout the flock. Traditionally, histomoniosis has been thought of as affecting turkeys while doing little damage to chickens. However, outbreaks in chickens may cause morbidity and moderate mortality. Liver lesions tend to be absent or less severe in chickens but can involve secondary bacterial

infections. In most cases, chickens recover from clinical signs but remain carriers, whereas turkeys succumb to the infection.

### Life cycle

The life cycle of *Histomonas meleagridis* is shown in the figure. *Histomonas* trophozoites are ingested from the external environment in various forms by a gallinaceous bird (1). The flagellated trophozoite form of *Histomonas* travels to the caeca (i) where it multiplies by longitudinal binary fission (ii). Infections with *Histomonas* usually result in lesions on the caecal wall accompanied by a yellowish diarrhoea. Eventually, *Histomonas* trophozoites penetrate the caecal mucosa and travel to the liver, where they take on an amoeboid form (iii). The amoeboid form also multiplies by binary fission (iv). The damage caused to liver tissues during the invasive liver stage is often so severe that death will ensue. *Histomonas* organisms in various forms are then passed in the host's faeces (2) and contaminate food and water sources of other gallinaceous birds. In the event of a *Heterakis/Histomonas* coinfection, *Histomonas* trophozoites are ingested by a female *Heterakis* worm and invade its ovaries. Once in the *Heterakis* ovaries, *Histomonas* can then penetrate the developing *Heterakis* ova (3). These ova are then shed into the host's caeca by the female worm and are eventually passed in the host's faeces. *Histomonas* can remain viable outside the host within these ova for up to 2 years (4a). Alternatively, free flagellated trophozoites of *Histomonas* which were shed in the faeces may be directly ingested by a new host resulting in a *Histomonas* infection (4b). Recently, cyst-like structures of *Histomonas* have been described (4c) which could represent a newly discovered transmissible stage. However, the infectivity of these cyst-like structures is yet to be demonstrated. In the soil, *Heterakis* ova containing *Histomonas* organisms (4a) may also be ingested by the common earth worm (5) which may then be consumed by a gallinaceous bird, resulting in a *Histomonas* infection. Earthworms are believed to play a significant role in the survival of *Histomonas* organisms in the soil.



## Clinical Findings of Histomoniasis in Poultry

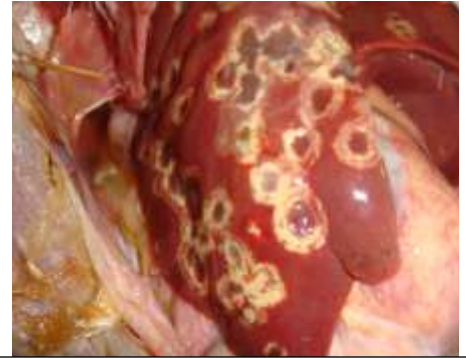
Signs of histomoniasis are apparent in turkeys 7–12 days after infection and include: listlessness reduced appetite drooping wings unkempt feathers yellow fecal droppings in the later stages of the disease

The origin of the name “**blackhead**” is obscure and misleading; birds do not display a cyanotic head. Young birds have a more acute disease course and die within a few days after signs appear. Older birds may be sick for some time and become emaciated before death.

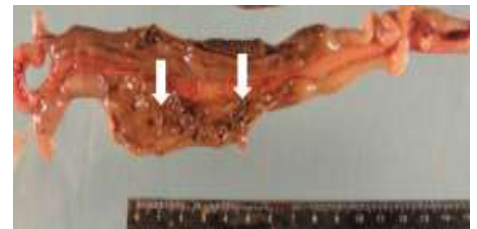The primary lesions of histomoniasis are in the ceca, where the parasite migrates into the submucosa and muscularis mucosae. This leads to inflammation and development of a yellowish green caseous exudate or, in later stages, a dry, cheesy core. Occasionally, these ulcers erode cecal wall, leading to peritonitis and involvement of other organs. The clinical signs in the caeca are apparent 3–4 days after *H meleagridis* invasion.

Histomonads can reach the liver either by the vascular system or via the peritoneal cavity. Liver lesions are highly variable in appearance; in turkeys, they appear 6–8 days after infection and may be up to 4 cm in diameter and involve the entire organ.

In some cases, the liver will appear green or tan. Lesions are also seen in other organs, such as the kidneys, bursa of Fabricius, spleen, and pancreas.



Multifocal to coalescing necrotic target lesions in the liver of a turkey with histomoniasis



Multiple pale whitish caecal worms (arrows) within a necrotic cecal lumen

## Diagnosis of Histomoniasis in Poultry

The liver and cecal lesions together are pathognomonic

PCR, examination of cecal contents under a microscope, and histopathologic examination can be used to diagnose histomoniasis. The liver lesions must be differentiated from those of: tuberculosis leukosis avian trichomoniasis mycosis

Histomonads are intercellular, although they may be so closely packed as to appear intracellular. The nuclei are much smaller than those of the host cells, and the cytoplasm less vacuolated. Scrapings from the liver lesions or ceca may be placed in isotonic saline solution for direct microscopic examination; *Histomonas* spp must be differentiated from other cecal flagellates.

## **Prevention and Treatment of Histomoniasis in Poultry**

Turkeys should not be raised with other galliformes such as chickens

Because healthy chickens and game birds often carry the caecal worm vector, any contact between turkeys and other galliformes should be avoided and care should be taken to reduce the worm population. Worm eggs, from contaminated soil, can be tracked inside by workers, causing infection. Arthropods such as flies may also serve as mechanical vectors. Because *H gallinarum* ova can survive in soil for many months or years, turkeys should not be put on ground contaminated by chickens. Once established in a turkey flock, infection spreads rapidly without a vector through direct contact. Dividing a facility into subunits using barriers can contain the outbreaks to specific units. Histomonads that are shed directly into the environment die quickly. Thus, in a turkey facility, where *H gallinarum* is unable to complete its life cycle, decontamination is not required. Immunization has only been partially successful in controlling histomoniasis, and reports differ on its effectiveness. The immune response of turkeys to live, attenuated *Histomonas* requires 4 weeks to develop. Vaccination of 18-week-old pullets 5 weeks before experimental infection has been shown to prevent a drop in egg production. Most workers have concluded that immunization of birds against this disease using live cultures is not practical. Killed organisms stimulate some immunity when given SC or IP but do not offer protection. No drugs are currently approved for use as treatments for histomoniasis. Historically, nitroimidazoles such as ronidazole, ipronidazole, and dimetridazole were used for prevention and treatment and were highly effective. Some of these products can be used by veterinary prescription in non-food-producing birds. Frequent worming of chickens with benzimidazoleanthelmintics helps reduce exposure to *H gallinarum* worms that carry the infection.

### **Treatment**

Furazolidone 0.01-0.02 % in food

Nithiazide 0.02% in the feed or drinking water

2-Acetylamino-5-nitrothiazole 0.025% in food

### **Key Points**

Chickens are a reservoir for *Histomonas meleagridis*.

*Heterakis gallinarum* eggs maintain *H meleagridis* in the environment.

Currently, there are no approved vaccines or treatments for histomoniasis (blackhead disease).