

# Viral Meningoencephalitis Patient with Comorbid Major Depression with Psychotic Symptoms: A Case Report

Maulana Farid Rizki<sup>1</sup>, Paulus Sugianto<sup>2,\*</sup>, Margarita Maria Maramis<sup>3</sup>, Soetjipto<sup>3</sup>

Maulana Farid Rizki<sup>1</sup>, Paulus Sugianto<sup>2,\*</sup>, Margarita Maria Maramis<sup>3</sup>, Soetjipto<sup>3</sup>

<sup>1</sup>Resident, Department of Neurology, Faculty of Medicine, Airlangga University, Dr. Soetomo General Hospital, Surabaya, INDONESIA.

<sup>2</sup>Medical Staff, Department of Neurology, Faculty of Medicine, Airlangga University, Dr. Soetomo General Hospital, Surabaya, INDONESIA.

<sup>3</sup>Medical Staff, Department of Psychiatry, Faculty of Medicine, Airlangga University, Dr. Soetomo General Hospital, Surabaya, INDONESIA.

## Correspondence

Paulus Sugianto

Medical Staff, Department of Neurology, Faculty of Medicine, Airlangga University, Dr. Soetomo General Hospital, Surabaya, INDONESIA.

E-mail: Paulus.sugianto.unair@gmail.com

## History

- Submission Date: 19-05-2022;
- Review completed: 11-06-2022;
- Accepted Date: 09-07-2022.

DOI : 10.5530/pj.2022.14.121

## Article Available online

<http://www.phcogj.com/v14/i3>

## Copyright

© 2022 Phcogj.Com. This is an open-access article distributed under the terms of the Creative Commons Attribution 4.0 International license.

## ABSTRACT

Viral meningoencephalitis causes meninges and brain parenchyma inflammation, thus provoking significant morbidity and mortality. Clinical features include neurological and psychiatric symptoms depending on the brain involved, mild symptoms such as fever, headache, neck stiffness, and confusion, or severe symptoms such as seizures, weakness, hallucinations, and coma. Therefore, the clinical diagnosis and treatment of such cases are challenging to make. This case report describes an adult male patient suffering from viral meningoencephalitis with comorbid major depression with psychotic symptoms. The patient requires holistic management of meningoencephalitis with comorbid depression and neuropsychiatric symptoms that may occur in the long term.

**Key words:** Viral meningoencephalitis, Comorbid, Depression.

## INTRODUCTION

Viral meningoencephalitis is an inflammation due to a viral infection involving the meninges and brain parenchyma. The incidence is around 3.5/100,000 to 7.4/100,000.<sup>1</sup> Clinical symptoms vary depending on the part of the brain involved. The prognosis is generally good, but some sudden and progressive onset cases may end with neurologic sequelae or even death. In clinical practice, clinicians need to master and carefully identify psychiatric symptoms caused by viral meningoencephalitis to reduce the rate of misdiagnosis and increase the efficiency of the diagnosis and therapy.<sup>2,3</sup>

Depression is a developing health problem in public. In 2015, it was estimated to be the third leading cause of disability worldwide.<sup>4</sup> Depression has a two-way relationship with other illnesses where the prognosis is worse when depression is present. Depression can be a risk factor in hospitalized infection patients.<sup>5</sup> A large population-based study in 60 countries found that 9-23% of people with chronic physical conditions had comorbid depression.<sup>6</sup>

Viral meningoencephalitis is inseparable from psychiatric symptoms in the form of organic mental disorders, which is essential to be considered because it is associated with systemic or brain disorders that can cause high mortality. This disorder often receives delayed treatment of the etiological cause because of the problematic identification of symptoms that can be fatal. In this case, patients with organic hallucinatory manifestations in viral meningoencephalitis received neurological and psychiatric management, so patient outcomes were successfully improved.<sup>7,8</sup>

## METHOD

This paper is a descriptive case report from a patient who has been briefed and received written consent regarding the neuropsychiatric interview, physical

and supporting examinations, case presentation, and confidentiality of all personal information of the patient.

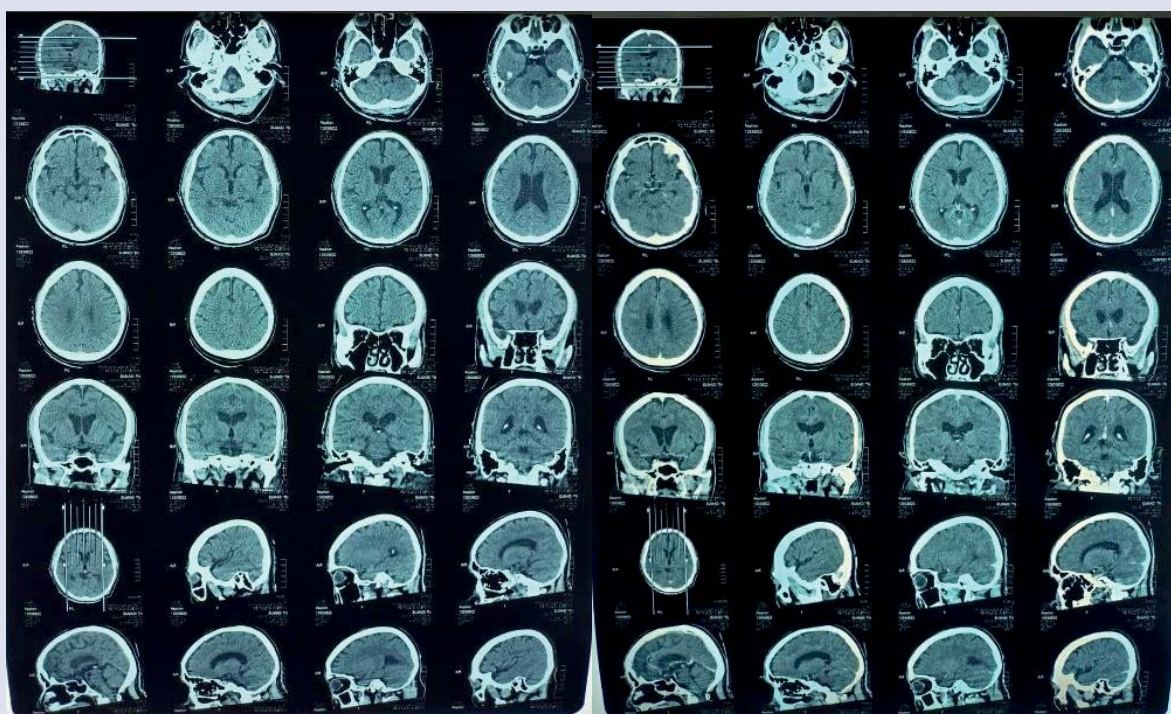
## CASE PRESENTATION

A 49-year-old male patient, Mr. S, with big stature, Javanese ethnicity, Muslim religion, lives in Nganjuk East Java, unmarried, a farmer.

The patient was referred to Dr. Soetomo General Hospital from Menur Mental Hospital with a suspected intracranial process that cannot be ruled out. The patient experienced a gradual decrease in consciousness starting two days before hospital admission. A few hours into hospital admission, the patient was screaming and angry before eventually losing consciousness. The patient had a fever for seven days before the hospital admission and vomited three times. The family did not know whether the patient had any previous headaches. Weakness/tingling/numbness in half of the body, facial drooping, slurred speech, seizures, and head trauma were denied. Complaints such as double vision, impaired taste, hearing loss, cavities, otorrhea, chronic cough, hemoptysis, and a history of using antituberculosis drugs were also denied. The previous history of hypertension, diabetes and stroke were denied. The patient had been treated at Menur Mental Hospital for 20 days before being referred to Dr. Soetomo General Hospital.

His vital signs included a blood pressure of 130/85 mmHg, heart rate of 90 beats per minute, respiratory rate of 22 breaths per minute, and body temperature of 37.5°C. Neurological examination revealed decreased consciousness with Glasgow Coma Scale (GCS) was 9/15 (Eye-opening, 3/4; Verbal response, 1/5; Moto response, 5/6) with positive meningeal sign in the form of neck stiffness but no lateralization and negative pathological reflexes while physiological reflexes were within normal limits. Laboratory investigations found leukocytosis (18710), hyponatremia (125 mg/dl), and an increase

**Cite this article:** Rizki MF, Sugianto P, Maramis MM, Soetjipto. Viral Meningoencephalitis Patient with Comorbid Major Depression with Psychotic Symptoms: A Case Report. Pharmacogn J. 2022;14(4): 455-458.



**Figure 1:** Head CT scan with and without contrast.

in AST (533) and ALT (101), while other parameters were within normal limits. On chest X-ray, no abnormalities were found. A head CT scan revealed leptomenigeal enhancement in the right and left parieto-occipital lobes as seen in (Figure 1).

The patient underwent a lumbar puncture (LP) on day 5 of treatment to analyze the cerebrospinal fluid/CSF. The results showed a predominance of mononuclear cells (100%), elevated protein (64 mg/dl), and decreased ratio of CSF glucose (82 mg/dl) and Serum glucose (161 mg/dl). However, the number of cells was within the normal limit (2 cells/mm<sup>3</sup>) because the patient had been taking 5 x 800 mg of acyclovir therapy per sonde for three days. Cerebrospinal fluid culture results showed no bacterial infection.

The patient was angry and screaming; therefore, the patient was then referred to the psychiatry department. Based on the examination, the patient appeared to be an adult male with an age-appropriate face, lying and fixated in both hands and feet on a bed with nasal cannula O<sub>2</sub> installed, an infusion line on the right hand, and a urinary catheter attached. The patient's eyes were closed, but he was able to be awakened, looked confused, and answered "yes" for greetings given. Likewise, any other questions were also answered with "yes". The patient was unable to maintain eye contact. The patient experienced disorientation in time and place and mistakenly recognizes the family waiting for him. The patient was unable to follow simple commands. The patient tried to sit up and screamed to urinate even though a urinary catheter was attached before the patient could be calmed down.

The patient's siblings and nephews stated that twenty days before the hospital admission, the patient's lips were drooping and drooling a lot. The patient also had difficulty walking, so he was taken to Menur Mental Hospital. After being treated in Menur Mental Hospital, the patient improved. He then could walk again, and his lips were not drooping anymore. Seven days before the hospital admission, the patient complained of chest pain and fever and screamed with a blank stare. A day before the hospital admission, the patient did not recognize the family, then he was brought again to the Menur Mental Hospital and referred to the Dr. Soetomo General Hospital.

The patient had a history of suicide attempts with many cuts on his stomach about four years ago when his mother died, and then he was treated at the Menur Mental Hospital with sertraline, clozapine, trihexyphenidyl, and vitamin B. The patient was then diagnosed with major depression with psychotic symptoms. He had routine medical control at Rejoso Nganjuk Hospital and then never relapsed. About six months ago, the patient's girlfriend died due to COVID-19, so the patient was confused and gradually stopped working in the rice fields. The patient told his sister that he heard male and female voices telling him to "just die".

The psychiatrist suggested temporarily discontinuing the previous drugs and the patient should have psychopharmaceutical therapy with haloperidol 0.5 mg orally, every morning and evening, if possible. If restless, haloperidol 2.5 mg intramuscular injection might be given. The patient was placed in a quiet room with enough brightness and accompanied by a known family. Supportive psychotherapy was given to the patient every time a visit was made to make the patient feel comfortable and cooperative with the undergoing therapy. The patient's family had received psychoeducation about the patient's condition and could understand the situation.

## DISCUSSION

### Viral meningoencephalitis

Viral meningoencephalitis is inflammation due to viral infection involving the meninges and brain parenchyma.<sup>1</sup> Clinical features include neurological and psychiatric symptoms depending on the brain affected, mild symptoms such as fever, headache, neck stiffness, confusion, or severe symptoms such as seizures, weakness, hallucinations, and coma. Herpes simplex virus (HSV) accounts for 50% to 75% of identified viral cases, with varicella-zoster virus (VZV), enteroviral, and arboviral making up the majority of the rest. A physical examination only is difficult to be used as a reference to establish a diagnosis. Routine laboratory tests are not very helpful in establishing the diagnosis. Some evaluation tests include complete blood count, kidney function tests, and liver function tests.<sup>2,9</sup>

On lumbar puncture examination, CSF pleocytosis ( $> 5$  cells/uL) occurred in  $> 95\%$  of immunocompetent patients with viral meningoencephalitis. There were cases where pleocytosis was not found in the initial LP but appeared in the later lumbar puncture. However, such cases are rare. CSF analysis is crucial, including polymerase chain reaction (PCR), because magnetic resonance imaging (MRI) can only diagnose meningoencephalitis but cannot differentiate viral etiologic agents. Neuroimaging CT scan in meningoencephalitis is useful for rapidly evaluating suspected edema and/or compartmental shifting of the brain that may require intervention and contraindicate for lumbar puncture. On CT scan, focal areas of low absorption, mass effect, and contrast enhancement are seen. MRI is superior to CT scan for diagnostic. Meningoencephalitis cases on CT scans were abnormal in about half of all cases, whereas MRI results were abnormal in almost all cases.<sup>10,11</sup>

In this case, the patient experienced fever, neck stiffness, and behavioral changes like anger and screaming as the symptoms of an organic mental disorder, supporting the diagnosis of viral meningoencephalitis. The symptoms of organic mental disorder caused by viral meningoencephalitis mainly consist of cognitive impairment, attention disorders, perceptual disorders, and changes in ways of thinking, mood, and personality. Approximately 81% of patients with viral meningoencephalitis have varying degrees and symptoms of mental disorders seen in different stages of the disease course. These symptoms are easily confused with schizophrenia. The misdiagnosis rate reaches 45%.<sup>1</sup>

Head CT-Scan imaging showed leptomeningeal enhancement in the right and left parieto-occipital lobes. This feature is usually associated with meningitis. CSF analysis in this patient showed a predominance of mononuclear cells (100%), elevated protein (64 mg/dl), decreased ratio of CSF glucose (82 mg/dl) and Serum Glucose (161mg/dl). However, the cell count of this patient was within the normal limit (2 cells/mm<sup>3</sup>) because he had been taking 5 x 800 mg of acyclovir therapy per sonde for three days, supporting the diagnosis of viral infection. CSF culture results showed no bacterial infection. The patient also experienced clinical improvement with the administration of acyclovir.

### Major depression with psychotic symptoms as comorbidity

The patient had a history of depression for four years since his mother died. Depression is a mood disorder characterized by the presence of depressive affect, anhedonia, anergia, and other minor symptoms.<sup>6</sup> Numerous studies have reported that depression was prospectively associated with an increased risk of acute respiratory infections, viral shingles, intestinal *E. coli* infections, pneumonia, meningitis, also COVID-19. Here are some mechanisms by which depression can increase the likelihood of infection and hospitalization. First, the dysregulation of neuroendocrine pathways (e.g., hypothalamic-pituitary-adrenal axis) results in immunosuppression evidenced by changes in immune cell distributions, decreased lymphocyte proliferation, as well as reduced virus-specific T cell response, and memory T cell response. Thus, increasing the risk of contracting infectious diseases. Second, there is evidence of the two-way relationship between depression and changes in the gut microbiome. The gut microbiome is known to interact with the immune system. It means that the changes caused by suppression in the microbiome can have implications for the spread of infection. In addition, unhealthy behaviors are associated with decreased physical activity and poor sleep quality. These have been given an impact on immune function and increase the risk of infection. Other factors such as poor coping skills, lack of social support, and functional impairment related to depression. They may increase the likelihood of hospitalization regardless of the severity of the infection.<sup>5,12</sup>

We still found subjective cognitive complaints, depression, and anxiety in post-meningoencephalitis infection. Psychiatric examinations showed significantly higher short- and long-term depression and anxiety levels. These findings were in line with other studies that explain the psychiatric sequelae of meningoencephalitis in the form of depression and anxiety caused by neurobiological changes and psychological adjustments to meningoencephalitis. The outcomes of meningoencephalitis vary depending on the etiology, so the rehabilitation program should be adapted.<sup>7</sup> Once the neurotropic virus reaches the brain parenchyma, cells such as neurons, astrocytes, and microglia, can be infected, causing the secretion of pro-inflammatory molecules and infiltration of immune cells that cause brain damage. A local immune response can remain active after viral infection, contributing to long-term neuropsychiatric, neurocognitive, and degenerative disorders.<sup>3</sup>

### Treatment

Meningoencephalitis patients often require intensive monitoring and supportive care of oxygenation, airway patency, circulatory support, treatment of fever, cardiac arrhythmias, and instability of the autonomic system. Monitoring is necessary to know the direct effects of cerebral inflammation, especially cerebral edema, increased intracranial pressure, and focal or general seizures. Antiviral administration is essential to minimize clinical symptoms, prevent complications and morbidity of the disease, and reduce the recurrence rate and the spread of the virus itself. Acyclovir, as the drug of choice, can be given at a dose of 10-15 mg/kg IV every 8 hours for 10 days; sometimes, it takes up to 14-21 days.<sup>9,13</sup>

Many post-meningoencephalitis patients experience significant morbidity that requires ongoing treatment of some aspects that can get benefit from rehabilitation and prevent further worsening. Patients recovering from the acute phase need to undergo long-term rehabilitation with considerable variability in the degree of functional, cognitive, and emotional recovery. The first step in treating post-meningoencephalitis patients is to ensure that adequate medical care is available to identify and deal with ongoing problems. Psychiatric follow-up is also essential. Patients with post-meningoencephalitis may show severe behavioral disorders, possibly due to damage to the amygdala or perfusion changes to the frontal lobe. Neuropsychiatric evaluation will be able to identify ongoing emotional disorders (anxiety, depression, psychosis) or behaviors (agitation, aggression, disinhibition) and provide appropriate psychopharmaceutical management to solve each problem symptomatically. Frequently used medication includes benzodiazepines, antipsychotics, anticonvulsants, antidepressants, stimulants, and cholinesterase inhibitors. In addition, new modalities, such as transcranial magnetic stimulation (TMS), can be considered.<sup>8,14</sup>

### CONCLUSION

The clinical manifestations of viral meningoencephalitis are not only neurological symptoms but also psychiatric symptoms such as behavioral changes. Depression as comorbidity is one of the risk factors for infection. In addition, depression can be a long-term complication in viral meningoencephalitis. Therefore, holistic management, including etiological and psychiatric treatments of the acute phase and long-term view is essential in treating such patients.

### CONFLICTS OF INTEREST

The authors declare no conflicts of interest regarding the publication of this paper.

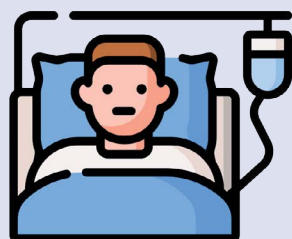
### ACKNOWLEDGMENT

The authors would like to thank the patient and family for allowing us to get the data and have been willing to be published.

## REFERENCES

1. Costa BK da, Sato DK. Viral encephalitis: a practical review on diagnostic approach and treatment. *J Pediatr (Rio J)*. 2020;96(1):12-9.
2. Bohmwald K, Andrade CA, Gálvez NMS, Mora VP, Muñoz JT, Kalergis AM. The Causes and Long-Term Consequences of Viral Encephalitis. *Front Cell Neurosci*. 2021;15(3):1-19.
3. Zheng M, Bi R, Lin Y, Zhu C, Zhu D. Case report of the treatment and experience of mental disorders due to chronic viral encephalitis. *Gen Psychiatry*. 2021;34(1):2020-2.
4. Park LT, Zarate CA. Depression in the primary care setting. *N Engl J Med*. 2019;379(6):559-68.
5. Ronaldson A, de la Torre JA, Sima R. Prospective associations between depression and risk of hospitalization for infection: Findings from the UK Biobank. *Brain Behav Immun*. 2022;102(2):292-8.
6. Ferencik EK, Ramanuj P, Pincus HA. Depression in primary care: part 1-screening and diagnosis. *BMJ*. 2019;365:l794.
7. Harris L, Griem J, Gummery A. Neuropsychological and psychiatric outcomes in encephalitis: A multi-centre case-control study. *PLoS One*. 2020;15(3):1-24.
8. Harder JA, Mariano TY. The importance of comprehensive neuropsychiatric care in the postencephalitic patient. *Future Neurol*. 2018;13(4):173-6.
9. Tyler KL. Acute Viral Encephalitis. *N Engl J Med*. 2018;379(6):557-66.
10. Kennedy PGE, Quan PL, Lipkin WI. Viral encephalitis of unknown cause: Current perspective and recent advances. *Virales*. 2017;9(6):1-8.
11. Feng G, Zhou L, Li F, Hu Y, Wang X, Tian X. Predictors of Outcome in Clinically Diagnosed Viral Encephalitis Patients: A 5-Year Prospective Study. *Biomed Res Int*. 2020;2020:2832418.
12. Doyle C, Swain WA, Swain Ewald HA, Ewald PW. Inflammation, infection and depression: an evolutionary perspective. *Evol Hum Sci*. 2019;1.
13. Munir B. Ensefalitis Virus. In: Sugianto P, Ganiem AR, Munir B. *Modul Neuroinfeksi*. 1st ed. UB Press. 2019;129-74.
14. Quist-Paulsen E, Ormaasen V, Kran AMB. Encephalitis and aseptic meningitis: short-term and long-term outcome, quality of life and neuropsychological functioning. *Sci Rep*. 2019;9(1):1-9.

## GRAPHICAL ABSTRACT



A male patient



suffering from viral meningoencephalitis with comorbid major depression with psychotic symptoms

## ABOUT AUTHORS



Maulana Farid Rizki is a Neurology Resident at Department of Neurology, Faculty of Medicine, Airlangga University that practices in Dr. Soetomo General Hospital, Surabaya city, Indonesia.

**Cite this article:** Rizki MF, Sugianto P, Maramis MM, Soetjpto. Viral Meningoencephalitis Patient with Comorbid Major Depression with Psychotic Symptoms: A Case Report. *Pharmacogn J*. 2022;14(4): 455-458.