

CASE REPORT

Central Retinal Artery Occlusion, Reduced to Inferotemporal Branch Retinal Artery Occlusion in an Otherwise Healthy Full Term Pregnant Patient: A Case Report

Anastasios John Kanellopoulos*

¹LaserVision Clinical & Research Eye Institute, Athens, Greece

***Corresponding Author:** Anastasios John Kanellopoulos, Laservision Clinical and Research Eye Institute, Athens, Greece, Tel.: +306944789787, Fax: + 30 210 7472789, E-mail: ajkmd@mac.com

Citation: Anastasios John Kanellopoulos (2023) Central Retinal Artery Occlusion, Reduced to Inferotemporal Branch Retinal Artery Occlusion in an Otherwise Healthy Full Term Pregnant Patient: A Case Report. J Clin Trials Rep 1: 101

Abstract

Purpose: To report the diagnosis and immediate care in a case of a low-risk pregnancy complicated at late term by acute retinal artery occlusion at the 39th week of gestation.

Methods: Single patient, comprehensive obstetric, medical and ophthalmic examination.

Results: A primipara woman, aged 32, reported sudden, painless loss of vision in her left eye during the 39th week of a well monitored and non-incidental gestation. The patient was evaluated immediately by her obstetrician (PH) and excluded sudden onset pre-eclampsia complication of pregnancy. Urgent parallel ophthalmologic examination revealed initially a central retinal artery occlusion that prompted immediate anterior chamber paracentesis for ocular decompression and vigorous orbital massage, urgent cesarian delivery was performed few hours later, followed by short term anticoagulant therapy. Visual symptoms rapidly improved and 4 days later extensive ophthalmic evaluation revealed improved diagnosis of a inferotemporal branch retinal occlusion. Extensive laboratory and imaging workup was unable to identify any underlying etiology.

Conclusion: CRAO and BRAO has been reported to rarely occur in young patients as a sudden insult without history of thromboembolism. CRAO and/or BRAO in the context of pregnancy alone has been considered very rare. This case suggests that prompt ophthalmic intervention may have reduced the incident from a CRVA to an BRAO and fortunately prompt obstetrics intervention achieved an excellent outcome for both the neonate and mother.

Keywords: CRAO; BRAO; Retinal Occlusion; Pregnancy

Background

Central (CRAO) and Branch retinal artery occlusion (BRAO) causes obstruction of blood flow in the distribution of the affected vessel, leading to ischemia of the retinal layers, accompanied by abrupt, segmental visual loss. It is mainly associated with thrombophilia, commonly found in the elderly, in the context of vascular atheromatosis. There are reports of CRAO and BRAO occurring in young individuals, most of which have an underlying thrombophilia, although there have been cases in which the etiology is poorly understood. Several physiologic hormonal and/or anatomic changes of multiple factors in pregnancy can result in thromboembolic pre-disposition, to include rare central or branch retina artery occlusion.. Co-existing in pregnancy physiologic changes hormonal factors such as increased angiopoiesis induced by progesterone, thrombophilic diathesis during pregnancy from hypercoagulability and/or thrombophilia, metabolic, cardiovascular increased output, and even pregnancy-related immunologic changes that may propagate retinal vascular occlusive events may increase the risk and incidence of this rare disorder.

In general there are several systemic underlying risk factors that may predispose and/or propagate retinal vascular occlusion such as:

- 1-Primary antiphospholipid antibody syndrome, high factor VIII
- 2- Low protein S
- 3-Factor V Leiden mutation
- 4-Increased D-dimer

We report a rare case of CRAO that was reduced to BRAO in a healthy almost at term 32 year-old pregnant woman.

Case Presentation

A primipara (G1,P0) healthy woman, aged 32, reported a sudden loss of vision in her left eye, at the 39th week of gestation.

Patient History and Pregnancy: The current pregnancy was spontaneous and there were no previous pregnancies or miscarriages. She had no history of infectious diseases or any previous surgeries, nor any previous notable ophthalmologic incident. The patient herself was an experienced active nurse. Body weight at the time of the incident was 75kg (BMI 23.9 m/Kg²) 14kgs of those attributed to the current pregnancy. Her past medical history was normal, she had no allergies, used no medication prior or during her pregnancy besides Folate and vitamin supplements. Her blood type was group O rhesus positive.

She had a 5 pack -year cigarette smoking history, and had reduced smoking significantly during the current pregnancy. She had a history of an unspecified positive Ra test (Rheumatoid Factor) 6 years before pregnancy with negative further evaluation at the time for rheumatoid arthritis. extensive prenatal examinations including 1st trimester biochemistry, mid-pregnancy fetal anatomy ultrasonography and 3rd trimester Doppler ultrasonography examination, monthly blood pressure and urinalysis were all normal, with only exception uterine artery notching noted by ultrasonography that was treated with 80mg acetylsalicylic acid (aspirin) daily from the 12th to 36th week of gestation, at which time it was discontinued, to allow parturition.

The reduction of vision was abrupt, described as amaurosis from her left eye, painless, and occurred during daily showering and without any noted provocative factors. She only recalled experiencing some brief transient visual floater episode from that left eye a week prior, that resolved spontaneously without any visual function reduction.

Immediately following her amaurosis she reached her maternity hospital and was evaluated immediately both for her ophthalmic symptoms and also to exclude an acute onset hypertensive disorder of pregnancy. Fetal viability and blood pressure were normal and rapid urinalysis negative for proteinuria.

Significant visual loss was documented in the left eye, as acuity had dropped to count fingers while the right was 20/20 uncorrected. A running diagnosis at the maternity hospital was that of central retinal artery occlusion. Immediately anterior chamber decompression by aspiration of aqueous fluid was performed by the on-call ophthalmologist, using a 30 gauge needle inserted in the anterior chamber via the corneal periphery at the slit-lamp, combined with vigorous left globe massage, both estimated less than an hour since the amaurosis symptoms first started.

To prevent possible further thromboembolic insult and to allow administration of therapeutic doses of anticoagulants, a cesarean section was performed right away-three hours after the visual symptoms onset. Subsequently, low molecular weight heparin was administered at 7500 IU subcutaneously daily. The neonate was a fully healthy male with birth weight 3180 grams.

The mothers postpartum period from the obstetrics standpoint was uneventful, during which she underwent extensive laboratory and imaging examination, in order to identify any possible etiology and continuation of the above-mentioned prophylactic heparin treatment.

We evaluated the patient 4 days postpartum on an outpatient basis. Uncorrected Distance Visual Acuity was 20/20 in her right, while her left eye had improved to 20/30 (patient was emmetropic in both eyes) with clear subjective description that only her lower temporal field was lucent and she was still experiencing upper half and nasal quadrant scotomas. Intraocular pressures measured by applanation were 14 and 10 mmHg respectively. She had a positive left afferent pupillary defect, anterior segment evaluation was normal for both eyes, while fundus examination was normal for the right eye and the left revealed retina palor along the inferior temporal retinal arcade, consistent with inferotemporal branch retinal artery occlusion at this point, confirmed by OCT angiography (OCT model Avanti, Optovue, CA, USA) illustrated in Figure 1.

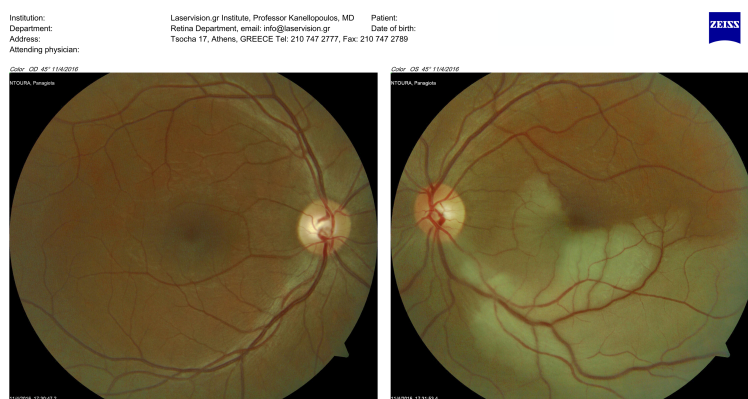

Figure 1: Clinical image documenting the Branch Inferior Temporal Artery occlusion in the left eye with marked associated whitish edema of the inferotemporal retina, The CRASO has been converted successfully to a BRVO

Extensive Evaluation Included

Cardiologic: Heart ultrasound triplex was performed twice, of which the first, was took place within the delivery ward just prior to the cesarean section followed by a more extensive triplex examination in the 1st post-partum day. A 24 hour Holter monitor examination for possible arrhythmia was also performed the same day. Ultrasound Triplex examination of the carotid arteries was performed on postpartum day 2.

Neurologic examination including magnetic resonance imaging and angiography (MRI and MRA) of the brain was also performed all of the above without any identifiable pathology.

Blood assessment for thrombophilia or vasculitis included extensive laboratory examination to include factor V Leiden, protein S, protein C, and antiphospholipid antibodies, serum homocysteine levels and a series of possible mutations given.

All factors were within normal range. Extensive laboratory Rheumatologic examination was repeated (taken the older unspecified positive Ra test (Rheumatoid Factor) 6 years before pregnancy) and was negative.

No further treatment was administered besides a 6 month prophylactic use of 80mg of aspirin following the first postpartum week.

Last ophthalmologic evaluation five years later, revealed no change in acuity with UDVA 20/20 and 20/23 OD and OS respectively, normal IOP, a left afferent pupillary defect, normal anterior and posterior evaluation. Repeat OCT angiography demonstrated persistent deficit of the perfusion of the area where the occlusion took place and her GCC retina map shows the loss of ganglion cells respectively (Avanti, Optovue, CA, USA).

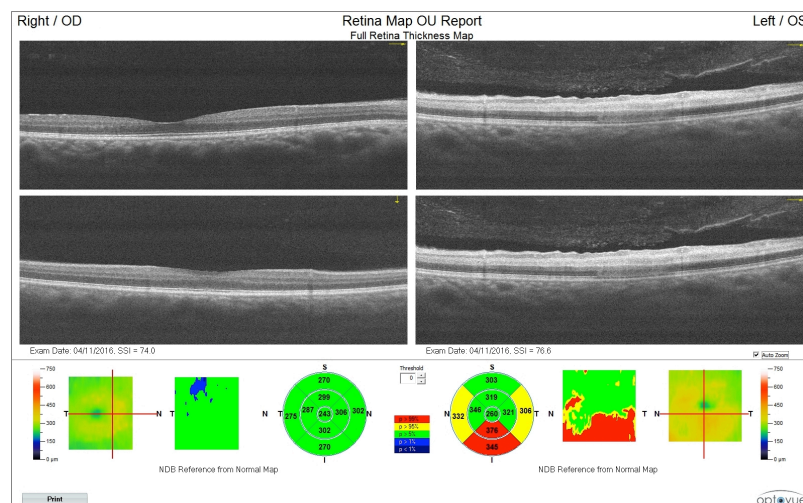


Figure 2: Corresponding OCT macula section comparison between the right healthy macula, and the left demonstrating signs of marked NFL edema

Discussion

The first case of CRAO (central retinal arterial occlusion) was described in 1859 by von Graefe and it was a case caused by multiple systemic emboli from endocarditis [1]. Typically patients present with painless unilateral decreased vision and visual field loss. Upon examination the retina is found to be white along the route of the affected artery. Emboli may also be observed [2].

Considering the symptomatology and the well documented early ophthalmic findings and interventions the case described herein may have started as a CRAO that was reduced to a inferotemporal BRAO attributed to the under 60 minute prompt ophthalmic intervention that may had been successful in dislodging the possible causative embolus from the central retinal artery.

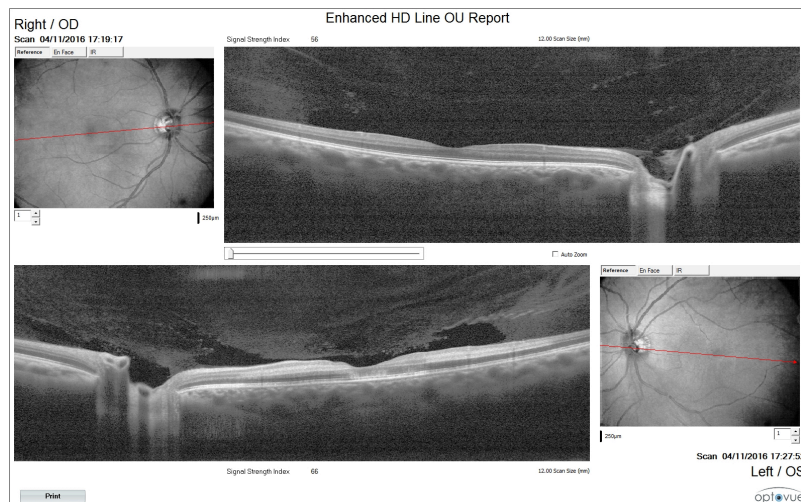


Figure 3: Another comparison of OCT sections of the OD and OS at the day we initially evaluated the patient

Even successfully reduced as a BRAO, this case poses an extremely rare clinical entity especially when considering the young age of the patient and absent known pre-disposing factors. The incidence of retinal arterial obstruction in patients under the age of 30 years has been estimated at less than 1 in 50,000 outpatients [3, 4]. In this age group the thrombotic episode occurs most often secondarily to an underlying condition, most often emboli originating from the heart or the carotids [5]. Therefore, a thorough evaluation of cardiac function, valvular pathology or the presence of a patent foramen oval, and abnormalities of blood flow through the carotid arteries must be conducted when encountering a BRAO patient. It is of particular significance to note that not only the degree of carotid stenosis is important when investigating the cause of the occlusion, but also the presence of plaques along the carotid arteries [6]. Our patient’s transesophageal echocardiogram and carotid ultrasound were negative.

Other reported associated conditions include hypercoagulable states, hyperhomocysteinemia, vasculitis, other risk factors such as smoking, use of oral contraceptives, and vasospasm such as in a history of migraine, embolism from atheromatous plaques in the carotid arteries, during carotid angiography and stenting or cardiac cauterization or coronary angiography, atrial fibrillation, mitral or aortic valve mass, bacterial endocarditis, atrial myxoma, patent foramen ovale, anti-phospholipid syndrome, Takayasu’s arteritis, migraine, Susac’s syndrome and other viral or infectious etiologies, including recently reported even COVID-19 infections [7-10].

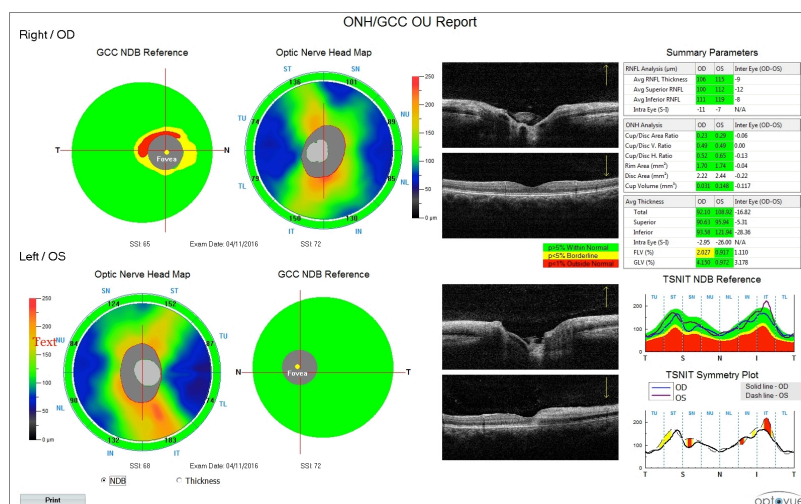


Figure 4: ONH and Ganglion cell layer (GCC) comparison of the OD and affected OS at the day of our initial evaluation demonstrating little difference

A significant percentage of patients presenting with BRAO had an underlying thrombophilic disposition such as factor V Leiden, protein C and S deficiency or homocystinuria[2, 11, 12] These disorders are more commonly found among younger individuals and thus it is imperative to promptly check for these pathologies when encountering a patient with BRAO. This workup in our patient came back normal

Currently there is no treatment proven to reverse arterial occlusion but various methods have been proposed. Commonly an anterior chamber paracentesis is performed to reduce intraocular pressure and promote retinal vessel dilation and thus enhance retinal perfusion. The same logic applies when performing ocular massage. In our case this intervention administered promptly may have improved the possible initial CRAO to a BRAO with obviously far better prognosis for the patient. Other methods reported include a hyperbaric oxygen chamber, thrombolysis, YAG laser embolotomy or use of medications to lower intraocular pressure. The potential therapeutic effect for these methods remains either anecdotal or limited to case series and few have been evaluated via randomized clinical trials. [13-15].Furthermore, the application of any of the aforementioned techniques must occur within a limited window of time as animal models suggest the retina can tolerate retinal ischemia without detectable damage for a maximum of 97 minutes. If the retina remained ischemic for more than 4 hours then the damage was considered irreversible [6].

While it seems prudent to prescribe aspirin after an incident of retinal occlusion, no treatment is proven to provide a therapeutic outcome for BRAO. The clinician must take into account the possibility of a future thrombotic episode, which is more likely after a retinal artery occlusion event,[16] and consider the administration of antithrombotic agents such as low dose aspirin as a prophylactic measure. However, Kang et al. reported that there was no benefit on attenuating the risk of ischaemic stroke, acute coronary syndrome or major bleeding incidents when aspirin was prescribed [17]. Hayreh et al. recommended the use of aspirin compared to other anticoagulant therapy [6].

In our case, the patient received low dose aspirin due to uterine artery notching, which was discontinued 3 weeks prior her acute visual field loss. After acute management the patient was put on low dose aspirin and no other thrombotic incident was reported.

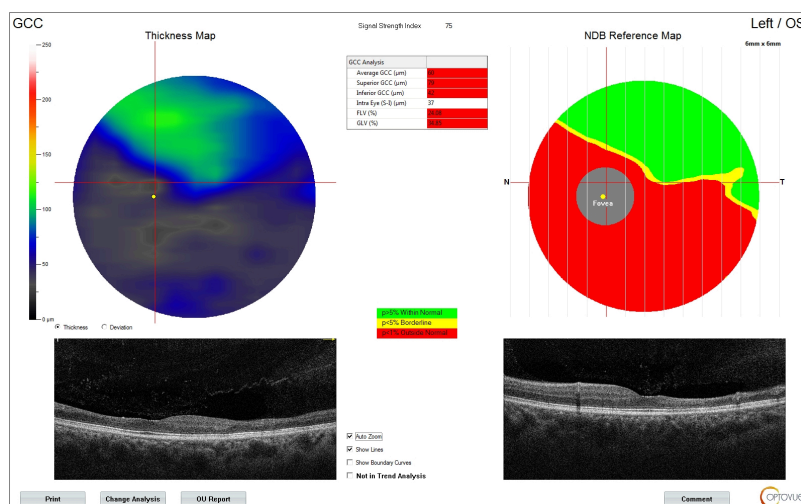


Figure 5: ONH and GCC respective imaging 3 years later demonstrating the severe loss of inferotemporal optic disc rim fibres and corresponding loss of the inferior portion of the macula ganglion cell layer in red (GCC) the vision has dropped to 6/10 or 20/30+ from 20/20 at presentation

The visual outcome after acute management of BRAO depends on whether the occlusion is permanent or temporary. When it comes to permanent BRAO, 79% of patients with initial VA of less than 20/40 improved a week after the onset of symptoms as reported by Hayreh et al. This improvement can occur spontaneously with no intervention as patients learn to fixate eccentrically [18].

Conclusion

To our knowledge, this is the first case report of a young female patient presenting with initial CRAO that may have been successfully reduced to a BRAO, at full term pregnancy, with no other known underlying condition other than light smoking. We hope sharing these data will help caution ophthalmic and maternity clinicians on any similar potential cases and the importance of immediate multispecialty and multidisciplinary intervention.

Conflict of Interest

The authors declare that there is no conflict of interests regarding the publication of this paper.

References

1. Graefe A (2007) Ueber Embolie der Arteria centralis retinae als Ursache plötzlicher Erblindung. *Archiv für Ophthalmologie*, 5: 136-157.
2. Mehta N, Marco RD, Goldhardt R, Modi Y (2017) Central Retinal Artery Occlusion: Acute Management and Treatment. *Curr Ophthalmol Rep*. 5: 149-59.
3. Bisighini S and T Zerilli-Zavgorodni (2012) Branch retinal artery occlusion secondary to antiphospholipid syndrome. *Optom Vis Sci*. 89: e78-84.
4. Brown GC et al. (1981) Retinal arterial obstruction in children and young adults. *Ophthalmology*. 88: 18-25.
5. Stepanov A et al. (2015) Transient branch retinal artery occlusion in a 15-year-old girl and review of the literature. *Biomed Pap Med Fac Univ Palacky Olomouc Czech Repub*. 159: 508-11.
6. Vestergaard N et al. (2019) Animal Models Used to Simulate Retinal Artery Occlusion: A Comprehensive Review. *Transl Vis Sci Technol*. 8: 23.
7. Hayreh SS, PA Podhajsky and MB Zimmerman (2009) Branch retinal artery occlusion: natural history of visual outcome. *Ophthalmology*. 116: 1188-94.
8. Hayreh SS (2011) Acute retinal arterial occlusive disorders. *Prog Retin Eye Res*. 30(5): p. 359-94.
9. Ateş O, M Yıldırım and K Yıldırım (2021) Branch Retinal Artery Occlusion in Patient with COVID-19. *Korean J Ophthalmol*.
10. Agarwal M et al. (2020) Ocular Gnathostomiasis Presenting as Branch Retinal Artery Occlusion. *Ocul Immunol Inflamm* 1-4.
11. Sauma J et al (2020) Susac's syndrome: an update. 104: 1190-5.
12. Shute C (2018) A case report of branch retinal artery occlusion in a teenager due to hyperhomocysteinaemia; the interplay of genetic and nutritional defects. *BMC Ophthalmol*, 18(Suppl 1): 220.
13. Kurtz WS et al. (2016) Retinal artery and vein thrombotic occlusion during pregnancy: markers for familial thrombophilia and adverse pregnancy outcomes. *Clin Ophthalmol* 10: 935-8.
14. Scott IU et al (2020) Retinal vascular occlusions. *Lancet* 396: 1927-40.

15. Sharma RA et al. (2018) Treatment of Nonarteritic Acute Central Retinal Artery Occlusion. *Asia Pac J Ophthalmol (Phila)*. 4: 235-41.
16. Youn TS et al. (2018) Current treatment of central retinal artery occlusion: a national survey. *Journal of Neurology*, 265: 330-5.
17. French DD, CE Margo and PB (2018) Greenberg, Ischemic Stroke Risk in Medicare Beneficiaries with Central Retinal Artery Occlusion: A Retrospective Cohort Study. *Ophthalmology and Therapy* 7: 125-31.
18. Kang EY et al. (2019) Aspirin use in central retinal arterial occlusion to prevent ischaemic stroke: a retrospective cohort study in Taiwan. *BMJ Open*, 9: e025455.
19. Hayreh SS (2014) Ocular vascular occlusive disorders: natural history of visual outcome. *Prog Retin Eye Res*. 41: 1-25.