



ISSN (E): 2277- 7695

ISSN (P): 2349-8242

NAAS Rating: 5.03

TPI 2019; 8(1): 159-162

© 2019 TPI

www.thepharmajournal.com

Received: 29-11-2018

Accepted: 30-12-2018

S Soujanya

Assistant Professor, Department of Veterinary Pathology, College of Veterinary Science, Korutla, PV Narasimha Rao Telangana Veterinary University, PVNRTVU, Telangana, India

M Lakshman

Professor and Office in-Charge of Ruska labs, Department of Veterinary Pathology, College of Veterinary Science, Korutla, PV Narasimha Rao Telangana Veterinary University, PVNRTVU, Telangana, India

D Madhuri

Professor and University Head, Department of Veterinary Pathology, College of Veterinary Science, Korutla, PV Narasimha Rao Telangana Veterinary University, PVNRTVU, Telangana, India

Correspondence

S Soujanya

Assistant Professor, Department of Veterinary Pathology, College of Veterinary Science, Korutla, PV Narasimha Rao Telangana Veterinary University, PVNRTVU, Telangana, India

Occurrence of lymphoid leukosis in chicken

S Soujanya, M Lakshman and D Madhuri

Abstract

A survey was undertaken to study the occurrence of lymphoid leukosis in chicken in Rajendranagar, Hyderabad during December 2016 to July 2017. Lymphoid leukosis was diagnosed based on characteristic gross and histopathological changes in 36 poultry carcasses which were presented to postmortem examination to Department of Veterinary Pathology, College of Veterinary Science, Rajendranagar. Grossly, diffuse enlargement of liver, kidneys and spleen with multiple greyish-white foci were noticed. Whereas some birds showed multiple, variable sized soft, smooth, glistening, raised nodules on liver, kidney and heart. Cut surface of the nodule has creamy white appearance. Bursa was enlarged and showed nodular appearance. Ovaries were enlarged with soft whitish nodular masses having cauliflower like appearance. Proventriculus was enlarged and the mucosa was thickened. Microscopically, diffuse proliferation and infiltration with uniform neoplastic lymphoblast cells were noticed in various visceral organs.

Keywords: Lymphoid leukosis, chicken, tumours, lymphoblasts

Introduction

Avian leukosis is a group of diseases of chicken comprises of lymphoid, erythroid, myeloid leukoses, Other tumours such as fibroma, haemangioma, nephroblastoma and Osteopetrosis. Lymphoid leukosis is the commonest neoplasm in chicken caused by avian leukosis virus (ALV). It usually occurs between 14th to 30th week of age. Incidence is highest at about sexual maturity [1]. However avian leukosis outbreaks have also been reported in younger chickens [2, 3]. Transmission of ALV occurs both horizontally and vertically [4]. It is a lymphocytic lymphoma arising from malignant lymphocytes of bursal origin and later the malignant lymphocytes migrate and proliferate in other visceral organs to form tumors [5]. ALV are classified into five subgroups (A, B, C, D and J) based on their host range, viral envelope interference and cross-neutralization patterns. ALV subgroups A and B are more commonly associated with lymphoid leucosis [6]. Chicken are the natural host for ALV but lymphoid leukosis was also reported in ostriches [7], green peafowls [8] and in budgerigar [9]. Clinical signs in lymphoid leukosis are not specific. Pale, shrivelled and cyanotic comb may be seen. Other signs include anorexia, emaciation, weakness, diarrhoea and enlargement of abdomen. Enlargement of liver, bursa and kidneys can be detected by palpation [1]. In a nine year study of avian neoplastic diseases in Nigeria the lymphoid leukosis was contributed 14.10% of the total avian neoplastic disease outbreaks [10]. 5.88% of prevalence of lymphoid leukosis was earlier reported in a one year study in poultry population of Mizoram [11]. It is one of the avian neoplastic disease responsible for economic loss due to both mortality and depressed performance. So Present communication was designed to study the occurrence of lymphoid leukosis in naturally infected chicken of Rajendranagar, Hyderabad.

Materials and Methods

A total of 346 chicken carcasses of various age groups were presented to postmortem examination to Department of Veterinary Pathology, College of Veterinary Science, Rajendranagar over a period of seven months from December 2016 to July 2017. A detailed postmortem examination of all dead birds was performed and the gross lesions were carefully recorded. 36 birds were showed nodular tumor growths on various visceral organs. Representative tissue samples from liver, kidney, heart, spleen, bursa, ovaries and proventriculus showing lesions were collected in 10% neutral buffered formalin for histopathology. Formalin fixed tissues were washed under running tap water, dehydrated in ascending grades of alcohol, cleared in xylene and embedded in paraffin. Then 5µm thin sections were made and stained with Hematoxylin and Eosin (H&E) as per the standard

Procedure [12]. Then the slides were examined under microscope for histopathological examination.

3. Results and Discussion

In present study out of 346 poultry carcasses examined, 36 cases (10.4%) were diagnosed as lymphoid leukosis based on gross lesions and microscopic examination.

3.1 Gross lesions

On postmortem examination, the condition of most of the carcasses were poor and they showed severe emaciation and dehydration. It might be due to anorexia during the disease course. Grossly, in most cases liver was greatly enlarged, pale colored with multiple, variable sized, greyish-white foci on its surface and occupied the whole abdominal cavity (Fig 1). Whereas in some birds multiple, variable sized, greyish-white, soft, smooth, glistening, raised tumorous nodules were noticed on liver (Fig 2). Kidneys were enlarged, swollen, pale colored with distinct, whitish, soft tumorous nodular growths on its surface (Fig 3). Heart showed multiple, soft, white nodular masses without any gross enlargement (Fig 4). Cut surface of the nodule has creamy whitish areas of necrosis. Spleens were diffusely enlarged, they were almost double to the normal size of the spleen and minute haemorrhagic foci were noticed on the surface (Fig 5). In few birds bursa was enlarged and showed nodular appearance. Ovaries were enlarged with soft whitish nodular masses having cauliflower like appearance. Proventriculus was enlarged and the mucosa was slightly thickened which might be due to lymphoproliferations. Similar gross lesions were described by earlier workers [11, 13-16]. There was no enlargement of peripheral nerves and no tumorous growths on skin and feather follicles which was helpful in differentiating it from Marek's disease.

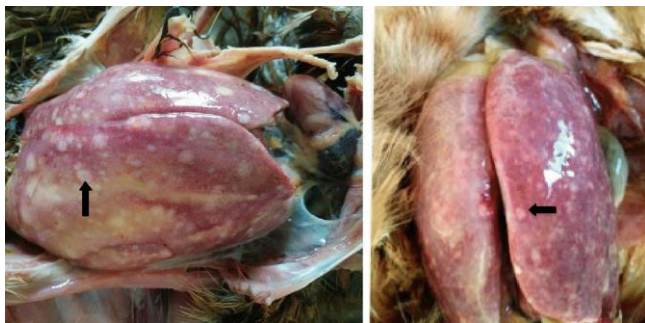

Fig 1: Enlargement of livers with multiple, variable sized, greyish-white foci (arrow) on its surface and it has occupied the whole abdominal cavity.

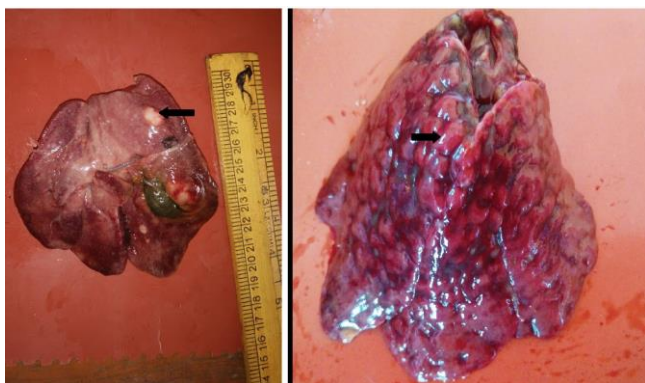

Fig 2: Livers with multiple, variable sized, soft, smooth, glistening, raised tumorous nodules (arrow).

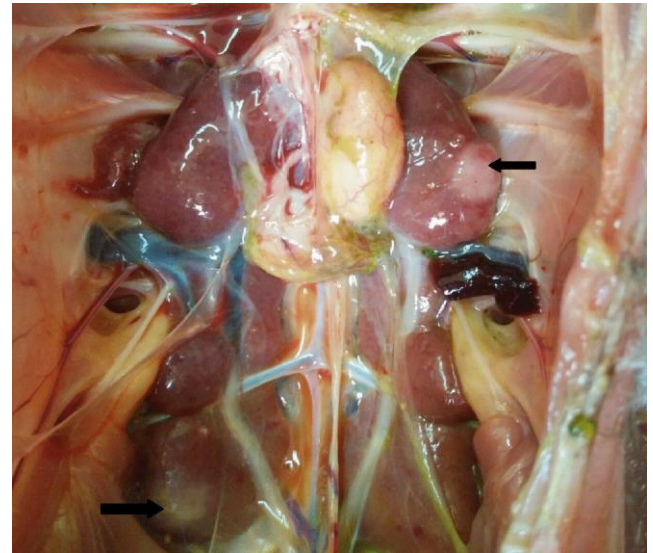


Fig 3: Enlarged kidneys with distinct, whitish, soft tumorous nodular growths (arrow).

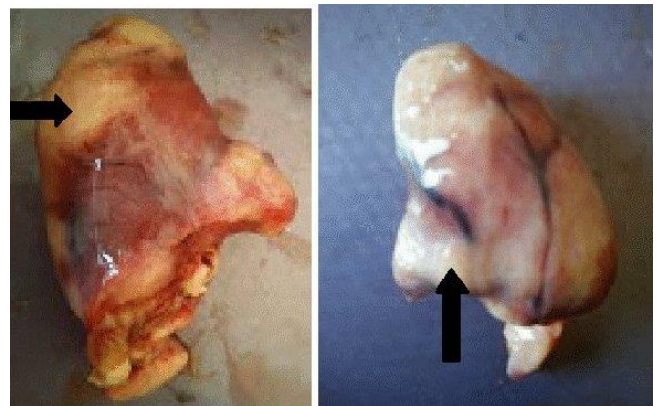

Fig 4: Hearts showing multiple, soft, white nodular masses without any gross enlargement (arrow).

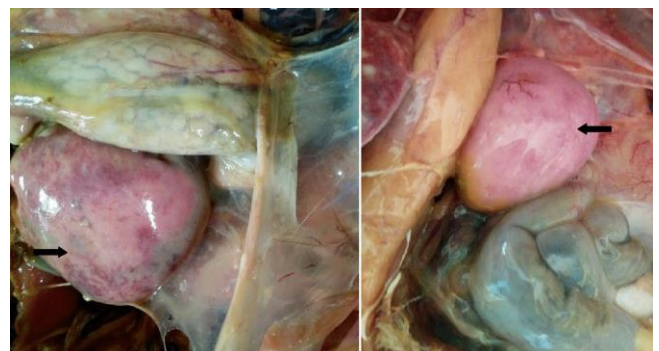


Fig 5: Diffusely enlarged spleens (arrow) with minute haemorrhagic foci on the surface.

3.2 Histopathological lesions

Liver: Microscopically the sections of liver revealed diffuse and focal aggregates of proliferating uniform sized immature lymphoid cells which displaced and compressed the hepatocytes. Fatty change with presence of clear vacuoles in the cytoplasm of hepatocytes was noticed (Fig 6). Few degenerated hepatocytes and areas of necrosis were observed. Some hepatocytes lost their normal architecture. Sinusoidal spaces were narrowed and infiltrated with lymphoblasts (Fig 7). Neoplastic cells having large, pleomorphic nuclei with prominent nucleoli. These findings were in agreement with the previous reports [2, 11, 13, 15, 17].

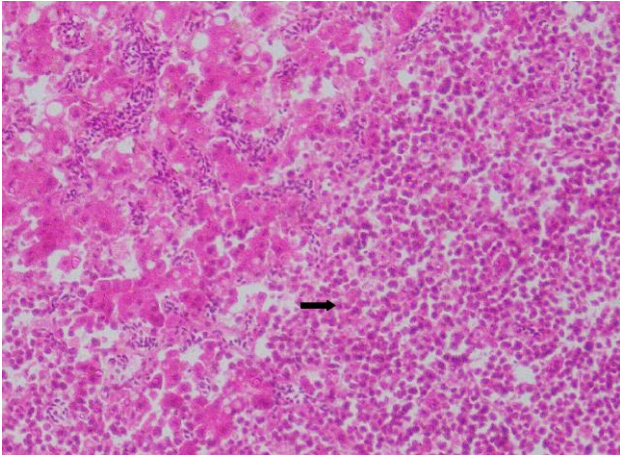


Fig 6: Liver section showing aggregates of proliferating uniform sized immature lymphoid cells (arrow) and fatty change with presence of clear vacuoles in the cytoplasm of hepatocytes. Haematoxylin & Eosin x20.

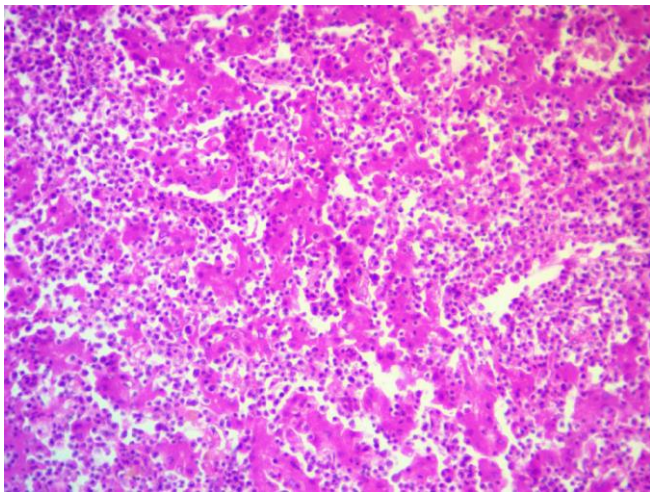


Fig 7: Liver section showing diffuse infiltration of proliferating immature lymphoid cells in sinusoidal spaces. Haematoxylin & Eosin x40

Kidney: Diffuse infiltration of uniform lymphoid cells was noticed in interstitial spaces in sections of kidney (Fig 8). Tubular epithelial cells were degenerated and glomeruli were shrunken. These findings supported the observations of earlier researchers [11, 13, 18].

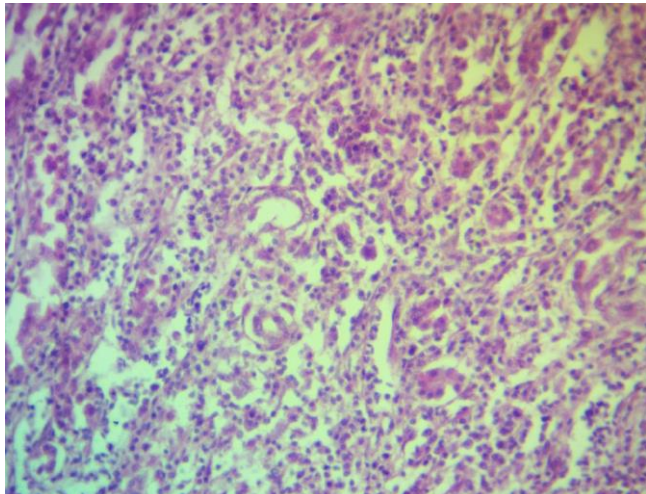


Fig 8: Kidney section showing diffuse infiltration of uniform lymphoid cells in interstitial spaces. Haematoxylin & Eosin x40

Heart: Sections of heart revealed diffuse infiltration of neoplastic lymphoid cells in between the myofibrils (Fig 9). Some of the myofibrils were showed degenerative changes and pressure atrophy due to proliferating lymphoblasts which were in congruence with previous reports [13].

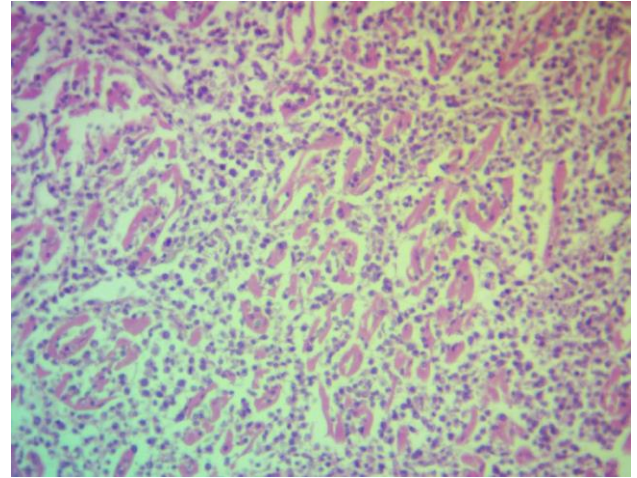


Fig 9: Section of heart showing infiltration of neoplastic lymphoid cells in between the myofibrils. Haematoxylin & Eosin x40

Spleen: Proliferating neoplastic lymphoid cells were found in spleen sections (Fig 10). Areas of congestion and haemorrhage was also noticed. Similar type of lesions were described in earlier reports [11, 13].

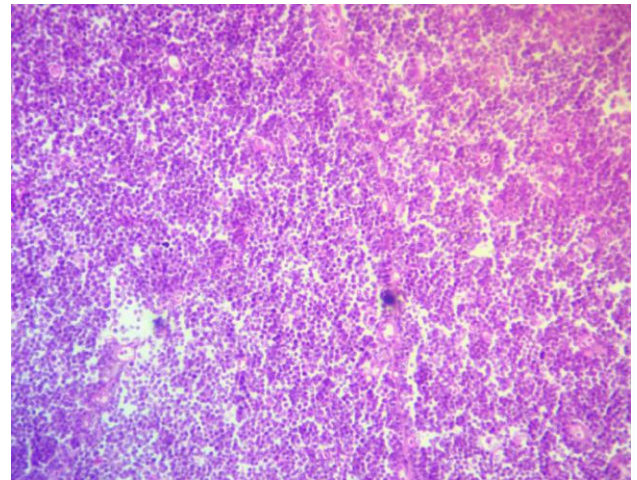


Fig 10: Spleen section showing proliferating neoplastic lymphoid cells. Haematoxylin & Eosin x40

Bursa, ovaries and proventriculus: Diffuse lymphoid infiltration was noticed in bursal follicles, in ovarian parenchyma and in the submucosa of proventriculus which were in agreed with the description of earlier workers [2, 11, 13].

Conclusion

ALV infection in chicken causes development of neoplasms in various organs also induces immunosuppression [19]. ALV can damage organs by viraemia and by the proliferation of neoplastic tissue. ALV infection often results in interference with many macrophage functions. Such birds are more prone to secondary infections which can further weaken the immune system [9]. So prevention and control of lymphoid leukosis is very important to avoid huge economical losses due to mortality and decreased performance of the birds.

In conclusion, the present study revealed 10.4% occurrence of

lymphoid leukosis in poultry population in and around Rajendranagar, Hyderabad despite of taking various control measures because the incidence of lymphoid leukosis was influenced by the genetic makeup of the flock, various other unrecognized factors ^[20] and it was diagnosed on the basis of gross lesions and characteristic microscopic changes of proliferating lymphoid cell aggregates in various visceral organs.

Acknowledgements

The authors are thankful to the PV Narasimha Rao Telangana Veterinary University (PVNRTVU), Rajendranagar, Hyderabad, Telangana for providing support and necessary facilities to carry out the work.

References

1. Vegad JL, Katiyar AK. A text book of veterinary Special pathology. Edn 1. International book distributing co., Lucknow, 2001, 96-97.
2. Balchandran C, Pazhanivel N, Vairamuthu S, Murali-Manohar B. Marek's disease and lymphoid leukosis in chicken- A histopathological survey. Tamilnadu Journal of Veterinary and Animal Science. 2009; 5(4):167-170.
3. Sani NA, Oladele SB, Raji MA, Ibrahim NDG. Seroprevalence of avian leukosis virus antigen using ELISA technique in commercial exotic-layer chickens in Zaria and its environs. African Journal of Microbiology Research. 2012; 6(21):4438-4442.
4. Payne LN, Venugopal K. Neoplastic diseases: Marek's disease, avian leukosis and reticuloendotheliosis. Review Science Technical, Office of International Epizootics. 2000; 19(2):544-564.
5. Purchase HG, Burmester BR. Leukosis/Sarcoma Group. In: Hofstad S, Calnek BW, Helmboldt CS, Reid WM, Yoder HW. Diseases of Poultry, Edn 6, Iowa State University Press, Ames, Iowa, 1972, 502-568.
6. Payne LN, Fadly AM. Leukosis/sarcoma Group. In: Calnek BW, Barnees HJ, Beard CW, McDougald CR, Saif YX. Diseases of Poultry, Edn 11, Iowa State University Press, Ames, Iowa, 2003, 465-519.
7. Garcia-Fernandez RA, Perez-Martinez C, Espinosa-Alvarez J, Escudero-Diez A, Garcia-Marin JF, Nunez A *et al.* Lymphoid leukosis in an ostrich (*Struthio camelus*). Veterinary Record. 2000; 146:676-677.
8. Khordadmehr M, Firouzamandi M, Zehtab-Najafi M, Shahbazi R. Naturally occurring co-infection of avian leukosis virus (Subgroups A-E) and reticuloendotheliosis virus in green peafowls (*Pavo muticus*). Brazilian Journal of Poultry Science. 2017; 19(4):609-614.
9. Nouri M, Gharagozlou MJ, Azarabad H. Lymphoid leucosis and coligranoloma in a budgerigar (*Melopsittacus undulatus*). International Journal of Veterinary Research. 2011; 5(1):5-8.
10. Sani NA, Aliyu HB, Musa IW, Wakawa AM, Abalaka SE, Oladele SB *et al.* A nine - year retrospective study of avian neoplastic diseases in Zaria, Kaduna state, Nigeria. Sokoto Journal of Veterinary Sciences. 2017; 15(1):36-41.
11. Bhutia LD, Damodar Singh Y. Occurrence of lymphoid leukosis in poultry population of Mizoram. Indian Journal of Veterinary Pathology. 2017; 41(3):228-231.
12. Luna GLHT. Manual of histological and special staining techniques. Edn 2, the Blakistone Divison McGraw-Hill Book Company, New York, Toronto London. 1968; 1-5:9-34.
13. Sneha S, Debiprasanna D, Panda SK, Supriya D, Basanti J, Rajesh Kumar S. Avian leukosis in chickens: A Clinico-pathological survey. Journal of Entomology and Zoology Studies. 2017; 5(6):1697-1701.
14. Mathew C, Matondo R, Malago JJ, Maselle RM, Mwamengele GL. Lymphoid leukosis in commercial layers in Morogoro. Tanzania Veterinary Journal. 2010; 27:14-20.
15. Gopal S, Manoharan P, Kathaperumal K, Balachandran C, Kurunchi CD. Differential detection of avian oncogenic viruses in poultry layer farms and turkeys by use of multiplex PCR. Journal of Clinical Microbiology. 2012; 50(8):2668-2673.
16. Latif MM, Khalafalla AI. Detection by PCR of multiple subgroups of Avian Leucosis Virus (ALV) in broilers in the Sudan. Journal of Animal and Veterinary Advances. 2005; 4(3):407-413.
17. Ravikumar R, Saravanajayam M, Madheswaran R, Tamilmam TV. Occurrence of avian leucosis complex in commercial layer chicken raised in cages. Indian Veterinary Journal. 2016; 93(6):79-80.
18. Huang JQ, Xin JK, Mao C, Zhong F, Chai JQ. Co-infection of avian leukosis virus and *Salmonella pullorum* with the preliminary eradication in breeders of Chinese local Shouguang chickens. Pakistan Veterinary Journal. 2013; 33:428-432.
19. Luticken D. Viral disease of the immune system and strategies to control infectious bursal disease by vaccination. Acta Veterinaria Hungarica. 1997; 45:239-249.
20. Crittenden LB. The epidemiology of avian lymphoid leukosis. Cancer Research. 1976; 36:570-573.