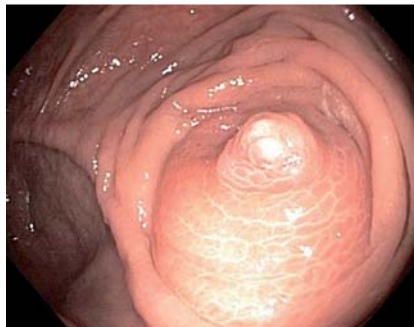

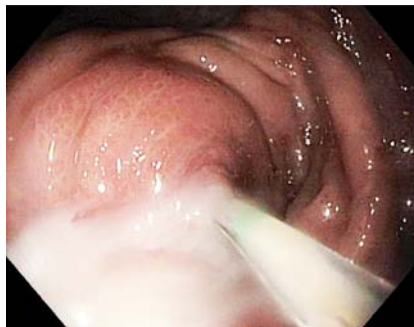## Pericecal abscess treated by endoscopic transappendiceal stenting

A 63-year-old woman presented with abdominal pain without fever or diarrhea. Laboratory data were notable for elevated C-reactive protein of 12.8 mg/dL (normal <1.0 mg/dL). A colonoscopy carried out on the day after admission showed that the appendiceal orifice was inflamed and protruding (● Fig. 1). A computed tomography (CT) scan taken after colonoscopy demonstrated a 5 × 3 cm pericecal abscess. The consulted surgeon recommended drainage and antibiotic therapy. Since the patient's colon was still clean we decided to do endoscopic transluminal drainage as described previously [1–3], although we intended to carry out transappendiceal stenting for long-term drainage, a procedure which has not been reported to date. A second colonoscopy was performed the same day. We intubated the appendix easily, using a guide wire sphincterotome, and plenty of pus discharged from the appendiceal orifice (● Fig. 2). The abscess was visualized on fluoroscopy, using a contrast medium (● Fig. 3). A double pigtail catheter, 4 cm in length and 7Fr in diameter, was placed into the abscess cavity (● Fig. 4). The patient was free of pain immediately after drainage and CRP levels returned to normal within a few days. Ultrasonographic follow-up demonstrated rapid resolution of the abscess. An abdominal X-ray taken 3 weeks later showed that the pigtail catheter was no longer in place but had passed spontaneously. The consulted surgeon did not carry out interval appendectomy since no further episodes of appendicitis were expected to occur because of the likely obliteration of the appendiceal lumen [4]. After 6 months follow-up the patient is well without any recurrence or clinical signs of appendicitis. Percutaneous drainage in conjunction with antibiotic therapy is the treatment of choice in patients with pericecal abscesses. In this report we have demonstrated that endoscopic transappendiceal drainage and stenting may be an alternative method of management in selected patients. Routine interval appendectomy after successful nonoperative treatment is not generally recommended [4].

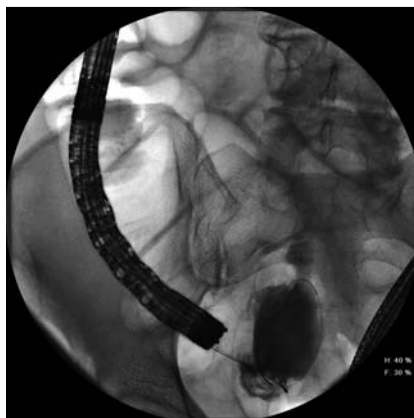
Endoscopy\_UCTN\_Code\_TTT\_1AQ\_2AJ



**Fig. 1** Colonoscopic view in a 63-year-old woman with abdominal pain but no fever or diarrhea showing the elevated, inflamed appendiceal orifice.



**Fig. 2** Profuse discharge of pus from the appendiceal orifice.

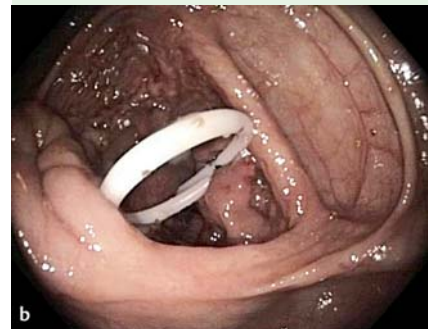
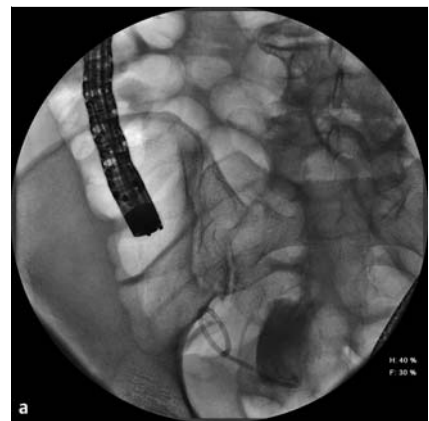
**Fig. 3** Fluoroscopic view of the pericecal abscess with guide wire in place.

**Competing interests:** None

**C. Kapral, F. Wewalka,  
A. Ziachehabi, R. Schoefl**

Department of Gastroenterology,  
Elisabethinen Hospital, Linz, Austria



**Fig. 4 a, b** A 4-cm long, 7-Fr double pigtail catheter placed in the abscess cavity.

### References

- 1 Said M, Ledochowski M, Dietze O et al. Colonoscopic diagnosis and treatment of acute appendicitis. *Eur J Gastroenterol Hepatol* 1995; 7 (Suppl. 06): 569–571
- 2 Ohtaka M, Asakawa A, Kashiwagi A et al. Pericecal appendiceal abscess with drainage during colonoscopy. *Gastrointest Endosc* 1999; 49 (Suppl. 01): 107–109
- 3 Liu CH, Tsai FC, Hsu SJ et al. Successful colonoscopic drainage of appendiceal pus in acute appendicitis. *Gastrointest Endosc* 2006; 64 (Suppl. 06): 1011
- 4 Kaminski A, Liu IL, Applebaum H et al. Routine interval appendectomy is not justified after initial nonoperative treatment of acute appendicitis. *Arch Surg* 2005; 140 (Suppl. 09): 897

### Bibliography

**DOI** <http://dx.doi.org/10.1055/s-0032-1309717>  
Endoscopy 2012; 44: E310  
© Georg Thieme Verlag KG  
Stuttgart · New York  
ISSN 0013-726X

### Corresponding author

**C. Kapral**  
Department of Gastroenterology  
Elisabethinen Hospital  
Fadingerstrasse 1  
A-4020 Linz, Austria  
[christine.kapral@elisabethinen.or.at](mailto:christine.kapral@elisabethinen.or.at)