



Imaging of Ampullary and Periapillary Conditions

Abhijit Sunnapwar¹ Arpit Nagar² Rashmi Katre¹ Lokesh Khanna¹ Hari Prasad Sayana³

¹Department of Radiology, University of Texas Health San Antonio, San Antonio, Texas, United States

²Department of Radiology, Ohio State University Wexner Medical Center, Columbus, Ohio, United States

³Department of Gastroenterology, University of Texas Health San Antonio, San Antonio, Texas, United States

Address for correspondence Abhijit Sunnapwar, MD, Department of Radiology, University of Texas Health San Antonio, 7703, Floyd Curl Drive, San Antonio, TX 78229, United States (e-mail: sunnapwar@uthsca.edu).

J Gastrointestinal Abdominal Radiol ISGAR 2021;4:214–228.

Abstract

The ampulla of Vater is formed by the union of the pancreatic duct and the common bile duct and is also known as hepatopancreatic ampulla or hepatopancreatic duct. The ampulla is surrounded by a muscular valve known as the sphincter of Oddi, which controls the flow of bile and pancreatic juices into the duodenum in response to food. The ampulla is also an important embryological landmark as it marks the anatomical transition from foregut to the midgut. Because of this, it is a watershed zone where the blood supply changes from the celiac axis to the superior mesenteric artery. Radiologic evaluation of the ampulla and the periampullary region is challenging because it requires an understanding of the embryology, the normal appearance, and different anatomic variants. Also, a wide variety of pathologies can occur in this region. The purpose of this review is to present the normal anatomy of the ampulla and the periampullary region on different imaging modalities and to summarize the imaging features of the common variants, and benign and malignant ampullary and periampullary conditions. Understanding of the normal anatomical appearance and variants along with the knowledge of common pathologic conditions affecting the ampulla and periampullary conditions can help radiologists in making accurate diagnosis resulting in optimum patient care.

Keywords

- ▶ ampullary
- ▶ biliopancreatic junction
- ▶ neoplasms
- ▶ periampullary

Introduction

The ampulla of Vater, also known as the hepato- or biliopancreatic ampulla, was first described by Vesalius and is named after a German physician: Abraham Vater. It is the dilated junction of the common bile duct (CBD) and the main pancreatic duct of Wirsung (MPD) that becomes a common channel before opening into the duodenum at the major papilla. Although meaning of ampulla is dilated common channel, it is rarely dilated, and this name is disputed by some investigators.¹

The ampulla of Vater is surrounded by a group of smooth muscles that forms the sphincter of Oddi which controls the flow of bile and pancreatic juices into the duodenum. These smooth muscles also extend to encircle the distal CBD, and the distal MPD. The major duodenal papilla is located along the medial wall of the second portion of the duodenum.²

Given the importance of these anatomic structures, it is essential for radiologists to understand the basic embryology, normal anatomy, and common variants of ampulla and periampullary region. Familiarity with the different pathologic

published online
May 5, 2021

DOI <https://doi.org/10.1055/s-0041-1726663>
ISSN 2581-9933

© 2021. Indian Society of Gastrointestinal and Abdominal Radiology
This is an open access article published by Thieme under the terms of the Creative Commons Attribution-NonDerivative-NonCommercial-License, permitting copying and reproduction so long as the original work is given appropriate credit. Contents may not be used for commercial purposes, or adapted, remixed, transformed or built upon. (<https://creativecommons.org/licenses/by-nc-nd/4.0/>).
Thieme Medical and Scientific Publishers Pvt. Ltd. A-12, 2nd Floor, Sector 2, Noida-201301 UP, India

conditions involving this region will improve the diagnostic accuracy of radiologists facing ampullary abnormalities.

Embryology

Development of the pancreas is like that of other exocrine glands in a way that the duct appears first and then cells implant around it to create lobules. The endocrine and exocrine parts of pancreas arise from the endodermal epithelium of the duodenum. As early as second and third gestational week, the ventral and dorsal ducts grow from the duodenum.³ The dorsal bud is larger and located higher than the ventral buds and forms the superior part of the head, the body, and the tail of the pancreas. Due to the rotation of the stomach and the duodenum during embryogenesis, the ventral bud moves to the dorsal direction. At the end of the rotation, the ventral bud is located under and behind the dorsal bud and forms the inferior part of the head, and the uncinate process of the pancreas.⁴ Each bud has its own independent duct and during the 7th week of gestation, the two buds fuse.⁵ Portion of the dorsal duct in the duodenal segment atrophies, while the rest of the duct, along with the duct of the ventral bud, forms the pancreatic duct. It joins the CBD to form the ampulla and drains into the duodenum via the major duodenal papilla (► Fig. 1). If the duodenal segment of the dorsal bud duct stays patent, it is called the accessory pancreatic duct that drains in the duodenum through the minor duodenal papilla.³ If the two buds fail to fuse, it results in pancreas divisum. The close proximity of the pancreatic bud to the stomach and duodenum can explain the heterotopic pancreatic tissue in the gastrointestinal tract. Heterotopic pancreas in the pancreaticoduodenal groove and duodenal wall can result in groove pancreatitis. Annular pancreas is a rare congenital anomaly resulting from incomplete rotation of the ventral duct, in which the pancreas forms a ring around the duodenum, which may result in duodenal atresia in neonates or duodenal obstruction or pancreatitis in adults.⁶

Normal Anatomy

The ampulla is seen along the medial wall of the duodenum with its length ranging from 1 to 12 mm (average length of 4.4 mm), and a diameter of 1 to 4 mm (2.6 mm on average).⁷ It is situated in the lower part of the pancreatic head. It protrudes in the medial aspect of the second portion of the duodenum for a length of 5 to 10 mm to form the major papilla.⁸ Major papilla can also be seen at the junction of the second portion and third portion of the duodenum.^{7,9} The ampullary region indicates the distal segments of the CBD and MPD that may or may not include a common channel (► Fig. 1). The periampullary region includes the duodenum for a length of 2 cm, the ampulla of Vater, and the distal most CBD.²

The CBD and the MPD may join each other in one of the three different ways:¹⁰

1. A common channel is formed by joining of the CBD and MPD measuring 1 to 8 mm in length (60%).
2. Absent common channel but single opening at the papilla with separate opening of CBD and MPD (38%).
3. In the least common type, there are separate openings in the papilla draining the CBD and MPD independently (2%).

The minor duodenal papilla is the orifice of the accessory pancreatic duct that is situated ~2 cm proximal to the major duodenal papilla. It contains terminal portion of the accessory pancreatic duct surrounded by pancreatic tissue.¹¹

The ampulla of Vater is usually seen on computed tomography (CT) or magnetic resonance imaging (MRI), but physiologic contraction of the sphincter of Oddi can result in non-visualization.⁸ On CT the ampulla is seen as a hypodense structure which shows enhancement after intravenous contrast similar to the duodenal mucosa even on multiphase exam. The normal duodenal papilla is usually less than 10 mm in diameter and the thickness of the wall of the ampullary part is less than 2 mm.⁸ The common channel can be a long (Y shaped) or short type (V-shaped) on magnetic resonance cholangiopancreatography (MRCP).¹² On T2-weighted imaging, the major papilla and sphincter complex appears as a round, slightly hypointense structure along the medial wall of the duodenum¹² (► Fig. 1). Similar to CT, the enhancement of the mucosa in the papilla and ampullary portion on dynamic imaging is isoenhancing to that of the surrounding duodenal mucosa. According to an article published by Sun et al target sign was seen in up to 70% of cases.¹⁰ The “target sign” was defined as the appearance produced by an enhancing mucosa with underlying hypodense ampulla/sphincter complex) of a normal papilla. Morphology of the papilla could be round, hemispherical, conical, or flat¹⁰ (► Fig. 1).

Role of Imaging

Conventional imaging including plain abdominal radiographs has low sensitivity in detecting biliary and pancreatic abnormalities. Incidental findings including pneumobilia, calcified stone, or pancreatic calcifications may be seen in patients presenting with abdominal pain.^{13,14} Fluoroscopy may show duodenal obstruction due to annular pancreas or mass lesion around ampulla.¹⁵ Many of the ampullary and periampullary abnormalities, including congenital anomalies and anatomical variants, are first detected on imaging, including CT and or MRI, as incidental findings in patients being investigated for various clinical problems. Patients with acquired benign or neoplastic lesions often present with abdominal pain, obstructive jaundice, and weight loss in case of malignancy. Ultrasound (US) is often the first modality used to screen patients with upper abdominal pain and jaundice. It is cost-effective, easily available, and lacks

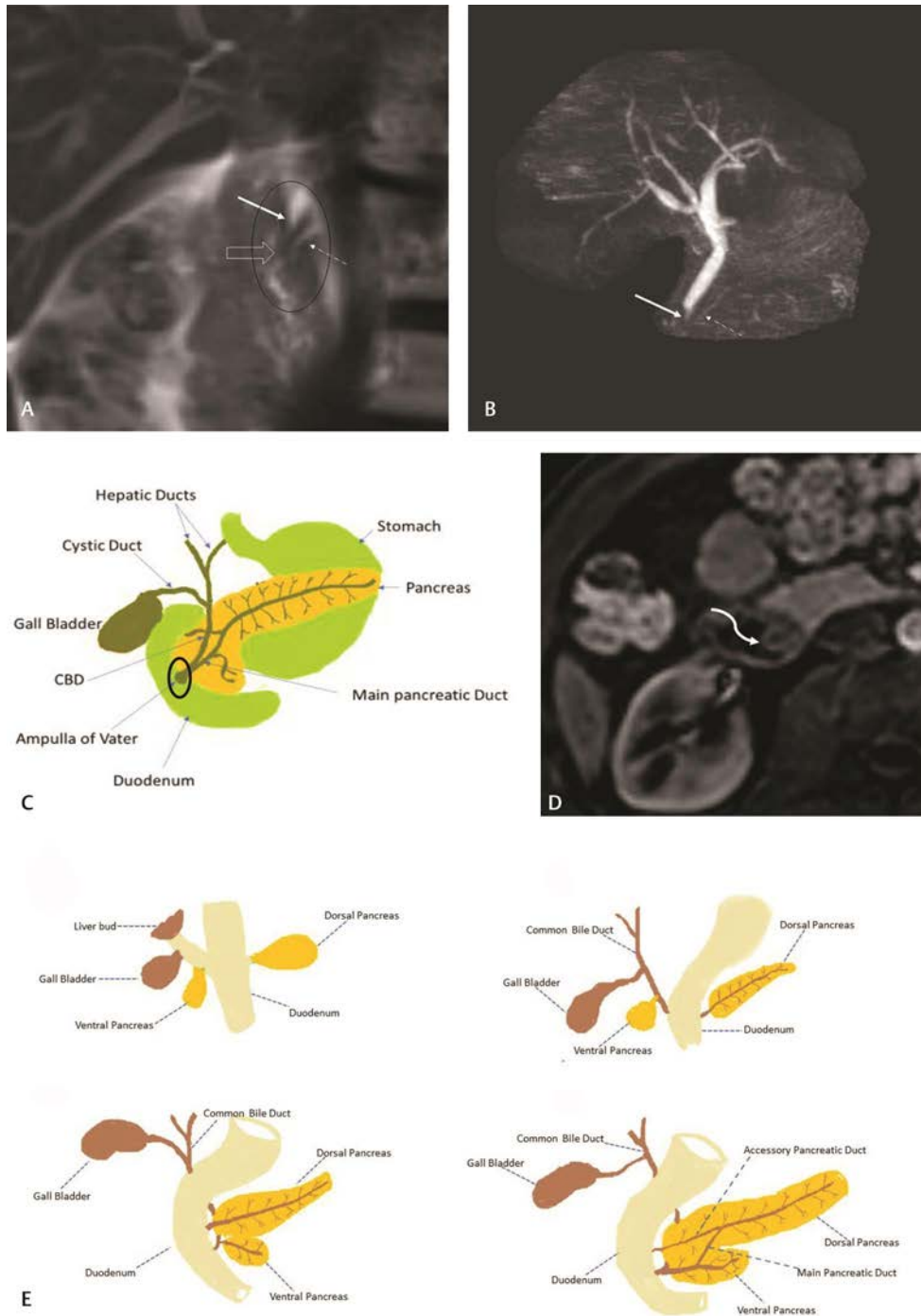


Fig. 1 Normal anatomy of the ampulla is demonstrated on coronal T2-weighted image (A), three-dimensional magnetic resonance cholangiopancreatography image (B), and an illustration (C). Distal common bile duct (solid arrow) joins the pancreatic duct (interrupted arrow) to form the ampulla. Major papilla is seen (open arrow) as a T2 hypointense structure (A) and periampullary region is shown in A and C outlined by an elliptical. Target sign is demonstrated in post-contrast arterial phase axial image D (curvilinear arrow). Embryology of the pancreas is depicted in image E. Image courtesy: Dr. Lokesh Khanna

ionizing radiation.¹⁶ On grayscale US, a hypoechoic mass may be seen in periampullary region, along with intra and extra-hepatic biliary and pancreatic ductal dilation.¹⁷ Color doppler is useful in assessing vascular involvement in malignant neoplasms.¹⁸ Metastatic nodes can be detected in peripancreatic and celiac axis and porta hepatis. It is somewhat limited in evaluating distal CBD and pancreatic duct near the ampulla and in differentiating benign from malignant lesions.¹⁹ Its sensitivity to detect liver metastases from ampullary and

periampullary neoplasms has improved with the introduction of contrast enhanced US.²⁰ US is limited in patients with large body habitus and those with lot of bowel gas. CT is the commonly used modality in patients presenting with upper abdominal pain including obstructive biliary symptoms. Use of multidetector technology has improved spatial resolution due to ability to obtain thinner sections and faster acquisitions reducing motion artifacts to a minimum.²¹ Multiplanar reformats are helpful in detecting tumors and evaluating

biliary and pancreatic ducts in different planes.²² Use of iodinated contrast has improved visualization of small ampullary and periampullary neoplasms. It is particularly helpful in staging the disease, detecting perilesional spread, lymph node metastases and distant spread, most commonly to liver. Multiphase CT helps in evaluating relation of tumor to arteries and veins that are essential for planning the treatment.²³ Patients receiving neoadjuvant chemotherapy need CT for restaging. One important limitation is radiation exposure, which is of particular concern in younger patients needing multiple follow-up exams. MRI with its superior soft tissue resolution helps in detecting small tumors, which is improved by multiparametric imaging including diffusion weighted and apparent diffusion coefficient map sequences along with dynamic contrast enhanced imaging.²⁴ MRCP provides a high-resolution image of ductal system comparable to endoscopic retrograde cholangiopancreatography (ERCP), in two-dimensional and three-dimensional.²⁵ MR limited due to longer acquisition time may cause patient discomfort and may not be performed in some patients including those with claustrophobia, metal pieces in sensitive location in body, pacemaker, or spinal nerve stimulators. Some of the major limitations due to patient motion and respiration are being addressed with introduction of short breath hold acquisitions, use of parallel imaging, and special respiratory trigger mechanisms.²⁶ ERCP has been a bedrock for evaluating biliary and pancreatic ductal abnormalities for a long time, helping in detailed assessment of the anatomy of pancreato-biliary ductal system, detecting any normal variants. It is particularly sensitive in detecting any mural lesions including strictures and intraluminal masses seen as filling defects.^{27,28} Various therapeutic interventions including sphincterotomy, balloon angioplasty, stenting, or stone extraction may be performed at the same time.¹⁹ It is limited by being invasive, along with a risk for post procedure pancreatitis. Endoscopic US (EUS) plays an important role in diagnosing ampullary and periampullary abnormalities, especially neoplasms.²⁹ It provides a detailed evaluation of anatomy in that region due to close approximation of probe to the concerned structures. It has

added advantage of obtaining tissue sample at the time of US.³⁰ Contrast-enhanced EUS greatly improves the accuracy, helping to differentiate malignant lesions that are usually hypovascular and help in detecting mural nodules in cystic lesions.³¹ It is limited due to being invasive in nature.

Benign Conditions Affecting Ampulla and Periapillary Region

Periapillary Duodenal Diverticulum

Duodenal diverticula are diverticula representing extraluminal mucosal outpouchings devoid of muscle layer. Most (up to 75%) are located in the second part of the duodenum along the medial wall, adjacent to the ampulla of Vater. When the diverticulum is within 2 to 3 cm from the ampulla of Vater, it is called periampullary diverticulum. Diverticulum containing the papilla (intradiverticular papilla) is also named as ampullary diverticula, whereas diverticulum not containing the papilla is often referred as juxta-papillary or juxta-ampullary duodenal diverticulum. The incidence increases with age and the reported incidence is highly variable, depending on the imaging type and the population, and ranges from 1 to 30%.^{32,33}

The majority of periampullary diverticula are incidentally found and are asymptomatic, but occasionally can cause complications. Nonbiliopancreatic complications include diverticulitis, hemorrhage, perforation or fistula formation. Biliopancreatic complications include bile duct stone formation, biliary obstruction, cholangitis, and pancreatitis.³⁴⁻³⁶ Obstructive jaundice from a periampullary duodenal diverticulum is also known as Lemmel's syndrome.³⁷ On fluoroscopic exam after barium ingestion, duodenal diverticulum can be seen as an outpouching from the medial wall of the second portion of the duodenum. CT and MRI may show fluid-filled diverticulum along the medial duodenal wall. Sometimes an air-fluid level is seen at the papillary junction that is easier to detect on CT (→ Fig. 2) and may appear as susceptibility artifact on MRI. Multiplanar reconstructions and oral contrast can improve the diagnostic yield of CT.³² At times, a small fluid filled

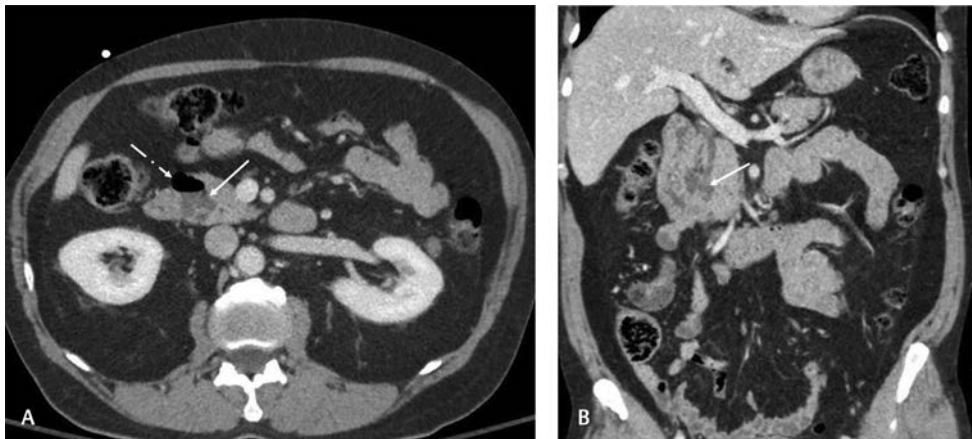


Fig. 2 Periapillary duodenal diverticulum is seen on axial (A) and coronal (B) contrast enhanced computed tomography as a fluid filled periampullary structure (solid arrow). Air within the diverticulum (interrupted arrow in A) helps in making accurate diagnosis.

diverticulum can be difficult to differentiate from an ampullary mass or cyst on imaging.

Intraluminal Duodenal Diverticulum

An intraluminal duodenal diverticulum results from incomplete recanalization of the embryologic foregut. There is a fenestrated membrane within the lumen of the duodenum and with years of peristalsis affecting the membrane results in the formation of an intraluminal diverticulum. Although most patients are asymptomatic, a few may experience abdominal pain, bloating, or fullness. Rarely it can lead to more severe complications such as gastrointestinal bleeding, and bowel obstruction.³⁸

Endoscopy of the duodenum shows two lumens: one is the opening of the diverticulum, and the other is the duodenal lumen. Imaging diagnosis can be made with barium fluoroscopic study with classic appearance of contrast filling of the diverticulum surrounded by radiolucent area that represents the diaphragm which itself is surrounded by contrast filling the duodenal lumen. This appearance is described as “windsock” or “finger-of-glove.”³⁸ CT usually shows a low-density mass within the lumen of the duodenum representing the collapsed diverticulum (► Fig. 3). Oral/intraluminal contrast can help in making accurate diagnosis if there is opacification of the lumen of the diverticulum.³⁹ Differential diagnosis includes periampullary neoplasm, intussusception, choledochal cyst, and duodenal duplication cyst. Duodenal duplication cysts are commonly extraluminal, located posteromedial to the second portion of the duodenum.⁴⁰

Ampullary Stenosis

Ampullary stenosis can be defined as the dilation of the CBD and the MPD with laboratory evidence of biliary obstruction in the absence of a mass or inflammatory lesion at the ampulla. It can also present with clinical symptoms, such as recurrent abdominal pain, pancreatitis, and jaundice.^{1,12,41} Dilated CBD and MPD can be easily depicted on CT and MRI; however, it is important to rule out underlying mass and most patients will need ERCP and EUS or imaging follow-up. Causes of ampullary stenosis can be sphincter of Oddi dysfunction (SOD), pancreaticobiliary maljunction, and iatrogenic stenosis.

Sphincter of Oddi Dysfunction

The most common cause of ampullary stenosis is SOD. Prevalence of SOD has been reported to be up to 15% in the general population.³² Gold standard for diagnosis of SOD is manometric demonstration of sphincter pressures >40 mm Hg during ERCP. Endoscopic manometry is, however, an invasive procedure. MRCP demonstrates dilated MPD and CBD with smooth tapering to the ampulla without calculus or mass lesion (► Fig. 4). Secretin-enhanced MRCP can be of added value by demonstrating increase in MPD diameter of more than 1 mm or prolonged dilatation (>3 mm at 10 minute) in patients with clinically suspected SOD.⁴²

Abnormal Biliopancreatic Junction

Abnormal biliopancreatic junction (ABPJ), also known as pancreaticobiliary maljunction, is a rare developmental anomaly in which the pancreatic and bile ducts join outside the duodenal wall, usually forming a long common channel. This anomaly can occur in isolation or in conjunction with other anomalies such as pancreas divisum and annular pancreas.⁴³ Radiologists should be aware of this entity to ensure early diagnosis as ABPJ can be associated with increased risk of biliary cancer and need close imaging follow-up.⁴⁴ In these patients, sphincter of Oddi does not regulate the flow that can lead to reciprocal reflux between the pancreatic duct and the CBD. This can cause bile stasis and pancreatitis. Chronic biliary stasis can be the etiology of biliary cancer. ABPJ can be associated with type I or type IV choledochal cysts.⁴⁵

Morphologically, ABPJ is divided into two broad categories depending upon presence or absence of CBD dilation. To make a diagnosis of ABPJ, one of the following is needed: an abnormally long common channel or an abnormal union between the pancreatic and bile ducts or a PBJ outside the duodenal wall^{46,47} (► Fig. 5). There is no consensus on the length of the common channel; however, in the literature, 8 mm to 15 mm length of the common channel has been reported.⁴⁸

Various imaging techniques such as MRCP, US, ERCP, or percutaneous or intraoperative cholangiogram can be used for the diagnosis ABPJ as well as its complications. MRCP is superior to ERCP in depicting the biliary anatomy⁴⁹ (► Fig. 5). Additionally, secretin enhanced MRCP images can be helpful

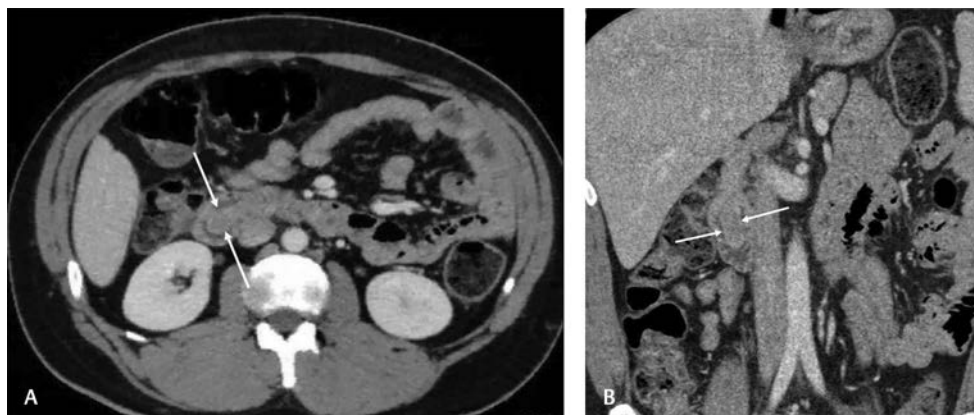

Fig. 3 Intraluminal duodenal diverticulum is demonstrated on contrast-enhanced axial (A) and coronal (B) computed tomography images as a smooth low-density mass within the lumen of duodenum (arrows).

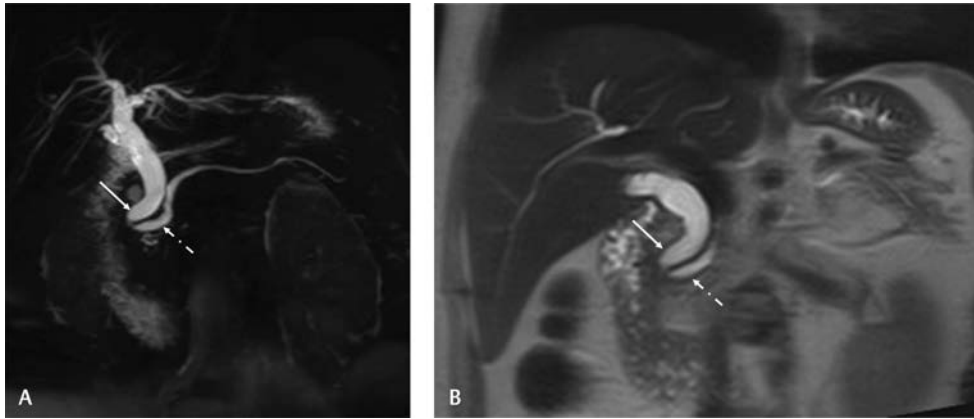


Fig. 4 Three-dimensional magnetic resonance cholangiopancreatography image (A) and T2-weighted coronal image demonstrating dilated common bile duct (solid arrow) and pancreatic duct (interrupted arrow) with smooth tapering toward the ampulla. Endoscopic evaluation with manometry showed elevated pressure at the ampulla without mass lesion that confirmed the diagnosis of sphincter of Oddi dysfunction.

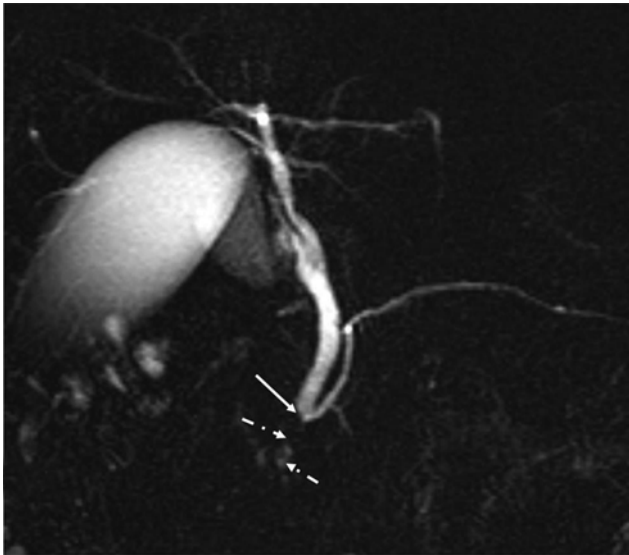


Fig. 5 Magnetic resonance cholangiopancreatography image demonstrating biliary pancreatic junction (solid arrow) outside the duodenal wall with abnormally long common channel (interrupted arrows).

in functional analysis. Gadoxetic acid, a hepatobiliary-specific MRI contrast agent, is excreted into the bile ducts and can be used to demonstrate biliopancreatic reflux in patients with ABPJ.⁵⁰ ERCP can help confirm the lack of effect of the sphincter of Oddi on the ABPJ even in patients with a relatively short common channel.⁵¹ Important advantages of ERCP are that it allows bile and tissue sampling as well as biliary intervention. An elevated amylase level in bile suggests reflux of pancreatic juice through an ABPJ.⁴⁷

Iatrogenic Ampullary Stenosis

Morphologically iatrogenic stenosis can be divided in two subtypes: type I, is when the stenosis only involves the intraduodenal part of the sphincter complex, and type II, when the stenosis extends to involve the CBD. Clinical presentation of biliary obstruction in the presence of history of prior endoscopic or biliary surgery, and the presence of a biliary dilation in absence of a mass at MRI or CT, without the

evidence of an ampullary mass is concerning for iatrogenic stenosis⁴¹ (► **Fig. 6**). Imaging is important to rule out the presence of a mass lesion.⁵² Finding that is useful on CT is the size of the papilla: diameter of the papilla more than 12.3 mm is concerning for malignancy.⁵³ MR findings of an ampullary mass, papillary bulging, and irregular CBD stricture are associated with cancer.³²

Ductal Anomalies

Ductal anomalies include pancreas divisum, ABPJ (previously discussed), choledochoceles, and annular pancreas.

Pancreas Divisum

Pancreas divisum is the result when the ventral and dorsal pancreatic ducts fail to fuse.⁵⁴ The ventral duct (duct of Wirsung) drains only the ventral pancreatic tissue into the major papilla, whereas the majority of the gland empties into the minor papilla through the dorsal duct (duct of Santorini). There is abnormal proportion of the duct size and draining enzymes, dorsal duct being smaller in caliber and draining most of the pancreatic tissue. This may sometimes give rise to santorinicele that is a focal dilatation of the terminal portion of the dorsal pancreatic duct secondary to the relative obstruction at the minor papilla⁵⁵ (► **Fig. 7**). Pancreas divisum is usually asymptomatic but can be associated with patients with chronic abdominal pain and idiopathic pancreatitis.⁵⁶ The diagnosis of pancreas divisum can be made with MRCP, multidetector computed tomography, and ERCP. Endoscopic retrograde pancreatography shows ventral duct opacification when standard cannulation of the major papilla is performed. MRCP, on the other hand, demonstrates noncommunicating dorsal and ventral ducts, independent drainage sites, and a dominant dorsal pancreatic duct.⁴⁹ The ventral duct is typically short and narrow.

Annular Pancreas

Annular pancreas is a rare congenital anomaly in which incomplete rotation of the ventral anlage leads to a segment of the pancreas encircling the second part of the duodenum.⁵⁷ Annular pancreas has different presentation in

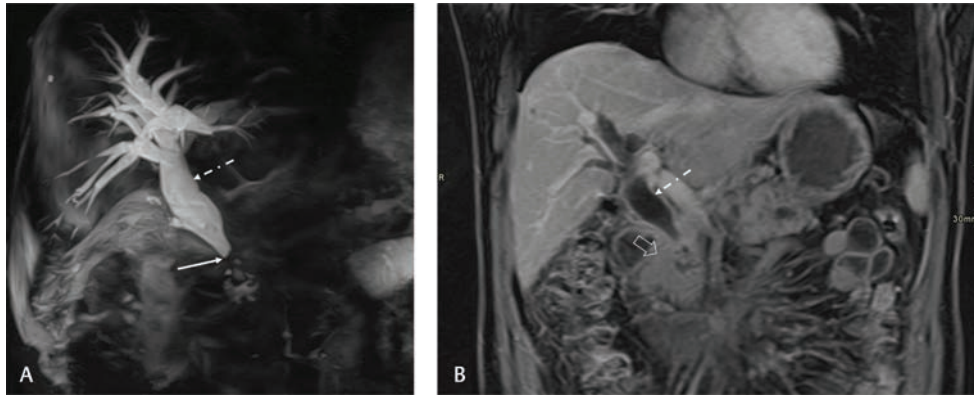


Fig. 6 Severe ampullary stricture is demonstrated on three-dimensional magnetic resonance cholangiopancreatography (A) and postcontrast coronal magnetic resonance images (B) with severe biliary dilation (interrupted arrow) with smooth distal tapering (solid arrow in A) with uniform enhancement of the ampulla without mass lesion (open arrow in B).

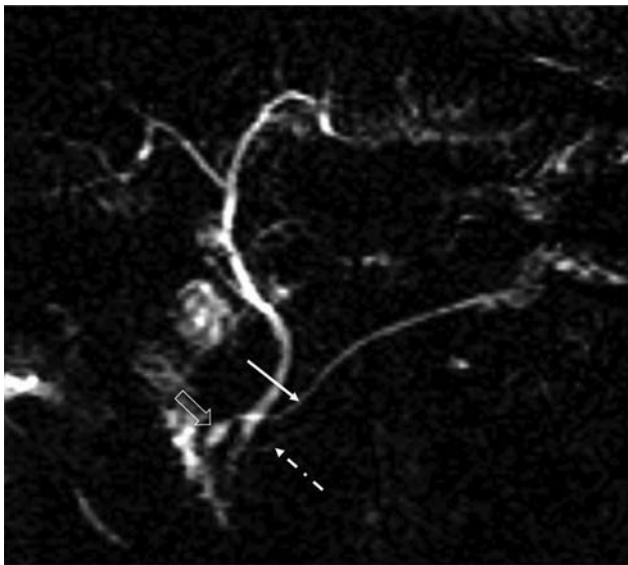


Fig. 7 Magnetic resonance cholangiopancreatography image showing nonfusion of the dorsal (solid arrow) and ventral (interrupted arrow) pancreatic duct suggestive of pancreas divisum. Focal dilation of the dorsal duct near its insertion to the minor papilla (open arrow) represents Santorini cèle.

adults and children; duodenal obstruction is the predominant feature in children, whereas, pancreatitis is the main presentation in adults.⁵⁸

Annular pancreas can be diagnosed on the basis of CT and MR imaging findings that reveal pancreatic tissue and an annular duct encircling the descending duodenum. Pancreatic tissue appears hyperintense on T1-weighted images, and T2-weighted images and MRCP can help in identifying the annular duct encircling the duodenum (► Fig. 8).⁵⁸

Cholechocele

Cholechoceles are cystic dilatations of the distal most (intraduodenal) portion of the CBD that causes enlargement of the papilla.¹ Classified per Todani classification as type III choledochal cysts, however, they have distinctive demographic and anatomic features than other types. They also have lower risk of malignancy than other types of choledochal

cysts.⁴⁵ Cholechoceles often present at an older age, with an average age at presentation of 51 years.⁵⁹ Clinical presentation is variable with most common presentation being upper abdominal pain. Most common complication is pancreatitis and other less common complications include cholestasis, choledocholithiasis, gastric outlet obstruction, and bleeding. Some researchers believe cholechoceles as a variant of duodenal duplication.⁵⁹ Endoscopically it appears as a protrusion of a dilated intramural segment of the CBD into the duodenum. On sonography, CT or MR imaging, cystic dilation of the duodenal portion of the distal CBD is seen⁶⁰ (► Fig. 9).

Inflammatory Conditions Affecting Ampulla and Periapillary Region

Duodenal Papillitis

Papillitis is an acute inflammation of mucosa overlying major papilla at the junction of CBD and MPD and can be seen with biliary or pancreatic abnormalities including cholangitis, pancreatitis, choledocholithiasis, parasitic infestations, or periampullary diverticulitis.⁶¹ An inflamed papilla is usually enlarged measuring more than 10 mm, hyperenhancing compared with adjacent duodenal mucosa, which may be homogeneous or striated.^{61,62} Symmetric wall thickening and hyperenhancement suggest benign papillitis compared with hypovascular malignant neoplasm.

Groove Pancreatitis

Groove pancreatitis is a rare form of chronic pancreatitis involving a region (groove), bordered by pancreatic head, duodenum, and CBD.⁶³ It may be associated with alcohol abuse, smoking, or functional obstruction of minor papilla.⁶⁴ Contrast-enhanced CT and MRI show “sheet like” curvilinear crescentic infiltrating soft tissue in pancreaticoduodenal groove, showing progressive enhancement on delayed images.^{63,65} Additionally, thickening of medial duodenal wall is seen along with cysts within the wall (► Fig. 10). On MRI, the soft tissue appears hypointense on T1, variable on T2 weighted images, showing progressive enhancement on contrast enhanced images. Duodenal wall cysts are prominently seen on T2-weighted images. MRCP may show distal CBD and pancreatic duct strictures, widening distance

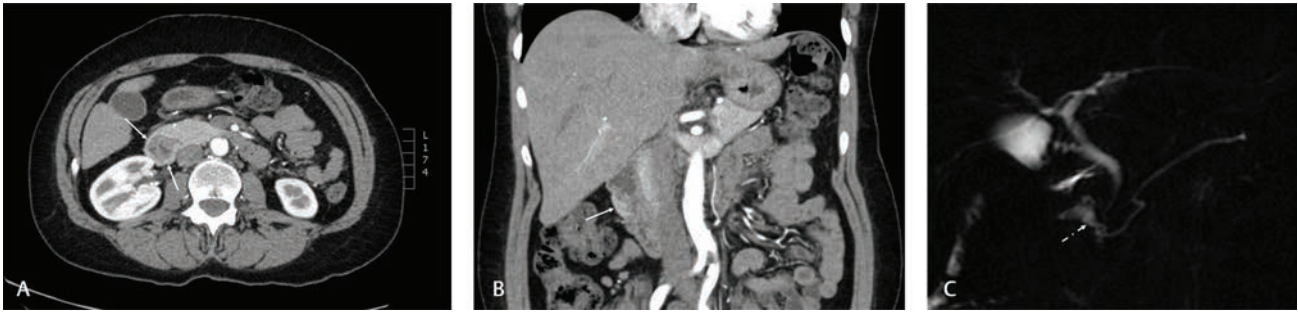


Fig. 8 Annular pancreas seen on axial (A) and coronal (B) postcontrast computed tomography images as soft tissue surrounding the duodenum (solid arrows) with enhancement similar to pancreas. Duct of the annular pancreas is well demonstrated on magnetic resonance cholangiopancreatography image (interrupted arrow in C)

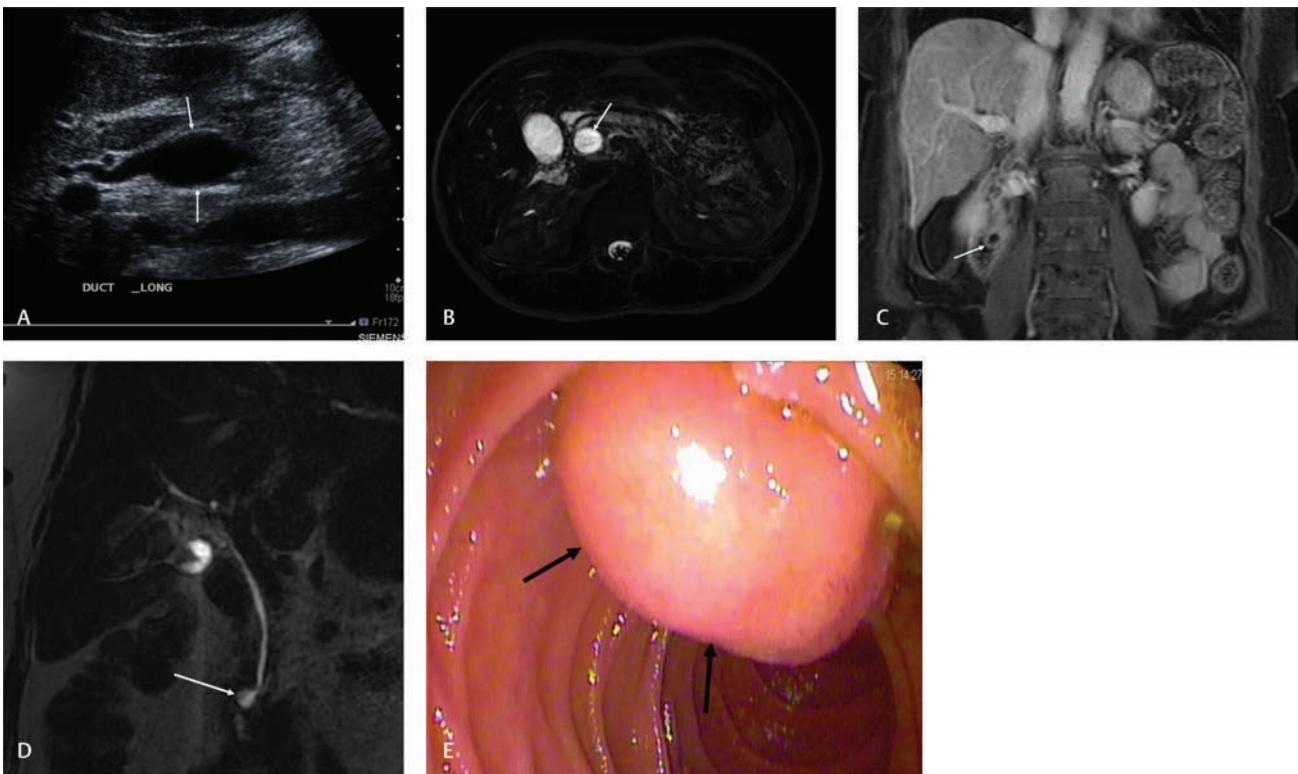


Fig. 9 Cystic dilation of the intraduodenal portion of the common bile duct is shown with white arrow on greyscale sonographic image (A), T2-weighted axial image (B), postcontrast coronal image (C), and coronal magnetic resonance cholangiopancreatography image (D). Endoscopy image showing smooth bulging papilla (black arrows in E)

between ampulla and medial duodenal wall and a dilated “banana shaped” gall bladder.⁶⁶ It may be difficult to exclude duodenal or pancreatic malignancy on noninvasive imaging necessitating an endoscopic US and biopsy and some patients may have to undergo Whipple’s surgery due to continued suspicion of malignancy.⁶³

Periampullary Neoplasms

Periampullary Adenomas

Benign neoplasms arising from the ampulla and the periampullary region are rare, representing less than 10% of periampullary neoplasms. The most common benign lesions are adenomas. Ampullary adenomas are glandular dysplastic lesions that arise in and around the duodenal papilla.⁶⁷

Within the duodenum, 10% of all duodenal polyps are ultimately found to be adenomas, and the most common location is in the periampullary region.⁶⁸ Ampullary adenomas are benign lesions but some have considered them to be premalignant and may possibly progress to carcinoma.^{67,68} Sixty to ninety percent of adenomas are known to have features of carcinoma especially in larger lesions.^{68,69}

Ampullary adenomas may occur sporadically or in the setting of familial adenomatous polyposis (FAP). Patients with FAP almost invariably develop duodenal adenomas and have a risk for ampullary carcinoma that is 124-fold greater than the general population.⁶⁹ These are often asymptomatic and incidentally discovered on endoscopy. Patients may present with symptoms related to obstruction of the biliary or pancreatic duct.⁶⁹

Multiple modalities are available for staging of these lesions and to help guide the most appropriate therapy. Contrast-enhanced CT or MRI show adenomas as a smoothly marginated, enhancing mass in the periampullary region of the duodenum (►Fig. 11). Signs of biliary obstruction can also be seen. The role of imaging is to detect aggressive features such as heterogeneity, ulceration, vascular invasion, and metastasis, and it also aids in operative planning.⁸

Cholangiocarcinoma

Cholangiocarcinomas of the extrahepatic duct mostly arise from the proximal one-third of the duct and distal CBD cholangiocarcinomas account for up to 20% of cases.⁷⁰ There is frequent involvement of the periductal nerves and lymphatics.⁷⁰ Ninety-five percent of these patients show ductal obstruction at the time of diagnosis.⁶⁸ There are three different morphologic subtypes that have different imaging appearances. These include a mass-forming cholangiocarcinoma, periductal infiltrating cholangiocarcinoma, and intraductal cholangiocarcinoma. The mass-forming cholangiocarcinoma usually presents as a discrete lesion that obstructs the extrahepatic bile duct, penetrates the

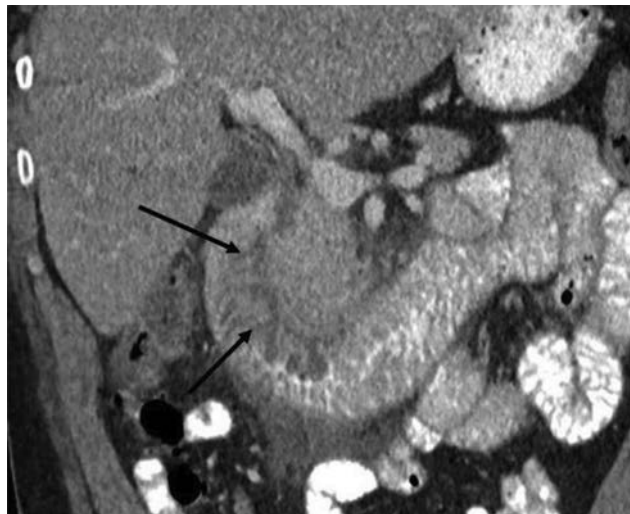


Fig. 10 Groove pancreatitis is seen as inflammatory changes in the duodenopancreatic groove with thickened medial wall of the duodenum showing cystic areas.

wall, and invades the periductal tissues. These lesions can show some hypervascularity on arterial phase images with progressive increased enhancement on delayed images (►Fig. 12).^{68,70} There is resultant proximal biliary ductal dilatation to varying degrees.⁷⁰ The periductal infiltrating variant is more challenging to identify and may present as asymmetric and/or concentric ductal wall thickening with associated enhancement at the site of transition and usually involves a short segment.⁶⁸ The thickness of the wall may measure up to 1 cm. The extent of the tumor varies, ranging from 0.5 to 6 cm in length, sometimes involving all the extrahepatic ducts and may extend proximally as far as the intrahepatic ducts.⁷⁰ On CT or MRI, the thickened bile ducts can be visualized as an enhancing ring or spot. Periductal-infiltrating cholangiocarcinoma tends to spread along the bile duct wall via the nerve and perineural tissues toward the porta hepatis. Portions of the tumor may extend beneath the intact mucosa. The tumor grows longitudinally and extends along the axis of the bile ducts resembling branches of a tree.⁷⁰

The intraductal variant is rare and can have a variable morphology. This subtype is not readily distinguishable from the other two morphologic subtypes. These lesions usually spread along the inner surface of the bile duct, either as a superficially spreading mass, focal wall thickening, or as a discrete intraluminal polypoidal lesion.⁶⁸

Discrete multiple tumors (cholangiocarcinomatosis) may be present along the inner surface of the bile ducts. This variety is limited to the mucosa and invades the wall and the surrounding tissue in the very late phase. Intraductal papillary cholangiocarcinoma is friable and sloughs easily at the time of surgery or endoscopic biopsy. It can also slough spontaneously and mimic bile duct stones, occluding the bile ducts.⁷⁰

Ampullary Carcinoma

The duodenal papilla is lined by intestinal mucosa, whereas the ampullary portions are covered by simple mucinous epithelium, as in the normal bile duct, malignancies of the ampulla can arise from these two cell types. Pancreaticobiliary type of differentiation is more common than intestinal. Intestinal type is associated with better prognosis.⁷¹

Ampullary carcinoma is rare, with an incidence rate of 4 to 6 per million. The intestinal type ampullary carcinoma is

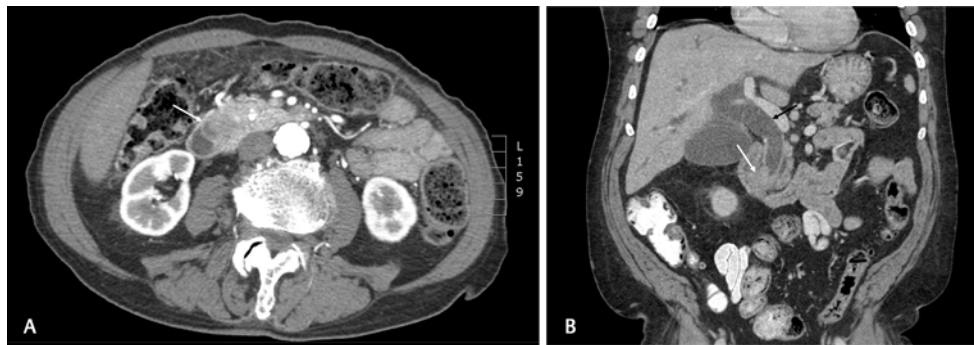


Fig. 11 Periampullary adenoma depicted on axial (A) and coronal (B) contrast-enhanced computed tomography as smooth enhancing mass at the ampulla causing biliary dilations (black arrow in B).

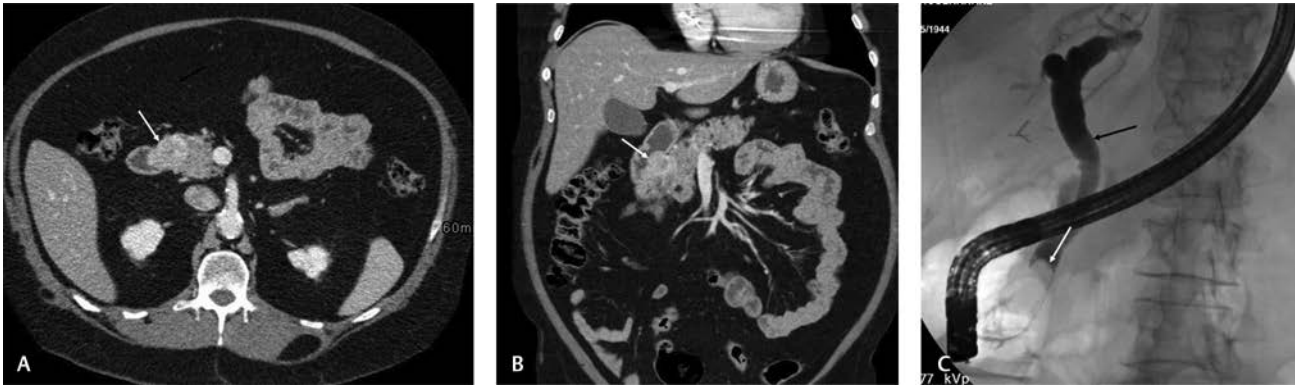


Fig. 12 Mass forming cholangiocarcinoma is seen as enhancing mass on axial (A) and coronal (B) postcontrast computed tomography images (white arrow). Mass (white arrow) is seen obstructing the bile duct (black arrow) on endoscopic retrograde cholangiopancreatography image.

relatively more common, and its incidence can increase 200- to 300-fold among genetically susceptible groups such as patients with hereditary polyposis syndromes. The average age at diagnosis of sporadic ampullary carcinomas is 60 to 70 years old with patients with an inherited polyposis syndrome presenting at an earlier age.⁷¹

The biologic behavior of these tumors depends on the exact organ of origin. Pathologists divide these tumors into three groups: tumors arising from the duodenal epithelium, tumors arising from the pancreato-biliary epithelium of the distal CBD or pancreatic duct, and intra-ampullary tumors showing histologic overlap with combined duodenal and pancreaticobiliary epithelium.

Intra-ampullary tumors tend to have the best prognosis with relatively earlier presentation because of early, severe ductal obstruction and a lesser invasive component. Tumors arising from the pancreatobiliary epithelium tend to have a worse prognosis with prognosis relatively similar to pancreatic adenocarcinoma.⁸ Tumors arising from the duodenal mucosa tend to be large at presentation with a greater propensity for lymph node metastases. These three subtypes cannot be reliably distinguished on imaging⁶⁸ (► Fig. 13).

Ampullary Carcinoid

Isolated ampullary carcinoid tumors are exceedingly rare and are biologically distinct from other small bowel or duodenal carcinoid tumors, with ampullary carcinoids showing a higher predilection for metastatic disease. These tumors tend to present as small lesions, can develop nodal disease even when the primary tumor is quite small, and almost never present with a hypersecretion syndrome. Given the risk of aggressive behavior even with small lesions and their tendency to obstruct the biliary tree, these tumors invariably are treated with a pancreaticoduodenectomy.

Like other neuroendocrine tumors in the bowel or the pancreas, ampullary carcinoid tumors (and their locoregional lymph node metastases) are isointense to muscle on T1-weighted images and are either hyper- or isointense to muscle on T2-weighted images^{8,68}

The most characteristic appearance of carcinoid tumor of the ampulla of Vater is an avidly enhancing discrete submucosal mass without necrosis or hemorrhage^{32,72} (► Fig. 14).

Pancreatic Adenocarcinoma

A pancreatic head or uncinus process adenocarcinoma is difficult to differentiate from a primary ampullary neoplasm. These neoplasms appear to have common imaging findings and presentation with similar biliary and pancreatic ductal obstruction and relative hypoenhancement to the surrounding pancreas on imaging (► Fig. 15). This is especially challenging in the region of the pancreaticoduodenal groove. Clear differentiation between these two types of lesions is not considered important given that both are treated with pancreaticoduodenectomy.⁶⁸

Periapillary Duodenal Adenocarcinomas

Adenocarcinoma represents up to 80 to 90% of all primary duodenal malignant tumors. It is predominantly located in the second portion of the duodenum. Fifty percent of patients present with metastasis at the time of diagnosis. The presenting symptoms are bleeding, anemia, obstructive jaundice, or duodenal obstruction with vomiting.⁷³ Clinical presentation including pancreatic and biliary ductal obstruction is similar, but their biologic behavior tends to be different. On CT and MR imaging, duodenal adenocarcinoma may present as a soft-tissue/ polypoid mass, a concentric or asymmetric thickening, an annular narrowing with irregular borders or as an ulcerated mass.^{8,68} Ulceration is strongly indicative of the diagnosis of adenocarcinoma and is well visualized on CT and MR imaging. Mild, heterogeneous late enhancement after IV contrast is seen may be seen because of a predominant fibrous component. Lymph node enlargement is often absent contrary to other tumors such as duodenal lymphoma.⁷³

Differentiating Benign and Malignant Biliary Stricture on Imaging

One of the important challenges of MRCP is to differentiate a benign versus malignant stricture. Several studies

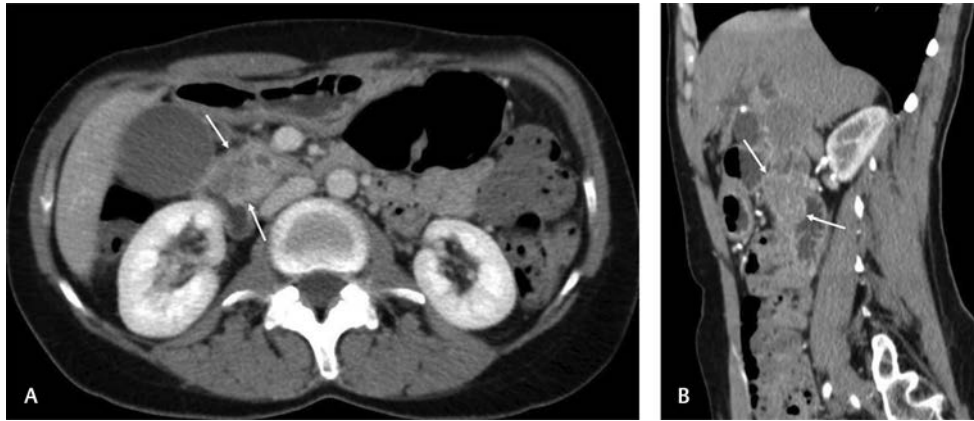


Fig. 13 Ampullary adenocarcinoma arising from duodenal mucosa is shown on axial (A) and sagittal (B) contrast enhanced computed tomography as a large lobulated mass arising from the periampullary region (arrows).

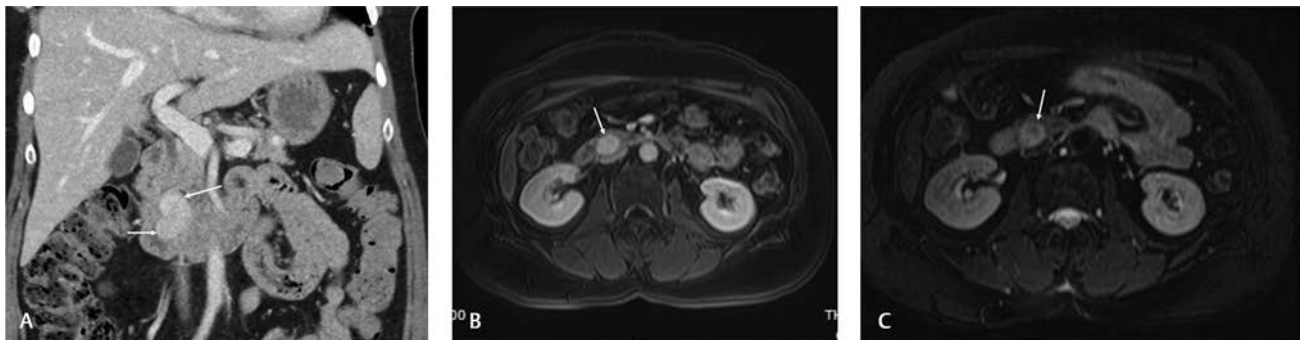


Fig. 14 Periampullary neuroendocrine tumor is seen on coronal contrast-enhanced computed tomography (A) and axial postcontrast magnetic resonance (MR) image (B) as an avidly enhancing mass that is hyperintense on T2-weighted MR images (C).

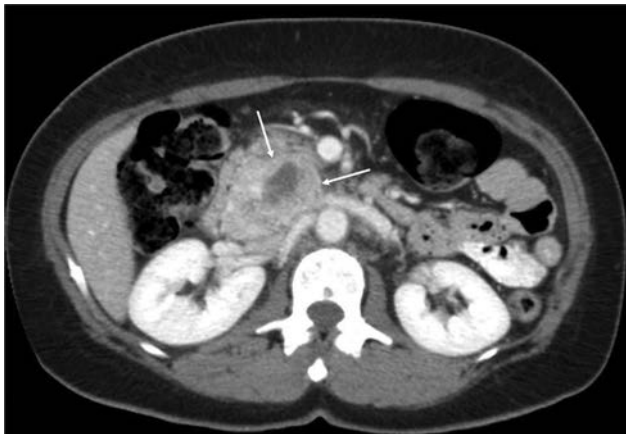

Fig. 15 Contrast enhanced axial computed tomography image shows a large necrotic pancreatic adenocarcinoma arising from the pancreatic head, close to the ampulla.

have shown malignant strictures to be more common in males compared with females.^{74,75} Benign strictures are commonly related to prior cholecystectomy, inflammation, or pancreatitis.⁷⁴ Patients with primary sclerosing

cholangitis or autoimmune disease may show multiple strictures.⁷⁶ Benign strictures are usually short segment with smooth margins and show symmetric dilation of biliary radicals.⁷⁴⁻⁷⁶ Malignant strictures on the other hand tend to be longer, irregular, and thicker due to infiltrative growth of cancer, with indistinct margins and showing increased enhancement relative to liver parenchyma on portal venous phase.^{74,75,77,78} There is asymmetric upstream biliary ductal dilation in malignant strictures. Presence of mass is highly specific for a malignant stricture; however, its nonvisualization does not exclude the possibility.⁷⁴

Conclusion

The ampulla of Vater is an anatomically complex region and is a site of wide range of anomalies and pathologies. Many times presentations can be nonspecific. Noninvasive imaging, especially, MDCT and MRCP, can detect these lesions and at times provide accurate diagnosis with better understanding of the anatomy, embryology, and pathophysiology. A summary of lesions affecting ampullary and periampullary region is provided in ► **Table 1**.

Table 1 A summary of lesions affecting ampullary and periampullary region

Type of abnormality	Clinical	Imaging
Congenital		
Periapillary Duodenal Diverticulum	Outpouchings along medial wall of duodenum within 2-3 cm of ampulla of Vater Incidental findings on CT or MR Complications: diverticulitis, hemorrhage, perforation or fistula formation, stone formation, biliary obstruction (Lemmel syndrome), cholangitis, and pancreatitis.	CT and MR fluid-filled outpouching along the medial duodenal wall, may have air fluid level seen as susceptibility artifact on MRI. Improved visualization with MPR reconstructions and oral contrast
Intraluminal Duodenal Diverticulum	Result of incomplete recanalization of embryonic foregut. Usually, asymptomatic. Rarely can cause abdominal pain and present with GI bleed or obstruction Endoscopy: dual lumens seen.	Fluoroscopy: Contrast filled diverticulum surrounded by radiolucency representing diaphragm, and outermost layer of contrast in duodenum (Windsock/finger in glove sign) CT: Hypodense mass in duodenum.
Abnormal biliopancreatic Junction (pancreaticobiliary maljunction)	Rare developmental anomaly. Pancreatic and bile ducts join outside the duodenal wall, forming long common channel. Increased risk of biliary cancer. Need close imaging follow-up. ERCP provides anatomical information, assess sphincter of Oddi function and bile sampling.	MRCP with secretin – Depicts biliary anatomy and provides functional information. MRI with hepatobiliary contrast (Gadoxetic acid)- can show biliopancreatic reflux.
Pancreatic divisum	Failure of fusion of ventral and dorsal pancreatic ducts. Can present as idiopathic pancreatitis. ERCP show ventral duct opacification with cannulation of the major papilla.	MRCP show dorsal and ventral ducts opening separately in minor and major papilla respectively.
Annular Pancreas	Rare congenital anomaly A part of pancreas encircles second part of duodenum. Can present as duodenal obstruction (children) and pancreatitis (adults).	CT/MRI: Pancreatic tissue seen surrounding the second part of duodenum. MRCP: Pancreatic duct seen encircling the duodenum.
Choledochocele	Cystic dilation of intraduodenal portion of CBD resulting in enlarged papilla (type III choledochal cyst). Can present as abdominal pain cholestasis, choledocholithiasis, gastric outlet obstruction and bleeding.	CT/MR: Cystic dilation of intraduodenal portion of distal CBD.
Acquired		
Ampullary Stenosis	Characterized by dilated CBD and MPD with laboratory evidence of biliary obstruction in the absence of a mass or inflammatory lesion at the ampulla. Can present with recurrent abdominal pain, pancreatitis, and jaundice.	CT and MRI/MRCP: Dilated CBD and MPD. Careful attention to rule out underlying mass
Sphincter of Oddi Dysfunction (SOD)	Inability of the sphincter to contract and relax in a normal way. May cause biliary obstruction, presenting with abdominal pain and pancreatitis. Gold standard for diagnosis: Manometric demonstration of sphincter pressures >40 mmHg during ERCP.	MRCP: Dilated MPD and CBD with smooth tapering to the ampulla without calculus or mass lesion. Secretin-enhanced MRCP demonstrates increase in MPD diameter of more than 1 mm or prolonged dilatation (>3 mm at 10 min)
Iatrogenic ampullary stenosis	Narrowing of sphincteric complex in presence of prior biliary intervention or endoscopy.	MRI and CT: Biliary dilation in absence of obstructing ampullary mass.

(Continued)

Table 1 (Continued)

Type of abnormality	Clinical	Imaging
Neoplasms		
Benign		
Periapillary adenomas	Benign lesions in and around ampulla. May have features of carcinoma in larger lesions, especially those with FAP. May present with biliary obstruction.	CT and MRI: Smooth enhancing mass in periampullary region. Biliary dilation. Signs of malignancy- heterogeneity, ulceration, vascular invasion, and metastasis.
Malignant		
Cholangiocarcinoma (CCA)	Can be mass like, infiltrating or intraductal. Present with obstructive jaundice.	CT and MRI: Depending upon tumor type. Mass forming- Heterogenous lesion showing progressive enhancement and biliary dilation. Periductal infiltrating- segmental enhancement and wall thickening, spreading along bile duct branches. Intraductal (rare)- intraluminal polyp or superficial spreading mass.
Ampullary Carcinoma	Mass lesions arising at ampulla. Intestinal or pancreatobiliary type. Seen with increased frequency in hereditary polyposis syndromes.	CT and MRI – Enhancing mass may be seen at ampulla with dilated bile and pancreatic ducts.
Ampullary carcinoid	Rare aggressive neoplasms present with metastases even when small. Usually, nonfunctioning. Cause biliary obstruction.	CT and MRI: Enhancing mass without necrosis or hemorrhage.
Pancreatic adenocarcinoma	Mass in pancreatic head presenting with abdominal pain and obstructive jaundice.	CT and MRI: present as a hypo enhancing mass in head of pancreas MRCP: CBD and pancreatic ductal dilation (double duct sign)
Periapillary Duodenal adenocarcinomas	Majority of primary duodenal malignant tumors present with bleeding, anemia, obstructive jaundice or duodenal obstruction with vomiting.	CT and MRI: polypoid soft tissue mass causing concentric or asymmetric narrowing of duodenal lumen. Ulceration strongly supports diagnosis of duodenal adenocarcinoma.

Conflict of Interest

None declared.

References

- Nikolaidis P, Hammond NA, Day K, et al. Imaging features of benign and malignant ampullary and periampullary lesions. *Radiographics* 2014;34(3):624–641
- Frierson HF Jr. The gross anatomy and histology of the gallbladder, extrahepatic bile ducts, Vaterian system, and minor papilla. *Am J Surg Pathol* 1989;13(2):146–162
- Russu IG, Vaida A. [New findings on the development of the pancreas]. *Acta Anat (Basel)* 1959;38:114–125
- Tadokoro H, Takase M, Nobukawa B. Development and congenital anomalies of the pancreas. *Anat Res Int* 2011;2011:351217
- Rizzo RJ, Szucs RA, Turner MA. Congenital abnormalities of the pancreas and biliary tree in adults. *Radiographics* 1995;15(1):49–68, quiz 147–148
- Henry BM, Skinningsrud B, Saganiak K, Pekala PA, Walocha JA, Tomaszewski KA. Development of the human pancreas and its vasculature - an integrated review covering anatomical, embryological, histological, and molecular aspects. *Ann Anat* 2019;221:115–124
- Horiguchi S, Kamisawa T. Major duodenal papilla and its normal anatomy. *Dig Surg* 2010;27(2):90–93
- Alessandrino F, Ivanovic AM, Yee EU, Radulovic D, Souza D, Mortelet KJ. MDCT and MRI of the ampulla of Vater. Part I: technique optimization, normal anatomy, and epithelial neoplasms. *Abdom Imaging* 2015;40(8):3274–3291
- Mirilas P, Colborn GL, Skandalakis LJ, Skandalakis PN, Zoras O, Skandalakis JE. Benign anatomical mistakes: “ampulla of Vater” and “papilla of Vater” *Am Surg* 2005;71(3):269–274
- Sun CH, Li X, Chan T, et al. Multidetector computed tomography (MDCT) manifestations of the normal duodenal papilla. *Eur J Radiol* 2013;82(6):918–922
- Suda K. Histopathology of the minor duodenal papilla. *Dig Surg* 2010;27(2):137–139
- Kim TU, Kim S, Lee JW, et al. Ampulla of Vater: comprehensive anatomy, MR imaging of pathologic conditions, and correlation with endoscopy. *Eur J Radiol* 2008;66(1):48–64
- Quencer K, Kambadakone A, Sahani D, Guimaraes AS. Imaging of the pancreas: part 1. *Appl Radiol* 2013;42(9):14–20
- Saran S, Malik S, Kharbanda A, Sharma Y. Pneumobilia with multiple air-fluid levels on abdominal radiography: a clincher. *Ann Afr Med* 2019;18(2):115–116
- Hope JW, Gibbons JF. Duodenal obstruction due to annular pancreas; with a differential diagnosis of other congenital lesions producing duodenal obstruction. *Radiology* 1954;63(4):473–490
- Ashida R, Tanaka S, Yamanaka H, et al. The role of transabdominal ultrasound in the diagnosis of early stage pancreatic cancer:

- review and single-center experience. *Diagnostics (Basel)* 2018;9(1):2
- 17 Kanno A, Masamune A, Hanada K, et al; Japan Study Group on the Early Detection of Pancreatic Cancer (JEDPAC). Multicenter study of early pancreatic cancer in Japan. *Pancreatology* 2018;18(1):61–67
 - 18 Gandolfi L, Torresan F, Solmi L, Puccetti A. The role of ultrasound in biliary and pancreatic diseases. *Eur J Ultrasound* 2003;16(3):141–159
 - 19 Tse F, Barkun JS, Romagnuolo J, Friedman G, Bornstein JD, Barkun AN. Nonoperative imaging techniques in suspected biliary tract obstruction. *HPB (Oxford)* 2006;8(6):409–425
 - 20 Albrecht T, Hohmann J, Oldenburg A, Skrok J, Wolf KJ. Detection and characterisation of liver metastases. *Eur Radiol* 2004;14(Suppl 8):25–33
 - 21 Patel NB, Oto A, Thomas S. Multidetector CT of emergent biliary pathologic conditions. *Radiographics* 2013;33(7):1867–1888
 - 22 Nino-Murcia M, Jeffrey RB Jr, Beaulieu CF, Li KCP, Rubin GD. Multidetector CT of the pancreas and bile duct system: value of curved planar reformations. *AJR Am J Roentgenol* 2001;176(3):689–693
 - 23 Zaky AM, Wolfgang CL, Weiss MJ, Javed AA, Fishman EK, Zaheer A. Tumor-vessel relationships in pancreatic ductal adenocarcinoma at multidetector CT: different classification systems and their influence on treatment planning. *Radiographics* 2017;37(1):93–112
 - 24 Luna A, Pahwa S, Bonini C, Alcalá-Mata L, Wright KL, Gulani V. Multiparametric MR imaging in abdominal malignancies. *Magn Reson Imaging Clin N Am* 2016;24(1):157–186
 - 25 Yeh BM, Liu PS, Soto JA, Corvera CA, Hussain HKMR. MR imaging and CT of the biliary tract. *Radiographics* 2009;29(6):1669–1688
 - 26 Zhang J, Israel GM, Hecht EM, Krinsky GA, Babb JS, Lee VS. Isotropic 3D T2-weighted MR cholangiopancreatography with parallel imaging: feasibility study. *AJR Am J Roentgenol* 2006;187(6):1564–1570
 - 27 Riff BP, Chandrasekhara V. The role of endoscopic retrograde cholangiopancreatography in management of pancreatic diseases. *Gastroenterol Clin North Am* 2016;45(1):45–65
 - 28 Canlas KR, Branch MS. Role of endoscopic retrograde cholangiopancreatography in acute pancreatitis. *World J Gastroenterol* 2007;13(47):6314–6320
 - 29 Săftoiu A, Vilmann P. Role of endoscopic ultrasound in the diagnosis and staging of pancreatic cancer. *J Clin Ultrasound* 2009;37(1):1–17
 - 30 Yoshida T, Yamashita Y, Kitano M. Endoscopic ultrasound for early diagnosis of pancreatic cancer. *Diagnostics (Basel)* 2019;9(3):81
 - 31 Harima H, Kaino S, Shinoda S, Kawano M, Suenaga S, Sakaida I. Differential diagnosis of benign and malignant branch duct intraductal papillary mucinous neoplasm using contrast-enhanced endoscopic ultrasonography. *World J Gastroenterol* 2015;21(20):6252–6260
 - 32 Alessandrino F, Souza D, Ivanovic AM, Radulovic D, Yee EU, Morteale KJ. MDCT and MRI of the ampulla of Vater. Part II: non-epithelial neoplasms, benign ampullary disorders, and pitfalls. *Abdom Imaging* 2015;40(8):3292–3312
 - 33 Karayiannakis AJ, Bolanaki H, Courcousakis N, et al. Common bile duct obstruction secondary to a periampullary diverticulum. *Case Rep Gastroenterol* 2012;6(2):523–529
 - 34 Buse PE, Edmundowicz SA. Proximal common bile duct obstruction secondary to a periampullary duodenal diverticulum: successful treatment with endoscopic stenting. *Gastrointest Endosc* 1991;37(6):635–637
 - 35 Wu SD, Su Y, Fan Y, et al. Relationship between intraduodenal peri-ampullary diverticulum and biliary disease in 178 patients undergoing ERCP. *Hepatobiliary Pancreat Dis Int* 2007;6(3):299–302
 - 36 Zoepf T, Zoepf DS, Arnold JC, Benz C, Riemann JF. The relationship between juxtampillary duodenal diverticula and disorders of the biliopancreatic system: analysis of 350 patients. *Gastrointest Endosc* 2001;54(1):56–61
 - 37 Yoneyama F, Miyata K, Ohta H, Takeuchi E, Yamada T, Kobayashi Y. Excision of a juxtampillary duodenal diverticulum causing biliary obstruction: report of three cases. *J Hepatobiliary Pancreat Surg* 2004;11(1):69–72
 - 38 Anand V, Provost J, Bakr M, et al. Two cases of intraluminal “windsock” diverticula resulting in partial duodenal obstruction. *ACG Case Rep J* 2016;3(4):e135
 - 39 Fidler JL, Saigh JA, Thompson JS, Habbe TG. Demonstration of intraluminal duodenal diverticulum by computed tomography. *Abdom Imaging* 1998;23(1):38–39
 - 40 Jayaraman MV, Mayo-Smith WW, Movson JS, Dupuy DE, Wallach MT. CT of the duodenum: an overlooked segment gets its due. *Radiographics* 2001;21(Spec No):S147–S160
 - 41 Veldkamp MC, Rauws EA, Dijkgraaf MG, Fockens P, Bruno MJ. Iatrogenic ampullary stenosis: history, endoscopic management, and outcome in a series of 49 patients. *Gastrointest Endosc* 2007;66(4):708–716, quiz 768, 770
 - 42 Aisen AM, Sherman S, Jennings SG, et al. Comparison of secretin-stimulated magnetic resonance pancreatography and manometry results in patients with suspected sphincter of Oddi dysfunction. *Acad Radiol* 2008;15(5):601–609
 - 43 Urushihara N, Hamada Y, Kamisawa T, et al. Classification of pancreaticobiliary maljunction and clinical features in children. *J Hepatobiliary Pancreat Sci* 2017;24(8):449–455
 - 44 Kamisawa T, Kuruma S, Chiba K, Tabata T, Koizumi S, Kikuyama M. Biliary carcinogenesis in pancreaticobiliary maljunction. *J Gastroenterol* 2017;52(2):158–163
 - 45 Law R, Topazian M. Diagnosis and treatment of choledochocoles. *Clin Gastroenterol Hepatol* 2014;12(2):196–203
 - 46 Kamisawa T, Ando H, Suyama M, Shimada M, Morine Y, Shimada H; Working Committee of Clinical Practice Guidelines for Pancreaticobiliary Maljunction. Japanese Study Group on Pancreaticobiliary Maljunction. Japanese clinical practice guidelines for pancreaticobiliary maljunction. *J Gastroenterol* 2012;47(7):731–759
 - 47 Kamisawa T, Ando H, Hamada Y, et al. Japanese Study Group on Pancreaticobiliary Maljunction. Diagnostic criteria for pancreaticobiliary maljunction 2013. *J Hepatobiliary Pancreat Sci* 2014;21(3):159–161
 - 48 Kamisawa T, Amemiya K, Tu Y, et al. Clinical significance of a long common channel. *Pancreatology* 2002;2(2):122–128
 - 49 Ono A, Arizono S, Isoda H, Togashi K. Imaging of pancreaticobiliary maljunction. *Radiographics* 2020;40(2):378–392
 - 50 Yeom SK, Lee SW, Cha SH, et al. Biliary reflux detection in anomalous union of the pancreatico-biliary duct patients. *World J Gastroenterol* 2012;18(9):952–959
 - 51 Morine Y, Shimada M, Takamatsu H, et al. Clinical features of pancreaticobiliary maljunction: update analysis of 2nd Japan-nationwide survey. *J Hepatobiliary Pancreat Sci* 2013;20(5):472–480
 - 52 Kobayashi M, Hirata N, Nakaji S, Shiratori T, Fujii H, Ishii E. Gastrointestinal stromal tumor of the ampulla of Vater: a case report. *World J Gastroenterol* 2014;20(16):4817–4821
 - 53 Chang S, Lim JH, Choi D, Kim SK, Lee WJ. Differentiation of ampullary tumor from benign papillary stricture by thin-section multidetector CT. *Abdom Imaging* 2008;33(4):457–462
 - 54 Hernandez-Jover D, Pernas JC, Gonzalez-Ceballos S, Lupu I, Monill JM, Pérez C. Pancreatoduodenal junction: review of anatomy and pathologic conditions. *J Gastrointest Surg* 2011;15(7):1269–1281
 - 55 Klein SD, Affronti JP. Pancreas divisum, an evidence-based review: part I, pathophysiology. *Gastrointest Endosc* 2004;60(3):419–425

- 56 DiMagno MJ, Wamsteker EJ. Pancreas divisum. *Curr Gastroenterol Rep* 2011;13(2):150–156
- 57 Sandrasegaran K, Patel A, Fogel EL, Zyromski NJ, Pitt HA. Annular pancreas in adults. *AJR Am J Roentgenol* 2009; 193(2):455–460
- 58 Zyromski NJ, Sandoval JA, Pitt HA, et al. Annular pancreas: dramatic differences between children and adults. *J Am Coll Surg* 2008;206(5):1019–1025, discussion 1025–1027
- 59 Ziegler KM, Zyromski NJ. Choledochoceles: are they choledochal cysts? *Adv Surg* 2011;45:211–224
- 60 Lee HK, Park SJ, Yi BH, Lee AL, Moon JH, Chang YW. Imaging features of adult choledochal cysts: a pictorial review. *Korean J Radiol* 2009;10(1):71–80
- 61 Kim S, Lee NK, Lee JW, et al. CT evaluation of the bulging papilla with endoscopic correlation. *Radiographics* 2007; 27(4):1023–1038
- 62 Miller FH, Hwang CM, Gabriel H, Goodhart LA, Omar AJ, Parsons WG III. Contrast-enhanced helical CT of choledocholithiasis. *AJR Am J Roentgenol* 2003;181(1):125–130
- 63 Raman SP, Salaria SN, Hruban RH, Fishman EK. Groove pancreatitis: spectrum of imaging findings and radiology-pathology correlation. *AJR Am J Roentgenol* 2013;201(1):W29–39
- 64 Triantopoulou C, Dervenis C, Giannakou N, Papailiou J, Prassopoulos P. Groove pancreatitis: a diagnostic challenge. *Eur Radiol* 2009;19(7):1736–1743
- 65 Kwak SW, Kim S, Lee JW, et al. Evaluation of unusual causes of pancreatitis: role of cross-sectional imaging. *Eur J Radiol* 2009; 71(2):296–312
- 66 Castell-Monsalve FJ, Sousa-Martin JM, Carranza-Carranza A. Groove pancreatitis: MRI and pathologic findings. *Abdom Imaging* 2008;33(3):342–348
- 67 Kim AL, Choi YI. Safety of duodenal ampullectomy for benign periampullary tumors. *Ann Hepatobiliary Pancreat Surg* 2017;21(3):146–150
- 68 Raman SP, Fishman EK. Abnormalities of the distal common bile duct and ampulla: diagnostic approach and differential diagnosis using multiplanar reformations and 3D imaging. *AJR Am J Roentgenol* 2014;203(1):17–28
- 69 Chini P, Draganov PV. Diagnosis and management of ampullary adenoma: the expanding role of endoscopy. *World J Gastrointest Endosc* 2011;3(12):241–247
- 70 Lim JH. Cholangiocarcinoma: morphologic classification according to growth pattern and imaging findings. *AJR Am J Roentgenol* 2003;181(3):819–827
- 71 Hennedige TP, Neo WT, Venkatesh SK. Imaging of malignancies of the biliary tract- an update. *Cancer Imaging* 2014;14:14
- 72 Yano F, Hama Y, Abe K, Iwasaki Y, Hatsuse K, Kusano S. Carcinoid tumor of the ampulla of Vater. Magnetic resonance imaging findings. *Clin Imaging* 2005;29(3):207–210
- 73 Barat M, Dohan A, Dautry R, et al. Mass-forming lesions of the duodenum: a pictorial review. *Diagn Interv Imaging* 2017; 98(10):663–675
- 74 Suthar M, Purohit S, Bhargav V, Goyal P. Role of MRCP in differentiation of benign and malignant causes of biliary obstruction. *J Clin Diagn Res* 2015;9(11):TC08–TC12
- 75 Saluja SS, Sharma R, Pal S, Sahni P, Chattopadhyay TK. Differentiation between benign and malignant hilar obstructions using laboratory and radiological investigations: a prospective study. *HPB (Oxford)* 2007;9(5):373–382
- 76 Katabathina VS, Dasyam AK, Dasyam N, Hosseinzadeh K. Adult bile duct strictures: role of MR imaging and MR cholangiopancreatography in characterization. *Radiographics* 2014; 34(3):565–586
- 77 Yu X-R, Huang W-Y, Zhang B-Y, Li H-Q, Geng D-Y. Differentiation of infiltrative cholangiocarcinoma from benign common bile duct stricture using three-dimensional dynamic contrast-enhanced MRI with MRCP. *Clin Radiol* 2014;69(6): 567–573
- 78 Kim JY, Lee JM, Han JK, et al. Contrast-enhanced MRI combined with MR cholangiopancreatography for the evaluation of patients with biliary strictures: differentiation of malignant from benign bile duct strictures. *J Magn Reson Imaging* 2007;26(2):304–312

This article has been corrected as per the Erratum published online on June 11, 2021. DOI of the Erratum is 10.1055/s-0041-1731096.