




Radiofrequency Thermocoagulation of the Gasserian Ganglion for Trigeminal Neuralgia using a Stereotactic Approach due to a Pterygoalar Bar

Termocoagulação por radiofrequência do gânglio de Gasser na nevralgia do trigêmeo, guiada por estereotaxia devido à presença de barra pterigoalar

Kalínio de Kássio O. Monteiro¹  Virgílio Vilá Moura¹ Renato Carvalho Santos¹
Ronan Arnon Anchieta¹ Atahualpa Cauê Paim Strapasson^{1,2} Jony Soares Ramos (in memorian)¹
Cláudia Sibebe Monteiro³

¹Neurosurgery Service, Hospital Santa Rosa, Cuiabá, MT, Brazil

²Centro Universitário de Várzea Grande (UNIVAG), MT, Brazil

³Centro Universitário UNI, Belo Horizonte, MG, Brazil

Address for correspondence Kalinio de Kassio de Oliveira Monteiro, Rua Adelf Maluf 119, Jardim Mariana, Cuiaba, Mato Grosso, CEP: 78040-600 (e-mail: kaliniomonteiro@icloud.com).

Arq Bras Neurocir 2022;41(3):e283–e287.

Abstract

The treatment of trigeminal neuralgia (TN) consists of pharmacotherapy and neurosurgical procedure, such as percutaneous radiofrequency rhizotomy. Here, we present the case of a patient with TN refractory to clinical treatment who presented an anatomical variation in the oval foramen, which required stereotactic-guided surgery to access the Gasser ganglion.

This is a 63-year-old male patient who presented with TN refractory to drug treatment. He used carbamazepine and nortriptyline, with no satisfactory response. The percutaneous approach to radiofrequency thermocoagulation was indicated, in view of the comorbidities presented and the patient's age. Due to the presence of a rare anatomical variation, stereotactic-guided surgery was used to cannulate the foramen ovale and, thus, successfully perform the neurosurgical procedure with an excellent clinical response. The use of stereotaxy to guide cannulation of the foramen ovale due to anatomical variation was essential for the success of the procedure. The knowledge of the existence of this anatomical variation, and the mastery of the stereotactic technique enabled the adequate management in the face of the unusual situation.

Keywords

- ▶ Gasserian ganglion
- ▶ trigeminal neuralgia
- ▶ stereotactic
- ▶ pterygoalar bar

received
June 22, 2021
accepted after revision
October 13, 2021

DOI <https://doi.org/10.1055/s-0042-1742426>.
ISSN 0103-5355.

© 2022. Sociedade Brasileira de Neurocirurgia. All rights reserved. This is an open access article published by Thieme under the terms of the Creative Commons Attribution-NonDerivative-NonCommercial-License, permitting copying and reproduction so long as the original work is given appropriate credit. Contents may not be used for commercial purposes, or adapted, remixed, transformed or built upon. (<https://creativecommons.org/licenses/by-nc-nd/4.0/>)
Thieme Revinter Publicações Ltda., Rua do Matoso 170, Rio de Janeiro, RJ, CEP 20270-135, Brazil

Resumo

O tratamento da neuralgia do trigêmeo (NT) consta de farmacoterapia e procedimento neurocirúrgicos, como a rizotomia percutânea por radiofrequência. Aqui apresentamos o caso de um paciente com NT refratária ao tratamento clínico que apresentava uma variação anatômica no forame oval, o que exigiu a realização de cirurgia guiada por estereotaxia para acesso ao gânglio de Gasser.

Trata-se de um paciente do sexo masculino, com 63 anos de idade, que apresentava quadro de NT refratária ao tratamento medicamentoso. Fez uso de carbamazepina e nortriptilina, sem resposta satisfatória. Foi indicada a abordagem percutânea para termocoagulação por radiofrequência, tendo em vista comorbidades apresentadas e a idade do paciente. Devido à presença de uma rara variação anatômica, utilizou-se a cirurgia guiada por estereotaxia para canular o forame oval, e, dessa forma, realizar o procedimento neurocirúrgico com sucesso e uma excelente resposta clínica. A utilização de estereotaxia para guiar a canulação do forame oval devido à variação anatômica foi essencial para o sucesso do procedimento. O conhecimento da existência dessa variação anatômica, e o domínio da técnica estereotática possibilitaram o adequado manejo frente a uma situação incomum.

Palavras-chave

- ▶ gânglio gasseriano
- ▶ neuralgia trigeminal
- ▶ estereotático
- ▶ ligamento pterigoalar

Introduction

Trigeminal neuralgia (TN) is one of the most common diseases that affect the cranial nerves, with an annual incidence of 12.6 per 100 thousand inhabitants.^{1,2} French doctors described it as *ticdouloureux*, due to the presence of facial spasms that could occur.³ The main clinical features were described by the English physician John Fothergill in 1773.² Currently, TN is defined by the International Headache Society as a pain in the hemiface, in shock, brief, limited in one of the most dermatomes of the trigeminal nerve.⁴

The latest Guideline of the European Academy of Neurology 2019⁵ indicates the surgical treatment of TN in cases of clinical refractoriness and consists of neurovascular decompression procedures or percutaneous therapies. These interventions include radiofrequency thermocoagulation, the alcoholization of nerves, and even balloon compression.

The surgical modality chosen for each patient will depend on the surgeon's experience as well as on criteria related to the patient, such as the presence of neurovascular conflict evident in imaging tests, and age (there is a tendency to perform decompression surgeries in younger patients).⁵

Among the options for percutaneous access, radiofrequency rhizotomy has the potential to offer definitive treatment for the disease's typical symptom of pain.¹

Recently, the use of 3D tomography, associated with stereotaxis, has been used to optimize the proposed treatment, considering that 2 to 4% of patients present anatomical variation, making it impossible to access the foramen ovale. The use of this technique enables surgeons to analyze the patient's anatomical characteristics and the relative position of the access.¹

Here we present the case of a 63-year-old patient with TN who presented an anatomical variation that prevented access to the foramen ovale, culminating in the need for a complementary surgical approach.

Case Report

A 63-year-old male patient presented with severe left hemifacial neuropathic pain, shock-like, in paroxysm, triggered by touch and mood changes. The onset of the pain happened about 1 year prior to the appointment, and it got progressively worse. Initially, the patient was treated with 200 mg carbamazepine, 3 times daily, associated with nortriptyline 25 mg for anxiety, with progressive increase in doses, but there was no satisfactory clinical response. Given the intense pain, percutaneous radiofrequency rhizotomy was proposed, considering the patient's age and the comorbidities presented, such as difficult-to-control arterial hypertension associated with anxiety disorder. In this specific case, we had to use general anesthesia because of the anxiety of the patient, in order to do the procedure. The electrode was guided by stereotomography until it reached the Gasser ganglion.

However, percutaneous puncture of the ipsilateral foramen ovale was not successful, with an apparent bone barrier. The patient was subsequently submitted to a computed tomography scan with 3D reconstruction that identified the presence of a pterygoalar bar (complete ossification) in front of the foramen ovale (► **Figure 1**). Therefore, we proposed to use stereotaxy to plan the trajectory for a new puncture attempt.

We proceeded to the positioning of the radiofrequency electrode, guided by stereotomography, with a stereotaxis ring installed 2 cm above the upper orbital rim, with fiducials facing caudally. The path and angle of entry into the foramen ovale was defined using the MNPS software (Mevis Informatica Médica Ltda., São Paulo, SP, Brazil), so that there was no collision with the pterygoalar bar (► **Figure 2**). During the procedure, the mandible was kept open to allow proper positioning (► **Figure 3**). The thermocoagulation electrode was successfully installed in the Meckel cavum, its position was confirmed with

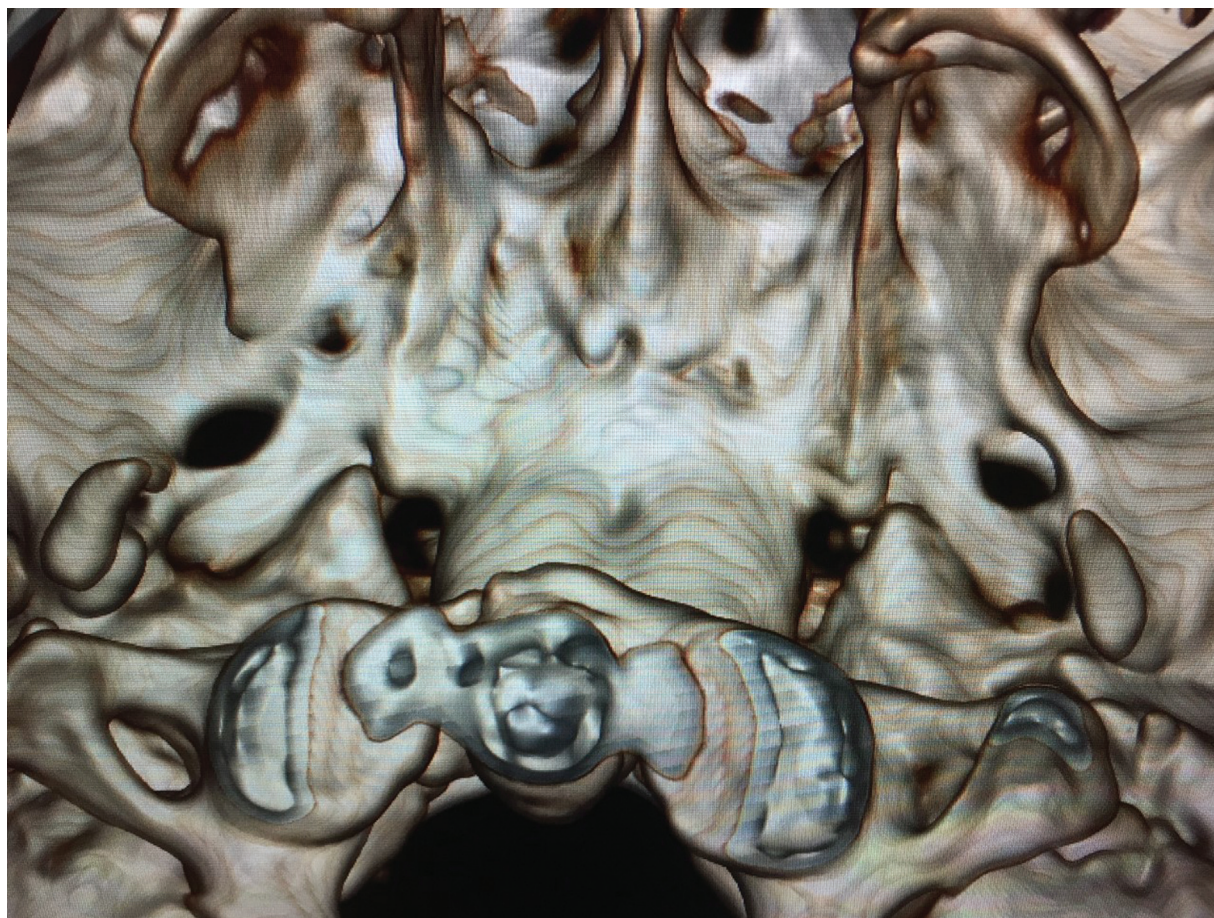


Fig. 1 3D tomographic image, inferior view of the skull revealing the presence of the pterygoalar bar.

radioscopy, and the thermocoagulation of the left Gasser ganglion was performed at a temperature of 60 to 65 degrees for about 60 seconds³ (► **Figure 3**). The patient showed clinical improvement of TN. During the last outpatient review with a 24-month follow-up, he had a Barrow Neurological Institute pain score of III,⁶ and visual analogue scale score of 03/10.

Discussion

Trigeminal neuralgia is a pathology described early in the medical literature, with its first reports going back to the time of Aretaeus of Capadocia. It is defined as paroxysmal pain in one or more branches of the trigeminal nerve, frequently causing pain of great magnitude.⁷

The diagnosis is eminently clinical, and this criterion has been defined by the International Headache Society. Pain attacks are paroxysmal, lasting for fractions of seconds up to 2 minutes in one or more territories of innervation of the trigeminal nerve. The frequency of which can vary from hundreds of attacks per day to years of remission between one crisis and another.^{7,8}

The treatment consists basically of two modalities, clinical and surgical. Anti-seizure drugs are among the most widely used medications, and carbamazepine has control rates of up to 70%.

When there is refractoriness to clinical treatment, or in cases of identified vascular compressions, surgical intervention can be indicated. The most used techniques consist of neurovascular microdecompression and ablative techniques: alcoholization of the peripheral branches of the trigeminal nerve, balloon rhizotomies in addition to electrocoagulation, or radiofrequency thermocoagulation.⁴

Radiofrequency rhizotomy selectively destroys sensory nerve fibers by crushing or applying heat. Pain relief occurs in up to 97% of initial cases and 58% within 5 years, while balloon compression also produces satisfactory results, but they are not long-lasting.

The percutaneous procedure for the treatment of TN was first described by Hartel in 1914.⁹ The surgical technique employed consists of puncture via an ascending anterolateral extra-buccal transoval, guided by fluoroscopy in a lateral sub-vertical position.

Three points of reference are used: 3 cm anterior to the external auditory meatus; the mid-pupillary aspect; and 2.5 to 3 cm lateral to the labial commissure. It is important to emphasize the need to follow a plan parallel to the clivus.⁷

The foramen ovale has a diameter between 4 and 7 mm³ and is located about 2 mm posterior to the pterygoid process.

The rates of failure in puncturing the foramen ovale using fluoroscopy by image intensifier are 0.5 to 4.0%, with an average of 2.7%.¹⁰

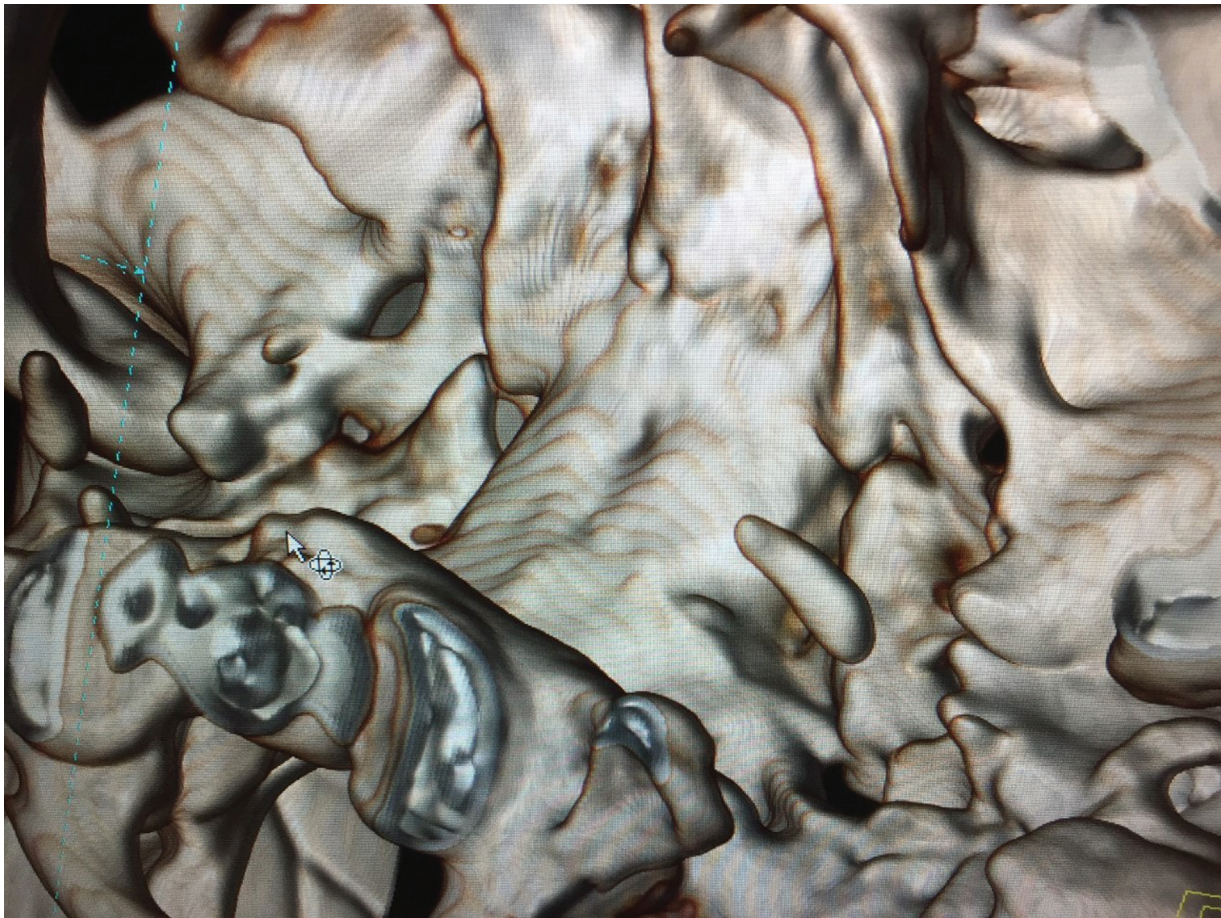


Fig. 2 3D tomographic image, inferior view of the skull, revealing the interposition of the pterygoalar bar in the trajectory to access the foramen ovale.

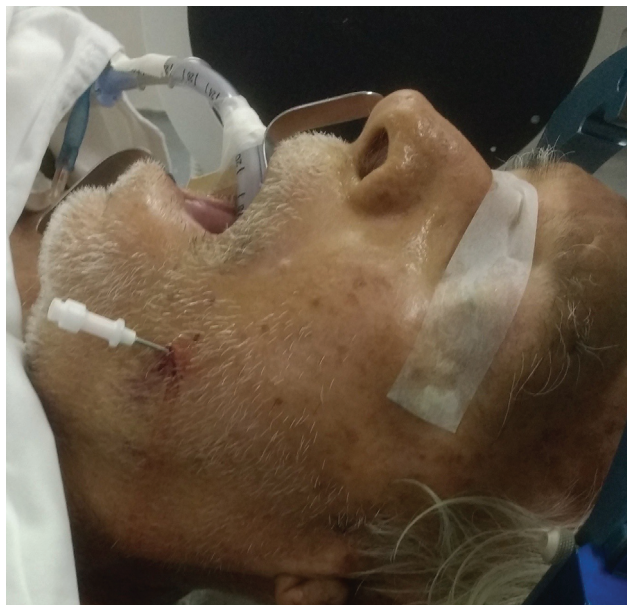

Fig. 3 Demonstrates a more caudal and lateral entry point in relation to the conventional technique.

Such failures may be implicated in technical difficulties, increased surgical time and even inability to perform the procedures.

The complete or incomplete ossification of the pterygoalar ligament (Hyrtl ligament) forms the pterygoalar bar that blocks the passage of the needle towards the foramen ovale.¹¹ It originates at the root of the lateral pterygoid process, extending to the lower surface of the larger sphenoid wing, close to the anterolateral edge of the spinous foramen.¹²

This rare anatomical variation (about 2–4% of the general population) is a barrier, with only a small passage (Hyrtl foramen) of access to the Meckel cavum.

The use of stereotomography or intraoperative tomography for cases of percutaneous rhizotomies appears to be a safe and low-cost methodology involved in the procedure.

Gusmão, in 2004,¹³ had already reported the use of fluoroscopy by computed tomography to perform the puncture of the foramen ovale, in view of the failures to access the foramen. There was a decrease in the attempts to puncture the foramen ovale and in the surgical time.

This case illustrates the importance of adequate anatomical assessment of patients for neurosurgical procedures. Likewise, it demonstrates the importance of mastering the stereotaxic technique in the neurosurgeon's daily practice.

In a literature review through PubMed, 6 articles^{14–19} were found regarding the relationship between the pterygoalar bar and TN, 5 of which are anatomical studies on cadavers, and another study¹⁹ in which a retrospective

analysis of operated cases was performed. We did not find any report of a patient with pterygoal bar and TN who needed to change the proposed approach.

Conclusion

The use of stereotaxy as a planning tool in unusual situations, generated by the presence of anatomical variations such as the presence of the pterygoalar bar, is an excellent alternative. This minimizes the need for additional procedures.

The procedure brings good cost/benefit ratio and satisfactory results as seen in the case described above, being an important neurosurgical apparatus.

Disclosure

The authors have no personal, financial, or institutional interest in any of the drugs, materials, or devices described in this article.

References

- Guo Z, Wu B, Du C, Cheng M, Tian Y. Stereotactic Approach Combined with 3D CT Reconstruction for Difficult-to-Access Foramen Ovale on Radiofrequency Thermocoagulation of the Gasserian Ganglion for Trigeminal Neuralgia. *Pain Med* 2016;17(09):1704–1716
- Sabalys G, et al. Aetiology and Pathogenesis of trigeminal neuralgia: a comprehensive review. <http://www.ejomr.org/JOMR/archives/2012>
- Gybels JM, Sweet WH. Neurosurgical treatment of persistent pain. Basel: Karger; 1989:21
- Nurmikko TJ, Eldridge PR. Trigeminal Neuralgia: Pathophysiology, diagnosis and current treatment. *Br J Anaesth* 2011;107:117–132
- Bendtsen L, Zakrzewska JM, Abbott J, et al. European Academy of Neurology guideline on trigeminal neuralgia. *Eur J Neurol* 2019;26(06):831–849
- LEITE Camila COSTA, Grazielle. Trigeminal neuralgia: peripheral and central mechanisms. *Rev Dor. São Paulo* 2015 oct-dec;16(04):297–301
- Siqueira MG. Tratado de neurocirurgia – 1ed Barueri SP: Manole. Cap 2016;127:1454–1481
- Maarjerg S, Di Stefano G, Bendtsen L, Cruccu G. (2017). Trigeminal neuralgia – diagnosis and treatment. *Cephalalgia* 37(07):648–657 journal.sagepub.com/home/cep
- Peris-Celda M, Graziano F, Russo V, Mericle RA, Ulm AJ. Foramen ovale puncture, lesioning accuracy, and avoiding complications: microsurgical anatomy study with clinical implications. *J Neurosurg* 2013;119(05):1176–1193
- Chen and Lee. The Measurement of Pain in Patient with Trigeminal Neuralgia. *Clinical Neurosurgery*. Vol 0, 2010
- Sol-Ji Ryu1, Min-Kyu Park1, U-Young Lee Hyun-Ho Kwak. Incidence of pterygospinous and pterygoalar bridges in dried skulls of Koreans. *Anat Cell Biol* 2016;49:143–150
- Tubbs RS, May WR Jr, Apaydin N, et al. Ossification of ligaments near the foramen ovale: an anatomic study with potential clinical significance regarding transcutaneous approaches to the skull base. *Neurosurgery* 2009;65(6, Suppl):60–64, discussion 64
- Gusmão, Sebastião; Magaldi, Marcelo; Arantes, Aluizio. Rizotomia trigeminal por radiofrequência para tratamento da neuralgia do trigêmeo: resultados e modificação técnica. *Arq. Neuro-Psiquiatr.*, São Paulo, v. 61, n. 2B, p. 434-440, June 2003
- Rosa RR, Faig-Leite H, Faig-Leite FS, Moraes LC, Moraes ME, Filho EM. Radiographic study of ossification of the pterygospinous and pterygoalar ligaments by the Hirtz axial technique. *Acta Odontol Latinoam* 2010;23(01):63–67
- Daimi SR, Siddiqui AU, Gill SS. Analysis of foramen ovale with special emphasis on pterygoalar bar and pterygoalar foramen. *Folia Morphol (Warsz)* 2011;70(03):149–153
- Natsis, Konstantinos & Piagkou, Maria & Skotsimara, Georgia & Totlis, Trifon & Apostolidis, Stelios & Panagiotopoulos, Nikitas-Apollon & Skandalakis, Panagiotis. (2013). The ossified pterygoalar ligament: An anatomical study with pathological and surgical implications. *Journal of cranio-maxillo-facial surgery: official publication of the European Association for Cranio-Maxillo-Facial Surgery*. 42. Doi: 10.1016/j.jcms.2013.10.003
- B KK, K V. Anatomical Study of Pterygospinous and Pterygoalar Bar in Human Skulls with their Phylogeny and Clinical Significance. *J Clin Diagn Res* 2014;8(09):AC10–AC13. Doi: 10.7860/JCDR/2014/9326.4888
- Elnashar A, Patel SK, Kurbanov A, Zyereva K, Keller JT, & Grande AW. (2019). Comprehensive anatomy of the foramen ovale critical to percutaneous stereotactic radiofrequency rhizotomy: cadaveric study of dry skulls. *Journal of Neurosurgery JNS*. 1–9
- Matys T, Ali T, Zaccagna F, Barone DG, Kirollos RW, & Massoud TF. (2019). Ossification of the pterygoalar and pterygospinous ligaments: a computed tomography analysis of infratemporal fossa anatomical variants relevant to percutaneous trigeminal rhizotomy. *Journal of Neurosurgery JNS*. 1–10.
- B KK, K V. Anatomical Study of Pterygospinous and Pterygoalar Bar in Human Skulls with their Phylogeny and Clinical Significance. *J Clin Diagn Res* 2014;8(09):AC10–AC13