



# Percutaneous Cholecystostomy: A Bridge to Less Morbidity

Anil Kumar Singh<sup>1</sup>

<sup>1</sup>Department of Radiodiagnosis, Sanjay Gandhi Postgraduate Institute of Medical Sciences, Lucknow, Uttar Pradesh, India

Address for correspondence Anil Kumar Singh, MD, DNB, PDCC, Department of Radiodiagnosis, Sanjay Gandhi Postgraduate Institute of Medical Sciences, Lucknow 226014, Uttar Pradesh, India (e-mail: singh.anil.kr01@gmail.com).

Arab J Intervent Radiol 2022;6:3–9.

## Abstract

Percutaneous cholecystostomy (PC) is a minimally invasive procedure for decompressing gall bladder (GB) or biliary system in emergency settings, performed in patients with GB or biliary diseases who are at high risk for surgical exploration. Indications range from acute cholecystitis in seriously ill patients to overdilated GB with impending perforation to overt GB perforation. This procedure, by allowing biliary drainage, helps in controlling the infection and optimizing the patient's condition for definitive treatment in the form of elective surgery if possible, thus acting as a bridge to a definitive treatment option. In some cases, such as acute acalculous cholecystitis, it may obviate the need for surgery, and in malignant biliary obstruction, it may be used as a palliative measure to keep GB decompressed. This review article focuses on and revisits many aspects of PC including technical aspects, clinical indications, outcomes, and safety of the procedure, in addition to its role as bridge therapy versus definitive therapy versus palliative option. It includes observations based on the author's own work experience and review of the literature.

## Keywords

- ▶ biliary system
- ▶ cholecystectomy
- ▶ cholecystitis
- ▶ computer tomography
- ▶ gall bladder perforation
- ▶ percutaneous cholecystostomy

## Introduction

Percutaneous cholecystostomy (PC) is a well-established minimally invasive procedure for decompressing gall bladder (GB) or biliary system in acute emergency settings where the patient's general condition is not optimal for surgical exploration. This procedure is performed in seriously ill patients suffering from acute cholecystitis (both calculous and acalculous) with or without impending GB perforation, biliary tract malignancy with overdilated GB/impending GB perforation, or in patients presenting with GB perforation.<sup>1–5</sup> Clinically, these patients present with right upper quadrant pain or diffuse abdominal pain, tenderness, lumpiness, and fever, with or without hemodynamic instability. Ultrasonography (USG), in the majority of situations, enables the radiological diagnosis of acute cholecystitis, overdis-

tended GB, or perforation/impending perforation, with computer tomography (CT) and magnetic resonance imaging (MRI) done for complex cases or further evaluation. USG and fluoroscopy are commonly used for guiding PC in cases where indicated.

In this article, technical aspects, clinical indications, outcomes, and safety of PC are being revisited and discussed. Also, under review and discussion is its role as bridge therapy versus definitive therapy versus palliative option. Observations are based on the author's own work experience and review of the literature.

## Percutaneous Cholecystostomy

PC for obstructive jaundice was first described in 1979, whereas for acute cholecystitis, it was first introduced in

published online  
April 20, 2022

DOI <https://doi.org/10.1055/s-0042-1744213>.  
ISSN 2542-7075.

© 2022. The Pan Arab Interventional Radiology Society. All rights reserved.

This is an open access article published by Thieme under the terms of the Creative Commons Attribution-NonDerivative-NonCommercial-License, permitting copying and reproduction so long as the original work is given appropriate credit. Contents may not be used for commercial purposes, or adapted, remixed, transformed or built upon. (<https://creativecommons.org/licenses/by-nc-nd/4.0/>)

Thieme Medical and Scientific Publishers Pvt. Ltd., A-12, 2nd Floor, Sector 2, Noida-201301 UP, India

1980.<sup>1-4</sup> Since then, PC has gained acceptance as a temporary treatment option for acute cholecystitis in poor surgical candidates where it helps in stabilizing and enabling patients for elective surgery as a definitive treatment option. Many studies have reported less morbidity in patients undergoing post-drainage elective cholecystectomy than those undergoing emergency surgeries.<sup>6-8</sup>

In patients who cannot undergo surgery even after PC (e.g., unresectable GB or biliary tract malignancies and critically ill patient not fit for surgery), a catheter can be left in place as a palliative measure with replacement at intervals or a catheter can be removed if there is no output and GB remains undistended. In patients with acute acalculous cholecystitis and no biliary obstruction, a catheter can be removed once the patient's clinical condition has improved and stabilized.

Over the years, there have been many advances in the technical aspect and clinical applications of PC. PC is now also a well-established bridge treatment option for type-2 GB perforation as detailed below. This procedure has been also included in revised 2013 Tokyo Guidelines as the management option for acute cholecystitis and cholangitis.<sup>9</sup>

### Pre-Procedure Imaging Work Up and Diagnosis

Imaging studies in GB diseases not only help in making diagnosis but also help in deciding treatment plan and follow-up. As far as PC is concerned, imaging studies facilitate decisions regarding access to GB (transhepatic vs. transomental route) and modality of image guidance (USG and fluoroscopic guidance or CT guidance).

Ultrasound, contrast-enhanced CT (CECT) and magnetic resonance cholangiopancreatography (MRCP) are imaging modalities commonly used in the assessment of biliary pathologies. USG has become the first imaging modality to be done in these cases. Thickened edematous wall (>3.0 mm) with pericholecystic edema is the characteristic of acute cholecystitis. Associated calculi are easily detected by USG. In patients with complicated cholecystitis, interface with liver may be ill-defined. There may also be areas of mural thinning indicating impending perforation. Largest GB diameter >4.5 cm indicates overdistended GB. The presence of pericholecystic abscess or intrahepatic collection near GB fossa indicates type-2 GB perforation (►Fig. 1A). Type-1 GB perforation is accompanied by free intraperitoneal fluid which is easily detected on USG. Type-3 (fistulous) GB perforation can be missed on USG or it can be suspected on the basis of its adhesion to bowel wall which needs further evaluation by CECT. CECT is done for comprehensive and detailed evaluation: GB wall thickening and defect/perforation, extent of inflammatory changes, involvement of liver, relationship with bowel, and underlying diseases (►Fig. 3A-B). In some cases such as emphysematous cholecystitis, CT can easily depict the presence of air in GB wall or lumen. However, radiolucent calculi are frequently missed at CT. MRCP also shows GB wall defect, underlying calculi, GB neck obstruction, and biliary anatomy. MRCP combined with contrast-enhanced MRI provides complete imaging evaluation, obviating need for CECT.<sup>1,9-11</sup>

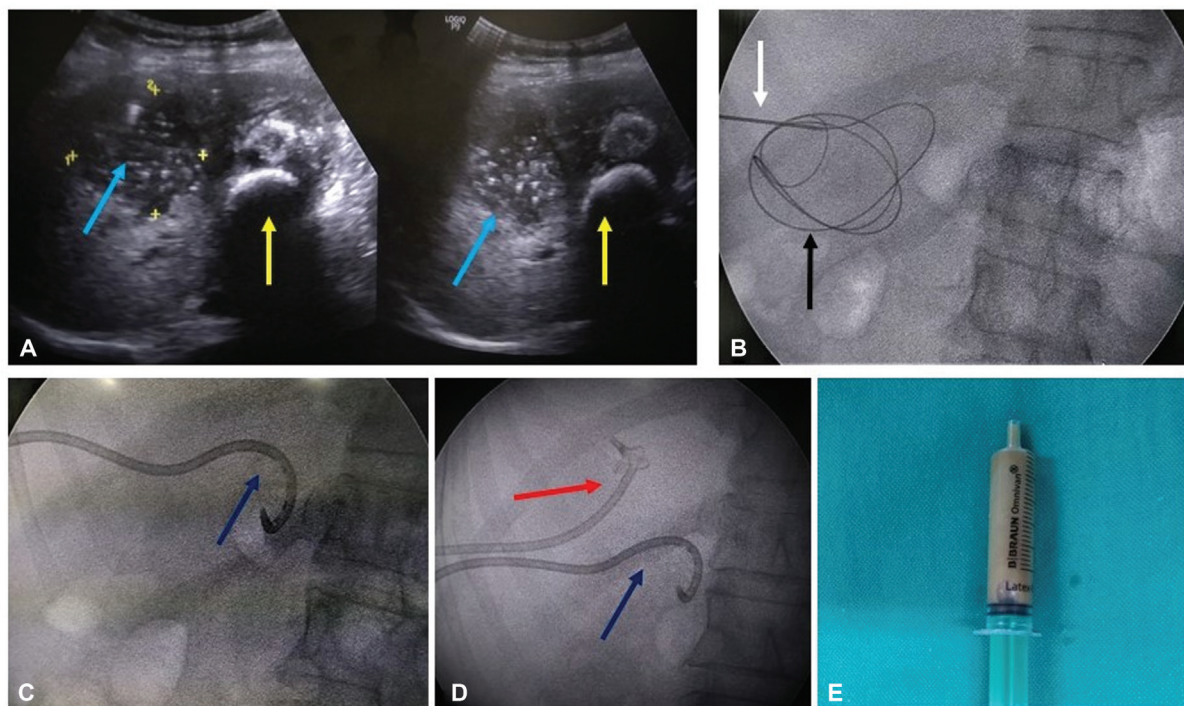
### Technical Aspects of PC

This is a minimally invasive procedure done under imaging guidance (USG, fluoroscopy, and less commonly CT guidance). PC catheter can be placed by using a single step trocar technique or a safer multistep Seldinger technique. The trocar technique employs placement using the preloaded triaxial needle, cannula, and catheter system where after gaining access to the desired location needle and cannula are taken out and a catheter is left in the place. In the multistep Seldinger technique, initially, access is gained by using a needle, sequentially followed by the placement of guidewire, tract dilatation, and placement of catheter over the guidewire—once the catheter is in GB lumen, wire is removed and the catheter is secured.<sup>1,4-7,9,10,12</sup>

At our center, the procedure of PC is done under combined USG and fluoroscopic guidance and using the Seldinger technique, preferably via the transhepatic route. It is usually performed under local anesthesia and, in some patients, under IV sedation. Under USG guidance, access is gained into GB lumen using an 18G needle via which a soft J-tip 0.035 inch guidewire is placed in GB lumen. (Sometimes, initial access is gained using a micro-puncture set which comes with a 22G fine needle, 0.018 inch guidewire, triaxial access system of stiffening cannula, introducer & 6 Fr sheath. After successful puncture with a fine needle, the access system is advanced over the wire, and once it reaches GB lumen, stiffener and introducer are taken out, and a 0.035 inch guidewire is placed via 6Fr sheath into GB lumen.) Guidewire manipulations and further steps are done mainly under fluoroscopic guidance. Once the guidewire is well secured in GB lumen, the needle (or sheath) is exchanged for dilator. After dilating the access tract, an 8 or 10 Fr catheter, preferably locking loop catheter, is placed in GB lumen (►Fig. 1B-D; 3C-E). If a patient cannot afford this catheter, a simple pigtail or malecot catheter can also be used. Later, under fluoroscopic guidance, cholecystography can be performed to look for the patency of cystic duct and CBD (►Fig. 2A-B). The catheter is left in situ till drain output is there, and usually, it is removed at the time of surgery. A PC catheter might have to be left for a longer period if there is persistent drain output as for cases with biliary obstruction unfit for surgery. In meta-analysis by Macchini et al, the timing of the drain removal ranged from 2 to 193 days, and there was no correlation between length of tube maintenance and the considered outcomes.<sup>13</sup>

The procedure can be also performed under USG guidance only as a bedside procedure in situations where patients cannot be shifted as may be with the ICU setting. Uncommonly, it is performed under CT guidance. CT guidance is required where GB is collapsed or poorly visualized on ultrasound.<sup>1,4,9,12,14</sup>

*Single time aspiration of contents from GB* has also been described in patients with acute cholecystitis, but it might have to be repeated.<sup>14,15</sup> This can also be done in cases of biliary tract malignancies where GB remains overdistended or patient develops cholecystitis despite percutaneous transhepatic biliary drainage (PTBD) or stenting; however, reaccumulation will need PC catheter placement, and in case of

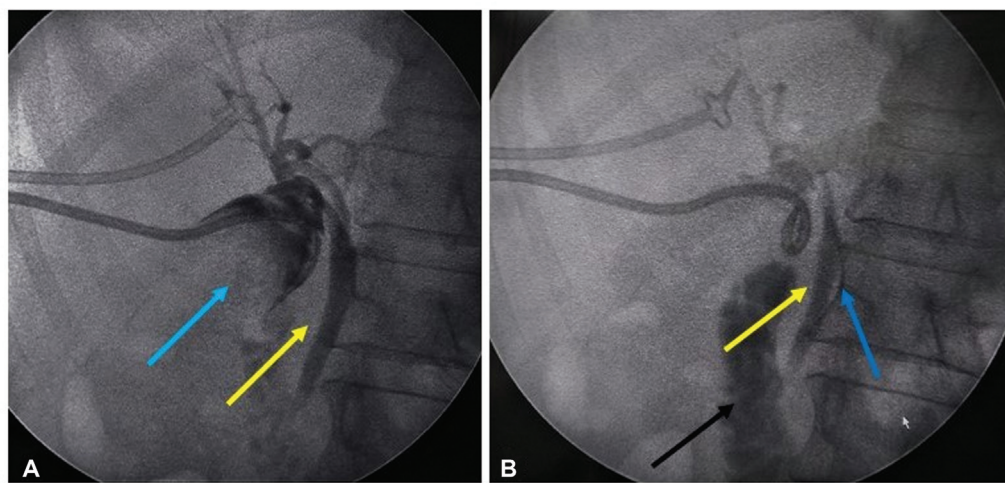


**Fig. 1** PC and PCD performed in a 60 years female patient with calculous cholecystitis with intrahepatic GB perforation (type-II GBP). (A) Ultrasound images showing collapsed gallbladder filled with calculi (yellow arrow), irregular GB wall thickening, ill-defined interface with liver, and heterogeneous fluid collection/abscess in liver adjoining GB fossa (light blue arrow); contents surrounding GB calculi are the same as in liver collection. (B) Fluoroscopy images showing an 18G access needle (Vygon) (white arrow) and well-secured 0.035 inch hydrophilic guidewire (Terumo Corporation) (black arrow) in GB lumen, (C) 10.2 Fr locking loop catheter (Cook Medical) in GB lumen (dark blue arrow), along with (D) the PCD catheter (10Fr malecot catheter, Devon Innovations) placed in liver abscess (red arrow). (E) Purulent aspirate from liver.

persistent catheter drainage, chemical ablation of GB can be done.<sup>16</sup> In case of failed single time GB aspiration in post-stenting cases, the option of endoscopic ultrasonography-guided biliary drainage by placing a plastic or metal stent between GB and duodenum is also being explored.<sup>17</sup>

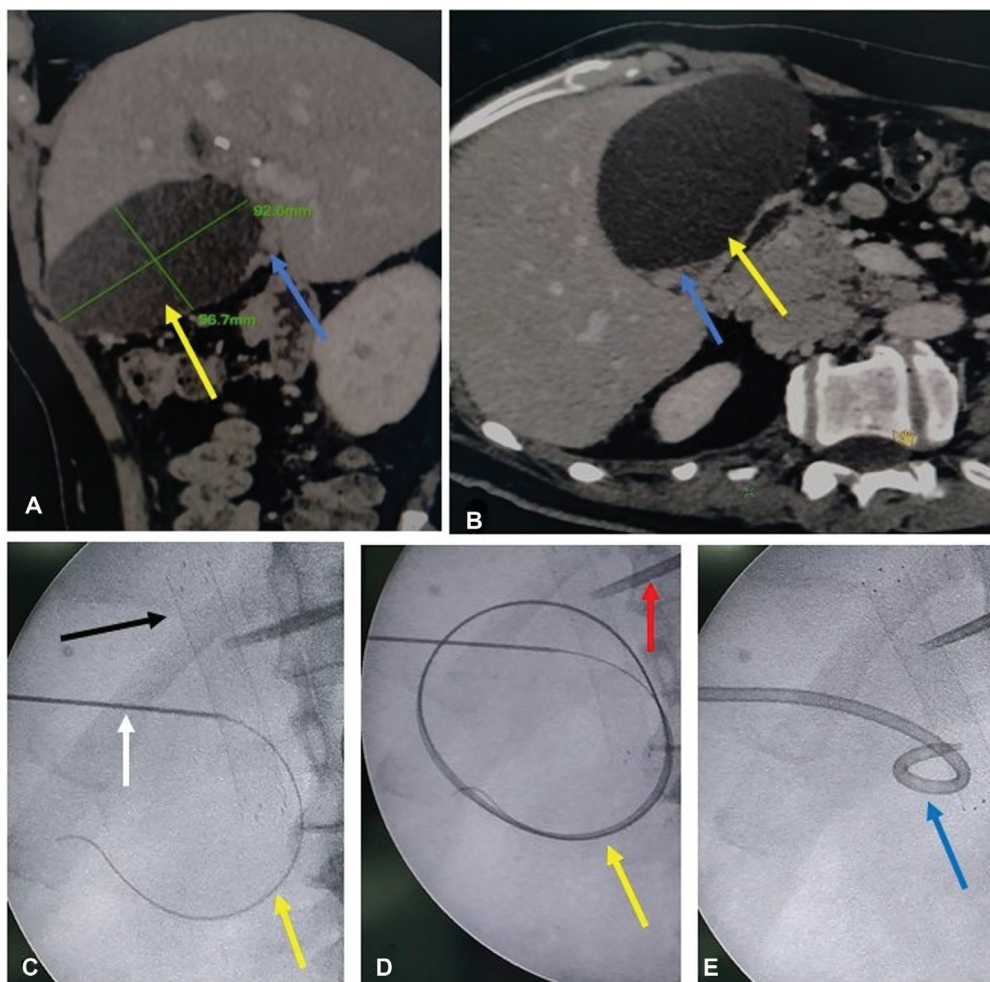
*Transhepatic versus Transperitoneal route for PC:* Transhepatic route is preferred for catheter stability and to prevent

pericatheter leakage into the peritoneal cavity. Chances of interfering with bowel are also less with the transhepatic route. It also allows rapid formation of fibrin sheath and tract maturation. The disadvantage of this route is bleeding/hemobilia; however, significant bleeding is uncommon. The transperitoneal route is taken only when the transhepatic route is not possible, as there are associated risks of interfering



**Fig. 2** Same patient as in Fig. 1. Cholecystography performed after drainage. (A and B) Post-drainage cholecystogram showing filling defects with “meniscus sign” (light blue arrow) corresponding to calculi in GB, with the catheter tip in the GB neck region. Patent CBD (yellow arrow) with low insertion of cystic duct (blue arrow) noted. Few weeks later, with an improved general condition of patient, subtotal cholecystectomy was done.





**Fig. 3** Percutaneous cholecystostomy (PC) performed in a 65 years male patient with metastatic carcinoma GB neck, who after undergoing biliary stenting, was having right upper quadrant pain in the region of overdistended GB. Initially, the patient was treated with single time aspiration from gall bladder. Post-aspiration, the patient's pain was relieved. However, in the view of reaccumulation of contents and overdistension of GB, PC catheter was placed. (A) Oblique sagittal and (B) axial reformatted CT images prior to stent placement showing GB neck lesion (blue arrow) with overdistended GB (yellow arrow). (C) Fluoroscopic images showing 18G access needle (Vygon) (white arrow) and 0.035 inch guidewire (Terumo Corporation) (yellow arrow) in GB lumen, (D) secured guidewire forming large loop in overdistended GB lumen (yellow arrow) and (E) 10.2 Fr locking loop catheter (Cook Medical) in GB. 10 mm diameter suprapapillary biliary stent (SEMS) in situ (black arrow). Also noted external biliary drainage catheter for isolated segment-III hepatic duct (red arrow). Later, in view of persistent output from PC catheter, two sessions of ethanol ablation were done for gall bladder resulting in decreased output; with few more ablation sessions planned and pending before considering removal of PC catheter.

with bowel loops, pericatheter leakage, and lesser catheter stability. Chances of hemorrhagic complications are less.<sup>1,9-12</sup> However, Beland et al, in their retrospective study, found no significant difference in the frequency of complications between PC catheters placed via transhepatic versus transperitoneal routes and leave the choice of route on the discretion of performing interventional radiologist and anatomy of patients. There was a significant difference in the average catheter size placed by two routes, 8.5Fr for the transperitoneal route and 10Fr for the transhepatic route. There were also certain limitations in their study.<sup>4</sup> However, for long time, the transhepatic route has been considered safer and preferred over the transperitoneal route. If more studies come with observations like those by Beland et al, this preference pattern might change.

There is no absolute contraindication to PC. The major contraindication is coagulopathy. In such cases, the procedure can be performed after the correction of coagulopathy: International Normalized Ratio (INR) should be <1.5 and platelet count should be >50,000/mL.<sup>9</sup>

High technical and clinical success rates have been described for PC. Reported technical and clinical success rate for percutaneous cholecystostomy (PC) is high (>90%).<sup>1,9,16,17</sup> Complications are uncommon. The main concerning complication is major bleeding requiring transfusion and further hemostatic management. This kind of complication is rare. Spontaneously resolving minor bleeding is seen in some cases, usually as the hemorrhagic stain of GB contents/bile initially, which becomes clearer within the short span of time the same day. Pericatheter leakage is an issue with

transperitoneal PCC, and if significant, it requires the placement of percutaneous drainage (PCD) catheter in peritoneal collection. In some cases, catheter dislodgment may occur, especially if the non-locking catheter is used. Sepsis usually results from the aggravation of pre-existing biliary infection due to instrumentation and is managed with antibiotic therapy (majority of patients already receiving antibiotic therapy), other medications, and drainage. Pneumothorax and bowel injuries are described but rare complications.<sup>1,4,9</sup>

Vagal hypotension has been also reported, which is managed conservatively with fluid support and medicines.<sup>5</sup> However, it seems quite uncommon at our center.

### Clinical Indications

Indications included for percutaneous cholecystitis are acute cholecystitis with or without impending perforation, acute cholangitis, overdistended GB in biliary tract malignancy, and GB perforation.

### Acute Cholecystitis

In settings of both calculous or acalculous acute cholecystitis where surgery has to be deferred or cannot be done due to medical reasons including a poor general condition of patient, PC provides a minimally invasive option to tide over acute crisis. These patients may also have overdistended GB/empyema GB with impending perforation as in cases of gangrenous or emphysematous cholecystitis. By allowing the drainage of bile which is often infected, along with supportive treatment in the form of IV fluids/electrolytes, antibiotics, and other medications, PC helps stabilize the patient and prepare/optimize them for surgery. In some patients, especially those with acalculous cholecystitis, PC alone may be sufficient and surgery may not be required. PC also provides a conduit for the removal of stones (→ **Figs. 1A-E, 2A-B**).

van Overhagen et al reported PC to be a safe and effective procedure for patients with acute cholecystitis and high surgical risks and to be considered as definitive therapy for most patients with acalculous cholecystitis and as a temporizing treatment option in calculous disease before definitive treatment.<sup>12</sup>

Hatzidakis et al in their study, regarding PC versus conservative treatment in high-risk acute cholecystitis patients, concluded that PC might be suggested to patients not presenting clinical improvement following 3 days of conservative treatment, to critically ill intensive care unit patients, or to candidates for percutaneous cholecystolithotripsy.<sup>18</sup>

Akyürek et al compared early PC followed by early cholecystectomy against medical treatment and delayed cholecystectomy in 70 high-risk patients (ASA grade II-IV), concluding that the PC and early cholecystectomy group benefited from a significantly shorter hospital stay and time to symptomatic improvement. There was no significant difference in postoperative complications between the groups.<sup>19</sup>

Polistina et al in their study of PC in severe cholecystitis concluded PC to be a valuable tool in the management of severe acute cholecystitis. Grade III acute cholecystitis was diagnosed according to the Tokyo Guidelines 2013. In their study, indications for PC included the failure of optimal

medical treatment within 48 hours, worsening of the clinical condition within early medical treatment, patients unfit for upfront surgery, and patient's preference. Ascites was considered a contraindication to PC, while coagulopathy was considered a minor contraindication.<sup>20</sup> In general, ascites is a relative contraindication and percutaneous biliary interventions can be performed after the drainage of ascites.<sup>9</sup>

Başaran et al concluded ultrasound-guided PC to be a relatively safe and easy method for treating acute cholecystitis in critically ill patients, with a low risk of complications and high likelihood of success.<sup>21</sup>

Atar et al conducted a study regarding the outcome of PC in critically ill patients with acute cholecystitis. Their study included 71 patients with calculous cholecystitis and 10 with acalculous cholecystitis. In all cases, the PC drain was successfully inserted with no immediate major procedural complications. They concluded early percutaneous GB drainage to be safe and effective in critically ill patients in the acute phase of cholecystitis, with a high technical success rate, and surgical outcomes in survivors to be better than those reported in patients treated without drainage. Bile duct stones can be eliminated without creating additional access.<sup>8</sup>

Yeo et al concluded PC to be safe and effective in the treatment of acute cholecystitis, with prompt PC to improve survival in high-risk surgical patients. They also reported mortality to be associated with severity of comorbidity, and patients with lesser comorbidity likely to receive eventual cholecystectomy.<sup>22</sup>

Cha et al in their single-center study concluded that PC without additional cholecystectomy might be the best definitive management in high-risk surgical patients.<sup>23</sup>

In CHOCOLATE trial, authors concluded laparoscopic cholecystectomy compared with percutaneous catheter drainage reduced the rate of major complications in high-risk patients with acute cholecystitis. However, this study included patients who underwent PC not followed interval elective cholecystectomy. These authors also agreed with short-term benefits of PC in high-risk patients as reported in earlier literature and advocate PC to be followed by elective cholecystectomy in all or at least in those who are more likely to develop recurrent gall stone-related symptoms.<sup>24</sup>

Jung and Park conducted a study focusing on the optimal timing of cholecystectomy after PC. In their study, patients were divided into two groups by the operation timing—those who underwent cholecystectomy within 10 days of PC and those who underwent cholecystectomy at more than 10 days after PC. They found the timing of laparoscopic cholecystectomy after PC did not affect postoperative outcomes; however, late surgery caused more complications related to cholecystostomy such as catheter dislodgment. Therefore, they advocate early laparoscopic cholecystectomy after PC catheter placement.<sup>25</sup>

Issue regarding the timing of laparoscopic cholecystectomy after PC has been also discussed in Tokyo Guidelines 2018 but no consensus could be made.<sup>26</sup>

### Acute Cholangitis

Acute cholangitis is also a serious life-threatening illness with the potential to cause hemodynamic disturbances and

septic shock. These patients usually have some sort of biliary obstruction such as calculi, strictures, or mass. This clinical condition, apart from medical management, also requires biliary drainage which is usually performed in the form of endoscopic retrograde cholangiopancreatography (ERCP) or PTBD before definitive therapy. However, in some cases, ERCP or PTBD may not be successful. In these cases, PC provides an alternative method of biliary drainage.

Li et al in their study regarding the role of PC for high-risk patients with acute cholangitis found 100% technical success rate for PC with no procedure-related mortality. They concluded PC to be an effective treatment for acute cholangitis in high-risk elderly patients; particularly valuable as a temporizing measure before definitive treatment in critical patients or as salvage therapy where other methods such as ERCP/PTBD failed.<sup>27</sup>

### Overdistended GB in Malignant Biliary Obstruction

In GB neck/biliary tract malignancies, GB may remain overdistended despite PTBD/biliary stenting.<sup>14,15</sup> These patients can present with pain in right upper quadrant in characteristic location or even with features of cholecystitis if GB is infected. PC is needed in these patients to decompress the GB to prevent GB perforation and to achieve relief from symptoms. In patients with unresectable disease with GB neck or cystic duct obstruction, PC is the only well-established option to decompress the GB and prevent serious complications such as perforation (► Fig. 3A-E). PC catheter is removed when output is nil. In some cases, catheter output may be persistent. Chemical ablation via PC has been tried in such cases.<sup>14</sup> In cases with resectable disease, the catheter can be removed when output is nil or at the time of surgery.

Also, in cases of malignant biliary obstruction where PTBD or ERCP is not possible due to some reason such as anatomical considerations or body habitus, PC can be used for biliary decompression. Biliary stenting via PC access has also been reported.<sup>28</sup>

Chung et al in their study focusing on applications of PC other than acute cholecystitis concluded PC to be a palliative procedure to achieve effective biliary decompression in patients with advanced malignancy, with high success and low complication rate.<sup>29</sup>

### GB Perforation

GB perforation is a serious clinical condition seen as a complication of different types of cholecystitis or less commonly malignant GB neck obstruction. GB perforation can be contained and localized to GB fossa, ruptured into liver, or it can lead to peritoneal contamination with bile and biliary peritonitis. Niemeier classified GBP into three types: type 1 or acute: free GB perforation and generalized biliary peritonitis; type 2 or subacute: pericholecystic abscess and localized peritonitis; and type 3 or chronic: cholecystoenteric fistula.<sup>17,30</sup> A variant of type 3 was reported by Anderson and Nazem in the form of cholecystobiliary fistula and termed as type 4 GBP.<sup>31</sup> However, fistula-type GB perforations have been included in type 3 for simplification.

These patients are usually known cases of cholelithiasis, GB Malignancy, critical illness, or sometimes presenting directly with GB perforation. Clinically, they present with abdominal pain with or without distension, fever, nausea, and vomiting. Abdominal examination may reveal tenderness in right upper quadrant or features of generalized peritonitis, such as diffuse abdominal tenderness, rigidity, and guarding. Laboratory investigations reveal elevated total leukocyte count. Depending on the severity, patients may also have elevated inflammatory/sepsis markers such as erythrocyte sedimentation rate, C-reactive protein, and procalcitonin.<sup>17</sup>

For patients with GB perforation, definitive treatment is cholecystectomy. However, in many cases, upfront surgery may not be possible due to poor general condition and hemodynamic instability. PC has become an accepted bridge treatment option to manage the phase of acute crisis and stabilize the patient, allowing definitive treatment in the form of cholecystectomy to be done at later date with lower morbidity. Also, if the patient has intrahepatic or peritoneal extension, the PCD catheter needs to be placed in respective locations to optimize drainage and minimize morbidity (► Fig. 1A-E).

In the literature, the emphasis of percutaneous drainage in cases of GB perforation has been mainly on type-2 perforation. For cases with type-1 GBP, upfront urgent cholecystectomy with peritoneal lavage is still the preferred option. Percutaneous drainage, however, remains a treatment option in these patients also.<sup>17,32-35</sup> Type-3 GBP cases are usually managed by surgical interventions with cholecystectomy and fistulectomy/fistula repair being definitive treatment.<sup>34,35</sup>

Abusedera et al in their study concluded PC to be a safe and effective treatment option in localized GB perforation, such as type-2 perforation, especially in patients not fit for surgery. They also found this method to be highly associated with favorable outcomes. In their study, transhepatic cholecystostomy was done in all critically ill and poor surgical candidates of GBP type 2 ( $n = 10$ ); additional catheter placement was required for drainage of subhepatic abscesses and liver abscesses.<sup>32</sup>

In a study by Date et al, for patients with GBP type 2, radiological drainage was found to be a valuable alternative to surgery in emergent situations for patients unfit or unwilling for surgery.<sup>33</sup>

### Conclusion

PC is a safe and minimally invasive procedure offered by interventional radiology to tide over the phase of acute crisis in the management of high-risk patients with acute cholecystitis, impending GB perforation, or already happened GB perforation, serving as a bridge to surgery or even obviating the need for surgery in some cases. With drainage, it helps in controlling the infection and, thus, allows time to stabilize and optimize patients for further management, making overall and operative morbidity less severe.



**Author's Contribution**

A.K.S. contributed to interventional radiology procedures, conceptualization of research topic, literature review and analysis, manuscript preparation, and review.

**Funding**

None.

**Conflict of Interest**

None declared.

**References**

- Little MW, Briggs JH, Tapping CR, et al. Percutaneous cholecystostomy: the radiologist's role in treating acute cholecystitis. *Clin Radiol* 2013;68(07):654–660
- Elyaderani M, Gabriele OF. Percutaneous cholecystostomy and cholangiography in patients with obstructive jaundice. *Radiology* 1979;130(03):601–602
- Radder RW. Ultrasonically guided percutaneous catheter drainage for gallbladder empyema. *Diagn Imaging* 1980;49(06):330–333
- Beland MD, Patel L, Ahn SH, Grand DJ. Image-guided cholecystostomy tube placement: short- and long-term outcomes of transhepatic versus transperitoneal placement. *Am J Roentgenol* 2019;212(01):201–204
- vanSonnenberg E, Casola G, Varney RR, et al. Interventional radiology in the gallbladder. *Radiographics* 1989;9(01):39–49
- Huber DF, Martin EW Jr, Cooperman M. Cholecystectomy in elderly patients. *Am J Surg* 1983;146(06):719–722
- To KB, Cherry-Bukowiec JR, Englesbe MJ, et al. Emergent versus elective cholecystectomy: conversion rates and outcomes. *Surg Infect (Larchmt)* 2013;14(06):512–519
- Atar E, Bachar GN, Berlin S, et al. Percutaneous cholecystostomy in critically ill patients with acute cholecystitis: complications and late outcome. *Clin Radiol* 2014;69(06):e247–e252
- Gulaya K, Desai SS, Sato K. Percutaneous cholecystostomy: evidence-based current clinical practice. *Semin Intervent Radiol* 2016;33(04):291–296
- Sato KT. Percutaneous management of biliary emergencies. *Semin Intervent Radiol* 2006;23(03):249–257
- Derici H, Kara C, Bozdogan AD, Nazli O, Tansug T, Akca E. Diagnosis and treatment of gallbladder perforation. *World J Gastroenterol* 2006;12(48):7832–7836
- van Overhagen H, Meyers H, Tilanus HW, Jeekel J, Laméris JS. Percutaneous cholecystostomy for patients with acute cholecystitis and an increased surgical risk. *Cardiovasc Intervent Radiol* 1996;19(02):72–76
- Macchini D, Degrate L, Oldani M, et al. Timing of percutaneous cholecystostomy tube removal: systematic review. *Minerva Chir* 2016;71(06):415–426
- Currò G, Cucinotta E. Percutaneous gall bladder aspiration as an alternative to laparoscopic cholecystectomy in Child-Pugh C cirrhotic patients with acute cholecystitis. *Gut* 2006;55(06):898–899
- Haas I, Lahat E, Griton Y, et al. Percutaneous aspiration of the gall bladder for the treatment of acute cholecystitis: a prospective study. *Surg Endosc* 2016;30(05):1948–1951
- Lee TH, Park SH, Kim SP, et al. Chemical ablation of the gallbladder using alcohol in cholecystitis after palliative biliary stenting. *World J Gastroenterol* 2009;15(16):2041–2043
- Kozakai F, Kanno Y, Ito K, et al. Endoscopic ultrasonography-guided gallbladder drainage as a treatment option for acute cholecystitis after metal stent placement in malignant biliary strictures. *Clin Endosc* 2019;52(03):262–268
- Hatzidakis AA, Prassopoulos P, Petinarakis I, et al. Acute cholecystitis in high-risk patients: percutaneous cholecystostomy vs conservative treatment. *Eur Radiol* 2002;12(07):1778–1784
- Akyürek N, Salman B, Yüksel O, et al. Management of acute calculous cholecystitis in high-risk patients: percutaneous cholecystostomy followed by early laparoscopic cholecystectomy. *Surg Laparosc Endosc Percutan Tech* 2005;15(06):315–320
- Polistina F, Mazzucco C, Coco D, Frego M. Percutaneous cholecystostomy for severe (Tokyo 2013 stage III) acute cholecystitis. *Eur J Trauma Emerg Surg* 2019;45(02):329–336
- Başaran O, Yavuzer N, Selçuk H, Harman A, Karakayali H, Bilgin N. Ultrasound-guided percutaneous cholecystostomy for acute cholecystitis in critically ill patients: one center's experience. *Turk J Gastroenterol* 2005;16(03):134–137
- Yeo CS, Tay VW, Low JK, Woon WW, Punamiya SJ, Shelat VG. Outcomes of percutaneous cholecystostomy and predictors of eventual cholecystectomy. *J Hepatobiliary Pancreat Sci* 2016;23(01):65–73
- Cha BH, Song HH, Kim YN, et al. Percutaneous cholecystostomy is appropriate as definitive treatment for acute cholecystitis in critically ill patients: a single center, cross-sectional study. *Korean J Gastroenterol* 2014;63(01):32–38
- Loozen CS, van Santvoort HC, van Duijvendijk P, et al. Laparoscopic cholecystectomy versus percutaneous catheter drainage for acute cholecystitis in high risk patients (CHOCOLATE): multicentre randomised clinical trial. *BMJ* 2018;363:k3965
- Jung WH, Park DE. Timing of cholecystectomy after percutaneous cholecystostomy for acute cholecystitis. *Korean J Gastroenterol* 2015;66(04):209–214
- Yokoe M, Hata J, Takada T, et al. Tokyo Guidelines 2018: diagnostic criteria and severity grading of acute cholecystitis (with videos). *J Hepatobiliary Pancreat Sci* 2018;25(01):41–54
- Li YL, Wong KH, Chiu KW, et al. Percutaneous cholecystostomy for high-risk patients with acute cholangitis. *Medicine (Baltimore)* 2018;97(19):e0735
- Harding J, Mortimer A, Kelly M, Loveday E. Interval biliary stent placement via percutaneous ultrasound guided cholecystostomy: another approach to palliative treatment in malignant biliary tract obstruction. *Cardiovasc Intervent Radiol* 2010;33(06):1262–1265
- Chung HY, Hsu CC, Hung YL, et al. Alternative application of percutaneous cholecystostomy in patients with biliary obstruction. *Abdom Radiol (NY)* 2021;46(06):2891–2899
- Niemeier OW. Acute free perforation of the gall bladder. *Ann Surg* 1934;99(06):922–924
- Anderson BB, Nazem A. Perforations of the gallbladder and cholecystobiliary fistulae: a review of management and a new classification. *J Natl Med Assoc* 1987;79(04):393–399
- Abusedera MA, Khalil M, Hassan AEMA. Surgical and non-surgical treatment of non-traumatic gallbladder perforation. *Egypt J Radiol Nucl Med* 2017;48:43–49
- Date RS, Thrumurthy SG, Whiteside S, et al. Gallbladder perforation: case series and systematic review. *Int J Surg* 2012;10(02):63–68
- Patel G, Jain A, Kumar RB, Singh N, Karim T, Mishra R. Gallbladder perforation: a prospective study of its divergent appearance and management. *Euroasian J Hepatogastroenterol* 2019;9(01):14–19
- Singh G, Merali N, Shirol S, Drymoussis P, Singh S, Veeramootoo D. A case report and review of the literature of Bouveret syndrome. *Ann R Coll Surg Engl* 2020;102(01):e15–e19