

Acute hemorrhagic encephalitis: An unusual presentation of dengue viral infection

Jeyaseelan Nadarajah, Kumble Seetharama Madhusudhan, Ajay Kumar Yadav, Arun Kumar Gupta, Naval Kishore Vikram¹

Departments of Radiodiagnosis and ¹Medicine, All India Institute of Medical Sciences (AIIMS), New Delhi, India

Correspondence: Dr. K S Madhusudhan, Department of Radiodiagnosis, All India Institute of Medical Sciences (AIIMS), New Delhi - 110 029, India. E-mail: drmadhuks@gmail.com

Abstract

Dengue is a common viral infection worldwide with presentation varying from clinically silent infection to dengue fever, dengue hemorrhagic fever, and severe fulminant dengue shock syndrome. Neurological manifestation usually results from multisystem dysfunction secondary to vascular leak. Presentation as hemorrhagic encephalitis is very rare. Here we present the case of a 13-year-old female admitted with generalized tonic clonic seizures. Plain computed tomography (CT) scan of head revealed hypodensities in bilateral deep gray matter nuclei and right posterior parietal lobe without any hemorrhage. Cerebrospinal fluid (CSF) and serology were positive for IgM and IgG antibodies to dengue viral antigen. Contrast-enhanced magnetic resonance imaging (MRI) revealed multifocal T2 and fluid attenuated inversion recovery (FLAIR) hyperintensities in bilateral cerebral parenchyma including basal ganglia. No hemorrhage was seen. She was managed with steroids. As her clinical condition deteriorated, after being stable for 2 days, repeat MRI was done which revealed development of hemorrhage within the lesions, and diagnosis of acute hemorrhagic encephalitis of dengue viral etiology was made.

Key words: Cerebral hemorrhage; dengue; diffusion-weighted images; Dengue hemorrhagic encephalopathy, encephalitis

Introduction

Dengue fever is a common viral infection worldwide, especially in tropical regions. Presentation of dengue viral infection is often unpredictable, varying from clinically silent infection to uncomplicated dengue fever, dengue hemorrhagic fever, and severe fulminant dengue shock syndrome. Neurological manifestation in dengue hemorrhagic fever usually results from multisystem dysfunction secondary to liver failure, cerebral hypoperfusion, electrolyte imbalance, shock, cerebral edema, and hemorrhage related to vascular leak.^[1,2]

Presentation as viral encephalitis is rare as the virus is not considered neurotrophic.^[3] Here we present a case of dengue fever developing acute hemorrhagic encephalitis during the course of the disease.

Case Report

A 13-year-old girl presented to the emergency department with history of fever, severe headache, and vomiting of 3 days duration. She had an episode of generalized tonic clonic seizure at the time of presentation. On examination, she was conscious, oriented and her vital parameters were stable. Neurological and fundoscopic examinations were within normal limits. Laboratory investigations revealed blood hemoglobin of 14 g/dl, neutrophil count of 12,000 cells/mm³, and platelet count of 50,000 cells/mm³. Liver and renal parameters and D-dimer level were within normal limits. USG (GE healthcare, Logiq P6, Milwaukee, USA) of the abdomen revealed mild bilateral pleural effusion and minimal free fluid in pelvis. Non-contrast computed tomography (CT) (Siemens Somatom Sensation,

Access this article online

Quick Response Code:



Website:
www.ijri.org

DOI:
10.4103/0971-3026.150145

Erlangen, Germany) scan of the head showed asymmetric hypodensity in bilateral deep gray matter nuclei and right posterior parietal lobe without any hemorrhage. Cerebrospinal fluid (CSF) examination revealed mildly elevated protein with lymphocytosis and no red blood cells (RBC). Serologic testing for malaria and leptospira was negative. Serology and CSF analysis for dengue (IgM and IgG antibodies) was positive, confirming the etiology.

Magnetic resonance imaging (MRI) (Siemens Avanto, Erlangen, Germany) was performed the next day which revealed multifocal T2-weighted (T2W) and fluid attenuated inversion recovery (FLAIR) hyperintensities in bilateral cerebral hemispheres including basal ganglia [Figure 1]. Some of these regions showed restricted diffusion and subtle peripheral contrast enhancement [Figure 2]. None of the lesions revealed hemorrhage. Diagnosis of acute viral encephalitis was made based on the clinical and imaging findings. Patient was started on methyl prednisolone (15 mg/kg/day for 5 days). Patient was clinically stable for next 2 days. On the 3rd day, she had another episode of generalized seizure with severe headache. Repeat laboratory investigations revealed blood hemoglobin of 13.5 g/dl, neutrophil count of 11,000 cells/mm³, and platelet count of 35,000 cells/mm³. Liver and renal parameters were within normal limits. Neurological examination at that time revealed weakness of right upper and lower limbs with a motor power of 3/5. Repeat MRI was performed which revealed hemorrhages [Figure 3] in the lesions that were noted previously. No new lesions were seen. She was managed conservatively with IV steroids and IV immunoglobulins. She improved clinically and was discharged a week later. At the time of discharge, the motor power was 4/5. Follow-up after 1 month revealed complete motor recovery in the right upper limb and a power of 4/5 in the lower limb.

Discussion

Dengue virus is a single-stranded RNA virus of the *Flavivirus* genus classified into four serotypes.^[1-4] Neurological manifestations, commonly seen with serotypes 2 and 3, occur in 0.5-21% of patients and usually result from multisystem dysfunction secondary to liver failure, cerebral hypoperfusion, electrolyte imbalance, shock, cerebral edema, and hemorrhage related to vascular leak which leads to encephalopathy.^[4,5] Patients present with the following neurological complaints: stroke, mononeuropathies, polyneuropathies, Guillain-Barre syndrome (GBS), myelitis, meningitis, acute disseminated encephalomyelitis (ADEM), encephalopathy, encephalitis, neuromyelitis optica, and optic neuritis.^[6-10] Dengue has classically been thought not to be neurotrophic; however, presence of dengue virus and anti-dengue IgM antibodies in patient's CSF with encephalitis suggests the possibility of direct cerebral invasion. Although the exact mechanism

by which dengue virus crosses the blood-brain barrier is unclear, it has been proposed that the entry occurs through infected macrophages.^[6] In our patient, IgM antibody was strongly positive in the CSF. However, polymerase chain reaction (PCR) for dengue viral RNA was not performed.

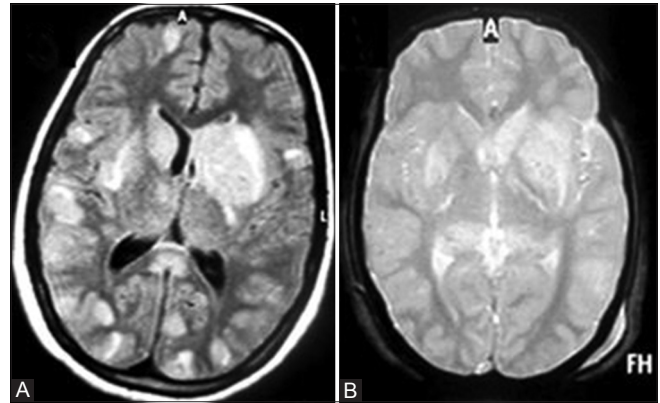


Figure 1(A and B): (A) Axial FLAIR and (B) gradient echo (GRE) MR images at the level of basal ganglia show multifocal FLAIR hyperintense lesions at gray-white matter junction and in bilateral basal ganglia. None of the lesions shows evidence of hemorrhage (B)

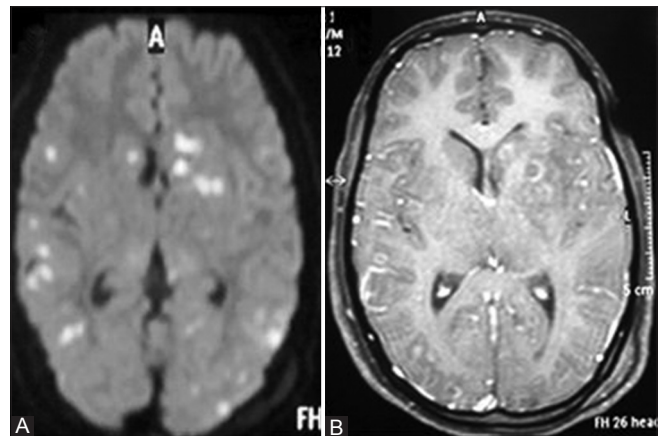


Figure 2 (A and B): (A) Axial DWI MR image at the level of basal ganglia shows restricted diffusion within these lesions. (B) Contrast-enhanced T1W MR image shows peripheral rim enhancement of the lesions

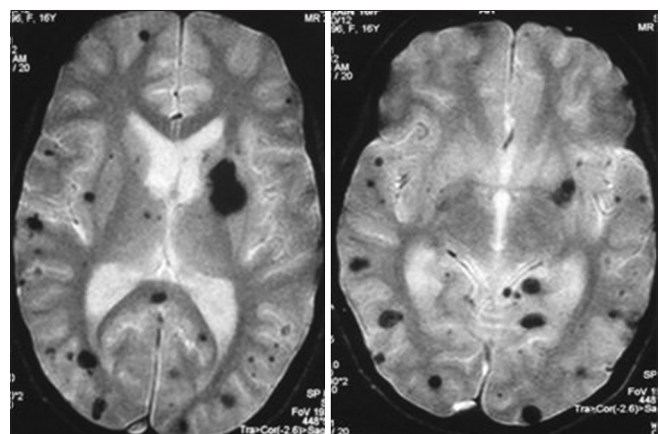


Figure 3: Follow-up GRE MR image, done after 72 h, shows multifocal areas of blooming within the lesions, suggestive of hemorrhage

Both dengue encephalitis and encephalopathy can present with diminished level of consciousness, headache, seizure, disorientation, and behavioral symptoms. Hence, clinical differentiation is not possible. However, few studies have shown that presentation as seizure is much more common in encephalitis than in encephalopathy. It is also necessary to rule out precipitating factors for encephalopathy, including acute liver failure, hypovolemic shock, and metabolic disorientation.^[5] Our patient also presented with seizure, and detailed examination revealed thrombocytopenia without significant systemic manifestations except for minimal bilateral pleural effusion and minimal pelvic free fluid. Diagnosis required CSF examination.

Multiple case reports and case series of dengue encephalitis have been published in literature. Solomon *et al.*^[4] reported a series of nine cases of dengue encephalitis, wherein all patients were positive for dengue serology, but virus/antibody was found in the CSF in only two patients. In their study, seven patients did not show the classic clinical features of dengue. Our patient also did not show typical clinical features of dengue.

Although diagnosis is mainly based on clinical and laboratory investigations, imaging (MRI) plays a supportive role in confirming the diagnosis of encephalitis. The number of studies describing the imaging features of dengue is limited. Kamble *et al.*^[11] described a case of dengue encephalitis with imaging features similar to Japanese encephalitis on CT. Few other case reports described involvement of hippocampus, temporal lobe, and pons. Few case reports have described involvement of bilateral gangliocapsular location, mid brain, and spinal cord on MRI.^[12] MRI findings are often non-specific, and not much data on MRI findings are available because of the rarity of this condition. Japanese and herpes encephalitis are common in the subcontinent and should be considered in differential diagnosis, and imaging with MRI helps in differentiating these from DHE (Dengue hemorrhagic encephalopathy). Although MRI appearances are typical in these conditions (bilateral thalamic and basal ganglia involvement in Japanese encephalitis; bilateral temporal and basifrontal lobes in herpes encephalitis), it may be difficult to differentiate from DHE in a given case and CSF analysis may be required.^[11,12] Chikungunya fever with encephalitis can also be a clinical differential in this case. However, MRI in Chikungunya encephalitis shows T2W hyperintense white matter lesions with restricted diffusion.^[13] No hemorrhage or basal ganglia involvement has been reported.

In our study, there was widespread involvement of bilateral cerebral hemispheres including deep gray matter nuclei. This finding can also be seen in ADEM. Changes of ADEM in dengue fever are similar to DHE on MRI and may not be possible to differentiate on MRI.^[14] As ADEM is immune mediated, there is temporal relationship

between exposure to dengue and manifestation of clinical symptoms. Typically, there is monophasic course of illness with eventual recovery, as against encephalitis where recovery is unpredictable. Our patient also had hemorrhage within the lesion on repeat MRI, probably related to thrombocytopenia caused by dengue, though the platelet level never dropped below 20,000 cells/mm³. Although intracerebral hemorrhage can occur in dengue due to profound thrombocytopenia, hemorrhage due to infection itself is rarely reported. Autopsy studies have shown focal hemorrhages in five diagnosed cases of dengue fever. Of these, three had dengue viral antigen in the brain tissue sample.^[15] However, details of platelet count were not available. In another proven case of dengue encephalitis, hemorrhage due to decreased platelet count has been reported.^[16]

There is no specific treatment for dengue encephalitis. Treatment is mainly supportive. Studies have shown inhibition of viral replication in cell culture by many promising agents like ribavirin and geneticin.^[17] In future, these agents may play a role in treatment.

Conclusion

In conclusion, though the presentation of dengue fever as encephalitis is very rare, diagnosis should be suspected in a patient from an endemic region with typical clinical and imaging features of encephalitis.

References

1. Cam BV, Fonsmark L, Hue NB, Phuong NT, Poulsen A, Heegaard ED. Prospective case-control study of encephalopathy in children with dengue hemorrhagic fever. *Am J Trop Med Hyg* 2001;65:848-51.
2. Hendarto SK, Hadinegoro SR. Dengue encephalopathy. *Acta Paediatr Jpn* 1992;34:350-7.
3. Nathanson N, Cole GA. Immunosuppression and experimental virus infection of the nervous system. *Adv Virus Res* 1970;16:397-428.
4. Solomon T, Dung NM, Vaughn DW, Kneen R, Thao LT, Raengsakulrach B, *et al.* Neurological manifestations of dengue infection. *Lancet* 2000;355:1053-9.
5. Carod-Artal FJ, Wichmann O, Farrar J, Gascón J. Neurological complications of dengue virus infection. *Lancet Neurol* 2013;12:906-19.
6. Misra UK, Kalita J, Syam UK, Dhole TN. Neurological manifestations of dengue virus infection. *J Neurol Sci* 2006;244:117-22.
7. Miagostovich MP, Ramos RG, Nicol AF, Nogueira RM, Cuzzi-Maya T, Oliveira AV, *et al.* Retrospective study of dengue fatal cases. *Clin Neuropathol* 1997;16:204-8.
8. Pancharoen C, Thisyakorn U. Neurological manifestations in dengue patients. *Southeast Asian J Trop Med Public Health* 2001;32:341-5.
9. Thisyakorn U, Thisyakorn C, Limpitikul W, Nisalak A. Dengue infection with central nervous system manifestations. *Southeast Asian J Trop Med Public Health* 1999;30:504-6.
10. Yamamoto Y, Takasaki T, Yamada K, Kimura M, Washizaki K, Yoshikawa K, *et al.* Acute disseminated encephalomyelitis

- following dengue fever. *J infect Chemother* 2002;8:175-7.
11. Kamble R, Peruvamba JN, Kovoov J, Ravishankar S, Kolar BS. Bilateral thalamic involvement in dengue infection. *Neurol India* 2007;55:418-9.
 12. Acharya S, Shukla S, Thakre R, Kothari N, Mahajan SN. Dengue encephalitis-A rare entity. *J Dent Med Sci* 2013; 5:40-2.
 13. Ganesan K, Diwan A, Shankar SK, Desai SB, Sainani GS, Katrak SM. Chikungunya encephalomyeloradiculitis: Report of 2 cases with neuroimaging and 1 case with autopsy findings. *AJNR Am J Neuroradiol* 2008;29:1636-7.
 14. Gera C, George U. Acute disseminating encephalomyelitis with hemorrhage following dengue. *Neurol India* 2010;58:595-6.
 15. Chimelli L, Hahn MD, Netto MB, Ramos RG, Dias M, Gray F. Dengue: Neuropathological findings in 5 fatal cases from Brazil. *Clin Neuropathol* 1990;9:157-62.
 16. Khanna A, Atam V, Gupta A. A case of dengue encephalitis with intracerebral hemorrhage. *J Glob Infect Dis* 2011;3:206-7.
 17. De Clercq E. Yet another ten stories on antiviral drug discovery (Part D): Paradigms, paradoxes and paradoctions. *Med Res Rev* 2010;30:667-707.

Cite this article as: Nadarajah J, Madhusudhan KS, Yadav AK, Gupta AK, Vikram NK. Acute hemorrhagic encephalitis: An unusual presentation of dengue viral infection. *Indian J Radiol Imaging* 2015;25:52-5.

Source of Support: Nil, **Conflict of Interest:** None declared.