

Original Research Article

Outcomes of reconstruction of polydactyly among children in a tertiary health facility in China

Gengliang Lan¹, Jihai Xu², Zhaoqing Wang¹, Yuanyong Rao¹, Renlin Tan^{1*}

¹Hand Surgery Department of The First People's Hospital of Hechi, Guangxi Hechi, 546300, China, ²Hand Surgery Department of Ningbo 6 Hospital, Ningbo 315040, China

For correspondence: Email: hds98663@126.com

Sent for review: 11 August 2020

Revised accepted: 7 September 2020

Abstract

Purpose: To evaluate the outcome of reconstruction of congenital bimanual polydactyly and bipedal polydactyly in children in a tertiary health facility in China.

Methods: All 8 children diagnosed with polydactyly of hands and feet from March 31st of 2016 to April 1st of 2020 underwent surgical reconstruction and were followed up for 6 to 36 months. Evidence of family history and outcome of the surgical intervention in the hospital using Tada scoring were analyzed.

Results 7 of the patients had the same family history with the same diagnosis of the same symptom in their fathers, grandfather and great grandfather. All the incisions healed well, the appearance of both hands and feet was satisfactory, and the function was significantly improved. The children's hand shape was satisfactory and their motor function was better than that before operation.

Conclusion Congenital polydactyly of both hands and feet is rare and complex. As long as the timing and method of operation are properly chosen, both hands and feet can acquire good appearance and functions after operation.

Keywords: Congenital polydactyly; multi-fingered hands; multi-toed feet

This is an Open Access article that uses a fund-ing model which does not charge readers or their institutions for access and distributed under the terms of the Creative Commons Attribution License (<http://creativecommons.org/licenses/by/4.0>) and the Budapest Open Access Initiative (<http://www.budapestopenaccessinitiative.org/read>), which permit unrestricted use, distribution, and reproduction in any medium, provided the original work is properly credited.

Tropical Journal of Pharmaceutical Research is indexed by Science Citation Index (SciSearch), Scopus, International Pharmaceutical Abstract, Chemical Abstracts, Embase, Index Copernicus, EBSCO, African Index Medicus, JournalSeek, Journal Citation Reports/Science Edition, Directory of Open Access Journals (DOAJ), African Journal Online, Bioline International, Open-J-Gate and Pharmacy Abstracts

INTRODUCTION

Often referred to as *hyperdactyly* or *hexadactyly*, polydactyly is a very common hereditary limb deformity in children usually characterized by extra fingers or toes[1]. Congenital polydactyly refers to the single or multiple redundant finger malformations formed outside the normal finger structure, which is the most common clinical congenital hand malformation[2]. In a broad sense, the non-syndromic polydactyly is classified into preaxial polydactyly (radial), central polydactyly (axial), and postaxial

polydactyly (ulnar) even though other types exist and are rare. Polydactyly often occurs on the inside of the first toe or the outside of the fifth toe[3]. However, it is rare to report cases of polydactyly of both hands and feet. The disorder is mostly inherited as an autosomal dominant entity and at least 10 loci and six genes causing the non-syndromic polydactyly that include *ZNF141*, *GLI3*, *MIPOL1*, *IQCE*, *PITX1*, and the *GLI1* have been identified [1].

It is widely believed that the surgery timing influences the therapeutic effect on both

functions and appearance. Clinically, it has been previously reported that polydactyly newborns subject to immediate excision after birth do not suffer from residual deformity nor complications after surgery and under proper anesthesia[4]. Moreover, children start to walk after 1 year old and if the feet are polydactyly, it will affect the children's ability to wear shoes and walk. Due to rapid physical growth and development, bipedal deformity of both hands and feet will affect the growth and development of the hands and feet of children who are above 2 years of age[5, 6]. Former clinical studies also revealed that the optimal timing for surgery is 18-30 months old [5], which implied that if they cannot undergo surgery on time, it may cause shortness of fingers or toes. In this study, the samples involved were aged 18-40 months, which is quite close to the optimal timing. We reviewed the surgical process and evaluated the therapeutic effects on all the cases of this deformity encountered in our health facility using Tada scoring system, with the hope of better understanding of the correlations between the surgical intervention and timing and family links.

METHODS

Setting

This study was carried out in the First People's Hospital of Hechi City, China with over 1000 beds and an annual out-patient attendance of more than 600,000. The Surgery Department has over 30000 cases of operations yearly with 1299 qualified doctors.

Study design

Following ethical approval from the Ethical Committee of Medical College of Ningbo University (Ref No. SX201950), children with bilateral polydactyly of hands and feet (each with 2 feet and 2 hands) admitted for treatment were recruited from March 31st 2016 to April 1st, 2019. Upon recruitment, family history of the deformity was obtained from the parent/care giver of the children. In one case of the patients, the fingers of the right hand were only slightly connected with the skin. For all the children, the lateral polydactyly existed on the outside of the fifth toe and the joint of the fifth metatarsal bone was formed outside the foot with the metatarsal toe joint and the fifth toe presenting 90° deformity.

A typical presentation is that of a 19 months old female born with polydactyly deformity in both hands and feet. She was not treated right after birth. According to her family history, her

grandfather and father were both born with the same deformity syndrome in both hands and feet. Her vital signs were normal and growth and development were normal. There was no abnormality in her heart, lung or abdomen. The ulnar side of the fifth metacarpal bone of both hands had a polydactyly, and the polydactyly could not move. The inner side of the fifth toe of the left foot had a polydactyly, which was similar in size to the fifth toe and could move. Outside of the fifth metatarsal bone of the right foot had a polydactyly of 90 degrees into angular malformation, with polydactyly as the same size as the other toes and the polydactyly cannot move (Figure 1).

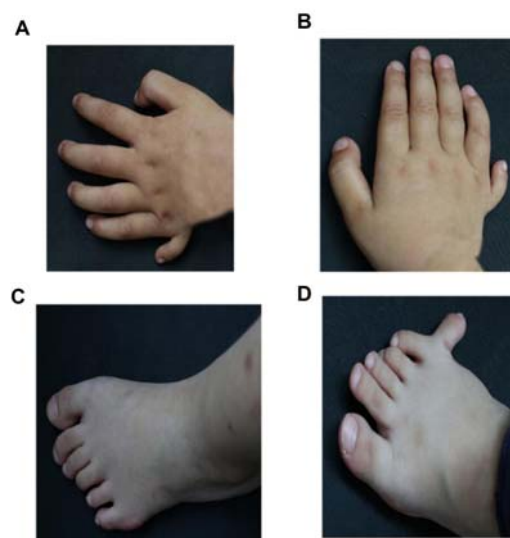


Figure 1: Photos of both hands and feet (left and right) of a patient with polydactyly deformity before surgery (A-B: left and right hands; C-D: left and right feet)

Diagnosis of the syndrome was confirmed using X-ray plain film to better understand the multi-finger and multi-toe deformity of the hands and feet of each child. Under X-ray films (Figure 2) polydactyly showed in both hands and feet, among which, the metatarsal bone bifurcated in the fifth toe of left foot. Therefore, she was diagnosed as Double-little finger polydactyly and double-foot polydactyly.

Surgical process

Under the condition of endotracheal intubation and general anesthesia, "Drive the Blood and Take band" procedure was used on the upper limbs to stop bleeding. The first operation was performed on the polydactyly in both hands. To surgically address the polydactyly in both hands, the fifth metacarpophalangeal capsule was repaired. First, fusiform incision was cut in the roots of the polydactyly of the 5th figures after

probing whether there existed flexion tendons after the skin incision. Where there was tendon, the tendon tissues at a certain length were preserved. After the extra finger was resected, the retained tendon tissues were sutured to the proximal phalanx of the metacarpophalangeal joint, and the metacarpophalangeal joint was stabilized. If there was no tendon tissue, the periosteum and tendinous tissues of the proximal phalanx of the extra finger could be retained when the resection was performed, and the tendinous tissues of the extra finger could be sutured to repair the joint capsule.

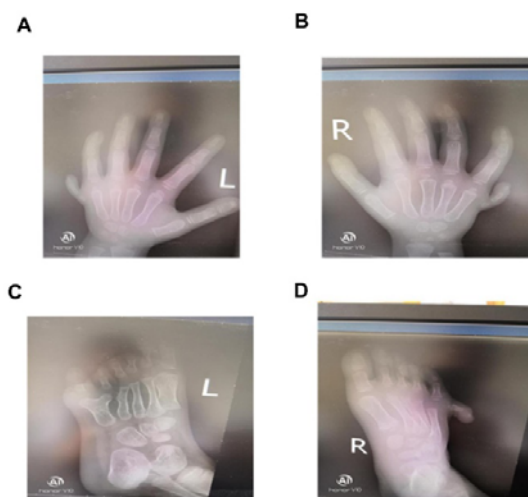


Figure 2: X-ray images of both hands and feet (left and right) of a child before surgery (A-B: left and right hands; C-D: left and right feet)

Lower extremities were treated with tourniquet and then the extra toe in the right foot was resected. Then the fifth metatarsophalangeal joint capsule was repaired and the metatarsophalangeal joint was stabilized. The extra toe between the fourth and sixth was removed in the left foot and the inner side of the bifurcation metatarsal bone was osteotomized. Lateral toe was retained, and the fourth metatarsal toe joint was restored. Thereafter, the joint capsules of the fourth and fifth were sutured for repair. Finally, the fifth (previously the sixth) toe was sutured toward the fourth one to narrow the distance in between. Similarly, all the other patients underwent the resection and repair operations to treat the congenital polydactyly in both hands and feet.

After the surgery, the clinical outcome of all the cases was assessed using improved Tada scoring [7], which not only included motion range of the metacarpophalangeal and interphalangeal joints, stability of joint, coronal alignment but also the subjective feedbacks from family of the children. Improved Tada scoring scale applied in

this study is provided in Table 1. The follow-up monthly visits continued for 6 to 36 months with 21.5 months as an average.

Written consent to support this research was provided by the parents of the children

Table 1: Improved Tada scoring scale for the outcome after surgical treatments for polydactyly.

Variable	Score
Motion range (degrees)	
>70	2
50-70	1
<50	0
Stability	
Yes	1
No	0
Malalignment	
<10	2
10-20	1
>20	0
Family assessment-Appearance	
Satisfied	1
Unsatisfied	0
Family assessment-Function improvement	
Satisfied	1
Unsatisfied	0
Total Tada score: 6-7 = good, 4-5 = fair, 0-3 = poor	

RESULTS

Among the patients were 4 boys and 4 girls with age ranging from 18 months to 40 months old (average age: 30 months). Seven families (87.5%) felt satisfied with the appearance after surgery (Table 2) except for one of the patients whose X-ray is shown in Figure 3 where the gap between the fourth and fifth toe was wider than normal after surgery. The stability of majority of

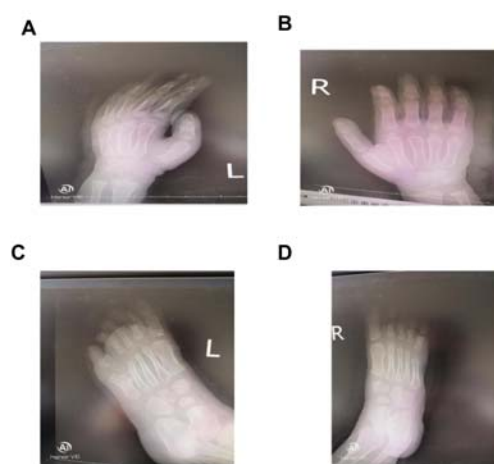


Figure 3: Hands and feet of a child diagnosed with polydactyly after surgery (A-B: left and right hands; C-D: left and right feet)

Table 2: Distribution of Tada scores in all variables

Variable	Tada score mean (sd)	Category	
		Good	Fair
Motion range (degrees)	1.625 (0.484)	62.5%	37.5%
Stability	0.875 (0.331)	87.5%	12.5%
Alignment	1.5 (0.5)	50%	50%
Family acceptance of children's appearance	0.875 (0.331)	87.5%	12.5%
Family assessment-functional improvement	1.125 (0.331)	12.5%	87.5%

the patients (87.5%) was also good and motion range was improved significantly in 5 patients (62.5%), In 4 cases (50%), there was excellent alignment while the alignment for the rest patients was considered to be fairly alright (Table 2). There is one interesting finding that the function improvement after surgery was significant with good rate in 1 case (12.5%) much lower than the rest criteria included in the revised Tada scoring system. It was only one family (12.5%) that agreed that the function improvement after surgery was significant enough to meet their expectation. For the rest 7 families (87.5%), the rating revealed that their families accepted the effect yet they had expected more before surgery. Outcome of the surgical intervention was generally good with total Tada score (6, 0.707) (Table 3). Family history of the patients indicated that nearly all the cases (87.5%) were linked to family history of the deformity.

Table 3: Total Tada score and age distribution

Sample No.	Total Tada score	Age (months) when surgery was performed
1	6	18
2	5	30
3	7	40
4	6	32
5	5	35
6	6	23
7	6	28
8	7	34
Mean (sd)	6 (0.707)	30 (6.538)

DISCUSSION

Polydactyly is an autosomal dominant heredity with innate limb defects whose pathogenesis has not been identified [8]. In addition to genetic factors, environmental factors affecting embryo development, such as certain drugs, viral infection, trauma, stimulation of radioactive substances, and industrial pollution may become teratogenic factors [9].

In this study, the patients had a strong heredity from their family, with genetic disposition following three generations (7 out of 8 cases with small finger duplication bilaterally in both feet and hands), which agrees with previous report on the heredity of this disease [10]. The environment factors may not have played any role in these patients since there was no other patient with the deformities in the neighbourhood where the patients lived. All seven patients shared the same sub-type of polydactyly, bilateral ulnar Polydactyly in all the three generations. The three cases were characterized by obvious familial aggregation and vertical distribution, which was consistent with autosomal dominant inheritance.

Results of this study are generally in agreement with earlier findings as the patients were aged from 18 to 40 months when they underwent surgery and there is no significant difference in the outcomes between all cases (Table 2) [5].

Preoperative auxiliary examination was done to confirm the syndrome in each patient. X-ray plain film of deformity in hands and feet of children, which is the main method to diagnose the development of children's bone and joint deformity [11]. In our study, we used the X-ray plain film to validate the details in the limbs of patients in diagnosis and post-surgery period.

The polydactyly in patients were in symmetry, so were the toes. Surgical treatment is mainly to develop personalized surgical plans and normally the duplicate fifth digit and toe are removed and joint capsule is repaired [12]. Some polydactyl operation is simple to some degree. If it is polydactyl deformity in the fifth metatarsophalangeal joint lateral, the operation will be polydactyl resection, and repairing the fifth metatarsophalangeal joint capsule. However, other polydactyl surgery tactics are relatively complex especially for instance, when there is little difference in appearance and function between the polydactyl toe and the fifth one. Before surgery, it is necessary to screen which toe should be retained and which toe should be removed, and comprehensive consideration

should be given to the appearance, function, development, and wishes of the children's family members. After deciding which one to remove and articular capsule should be repaired after toe resection. If there is bifurcation in the fifth metatarsal bone and the 4th metatarsal bone suffers extrusive dislocation, the polydactyly should be removed and the 4th plantar bone should be restored and the fourth and fifth plantar toe joint capsules should be repaired. Then the fifth digit suture should be adjusted towards 4 digits to narrow down the digit span.

According to our experience here, operation methods are chosen properly and personalized treatment plan is made based on the specific characteristics of the patients, both hands and feet will obtain good appearance and function after the operation. As for the evaluation of the clinical effects after surgery, we used an improved version of Tada scoring mechanism by including the family satisfaction with the appearance and function improvement due to the surgery. Our findings showed that generally all families were satisfied with the operative effects on appearance and function improvement.

CONCLUSION

Congenital polydactyly of both hands and feet is rare and complex. As long as the timing and method of operation are properly chosen, both limbs can be effectively can effectively be surgically constructed.

DECLARATIONS

Acknowledgement

This work was funded with the support of Ningbo Municipal Bureau of Science and Technology (2018A610262)

Conflict of interest

No conflict of interest is associated with this work.

Contribution of authors

We declare that this work was done by the author(s) named in this article and all liabilities pertaining to claims relating to the content of this article will be borne by the authors. All authors

read and approved the manuscript for publication.

Open Access

This is an Open Access article that uses a funding model which does not charge readers or their institutions for access and distributed under the terms of the Creative Commons Attribution License (<http://creativecommons.org/licenses/by/4.0>) and the Budapest Open Access Initiative (<http://www.budapestopenaccessinitiative.org/read>), which permit unrestricted use, distribution, and reproduction in any medium, provided the original work is properly credited.

REFERENCES

1. Umair M, Ahmad F, Bilal M, Ahmad W, Alfadhel M. *Clinical Genetics of Polydactyly: An Updated Review*. *Front Genet*. 2018; 9: 447.
2. Farrugia MC, Calleja-Agius J. *Polydactyly: A Review*. *Neonatal Netw*. 2016; 35: 135-42.
3. Burger EB, Baas M, Hovius SER, Hoogeboom AJM, van Nieuwenhoven CA. *Preaxial polydactyly of the foot*. *Acta Orthop*. 2018; 89: 113-8.
4. Samra S, Bourne D, Beckett J, Matthew M, Thomson JG. *Decision-making and Management of Ulnar Polydactyly of the Newborn: Outcomes and Satisfaction*. *J Hand Surg Asian Pac Vol*. 2016; 21: 313-20.
5. Jia ZW, Bai DM, Long JT, Guo XS, Tian Y, Zhang LQ, et al. [Optimal surgical timing and treatment of thumb duplication in children]. *Zhonghua Zheng Xing Wai Ke Za Zhi*. 2013; 29: 336-40.
6. Daneff M, Casalis C, Bruno CH, Bruno DA. *Bone age assessment with conventional ultrasonography in healthy infants from 1 to 24 months of age*. *Pediatr Radiol*. 2015; 45: 1007-15.
7. Tada K, Yonenobu K, Tsuyuguchi Y, Kawai H, Egawa T. *Duplication of the thumb. A retrospective review of two hundred and thirty-seven cases*. *J Bone Joint Surg Am*. 1983; 65: 584-98.
8. Abdullah, Yousaf M, Azeem Z, Bilal M, Liaqat K, Hussain S, et al. *Variants in GLI3 Cause Greig Cephalopolysyndactyly Syndrome*. *Genet Test Mol Biomarkers*. 2019; 23: 744-50.
9. Alexander PG, Clark KL, Tuan RS. *Prenatal exposure to environmental factors and congenital limb defects*. *Birth Defects Res C Embryo Today*. 2016; 108: 243-73.
10. Comer GC, Potter M, Ladd AL. *Polydactyly of the Hand*. *J Am Acad Orthop Surg*. 2018; 26: 75-82.
11. Wessel LE, Daluiski A, Trehan SK. *Polydactyly a review and update of a common congenital hand difference*. *Curr Opin Pediatr*. 2020; 32: 120-4.
12. Wang C, Huang X, Tan W. *A new skill for treating unclassified thumb polydactyly: ablation via a periosteal incision*. *Aesthetic Plast Surg*. 2012; 36: 928-33.