

Left Displaced Abomasum of Bovine



COLLEGE *of*
VETERINARY MEDICINE

MISSISSIPPI STATE UNIVERSITY™

Stephen M. Campbell

Class of 2018

Clinical Pathologic Conference

Presented December 8, 2017

CPC Advisor:

Dr. Jim Brett

Special Thanks to:

Dr. Jim Cooley

Introduction

Left displaced abomasum, more commonly known as a LDA, is a relatively common occurrence in dairy cattle (Oman et al.); a risk that appears to be increasing with demands of production. In recent studies, the incidence of a LDA occurring is between 3-7%, with 12 – 17 % resulting in unsuccessful outcomes (death or culling within 30 days). (Reynen). Left sided abomasal displacements are also the most common, comprising 80-90% of all abomasal displacements. They can also occur at any time, however, the majority occur during the transition period to one month post-freshening (Shaver). During lactation, dairy cattle that have experienced a left displaced abomasum and have been successfully treated are expected to produce approximately 557 kg less milk than similar, healthy cattle (Detilleux).

History and presentation

Cow #1036 was a 2 year old Holstein-Jersey cross, owned by the Mississippi State University Dairy. She was nine days in milk (DIM) and had a three day history of hyporexia and reduced milk production, producing 30 pounds daily. Upon presentation, she stood with abnormal posture and exhibited dull mentation. Physical examination revealed a body temperature of 102.5F, tachycardia (72 beats/min), and tachypnea (92 breaths/min). Tacky mucous membranes, a prolonged skin tent, endophthalmia, and capillary refill time indicated dehydration. Mucopurulent nasal discharge was present bilaterally. Auscultation of lung fields revealed no abnormalities, however, a high pitched “ping” could be heard along the dorsal thorax of the left side, between the 10th and 13th rib spaces. Ruminal contractions were weak to absent. Rectal palpation revealed an atonic uterus, indicative of subclinical hypocalcemia. It was at this time Cow #1036 was referred to Mississippi State University College of Veterinary Medicine Food Animal Department for further evaluation and surgery to correct her suspected left displaced abomasum (LDA).

Etiology

The etiology leading up to a displaced abomasum is multifactorial. Because the abomasum is loosely held in place by the greater and lesser omenta, pathophysiological processes that inhibit abomasal motility can disrupt the emptying of the pylorus, allowing for the abomasum to become distended with gas and gravitate towards either the left or right side of the abdominal cavity (Niehaus). Such etiologies can be narrowed down into three categories: mineral/electrolyte imbalances, increased amounts of concentrates in the diet, and negative energy balance.

Hypocalcemia and hypokalemia are two mineral/electrolyte abnormalities that are common in the predisposition of dairy cattle to LDA (Radostits et al.). Both are found in relatively high quantities in milk and are regularly depleted from the bodily stores. Once depleted in sufficient amounts, low dry matter intake results in decreased contractility and receptability of muscles to electrical impulses. The most susceptible type of muscle to these deficiencies is smooth muscle, as found in the abomasum. Once contractility of the abomasum is inhibited, passage of ingesta into the duodenum is slowed. Accumulation of non-structural carbohydrates undergoes fermentation resulting in gas production. The abomasum has been displaced cranio-ventrally due to the gravid uterus. The malposition, smooth muscle hypomotility, and formation of gas allows the abomasum to gravitate towards the left side of abdominal cavity. The abomasum passes underneath the rumen before rising up along the abdominal wall, resulting in a left displaced abomasum (Niehaus).

Increased concentrate to forage ratios in the transition ration is another predisposing factor that predisposes to a majority of other pathologies. Rations with elevated proportions of concentrates (high in starch) produce more gas than those of a more balanced concentrate/forage ration. Furthermore, increased amounts of concentrates can result in the rumen becoming acidic,

leading to ruminal acidosis, abomasal ulcers, and laminitis. All reduce the amount of dry matter intake. Reduced rumen fill is another predisposing factor to left abomasal displacements (Lester and Bolton).

Many factors can lead to negative energy balance. Any factor (i.e. stress of parturition, metabolic/nutritional disturbances, abomasal ulcers) that reduces caloric intake and the increased nutrient demand for milk production will cause an accelerated gluconeogenesis, leading to ketosis. Once this state is reached, ketone bodies, (beta-hydroxybutyrate, acetoacetate, and acetone) are released into the blood stream and have immunosuppressive effects. Cattle experiencing ketosis are more likely to have incidences of metritis, mastitis, and pneumonia, further reducing the daily caloric intake. It should also be noted that cattle with excessive body condition scores at the time of freshening are also predisposed to ketosis through increased triglyceride metabolism in the liver (Geishauser). Figure 2 provides additional abomasal disease conditions that can predispose dairy cattle to left abomasal displacement.

Pathogenesis

Due to the hypomotility of the abomasum combined with the continued gas production, the fundus of the abomasum begins to slide under the rumen and eventually rising to settle on the left dorsal side of the abdominal cavity, between the rumen and the rib cage. This movement of the fundus also causes movement of the pylorus and can cause displacement of the reticulum and omasum. It should be noted in some cattle the abomasum will move to the left side of the abdomen and not completely rise to the dorsal aspect. These cases are called “a floater or floating DA” when the left displaced abomasum spontaneously resolves. Once rotation of the abomasum is complete, the pylorus becomes obstructed, inhibiting fluid and ingesta from passing into the duodenum. Because of this blockage, the abomasal secretions pool in the abomasum, decreasing the pH to

< 2.0. A hypochloremic, hypokalemic metabolic alkalosis occurs in the blood stream. The hypochloremia develops from the sequestering of hydrochloric acid into the abomasum and refluxes into the rumen, and the hypokalemia results from anorexia, dehydration, and further sequestration of potassium into the abomasum. Because of the pyloric obstruction and anorexia, volatile fatty acid secretion to the liver is compromised, inducing a ketotic state from increased triglyceride metabolism and exhaustion of oxaloacetate (Constable). Furthermore, cattle may exhibit a paradoxical aciduria, in which excessive hydrogen is excreted into the urine causing the urine to be acidic. In a normal cow, sodium is reabsorbed by the renal system while potassium is excreted. However, in the case of abomasal displacements, an alkalotic blood stream moves potassium intracellularly resulting in excretion of hydrogen from the cells in an attempt to compensate for the alkalosis. The influx of potassium into the cells combined with the sequestering of potassium into the abomasum, severely depletes blood potassium leaving none to be exchanged for sodium by the renal system. Instead, hydrogen is substituted for potassium. This phenomenon is compounded by anorexia and decreased water consumption, leading to dehydration and activation of aldosterone by the renin-angiotensin system. The kidneys then retain more sodium in an attempt to retain water, resulting in more hydrogen being excreted (ECLinpath).

Clinical Findings

Gross physical examination findings consistent with a left displaced abomasum are anorexia, dehydration, decreased milk production, and elevated heart and respiratory rates. Ketone bodies (beta-hydroxybutyrate, acetoacetate, and acetone) can be elevated and may be present in blood or urine. Type III vagal indigestion may be present and is characterized by a “papple shaped abdomen” when examined from behind, as shown in Figure 1 (Grissett). Occasionally, cattle effected with abomasal displacements experience atrial fibrillation, most likely due to the effects

of hypokalemia and metabolic alkalosis. Once corrected, the atrial fibrillation will resolve in a matter of days (Constable). Bloodwork consistent with a left displaced abomasum is characterized by hypochloremia, hypokalemia, and a decreased TCO₂ indicating metabolic alkalosis (Grissett). Furthermore, blood serum concentrations of aspartate-aminotransferase (AST) and beta-hydroxybutyrate (BHBA) may play a role in prediction of abomasal displacement. One week following parturition, if AST concentrations were above 1700 nkat/L the odds ratio was 3:1 that a displaced abomasum would be diagnosed 1-3 weeks later. BHBA concentrations were measured and found to have a 4:1 odds ratio if above 1400 μmol/L one week post parturition. If these serum values remained into the second week post parturition, the odds ratio increased 8:1 (Geishauser).

In the case of Cow #1036, complete blood cell count and biochemistry were performed the day after surgery, and revealed neutrophilia, mild lymphopenia, decreased CO₂, hypoglycemia, increased AST, hyperglobulinemia, hypocalcemia, hypomagnesemia, and hypophosphatemia. It was also concluded that Cow #1036 was relatively dehydrated as indicated by an increased total protein and skin tent. These findings were consistent with a left abomasal displacement.

Diagnosis

Diagnosis of a left displaced abomasum by an experienced practitioner is relatively straightforward. A “ping” can be heard on auscultation due to the liquid/gas interface confined within a compartment. The left displaced abomasum “ping” can be heard between the 10th and 13th left rib spaces, along a line from the elbow to the ilium. In some instances, the left 13th rib will be slightly “sprung”; this occurs due to rib displacement by the abomasum (Niehaus). It is important to be able to distinguish the differences in pitch of a ruminal ping from that of a left displaced abomasum. A ruminal ping can be elicited in any number of anorexic cattle due to loss of the ruminal fiber mat. A good rule of thumb is that a ruminal ping will be of a lower pitch and will

extend cranial and caudal to the 10th and 13th rib spaces. A left displaced abomasum can be further diagnosed by ballottement, which can be performed by bumping the ventral aspect of the abdomen while auscultating in the area of the left displaced abomasum. Auscultating a characteristic sloshing sound will increase a practitioner's suspicion of a left displaced abomasum (Grissett).

Further diagnostic testing can be performed if previous attempts have revealed varying results. Abomasocentesis, or Liptak test, can be performed by first clipping and scrubbing the area of the suspected left displaced abomasum with chlorohexidine and isopropyl alcohol, before inserting a needle and aspirating back fluid. Any fluid obtained with a pH of <4.5 is indicative of a left displaced abomasum, as the normal pH of the rumen is 5.5 - 7.0. However, this test can have false positives if the patient has severe ruminal acidosis (Grissett).

Differential Diagnoses

As a practitioner, it is important to understand bovine anatomy and common locations of pings that can indicate presence of disease elsewhere in the abdomen. Three distinct disease states that can also produce a ping are ruminal atony, peritoneal gas, and intra-uterine gas. Ruminal gas, extends cranial and caudal to the left 10th and 13th rib spaces, while peritoneal gas resides dorso-caudal to the left 13th rib, just ventral to the lumbar spinous processes (Figure 3). Intra-uterine gas can sometimes produce a ping during times of metritis, when the colonizing bacteria is gas producing and the uterus resides under the caudal aspect of the rumen. However, this condition can be easily distinguishable from a left displaced abomasum by rectal palpation, while the previous differential diagnoses require careful auscultation by an experienced examiner (Grissett).

Treatment

Upon arrival to Mississippi State University College of Veterinary Medicine, Cow #1036 was again thoroughly evaluated before treatment. An orogastric tube was placed and Cow #1036 orally received five gallons of water combined with Hostetler's solution (sodium chloride and potassium chloride), 300 ml of calcium drench, and 300 ml of propylene glycol. Further treatment included two liters of 7.2% hypertonic saline intravenously.

Next, a right flank pyloromentopexy was performed to correct the left displaced abomasum. The right paralumbar fossa was clipped and scrubbed with chlorohexidine solution and isopropyl alcohol while a distal paravertebral nerve block was performed using 2% lidocaine. Cow #1036 was draped before an incision was made in the right flank to achieve access to the abdomen. Upon access to the abdominal cavity, palpation with sterile sleeves was performed. The abomasum was found to be displaced to the left of the rumen and distended with gas. A 14 gauge needle and suction tubing were used to deflate the abomasum before sweeping motions were used to retract the abomasum back to the right side of the abdomen. Once retracted, the abomasum was pyloropexied to the abdominal wall. The internal and external oblique muscles were then closed, while the skin and subcutaneous tissues were closed using a Ford Interlocking pattern. Alluspray, a protect adhesive, was applied over the incision.

Cow #1036 received Excede (ceftiofur crystalline free acid) (1.5 ml/100 lb), administered in the subcutaneous fat pad behind the right ear prior to surgery. To correct blood abnormalities, a further 300 ml of propylene glycol and 200 ml calcium drench consecutively over the next two days. Twenty milligrams of Predef 2X (isoflupredone acetate) was administered intramuscularly in the left side of the neck the following day after surgery. The glucocorticoid activity of Predef initiates a hyperglycemic effect to correct ketosis.

The treatments that Cow #1036 received are synonymous for all left abomasal displacement patients and are provided to correct the electrolyte abnormalities, dehydration, and ketosis. In this case Cow #1036 received a right flank pyloromentopexy, but there are other surgical options including: right paramedian abomasopexy, left flank abomasopexy, and roll and toggle/blind stitch. Laparoscopic surgery has been used to correct a left displaced abomasum but this method is less routine in private practice (Niehaus).

Prevention

The transition period from dry to production, coupled with act of parturition, is very stressful upon dairy cattle because this is the time when nutritional demand increases dramatically. It is crucial that these nutritional demands are managed appropriately to avoid disturbances that could lead to metabolic derangements; one of high importance is hypocalcemia. In order to prevent hypocalcemia, a negative dietary cation-anion difference diet (DCAD) must be maintained. Anionic diets are constructed by feeding anionic salts (magnesium sulfate, calcium sulfate, ammonium sulfate, calcium chloride, ammonium chloride, and magnesium chloride) which work by increasing blood anion/cation ratio, inducing a mild acidosis. This acidotic state promotes the production of parathyroid hormone, which works to release calcium carbonate from the bone and increase the cation (calcium) absorption into the blood. Unlocking the storage of calcium from bone is key to overcoming the lack of calcium when lactation starts. However, feeding a diet too high in anionic salts and achieving a blood chloride level above 0.8% has been shown to decrease feed intake. To manage the DCAD ratio, urine pH should be monitored. As blood becomes more acidic, urine will also become more acidic (Bethard and Stokes). A urine pH of 5.5 - 6.0 or 6.0 - 6.5 should be maintained for Jersey and Holstein breeds, respectively (Horst et al.).

Conclusion

Cow #1036 remained hyporexic the following two days after surgery, so the decision was made to transfer her back to the Mississippi State University dairy in the hopes that her appetite would increase. However, the next day, Cow #1036 was found down in the stalls and died before any further care could be administered. A necropsy was performed by Mississippi State University, but no gross pathology or histopathology could determine a cause of death. It was concluded that Cow #1036 died due to blood and electrolyte derangements that her body could not simply overcome.

In conclusion, left displaced abomasum in the bovine is a relatively common occurrence; one that leads to premature culling and milk production losses (Geishauser). The major risk period for developing left abomasal displacement has been shown to occur from the transition to postpartum period, when the demand for nutrients is the highest. The underlying etiologies associated include mineral/electrolyte deficiencies, reduced forage to concentrate diets, and negative energy balance and can be due in part by stress factors and concurrent diseases such as ketosis, mastitis, and metritis (Shaver). Prevention of left abomasal displacements, as well as other displacements, centers around the understanding of the various etiologies leading to beneficial management strategies, while diagnosis relies on observations from astute practitioners and producers, alike. While surgical correction is curative, it can only be perceived as salvage due to the increased loss of milk production throughout lactation (Detilleux).

Figure Legend

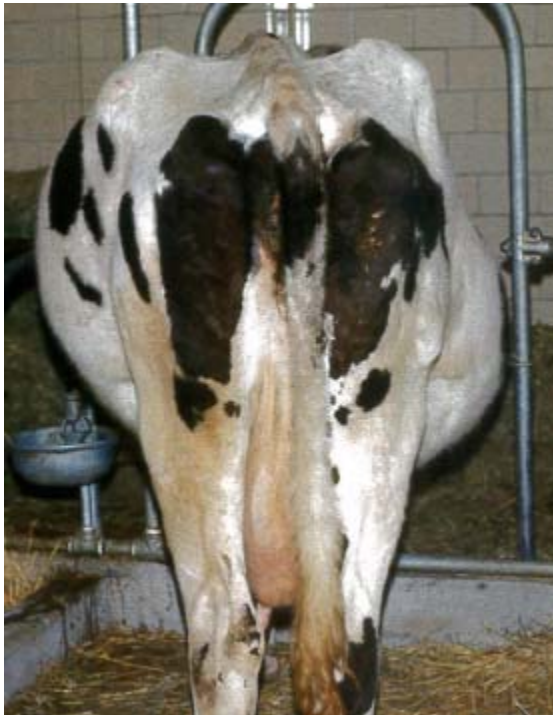

Figure 1: Characteristics papple shaped abdomen of dairy cattle with Type III vagal indigestion. This presentation is not pathognomonic for left displaced abomasum, but is reason of concern to practitioners when examining dairy cattle for some type of abomasal or ruminal dysfunction. From this image, one can grasp how the left 13th rib of this Holstein is “sprung”. (Grissett)

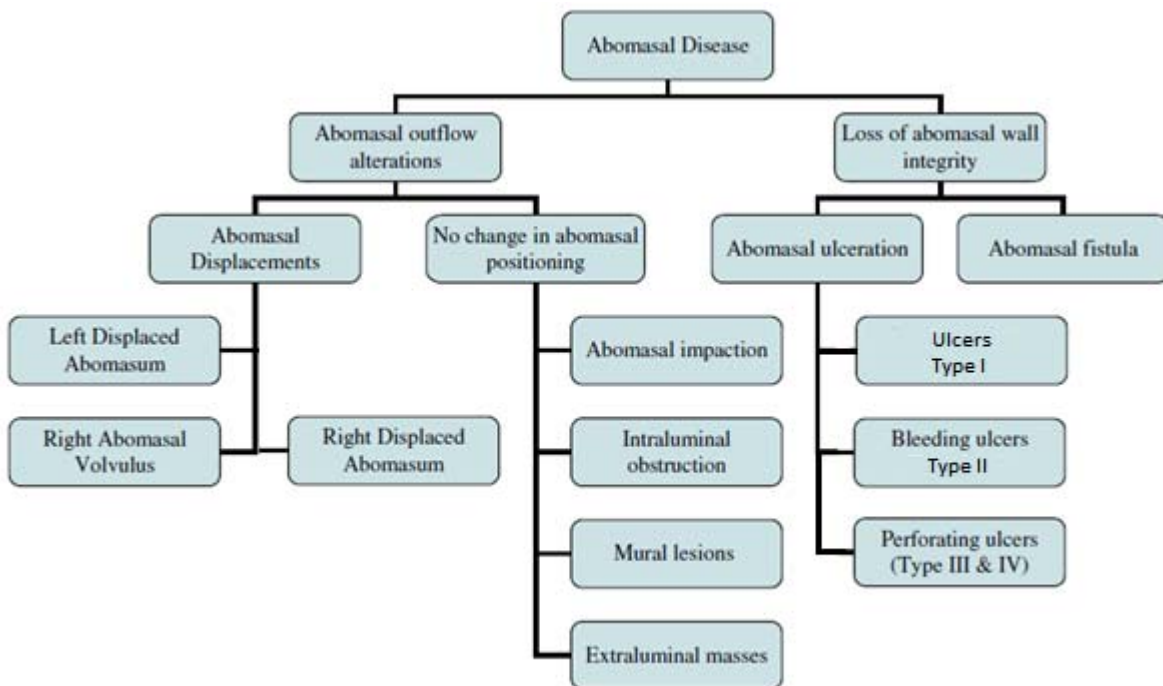


Figure 2: Diagram showing various abomasal diseases predisposing dairy cattle to left abomasal displacements by anorexia leading to initiation of negative energy balance, thus hypocalcemia. (Adapted from Niehaus)

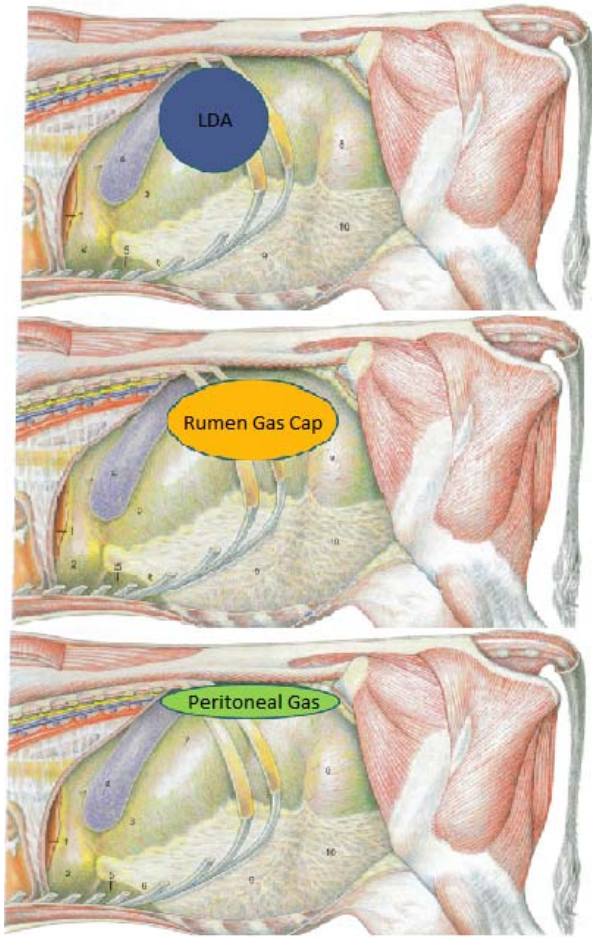


Figure 3: Locations of other left sided “pings”. (Grissett)

Normal topography of left abdominal viscera, cow, and left displacement of abomasum

A) Normal topography of left abdominal viscera, cow. B) Left displacement of abomasum. Illustration by Dr. Gheorghe Constantinescu. Adapted, with permission, from DeLahunta and Habel, *Applied Veterinary Anatomy*, W.B. Saunders, 1986.

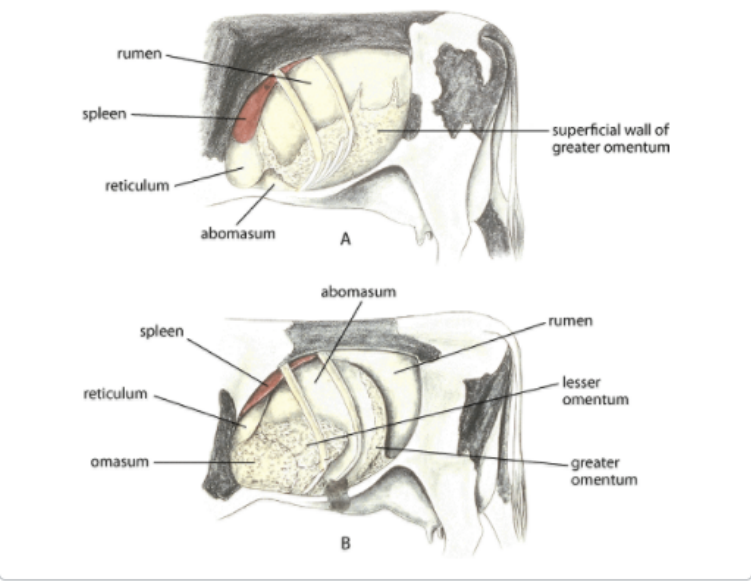


Figure 4
(Constable)

References

1. Bethard, G., Stokes, S. Managing Transition Cows for Better Health and Production. Oregon State University. Feb 2000. Available at: <https://ir.library.oregonstate.edu/xmlui/bitstream/handle/1957/25110/WREPNO149.pdf?sequence=1>. Accessed Nov. 18, 2017.
2. Constable, Peter D. “Left or Right Displaced Abomasum and Abomasal Volvulus - Digestive System.” Merck Veterinary Manual. Available at: www.merckvetmanual.com/digestive-system/diseases-of-the-abomasum/left-or-right-displaced-abomasum-and-abomasal-volvulus. Accessed Nov. 18, 2017.
3. Detilleux, J.c., et al. “Effects of Left Displaced Abomasum on Test Day Milk Yields of Holstein Cows.” *Journal of Dairy Science*, vol. 80, no. 1, 1997, pp. 121–126., doi:10.3168/jds.s0022-0302(97)75919-8.
4. EClinpath. “Paradoxic Aciduria in a Ruminant with Abomasal Displacement.” EClinpath, Available at: www.eclinpath.com/chemistry/acid-base/laboratory-detection/bicarbonate/paradoxic-aciduria/. Accessed Nov. 16, 2017.
5. Geishauser, Thomas, et al. “Metabolic Aspects in the Etiology of Displaced Abomasum.” *Veterinary Clinics of North America: Food Animal Practice*, Elsevier, 7 Jan. 2016.
6. Grissett, Gretchen. “Abdominal Surgery – Rumen and Abomasal.” *Food Animal Medicine and Surgery*. Starkville, MSU CVM.
7. Grissett, Gretchen. “Left Displaced Abomasum.” *Food Animal Medicine and Surgery*. Starkville, MSU CVM.
8. Horst, R.L., J.P. Goff, T.A. Reinhardt, and D.R. Buxton. 1997. Strategies for preventing milk fever in dairy cattle. *J. Dairy Sci.* 80:1269.
9. Lester GD, Bolton JR. Effect of dietary composition on abomasal and duodenal myoelectrical activity. *Res Vet Sci.* 1994;57:270–276. doi: 10.1016/0034-5288(94)90117-1.
10. Niehaus, Andrew J. “Surgery of the Abomasum.” *Veterinary Clinics of North America: Food Animal Practice*, vol. 24, no. 2, 2008, pp. 349–358., doi:10.1016/j.cvfa.2008.02.012.

11. Oman, R.e., et al. "Left Displacement of the Abomasum in 4 Beef Calves." *Journal of Veterinary Internal Medicine*, vol. 30, no. 4, Jan. 2016, pp. 1376–1380., doi:10.1111/jvim.14353.
12. Radostits OM, Gay CC, Hinchcliff KW, Constable PD. Diseases of the abomasum. In: Radostits OM, Gay CC, Hinchcliff KW, Constable PD, editors. *Veterinary medicine: a textbook of the diseases of cattle, horses, sheep, pigs and goats*. 10. Philadelphia: Elsevier Health Sciences; 2007. pp. 353–374.
13. Reynen, J L, et al. "Factors Associated with Survival in the Herd for Dairy Cows Following Surgery to Correct Left Displaced Abomasum." *Journal of Dairy Science.*, U.S. National Library of Medicine, June 2015.
14. Shaver, R.d. "Nutritional Risk Factors in the Etiology of Left Displaced Abomasum in Dairy Cows: A Review." *Journal of Dairy Science*, vol. 80, no. 10, 1997, pp. 2449–2453., doi:10.3168/jds.s0022-0302(97)76197-6.