

Angiostrongylus vasorum update

Author : SIMON TAPPIN

Categories : [Vets](#)

Date : April 21, 2014

SIMON TAPPIN looks at developments in the diagnosis and treatment of *Angiostrongylus vasorum* as the number of cases and geographical spread across the UK increase

Summary

Disease due to infection with *Angiostrongylus vasorum* has been well documented in small numbers of dogs in the south of Wales and south-east of England for some years; however, both the incidence and geographical distribution appear to be increasing, with cases now being reported in northern England and Scotland.

Most dogs develop signs of cardiorespiratory disease, but a significant proportion develop signs secondary to coagulopathy. A rapid patient-side blood test with good sensitivity and specificity has become available, greatly improving the ease of diagnosis. Imidacloprid/moxidectin, milbemycin and fenbendazole are all effective treatment options, with imidacloprid/moxidectin also being an effective prophylactic treatment.

Key words

Angiostrongylus vasorum, cough, coagulopathy, imidacloprid/moxidectin, milbemycin, fenbendazole

INFECTION with *Angiostrongylus vasorum* has been diagnosed with increasing frequency in the United Kingdom over the past 10 to 15 years.

A vasorum is a metastrongylid nematode that primarily infects canidae, especially domestic dogs and foxes, although infection has been reported in others including wolves, coyotes, otters and ferrets. Its distribution is patchy, but fairly widespread, through most of western Europe, with spasmodic reports in the US and Canada. There are geographical differences in case numbers in the UK, with well-documented hot spots of infection in the south-east of England and south of Wales, in which cases have been recorded for many years; more recently, cases have also been reported in northern England and in Scotland ([Figure 1](#); Helm et al, 2009; Yamakawa et al, 2009).

Causes of the change to the reported distribution of *A vasorum* are unclear, but are thought to be due to multiple factors, including changes to environmental conditions that have changed the distribution, or increased the abundance, of the mollusc hosts; and better awareness of clinical signs associated with the presence of the parasite (Helm et al, 2009).

Furthermore, it has been suggested the increasing prevalence of *Angiostrongylus* infection in dogs mirrors increased prevalence in the fox population, with the fox acting as a reservoir for canine infection (Morgan and Shaw, 2010).

Life cycle

A vasorum was first documented in 1853 in France and, as a result, is often referred to as French heartworm as the adults live in the pulmonary arteries and the right side of the heart. Dogs become infected by L3 larvae after eating infected intermediate hosts (molluscs such as slugs and snails) or paratenic hosts (for example, frogs). More than 25 different species of snail and slug have been identified as intermediate hosts for *A vasorum*, although hosts are likely to vary considerably depending on geographic location (Helm et al, 2010).

It has also been reported L3 larvae can leave the host and be ingested directly from the environment; the epidemiological significance of this is unclear (Barçante et al, 2003). Once ingested, L3 larvae migrate through the intestinal wall to the mesenteric lymph nodes where they develop to the L5 larvae. From here, they migrate via the lymphatic and venous systems to mature in the pulmonary vasculature. The prepatent period is variable, with reports ranging from 28 to 108 days (Cury et al, 1996).

Ova released from the adult worms are washed into the pulmonary capillaries, where they develop into L1 larvae and migrate into the alveoli. These are coughed up and swallowed, and are passed in the faeces. Molluscs are then infected by faecal contact.

Dogs with untreated asymptomatic infection are thought to excrete larvae for prolonged periods after infection; this has been documented experimentally with untreated dogs excreting L1 larvae for nearly two years post-infection (Oliveira Junior et al, 2006).

Clinical signs

Infected dogs have a range of clinical signs, which are mostly cardiorespiratory; bleeding diathesis is also fairly commonly reported. Coughing occurs due to the physical presence of the parasite and its associated inflammatory response; there may also be secondary bacterial infection or tachypnoea or dyspnoea as a result.

Severe pulmonary hypertension, leading to signs of rightsided heart failure (cor pulmonale) can sometimes be seen. Central nervous system signs are occasionally reported and are associated with haemorrhage or, more rarely, aberrant larval migration.

The cause of bleeding in patients with angiostrongylosis is not well understood and probably has many factors. Patients commonly have mild increases in prothrombin and activated partial thromboplastin times, with slight reductions in platelet numbers; although bleeding can be seen in patients with no documented changes in coagulation parameters.

These clinical findings, together with experimental work, suggest *A vasorum* triggers a form of compensated state of disseminate intravascular coagulation (DIC). Immune-mediated thrombocytopenia, reduced levels of factors V and VIII and acquired von Willebrand factor deficiency have also been reported. Clinical signs of coagulopathy are very variable and include petechiae ecchymosis and scleral haemorrhage ([Figure 2](#)).

Vascular changes are rarely documented on radiographs and a mixed pattern is more common. A patchy alveolar pattern in the peripheral lung fields is commonly reported ([Figure 3](#)). Haematology and serum biochemistry findings are variable, although eosinophilia is reported in between a quarter to half of cases and hyperglobulinaemia in three-quarters. Hypercalcaemia has been reported; the exact mechanism of this elevation is unclear, but is thought to be secondary to granuloma formation (Boag et al, 2005).

Diagnostic tests

Definitive diagnosis is made on confirming the presence of the parasite or an immunological response to it. Traditionally, this has been done using the modified Baermann flotation; however, this is a time-consuming test and of low sensitivity as the parasite is intermittently shed.

Pooled faecal samples over a three-day period or repeated sampling increases accuracy. A direct faecal smear is simple and quick to perform, with sensitivity of 54 per cent to 61 per cent depending on the experience of the assessor (Humm and Adamantos, 2010). Analysis of tracheobronchial secretions or tracheal wash samples can also confirm the presence of infection ([Figure 4](#)). PCR tests have been developed; however, their sensitivity is disappointing. An in-house ELISA test has been developed to document an antigen produced by adult *A vasorum* using blood samples. Although this test has very good sensitivity (96 per cent) and specificity (94 per cent; Schnyder et al, 2011) a diagnosis of angiostrongylosis should be made in conjunction with clinical signs and supportive evidence, such as imaging findings.

Treatment

In the UK, both imidacloprid/ moxidectin and milbemycin are licensed to treat angiostrongylosis. Imidacloprid/moxidectin has been shown to be effective against both immature and mature *Angiostrongylus* stages, with an efficacy of 85 per cent in a blinded, randomised, controlled field study (Willesen et al, 2007; Schnyder et al, 2009a). Milbemycin has also been used successfully to treat field infections (Conboy 2004a). Although not licensed for treating *A vasorum*, fenbendazole has traditionally been used as the drug of choice, with doses of 25 mg/kg to 50 mg/kg sid suggested for three to 21 days, with similar efficacy to imidacloprid/moxidectin reported (Willesen et al, 2007).

Occasionally, patients will develop worsening respiratory signs after adulticides are administered, especially if worms are killed rapidly; these signs may need to be treated with steroids. Where bleeding is clinically significant, whole blood or fresh frozen plasma may be required. In dogs where disseminated intravascular coagulopathy (DIC) has been documented, transfusion products and heparin may also be considered. In cases with significant pulmonary hypertension, sildenafil is occasionally indicated; however, signs of pulmonary hypertension usually resolve quickly with treatment.

Studies have shown imidacloprid/moxidectin used in the prepatent period clears infection with L4 and immature adult worms, and this now carries a licence in the UK for prevention of angiostrongylosis (Schnyder et al, 2009b). Milbemycin can reduce parasite numbers if used in the prepatent period (Conboy et al, 2004b). Thus, in an endemic area, regular treatment with an effective drug is a sensible strategy to reduce the risks of developing disease.

Other measures, such as removing toys from the garden overnight, limiting access to areas where slugs and snails may be present and regular removal of faecal matter, will further reduce the risks of exposure.

- Please note a number of medications referred to in this article are either not licensed for the indications described or not licensed for use in companion animals. Readers are reminded to follow the cascade and obtain informed consent from owners before prescribing medication.

References and further reading

- Barçante T, Barçante J, Dias S and dos Santos Lima W (2003). *Angiostrongylus vasorum* (Baillet, 1866) Kamensky, 1905: emergence of third-stage larvae from infected *Biomphalaria glabrata* snails, *Parasitology Research* **91**(6): 471-475.
- Boag A, Murphy K and Connolly D (2005). Hypercalcaemia associated with *Angiostrongylus vasorum* in three dogs, *Journal of Small Animal Practice* **46**(2): 79-84.
- Conboy G (2004a). Natural infections of *Crenosoma vulpis* and *Angiostrongylus vasorum* in dogs in Atlantic Canada and their treatment with milbemycin oxime, *Veterinary Record*

155(1):16-18.

- Conboy G, Schenker R and Strehlau G (2004b). Efficacy of Milbemax (milbemycin/praziquantel) for the treatment and prevention of *Angiostrongylus vasorum* infection in dogs, *Proceedings of the Joint AAVP 49th meeting/ASP 79th meeting*, Philadelphia: **92**.
- Cury M, Lima W and Vitor R (1996). Enzyme-linked immunosorbent assay (ELISA) for the diagnosis of *Angiostrongylus vasorum* (Baillet, 1866) infection in dogs [serology], *Revue de médecine vétérinaire*, **147(7)**: 525-530.
- Helm J, Gilleard J, Jackson M, Redman E and Bell R (2009). A case of canine *Angiostrongylus vasorum* in Scotland confirmed by PCR and sequence analysis, *Journal of Small Animal Practice* **50(5)**: 255-259.
- Helm J, Morgan E, Jackson M, Wotton P and Bell R (2010). Canine angiostrongylosis: an emerging disease in Europe, *Journal of Veterinary Emergency and Critical Care* **20(1)**: 98-109.
- Humm K and Adamantos S (2010). Is evaluation of a faecal smear a useful technique in the diagnosis of canine pulmonary angiostrongylosis? *Journal of Small Animal Practice* **51(4)**: 200-203.
- Morgan E and Shaw S (2010). *Angiostrongylus vasorum* infection in dogs: continuing spread and developments in diagnosis and treatment, *Journal of Small Animal Practice* **51(12)**: 616-621.
- Oliveira-Junior S D, Barçante J M P, Barçante T A, Dias S R C and Lima W S (2006). Larval output of infected and re-infected dogs with *Angiostrongylus vasorum* (Baillet, 1866) Kamensky, 1905, *Veterinary Parasitology* **141(1-2)**: 101-105.
- Schnyder M, Fahrion A, Ossent P, Kohler L, Webster P, Heine J and Deplazes P (2009a). Larvicidal effect of imidacloprid/moxidectin spot-on solution in dogs experimentally inoculated with *Angiostrongylus vasorum*, *Veterinary Parasitology* **166(3-4)**: 326-332.
- Schnyder M, Fahrion S and Stabler S (2009b). Clinical and laboratory findings in dogs experimentally infected with *Angiostrongylus vasorum*, *Proceedings of the 19th ECVIM-CA Congress*, Porto: **265**.
- Schnyder M, Tanner I, Webster P, Barutzki D and Deplazes P (2011). An ELISA for sensitive and specific detection of circulating antigen of *Angiostrongylus vasorum* in serum samples of naturally and experimentally infected dogs, *Veterinary Parasitology* **179(1-3)**: 152-158.
- Willesen J, Kristensen A, Jensen A, Heine J and Koch J (2007). Efficacy and safety of imidacloprid/moxidectin spot-on solution and fenbendazole in the treatment of dogs naturally infected with *Angiostrongylus vasorum* (Baillet, 1866), *Veterinary Parasitology* **20(2)**: 258-264.
- Yamakawa Y, McGarry J W, Denk D, Dukes-McEwan J, Macdonald N, Mas A, McConnell F, Tatton B, Valentine E, Wayne J, Williams J and Hetzel U (2009). Emerging canine angiostrongylosis in northern England: five fatal cases, *Veterinary Record* **164(5)**: 149-152.

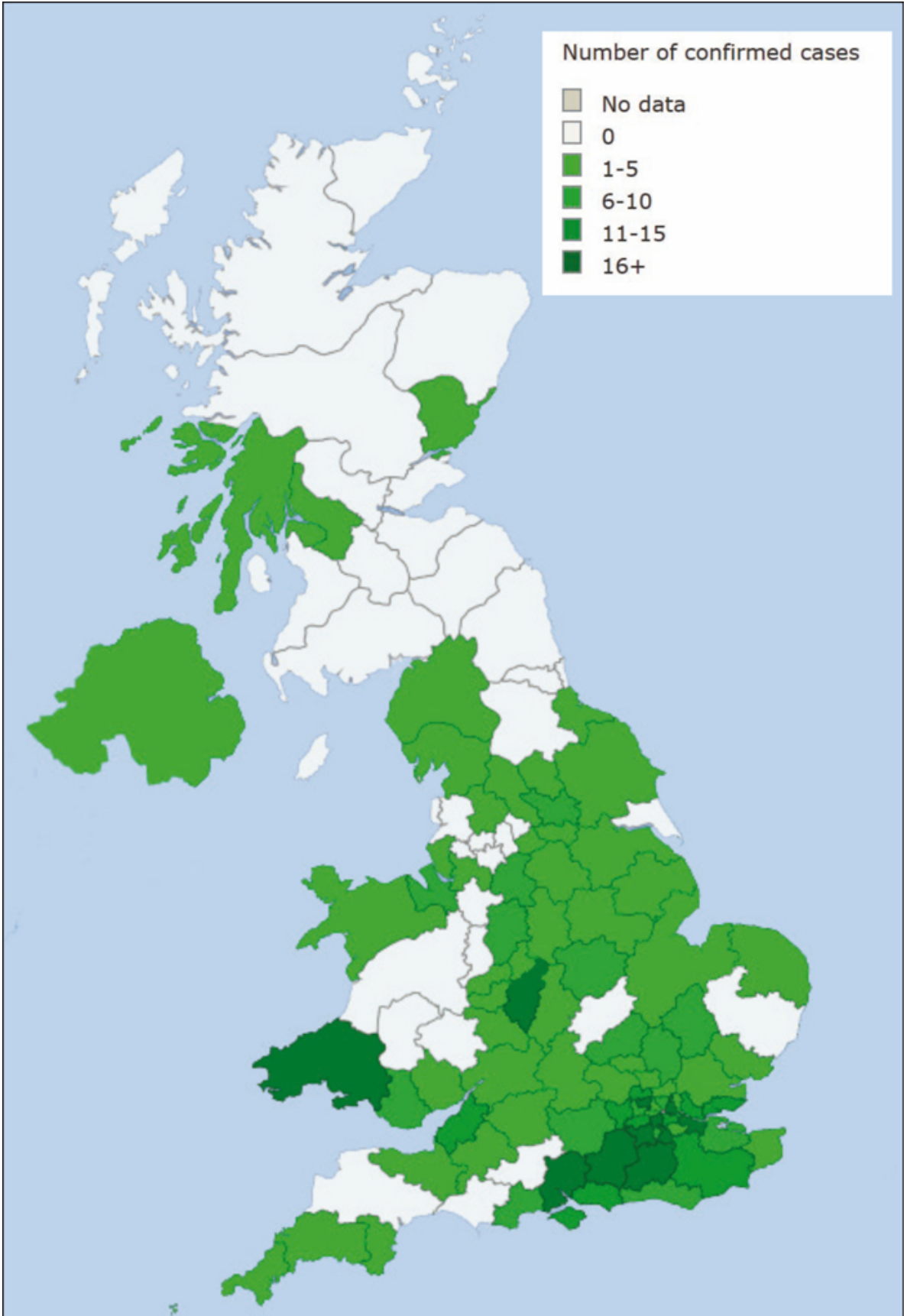


Figure 1. A map showing cases of Angiostrongylosis reported to the <http://angiodetect.co.uk> website as of January 2014.

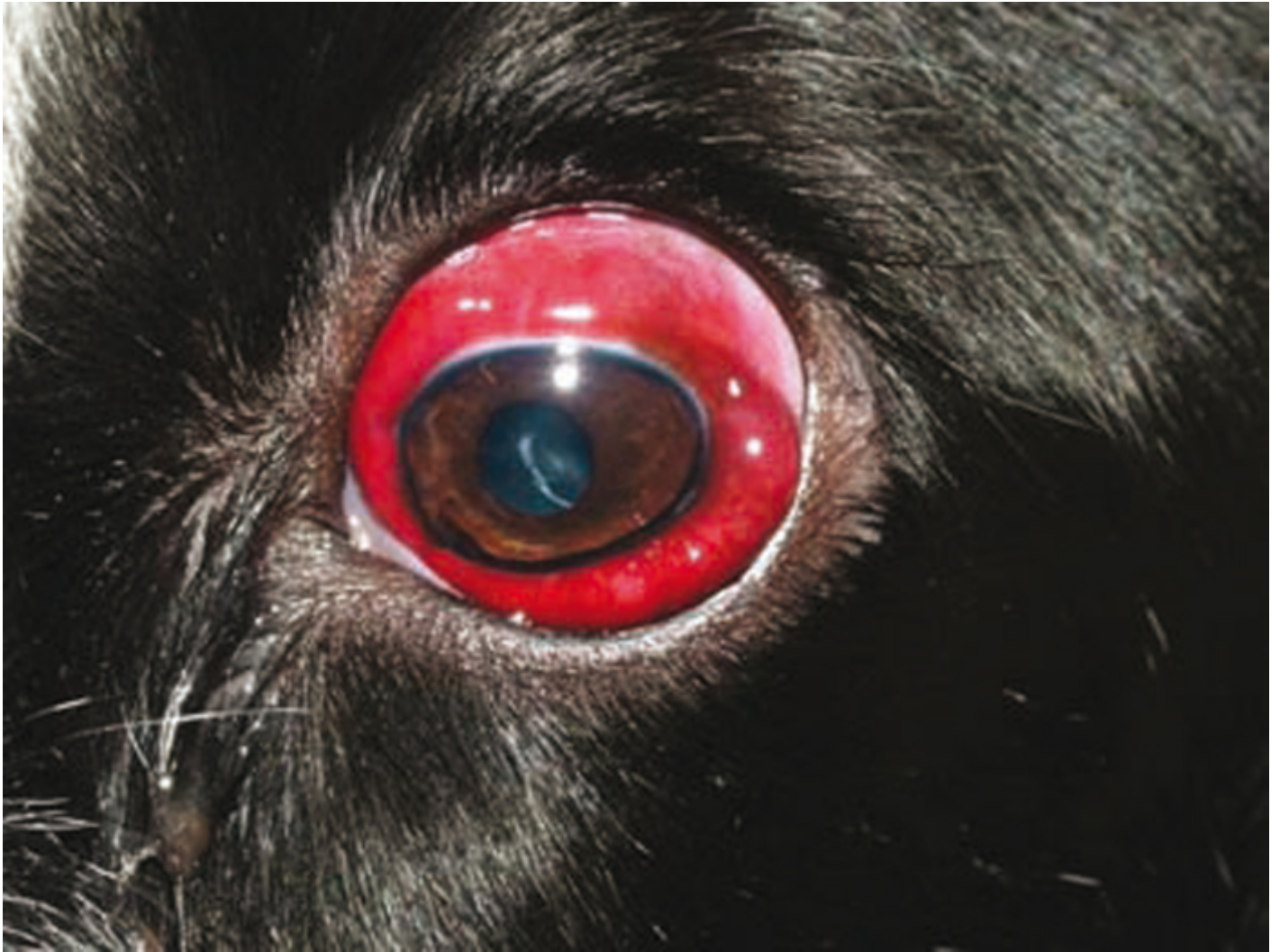

Figure 2. A dog with scleral haemorrhage secondary to infection with *Angiostrongylus vasorum*.

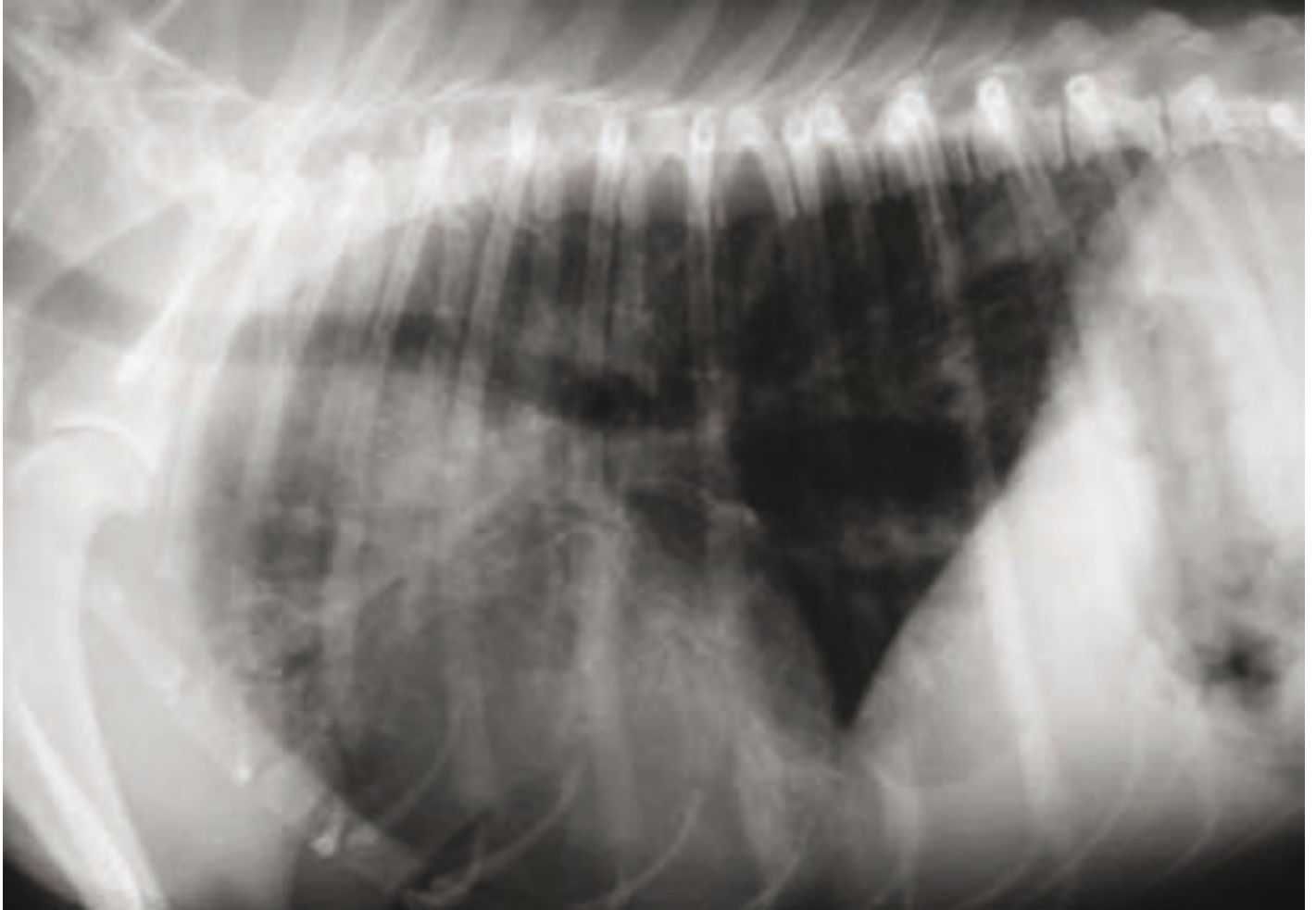


Figure 3. A right lateral thoracic radiograph of the dog in **Figure 2** revealing a patchy peripheral alveolar pattern secondary to infection with *Angiostrongylus vasorum*.

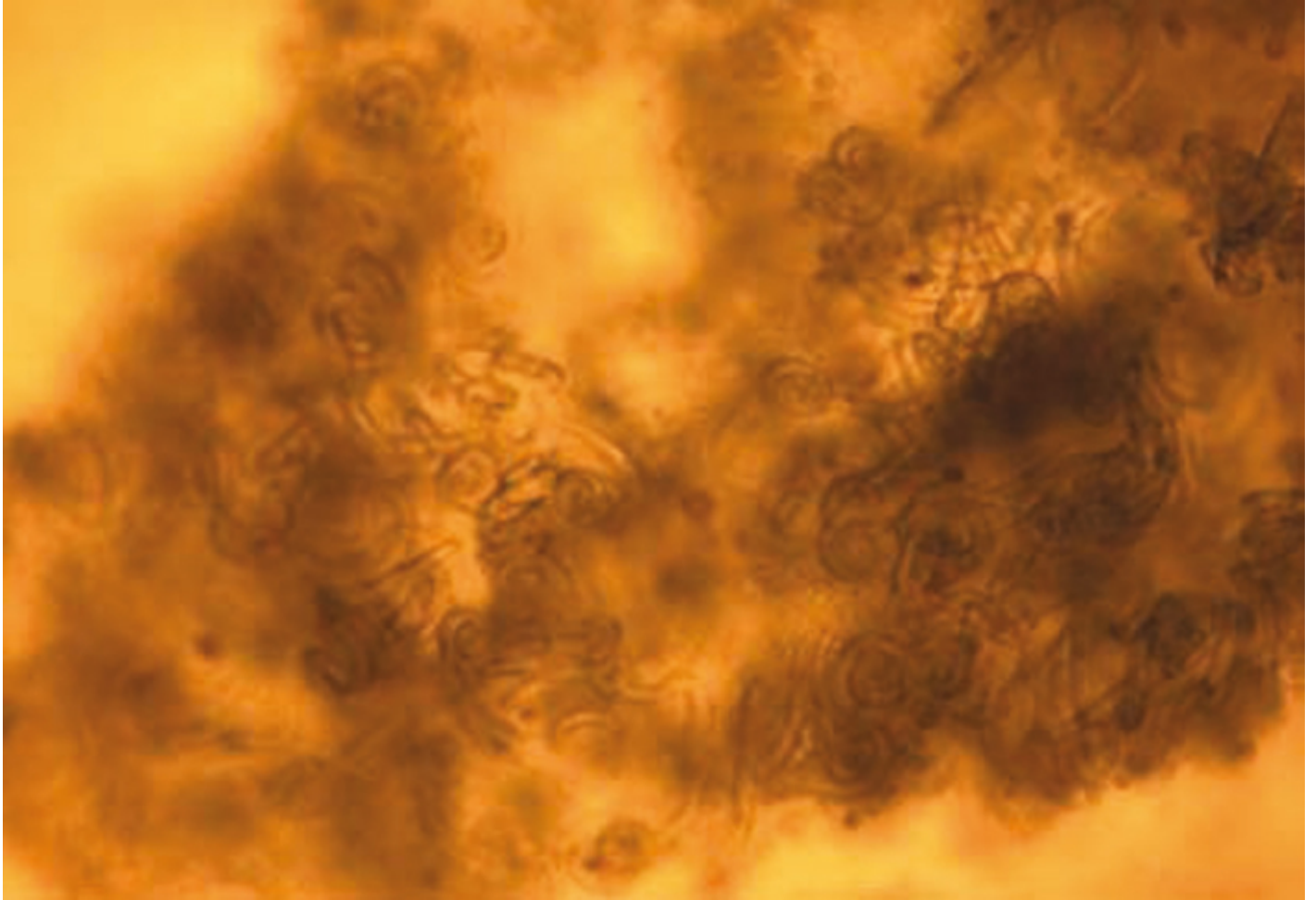


Figure 4. Clumps of *Angiostrongylus vasorum* larvae from a bronchoalveolar lavage sample taken from the dog in **Figures 2 and 3.**