

# Blood cell morphology of Turkish gekkonid lizards

(Squamata: Sauria: Gekkonidae, Phyllodactylidae)

Blutzellmorphologie türkischer Geckos

(Squamata: Sauria: Gekkonidae, Phyllodactylidae)

ONUR UCA & HÜSEYİN ARIKAN & KERİM ÇİÇEK

## KURZFASSUNG

Die Autoren erhoben Daten zur Größe peripherer Blutzellen (Erythrozyten, Leukozyten, Thrombozyten) aus mit Wright-Färbung behandelten Abstrichen für sechs Arten türkische Geckos: *Asaccus barani* TORKI, AHMADZADEH, ILGAZ, AVCI & KUMLUTAS, 2011, *Mediodactylus heterocercus* (BLANFORD, 1874), *Mediodactylus kotschyi* (STEINDACHNER, 1870), *Cyrtopodion scabrum* (HEYDEN, 1827), *Hemidactylus turcicus* (LINNAEUS, 1758) und *Stenodactylus grandiceps* HAAS, 1952.

Die längsten Erythrozyten fanden sich bei *S. grandiceps*, die breitesten und größten bei *A. barani*, die kürzesten bei *C. scabrum*, die schmalsten bei *M. kotschyi* und die kleinsten bei *C. scabrum*. Die längsten und größten Erythrozytenkerne wurden bei *M. heterocercus*, die kürzesten, schmalsten und kleinsten bei *M. kotschyi* und die größten bei *A. barani* gemessen. Bezüglich des Verhältnisses von Länge zu Breite, kamen die länglichsten Erythrozyten bei *S. grandiceps*, die rundlichsten bei *M. kotschyi* vor. Die Kern-Plasma-Relation zeigte bei *C. scabrum* und *M. heterocercus* den größten, bei *S. grandiceps* den geringsten Wert. Die Kern-Plasma-Relation türkischer Geckos war ähnlich der bei türkischen Lacertiden.

Zwischen den untersuchten Geckoarten bestanden beträchtliche Unterschiede in der Gestalt der Erythrozyten und ihrer Kerne, während das für die Leukozytenmorphologie nicht zutraf. Lymphozyten waren die häufigsten Leukozyten bei allen Arten. Die Kerne der eosinophilen und basophilen Granulozyten waren durch die starke Körnung des Zytoplasmas undeutlich. Die Thrombozyten waren bei allen Arten flach ellipsoidisch.

## ABSTRACT

Size parameters of peripheral blood cells (erythrocytes, leucocytes, thrombocytes) obtained from blood smears stained with Wright's stain are given for six species of Turkish gekkonid lizards: *Asaccus barani* TORKI, AHMADZADEH, ILGAZ, AVCI & KUMLUTAS, 2011, *Mediodactylus heterocercus* (BLANFORD, 1874), *Mediodactylus kotschyi* (STEINDACHNER, 1870), *Cyrtopodion scabrum* (HEYDEN, 1827), *Hemidactylus turcicus* (LINNAEUS, 1758) and *Stenodactylus grandiceps* HAAS, 1952.

The longest erythrocytes were found in *S. grandiceps*, the widest and largest in *A. barani*, the shortest in *C. scabrum*, the narrowest in *M. kotschyi* and the smallest in *C. scabrum*. The longest and biggest erythrocyte nuclei were measured in *M. heterocercus*, the shortest, narrowest and smallest in *M. kotschyi* and the largest in *A. barani*. Regarding their length-to-width ratio, the most oblong erythrocytes were found in *S. grandiceps*, the most roundish in *M. kotschyi*. The value of the nucleocytoplasmic ratio was highest in *C. scabrum* and *M. heterocercus*, and lowest in *S. grandiceps*. The nucleocytoplasmic ratio of the gekkonid erythrocytes was similar as in lacertids.

Among the species studied, erythrocyte and nucleus morphology showed considerable variation, whereas, leukocyte morphology did not. Lymphocytes outnumbered the other leucocytes in all species. The nuclei of eosinophils and basophils were not distinct because of intense granulation of the cytoplasm. The thrombocytes were the shape of a flattened ellipsoid in all species.

## KEY WORDS

Reptilia: Squamata: Sauria: Phyllodactylidae, *Asaccus barani*; Gekkonidae, *Cyrtopodion scabrum*, *Hemidactylus turcicus*, *Mediodactylus heterocercus*, *Mediodactylus kotschyi*, *Stenodactylus grandiceps*, blood smears, blood cell morphology, physiology, Turkey

## INTRODUCTION

Blood analyses are widely used tools in the diagnosis and monitoring of animal health and disease and the differentiation of physiological processes (CHRISTOPHER et al. 1999). These techniques are applied with several wildlife species, especially for threatened or endangered populations, and

help to indicate ecosystem health (DEEM et al. 2006). The cellular metabolism, its homeostatic control mechanisms and cellular configuration are optimized for specific requirements and temperature ranges. As a result, the composition of blood varies considerably among reptile groups (DESSAURER 1970).

The studies on the comparative morphology of peripheral blood cells (erythrocytes, leucocytes, thrombocytes) in reptiles mainly concentrated on the seasonal and sexual variation of counts (e.g., SZARSKI 1968; DESSAURER 1970; DUGUY 1970) and size (WINTROBE 1933; HARTMAN & LESSLER 1964; SAINT GIRONS & SAINT GIRONS 1969; SAINT GIRONS 1970; SEVINÇ et al. 2000; SEVINÇ & UĞURTAŞ 2001; ATATÜR et al. 2001; ARIKAN et al. 2009; ARIKAN & ÇIÇEK 2010; ARIKAN & ÇIÇEK 2014), and the diagnosis of blood parasites (ROCA & GALDON 2010). Nevertheless, only a few studies described the morphology and size of circulating blood cells of one or more species (e.g., HARTMAN & LESSLER 1964; SZARSKI & CZOPEK 1966; KNOTKOVÁ et al. 2002).

There are various studies on the comparative morphology of the peripheral blood cells in Turkish lacertids and scincids

(SEVINÇ et al. 2000; SEVINÇ & UĞURTAŞ 2001; ATATÜR et al. 2001; ARIKAN et al. 2009b; ARIKAN & ÇIÇEK 2010), however, knowledge on gekkonids is still limited. In Turkey, these saurians are, according to current knowledge (BARAN & ATATÜR 1998; UETZ & HOŠEK 2016), represented by two families (Phyllodactylidae and Gekkonidae), five genera and six species [*Asaccus barani* TORKI, AHMADZADEH, ILGAZ, AVCI & KUMLUTAŞ, 2011, *Mediodactylus heterocercus* (BLANFORD, 1874), *Mediodactylus kotschy* (STEINDACHNER, 1870), *Cyrtopodion scabrum* (HEYDEN, 1827), *Hemidactylus turcicus* (LINNAEUS, 1758), *Stenodactylus grandiceps* HAAS, 1952]. The objective of the present study was to obtain and discuss comparative information on morphology and size of peripheral blood cell types in these six gekkonid species from Turkey.

## MATERIALS AND METHODS

The study sample comprises a total of sixteen specimens collected in April and May 2000 to 2010 at various localities in Turkey (Table 1). Sexes were not distinguished. The blood samples were obtained according to MACLEAN et al. (1973), from postorbital sinuses using heparinized glass capillaries. Three smears per sample were measured and evaluated individually.

The blood smears prepared were stained with Wright's stain. The cells were measured under a light microscope, using a MOB-1-15x LOMO eyepiece ocular micrometer. From each blood smear, 40 erythrocytes were randomly chosen and their

lengths (EL), widths (EW) nuclear lengths (NL) and nuclear widths (NW) measured. The volumes of erythrocytes (EV) and their nuclei (NV) were calculated according to the formulae  $EV = (EL \cdot EW^2) \cdot (\pi/6)$  [ $\mu\text{m}^3$ ] and  $NV = (NL \cdot NW^2) \cdot (\pi/6)$  [ $\mu\text{m}^3$ ]. The cellular and nuclear shapes were compared using the EL/EW and NL/NW ratios while the comparison of the nucleocytoplasmic ratios (NR) were calculated according to the formula  $NR = NV/(EV-NV)$ . Besides, measurements of the largely spherical leukocytes (lymphocytes, monocytes, heterophils, eosinophils, basophils) and thrombocytes (length and width; TL, TW) were made.

Table 1: Collecting localities of the Turkish gekkonid specimens used in the present comparative hematological study. N – number of individuals.

Tab. 1: Fundorte der türkischen Geckos, die zur vorliegenden hämatologischen Untersuchung verwendet wurden. N – Anzahl der Individuen.

Species / Art	N	Locality / Fundort	Latitude / geogr. Breite	Longitude / geogr. Länge
<i>Asaccus barani</i>	2	Birecik-Urfa	37.025002	37.976955
<i>Mediodactylus heterocercus</i>	2	Mardin	37.301906	40.730414
<i>Mediodactylus kotschy</i>	4	Halfeti-Şanlıurfa	37.247000	37.866667
<i>Cyrtopodion scabrum</i>	2	Şanlıurfa	37.120305	38.784801
<i>Hemidactylus turcicus</i>	4	Mut-Mersin	36.644337	33.435555
<i>Stenodactylus grandiceps</i>	2	Kilis	36.718399	37.121220

The photographs of the blood cells were taken with an Olympus CX21-Altra 20 Soft Imaging Solutions system.

Since the measured data was normally distributed (Kolmogorov-Smirnov D test,  $P \geq 0.05$ ), parametric one-way ANOVA was used to determine the variation of peripher-

al blood cell morphology among species. The alpha level was set at 0.05, and the mean values were provided with their standard deviations. All statistical analyses were performed using PAST statistical package (HAMMER et al. 2001).

## RESULTS

The typical shape of erythrocytes in gekkonid lizards is oval, as is the case with fish, amphibians and other reptile species. Their nuclei are also oval and almost located at the centre of the cell. In Wright-stained preparations, cytoplasm looks light yellowish pink and chromophilic nuclei are dark purplish blue (Figs. 1A, 1B, 1C).

In the blood preparations considerable variation regarding length, width and volume of the erythrocytes was detected among species and even conspecifics. Potential differences in the physiological status, age or sex may have caused the observed high degree of variation among conspecifics. For the erythrocyte measurements, see Table 2.

The averages of the individual species' erythrocyte length, width, volume, and EL/EW ratio were ranged from 14.83 - 18.62  $\mu\text{m}$ , 8.34 - 9.94  $\mu\text{m}$ , 541.83 - 924.37  $\mu\text{m}^3$ , and 1.72 - 2.00, respectively. The longest erythrocytes were found in *S. grandiceps* (Fig. 1C, one-way ANOVA,  $F_{\text{EL}} = 72.20$ ,  $p < 0.01$ ); the widest and largest in *A. barani* ( $F_{\text{EW}} = 28.59$ ,  $p < 0.01$ ;  $F_{\text{ES}} = 58.54$ ,  $p < 0.01$ ), the shortest in *C. scabrum*, the narrowest in *M. kotschyi* and the smallest in *C. scabrum*. In terms of the EL/EW ratio, the most elongate erythrocytes were found in *S. grandiceps*, the most rounded ones in *M. kotschyi* (Table 2,  $F_{\text{EL/EW}} = 16.35$ ,  $p < 0.01$ ).

The averages of the individual species' nuclear length, width, and volume were ranged from 6.66 - 7.57  $\mu\text{m}$ , 3.69 - 4.59  $\mu\text{m}$  and 52.78 - 83.48  $\mu\text{m}^3$ , respectively, the mean length-to-width ratios (NL/NW) from 1.52 - 2.05. The species' mean nucleocytoplasmic ratios ranged between 0.07 - 0.15. The longest and biggest nuclei were measured in *M. heterocercus* ( $F_{\text{NL}} = 17.93$ ,  $p < 0.01$ ;  $F_{\text{NV}} = 41.33$ ,  $p < 0.01$ ); the shortest, narrowest ( $F_{\text{NW}} = 58.81$ ,  $p < 0.01$ ) and smallest in *M. kotschyi* and the largest in *A. barani*. When

the ratio NL/NW was considered, the most elongate nuclei were found in *S. grandiceps* and the most rounded ones in *A. barani* ( $F_{\text{NL/NW}} = 57.48$ ,  $p < 0.01$ ). The nucleocytoplasmic ratio was highest in *C. scabrum* and *M. heterocercus*, and lowest in *S. grandiceps* ( $F_{\text{NR}} = 99.75$ ,  $p < 0.01$ ; Table 2).

Regarding leucocytes, both small and large lymphocytes were observed as the dominant cells in the blood smears of all gekkonid species. Agranulocytes (lymphocytes and monocytes) constituted 80 % of the leucocytes of the examined species. The average diameter of small lymphocytes was biggest (10.34  $\mu\text{m}$ ) in *S. grandiceps* and smallest (7.11  $\mu\text{m}$ ) in *C. scabrum* (Table 3). In small lymphocytes, the spherical nuclei were more chromophilic and localized in a certain cell zone than in large lymphocytes in which the cytoplasm covered a larger area and was stained a pale blue, whereas, nuclei were stained a purplish blue with Wright's stain (Figs. 1D, 1E). The average diameter of large lymphocytes was biggest (15.18  $\mu\text{m}$ ) in *S. grandiceps*, and smallest (10.71  $\mu\text{m}$ ) in *C. scabrum* (Table 3).

Monocytes resembled large lymphocytes from which they were easily differentiated by their kidney-shaped nuclei. Cytoplasm was stained a light gray, and the nuclei a dark purplish blue with Wright's stain (Fig. 1F). The average monocyte diameter was biggest in *M. heterocercus* (14.58  $\mu\text{m}$ ), and smallest (10.50  $\mu\text{m}$ ) in *S. grandiceps* and *M. kotschyi* (Table 3).

Among the granulocytes, heterophils had light blue cytoplasm and numerous granules of ellipsoidal shape. Their bilobate nuclei were stained a dark purplish blue color with Wright's stain (Fig. 1G, 1H). The mean diameter of heterophil granulocytes was biggest (12.44  $\mu\text{m}$ ) in *S. grandiceps* and smallest (11.00  $\mu\text{m}$ ) in *M. kotschyi* (Table 3).

Table 2: Descriptive statistics of the size of erythrocytes and their nuclei in the peripheral blood of six gekkonid species from Turkey. EL – erythrocyte length, EW – erythrocyte width, EL/EW – erythrocyte aspect ratio, EV – erythrocyte volume, NL – nucleus length, NW – nucleus width, NV – nucleus volume; NR – nucleocytoplasmic ratio, N – sample size, mean – arithmetic mean, SE – standard error of the mean, Min – minimum, Max – maximum, SD – standard deviation.

Tab. 2: Deskriptive Statistiken der Größe von Erythrozyten und ihren Kernen im peripheren Blut von sechs Gekkoarten der Türkei. EL – Erythrozytenlänge, EW – Erythrozytenbreite, EL/EW – Erythrozytenformfaktor, EV – Erythrozytenvolumen, NL – Kernlänge, NW – Kernbreite, NV – Kernvolumen; NR – Kern-Plasma-Verhältnis, N – Stichprobengröße, mean – arithmetisches Mittel, SE – Standardfehler des Mittelwertes, Min – Minimum, Max – Maximum, SD – Standardabweichung.

Species / Art	N	EL (µm)	EW (µm)	EL/EW	EV (µm <sup>3</sup> )	NL (µm)	NW (µm)	NL/NW	NV (µm <sup>3</sup> )	NR
<i>A. barani</i>	Mean	17.78	9.94	1.79	924.37	6.95	4.59	1.52	77.00	0.09
	SE	0.11	0.09	0.02	19.73	0.05	0.04	0.01	1.73	0.003
	Min	16.25	9.00	1.59	727.64	6.25	4.00	1.35	52.33	0.06
	Max	19.00	11.25	2.03	1208.78	7.50	5.00	1.76	98.13	0.13
	SD	0.68	0.57	0.10	124.75	0.32	0.26	0.08	10.92	0.017
<i>M. heterocercus</i>	Mean	16.16	8.81	1.84	656.93	7.57	4.59	1.65	83.48	0.15
	SE	0.20	0.06	0.03	11.65	0.08	0.02	0.02	1.26	0.003
	Min	13.50	8.25	1.54	534.29	6.25	4.50	1.39	66.23	0.11
	Max	19.75	9.75	2.26	837.20	8.50	5.00	1.89	100.37	0.19
	SD	1.29	0.36	0.16	73.70	0.50	0.13	0.11	7.97	0.019
<i>M. kotschyi</i>	Mean	16.15	9.48	1.72	771.11	6.66	3.84	1.75	52.78	0.08
	SE	0.12	0.16	0.03	30.84	0.09	0.08	0.03	2.77	0.005
	Min	14.50	7.50	1.40	500.44	5.50	3.00	1.38	25.91	0.02
	Max	17.50	12.50	2.27	1430.99	8.00	5.00	2.23	104.67	0.17
	SD	0.78	1.01	0.18	195.06	0.60	0.50	0.2	17.51	0.034
<i>C. scabrum</i>	Mean	14.83	8.34	1.78	541.83	7.08	4.38	1.62	70.93	0.15
	SE	0.10	0.07	0.01	10.92	0.06	0.02	0.02	0.87	0.003
	Min	14.00	7.00	1.54	359.01	6.50	4.25	1.44	61.44	0.11
	Max	16.50	9.25	2.00	716.44	8.25	4.50	1.94	82.13	0.21
	SD	0.65	0.43	0.09	69.04	0.37	0.13	0.10	5.49	0.022
<i>H. turcicus</i>	Mean	16.52	8.91	1.85	689.95	7.44	4.41	1.69	75.69	0.13
	SE	0.22	0.07	0.02	15.82	0.09	0.02	0.02	1.14	0.003
	Min	14.50	8.25	1.57	525.39	6.25	4.25	1.44	59.08	0.09
	Max	20.50	9.75	2.28	945.24	8.75	4.50	2.06	90.08	0.17
	SD	1.37	0.42	0.15	100.06	0.58	0.12	0.12	7.18	0.018
<i>S. grandiceps</i>	Mean	18.62	9.37	2.00	867.74	7.50	3.69	2.05	55.13	0.07
	SE	0.15	0.15	0.03	30.20	0.12	0.08	0.04	2.88	0.003
	Min	16.25	7.25	1.71	488.26	5.25	2.50	1.67	17.17	0.03
	Max	20.50	11.00	2.72	1298.13	9.25	5.00	2.75	111.21	0.12
	SD	0.97	0.94	0.20	190.99	0.76	0.50	0.24	18.21	0.022

Table 3: Descriptive statistics of the size of leukocytes and thrombocytes in the peripheral blood of six gekkonid species from Turkey. TL – thrombocyte length, TW – thrombocyte width, N – sample size, Mean – arithmetic mean, SE – standard error of the mean, Min – minimum, Max – maximum SD – standard deviation.  
 Tab. 3: Deskriptive Statistiken der Größe von Leukozyten und Thrombozyten im peripheren Blut von sechs Gekkoarten der Türkei. TL – Thrombozytenlänge, TW – Thrombozytenbreite, N – Stichprobengröße, Mean – arithmetisches Mittel, SE – Standardfehler des Mittelwertes, Min – Minimum, Max – Maximum, SD – Standardabweichung.

Species / Art	Lymphocyte (large) / (groß) (µm)	Lymphocyte (small) / (klein) (µm)	Monocyte (µm)	Heterophil granulocyte (µm)	Eosinophil granulocyte (µm)	Basophil granulocyte (µm)	TL (µm)	TW (µm)
<i>A. barani</i>	N	8	5	5	4	7	10	10
	Mean	12.56	7.59	11.50	11.15	10.44	10.32	9.48
	SE	0.35	0.14	0.18	0.10	0.12	0.09	0.30
	Min	11.00	7.00	11.00	11.00	10.25	10.00	7.50
	Max	14.00	8.25	12.00	11.50	10.75	10.75	13.00
<i>M. heterocercus</i>	SD	0.99	0.40	0.40	0.22	0.24	0.24	0.95
	N	9	10	6	9	6	7	10
	Mean	11.11	7.50	14.58	12.42	10.50	10.18	7.00
	SE	0.15	0.06	0.17	0.29	0.09	0.11	0.05
	Min	10.00	7.25	14.00	11.25	10.25	9.75	6.75
<i>M. kotschy</i>	Max	11.50	7.75	15.00	13.50	10.75	10.50	7.25
	SD	0.45	0.20	0.41	0.87	0.22	0.28	0.17
	N	8	7	6	6	6	6	6
	Mean	14.31	9.82	10.50	11.00	8.96	10.42	6.67
	SE	0.16	0.19	0.26	0.14	1.80	0.08	0.14
<i>C. scabrum</i>	Min	13.75	9.25	10.00	10.50	0.00	10.25	4.25
	Max	15.00	10.75	11.50	11.50	11.25	10.75	4.75
	SD	0.46	0.49	0.63	0.35	4.40	0.20	0.34
	N	7	7	8	6	6	5	10
	Mean	10.71	7.11	12.91	11.42	10.00	10.00	7.08
<i>H. turicus</i>	SE	0.25	0.19	0.14	0.18	0.09	0.08	0.08
	Min	9.50	6.25	12.50	10.75	9.75	9.75	6.75
	Max	11.50	7.75	13.50	12.00	10.25	10.25	7.50
	SD	0.65	0.50	0.40	0.44	0.22	0.18	0.21
	N	8	8	5	5	3	7	7
<i>S. grandiceps</i>	Mean	12.81	8.03	12.30	11.20	10.75	10.50	6.75
	SE	0.32	0.06	0.38	0.09	0.14	0.08	0.19
	Min	11.50	7.75	11.00	11.00	10.50	10.25	6.00
	Max	14.00	8.25	13.25	11.50	11.00	10.75	7.50
	SD	0.91	0.16	0.86	0.21	0.25	0.20	0.50
<i>S. grandiceps</i>	N	10	8	5	9	7	7	10
	Mean	15.18	10.34	10.50	12.44	10.43	10.21	10.65
	SE	0.20	0.09	0.18	0.19	0.16	0.16	0.20
	Min	14.50	10.00	10.00	11.50	10.25	9.75	9.75
	Max	16.25	10.75	11.00	13.25	11.00	11.00	11.50
SD	0.64	0.27	0.40	0.56	0.31	0.42	0.63	

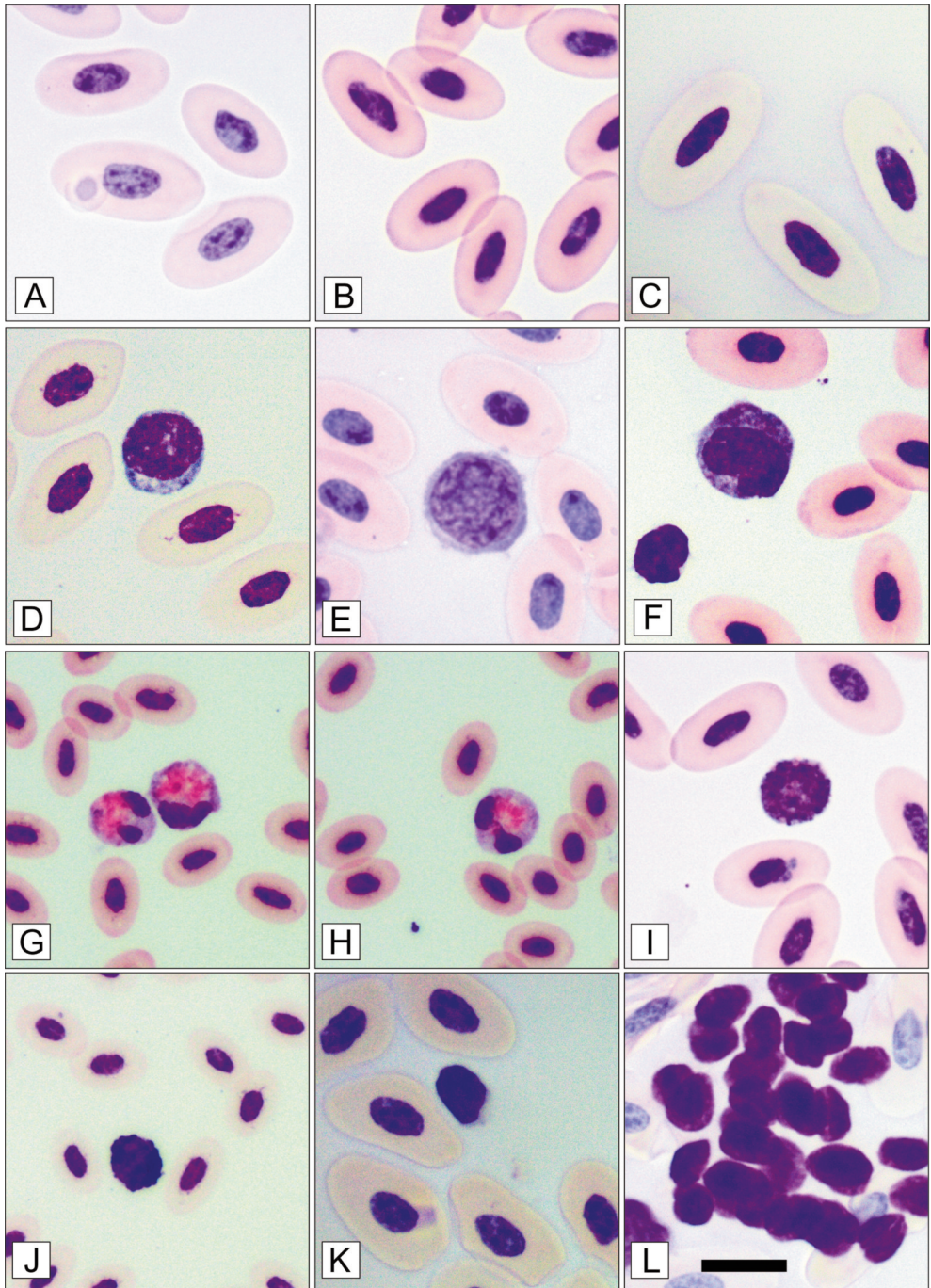


Fig. 1: For legend see opposite page. / Abb. 1: Legende siehe gegenüberliegende Seite.

The cytoplasm of eosinophil granulocytes was stained a light yellowish color with Wright's stain. Since the nucleus was masked by large and bright red granules in the cytoplasm, its shape couldn't be distinguished clearly (Fig. 1I). The mean diameter of eosinophils was biggest (10.75  $\mu\text{m}$ ) in *H. turcicus* and smallest (8.96  $\mu\text{m}$ ) in *M. kotschyi* (Table 3).

The cytoplasm of the basophil granulocytes was filled with black granules,

which masked the nucleus just like in the eosinophils (Fig. 1J). The mean diameter of basophils, which was smaller than of other granulocytes, was biggest (10.50  $\mu\text{m}$ ) in *H. turcicus* and smallest (10.00  $\mu\text{m}$ ) in *C. scabrum* (Table 4).

Thrombocytes were of flattened ellipsoidal shape, their nuclei filling nearly the whole cell (Figs. 1K, 1L). The longest and largest thrombocytes were observed in *A. barani*, the shortest and narrowest in *H. turcicus*.

## DISCUSSION

Reptilian erythrocytes are similar in function and appearance to the birds' red blood cells but differ in size and number. Among reptiles, the largest erythrocytes are observed in *Sphenodon punctatus* GRAY, 1831, turtles and crocodiles, the smallest in lacertid lizards (HARTMAN & LESSLER 1964; SAINT GIRONS & SAINT GIRONS 1969; SAINT GIRONS 1970; SEVINÇ et al. 2000). This heterogeneity in blood cell morphology is not only considerable between orders but even within families (e.g., HARTMAN & LESSLER 1964; SZARSKI & CZOPEK 1966; SAINT GIRONS & SAINT GIRONS 1969; SAINT GIRONS 1970; ARIKAN et al. 2009a, 2009b, 2010).

ARIKAN & ÇIÇEK (2010) studied the morphology of peripheral blood cells of various Turkish reptilian species, noted that there is considerable variation in the size of erythrocytes among or within lizard families and hypothesized that erythrocyte size might be correlated with differences in the species-specific activity levels. These authors found the largest erythrocytes in *Varanus griseus* (DAUDIN, 1803), the smallest in *Ophisops*

*elegans* MÉNÉTRIÉS, 1832. In terms of the EL/EW ratio, the most elongate cells were determined in *Lacerta pamphylica* SCHMIDTLER, 1975, and the most spherical in *Anatololacerta danfordi* (GÜNTHER, 1876).

As regards reptiles from Turkey, the erythrocyte and nucleus volumes observed by ARIKAN & ÇIÇEK (2010, 2014) were 366.88 - 675.01  $\mu\text{m}^3$  and 46.15 - 68.50  $\mu\text{m}^3$  for lacertids, and 421.52 - 497.98  $\mu\text{m}^3$  and 16.15 - 26.72  $\mu\text{m}^3$  for scincids; the nucleocytoplasmic ratios ranged between 0.04-0.05 in scincids and 0.10-0.13 in lacertids.

In the present study, the largest erythrocytes were seen in *Asaccus barani*, the smallest in *Cyrtopodium scabrum*, the most elongate in *Stenodactylus grandiceps*, the most spherical in *Mediodactylus kotschyi*.

The mean values of the nucleocytoplasmic ratios were between 0.07 and 0.15 for gekkonids. Concerning the nucleocytoplasmic ratio, the gekkonids studied resembled the lacertids.

Lymphocytes were the dominant cells in the blood smears of many reptile species

Fig. 1 (opposite page) / Abb. 1 (gegenüberliegende Seite):

Photomicrographs of erythrocytes, leukocytes and thrombocytes of some Turkish geckos.  
 Erythrocytes: A - *A. barani*, B - *C. scabrum*, C - *S. grandiceps*. Leukocytes: D - small lymphocyte (*M. heterocercus*), E - large lymphocyte (*C. scabrum*), F - monocyte (*H. turcicus*). Granulocytes: G - heterophil (*C. scabrum*), H - heterophil (*C. scabrum*), I - eosinophil (*C. scabrum*), J - basophil (*C. scabrum*).  
 Thrombocyte: K - (*M. kotschyi*), L - an aggregate of thrombocytes (*S. grandiceps*). Horizontal bar: 20  $\mu\text{m}$ .  
 Mikroskopische Aufnahmen von Erythrozyten, Leukozyten und Thrombozyten einiger türkischer Geckoarten.  
 Erythrozyten: A - *A. barani*, B - *C. scabrum*, C - *S. grandiceps*. Leukozyten:  
 D - kleiner Lymphozyt (*M. heterocercus*), E - großer Lymphozyt (*C. scabrum*), F - Monozyt (*H. turcicus*).  
 Granulozyten: G - heterophiler (*C. scabrum*), H - heterophiler (*C. scabrum*), I - eosinophiler (*C. scabrum*),  
 J - basophiler (*C. scabrum*). Thrombozyt: K - *M. kotschyi*, L - ein Aggregat von Thrombozyten  
 (*S. grandiceps*). Balkenlänge entspricht 20  $\mu\text{m}$ .

(e.g., ARIKAN et al. 2004, 2009a, 2010), and the nuclei of eosinophils and basophils were not easily distinguished as they were masked by dense granulation in the cytoplasm. Identical results were obtained for six gekkonid species in the present study.

Reptilian thrombocytes appear as flattened ellipsoidal cells with pale cytoplasm and centrally localized, extremely chromophilic nucleus which largely fills the cell (SAINT GIRONS 1970; CANFIELD & SHEA 1988;

ARIKAN et al. 2004, 2009a, 2010), which is in full agreement with the observations made here for six gecko species. The largest thrombocytes were observed in *A. barani*, the smallest in *H. turcicus*.

In conclusion, the present data details the considerable morphological variation of peripheral blood cells of six gekkonid species occurring in Turkey. Considering the nucleocytoplasmic ratio, the gekkonids were more similar to lacertids than scincids.

#### ACKNOWLEDGMENTS

The manuscript of this paper is based partly on the MSc thesis of the first author, Onur UCA (UCA, O. 2015: Blood cell morphology of Gekkonidae species

inhabiting Turkey. Ege University, Graduate School of Natural and Applied Sciences, Izmir, Turkey, pp. 16 (in Turkish).

#### REFERENCES

- ALLEMAN, A. R. & JACOBSON, E. R. & RASKINS, R. E. (1999): Morphologic, cytochemical staining, and ultrastructural characteristics of blood cells from eastern diamondback rattlesnakes (*Crotalus adamanteus*).- American Journal of Veterinary Research, Chicago; 53: 1645-1651.
- ALTMAN, P. L. & DITTMER, D. S. (Eds.) (1961): Blood and other body fluids. Washington, D.C. Federation of the American Societies for Experimental Biology, pp. XVII, 540.
- ARIKAN, H. & ÇİÇEK, K. (2010): Morphology of peripheral blood cells from various species of Turkish Herpetofauna.- Acta Herpetologica, Genova; 5 (2): 179-198.
- ARIKAN, H. & ÇİÇEK, K. (2014): Haematology of amphibians and reptiles: a review.- North-Western Journal of Zoology, Oradea; 10 (1): 190-209.
- ARIKAN, H. & GÖCMEK, B. & ATATÜR, M. K. & KUMLUTAŞ, Y. & ÇİÇEK, K. (2009a): Morphology of peripheral blood cells from various Turkish snakes.- North-Western Journal of Zoology, Oradea; 5: 61-73.
- ARIKAN, H. & GÖCMEK, B. & YILDIZ, M. Z. & KUMLUTAŞ, Y. & ILGAZ, Ç. (2009b): Morphology of peripheral blood cells from some lacertid lizards from Turkey.- Russian Journal of Herpetology, Moskva; 16: 101-106.
- ARIKAN, H. & KUMLUTAŞ, Y. & TÜRKÖZAN, O. & BARAN, İ. & ILGAZ, Ç. (2004): The morphology and size of blood cells of some viperid snakes from Turkey.- Amphibia-Reptilia, Leiden; 25: 465-470.
- ATATÜR, M. K. & ARIKAN, H. & ÇEVİK, İ. E. & MERMER, A. (2001): Erythrocyte measurements of some scincids from Turkey.- Turkish Journal of Zoology, Ankara; 25: 149-152.
- BARAN, İ. & ATATÜR, M. K. (1998): Turkish herpetofauna (amphibians & reptiles). Ankara (Republic of Turkey, Ministry of Environment), pp. 214.
- CAMPBELL, T. W. (2004): Hematology of lower vertebrates; pp. 1214.1104. In: ACVP & ASVCP (Eds.): Proceedings of the 55th Annual Meeting of the American College of Veterinary Pathologists (ACVP) and 39th Annual Meeting of the American Society of Clinical Pathology (ASVCP), Middleton WI, USA. [Internet Publisher: International Veterinary Information Service IVIS, Ithaca, NY < <http://wildlifehematology.uga.edu/FurtherReading/Campbell%202004.pdf> >].
- CANFIELD, P. J. & SHEA, G. M. (1988): Morphological observations on the erythrocytes, leucocytes and thrombocytes of blue tongue lizards (Lacertilia: Scincidae, *Tiliqua*).- Anatomia, Histologia, Embryologia, Berlin; 17: 328-342.
- CANNON, M. S. & FREED, D. A. & FREED, P. S. (1996): The leucocytes of the rougtail gecko *Cryptopodion*: a bright-field and phase-contrast study.- Anatomia, Histologia Embryologia, Berlin; 25: 11-14.
- CLAVER, J. A. & QUAGLIA, A. I. E. (2009): Comparative morphology, development, and function of blood cells in nonmammalian vertebrates.- Journal of Exotic Pet Medicine, Philadelphia; 18: 87-97.
- DEEM, S. L. & DIERENFELD, E. S. & SOUNGUET, G. P. & ALLEMAN, A. R. & CRAY, C. & POPPENGA, R. H. & NORTON, T. M. & KARESH, W. B. (2006): Blood values in free-ranging nesting leatherback sea turtles (*Dermochelys coriacea*) on the coast of the Republic of Gabon.- Journal of Zoo and Wildlife Medicine, Lawrence; 37: 464-471.
- DESSAUER, H. C. (1970): Blood chemistry of reptiles: physiological and evolutionary aspects; pp. 1-72. In: GANS, C. & PARSONS, T. S. (Eds.): Biology of the Reptilia; Vol. 3, Morphology C. London & New York (Academic Press).
- DUGUY, R. (1970): Numbers of blood cells and their variation. pp. 93-109. In: GANS, C. & PARSONS, T. S. (Eds.): Biology of the Reptilia; Vol. 3, Morphology C., London & New York (Academic Press).
- FRYE, F. L. (1991): Hematology as applied to clinical reptile medicine. pp. 209-280. In: FRYE, F. L. (Ed.): Biomedical and surgical aspects of captive reptile husbandry; Vol. 1. Malabar (Krieger Publishing Co.).
- GULLIVER, G. (1840): On the blood corpuscles of the Crocodilia.- Proceedings of the Zoological Society of London, London; 8: 131-133.
- GULLIVER, G. (1842): On the blood corpuscles of the British ophidians, reptiles and other oviparous



- vertebrates.- Proceedings of the Zoological Society of London, London; 10: 108-111.
- GULLIVER, G. (1875): Observations on the sizes and shapes of the red corpuscles of the blood of the vertebrates with drawings of them to a uniform scale, and extended and revised tables of measurements.- Proceedings of the Zoological Society of London, London, 43: 474-495.
- HAMMER, Ø. & HARPER, D. A. T. & RYAN, P. D. (2001): PAST: Paleontological Statistics Software Package for Education and Data Analysis. *Palaeontologia Electronica* 4 (1): pp. 9 [WWW resource available at < [http://palaeo-electronica.org/2001\\_1/past/past.pdf](http://palaeo-electronica.org/2001_1/past/past.pdf) >].
- HARTENSTEIN, V. (2006): Blood cells and blood cell development in the animal kingdom.- *Annual Review of Cell and Developmental Biology*, Palo Alto; 22: 677-712.
- HARTMAN, F. A. & LESSLER, M. A. (1964): Erythrocyte measurements in fishes, amphibia and reptiles.- *Biological Bulletin*, Woods Hole; 126: 83-88.
- JORDAN, H. E. (1938): Comparative hematology; pp. 699-839. In: DOWNEY, H. (Ed.): *Handbook of hematology*; Vol 2. New York (Harper and Brothers).
- KNOTKOVÁ, Z. & DOUBEK, J. & KNOTEK, Z. & HAJKOVÁ, P. (2002): Blood cell morphology and plasma biochemistry in Russian tortoises.- *Acta Veterinaria*, Brno; 71: 191-198.
- MACLEAN, G. S. & LEE, S. K. & WILSON, K. F. (1973): A simple method of obtaining blood from lizards.- *Copeia*, Washington; 1973 (2): 338-339.
- MADER, D. R. (2000): Normal hematology of reptiles; pp. 1126-1132. In: FELDMAN, B. F. & ZINKL, J. G. & JAIN, N. C. (Eds.): *Veterinary hematology*. Philadelphia (Lippincott, Williams & Wilkins).
- ROCA, V. & GALDÓN, M. A. (2010): Haemogregarine blood parasites in the lizards *Podarcis bocagei* (SEOANE) and *P. carbonelli* (PÉREZ-MELLADO) (Sauria: Lacertidae) from NW Portugal.- *Systematic Parasitology*, Dordrecht; 75: 75-79.
- SAINT GIRONS, M. C. & SAINT GIRONS, H. (1969): Contribution à la morphologie comparée des érythrocytes chez les reptiles.- *British Journal of Herpetology*, London; 4: 67-82.
- SAINT GIRONS, M. C. (1970): Morphology of the circulating blood cells; pp. 73-91. In: GANS, C. & PARSONS, T. S. (Eds.): *Biology of Reptilia*; Vol. 3, Morphology C. London & New York (Academic Press).
- SEVINÇ, M. & UĞURTAŞ, İ. H. (2001): The morphology and size of blood cells of *Lacerta rudis bithynica* (Squamata, Reptilia) in Turkey.- *Asiatic Herpetological Research*, Berkeley; 9: 122-129.
- SEVINÇ, M. & UĞURTAŞ, İ. H. & YILDIRIMHAN, H. S. (2000): Erythrocyte measurements in *Lacerta rudis* (Reptilia, Lacertidae).- *Turkish Journal of Zoology*, Ankara; 24: 207-209.
- SYKES, J. M. & KLAPHAKE, E. (2008): Reptile hematology.- *Veterinary Clinics of North America : Exotic Animal Practice*, New York etc.; 11: 481-500.
- SYPEK, J. & BORYSENKO, M. (1988): Reptiles. pp. 211-256. In: ROWLEY, A. F. & RATCLIFFE, N. A. (Eds.): *Vertebrate blood cells*. Cambridge (Cambridge University Press).
- SZARSKI, H. (1968): Evolution of cell size in lower vertebrates; pp. 445-453. In: ØRVIG, T. (Ed.): *Current problems of lower vertebrate phylogeny*. Proceedings of the fourth Noble Symposium held in June 1967 at the Swedish Museum of Natural History (Naturhistoriska riksmuseet) in Stockholm. Stockholm (Almqvist & Wiksell).
- SZARSKI, H. & CZOPEK, G. (1966): Erythrocyte diameter in some amphibians and reptiles.- *Bulletin of the Polish Academy of Sciences : Biological Sciences*, Warsaw; 14: 433-437.
- UETZ, P. & HOŠEK, J. (Eds.) (2016): The reptile database. WWW resource available at < <http://www.reptile-database.org> > [last accessed: 2016.02.08].
- UĞURTAŞ, İ. H. & SEVINÇ, M. & YILDIRIMHAN, H. S. (2003): Erythrocyte size and morphology of some tortoises and turtles from Turkey.- *Zoological Studies [SpringerOpen internet publication series]*; 42: 173-178.
- WINTROBE, M. M. (1933): Variations in the size and haemoglobin concentration of erythrocytes in the blood of various vertebrates.- *Folia Haematologica*, Leipzig; 51: 32-49.

DATE OF SUBMISSION: March 14, 2016

Corresponding editor: Heinz Grillitsch

AUTHORS: Onur UCA, Hüseyin ARIKAN & Kerim ÇIÇEK (Corresponding author < [kerim.cicek@hotmail.com](mailto:kerim.cicek@hotmail.com) > or < [kerim.cicek@ege.edu.tr](mailto:kerim.cicek@ege.edu.tr) >) – Ege University, Faculty of Science, Biology Department, Zoology Section, TR-35100, Bornova-Izmir, Turkey.

# ZOBODAT - [www.zobodat.at](http://www.zobodat.at)

Zoologisch-Botanische Datenbank/Zoological-Botanical Database

Digitale Literatur/Digital Literature

Zeitschrift/Journal: [Herpetozoa](#)

Jahr/Year: 2017

Band/Volume: [30\\_1\\_2](#)

Autor(en)/Author(s): Uca Onur, Arikan Hüseyin, Cicek Kerim

Artikel/Article: [Blood cell morphology of Turkish gekkonid lizards \(Squamata: Sauria: Gekkonidae, Phyllodactylidae\) 29-37](#)